




# Surgical Treatment of Upper Cervical Spine Trauma: Experience in a Regional Neurosurgery Unit in a Country with Limited Health Care Resources—About 22 Consecutive Cases

Mohameth Faye<sup>1,2,3</sup> Louncény Fatoumata Barry<sup>1</sup> Roger Mulumba Ilunga<sup>1</sup> Vital Nacoulma<sup>1</sup>  
El Hadji Cheikh Ndiaye Sy<sup>2</sup> Abdoulaye Diop<sup>1</sup> Tétéh Yav-Edem Aristide Donyo<sup>2</sup>  
Hugues Ghislain Atakla<sup>2</sup> Yakhya Cisse<sup>1,2</sup> Daouda Wague<sup>2</sup> Izoudine Blaise Koumare<sup>2</sup> Magatte Gaye<sup>3</sup> 

<sup>1</sup>Neurosurgery Unit, Thies Regional Hospital, Dakar, Senegal

<sup>2</sup>Neurosurgery Department, Fann Teaching Hospital, Dakar, Senegal

<sup>3</sup>Neurosurgery Department, Idrissa Pouye General Hospital, Dakar, Senegal

Address for correspondence Louncény Fatoumata Barry, MD, Neurosurgery Unit, Thies Regional Hospital Dakar, 5454, Senegal (e-mail: drlcbarry@gmail.com).

Asian J Neurosurg 2023;18:609–613.

## Abstract

**Objectives** Representing approximately 22% of cervical spine injuries, upper cervical spine injuries are becoming more frequent with the increase in road traffic accidents. The purpose of our study is to evaluate the results of our surgical series and to compare them with the literature.

**Materials and Methods** In this monocentric retrospective study of over three years (June 2019–May 2022), all the patients with traumatic injuries of the upper cervical spine with a surgical treatment and a minimum of 12 months follow-up were included.

**Results** The average age was 32.7 years, with a predominance of young patients. The predominant cause of injury was road traffic accident (86.3%). The clinical symptoms were cervical pain, associated with a motor deficit in two cases. Jefferson fracture associated with odontoid fracture was the most frequent injury (36.3%), followed by Hangman fracture (22.7%). Ten patients were treated with the Harms technique, four with occipitocervical C0-C2-C3 fixation, two with anterior screw insertion of the odontoid, and six with anterior C2-C3 arthrodesis. The average duration of follow-up was 12.2 months. The outcome was favorable in 21 cases and average in 1 case. Surgical morbidity and mortality were inexistent.

**Conclusion** This short series shows the effectiveness of surgical treatment in the managing traumatic injuries of the upper cervical spine and in the regression of the pain with a low risk of surgical morbidity and mortality.

## Keywords

- ▶ upper cervical spine
- ▶ trauma
- ▶ surgical treatment
- ▶ regional neurosurgery unit
- ▶ limited health care resources

article published online  
September 13, 2023

DOI <https://doi.org/10.1055/s-0043-1772761>.  
ISSN 2248-9614.

© 2023. Asian Congress of Neurological Surgeons. All rights reserved.

This is an open access article published by Thieme under the terms of the Creative Commons Attribution-NonDerivative-NonCommercial-License, permitting copying and reproduction so long as the original work is given appropriate credit. Contents may not be used for commercial purposes, or adapted, remixed, transformed or built upon. (<https://creativecommons.org/licenses/by-nc-nd/4.0/>)

Thieme Medical and Scientific Publishers Pvt. Ltd., A-12, 2nd Floor, Sector 2, Noida-201301 UP, India

## Introduction

Upper cervical spine (UCS) trauma is becoming increasingly common due to the increase in road traffic accidents (RTA). They represent about 22% of cervical spine traumas.<sup>1</sup> They are a serious pathology because of the damage to the osteoarticular, discoligamentary, and possibly bulbomedullary structures that they may cause.<sup>1,2</sup> However, the incidence of neurological deficit is relatively low in UCS trauma in contrast to lower cervical spine (LCS) trauma.<sup>3</sup>

The optimal management of these injuries is complex and should theoretically combine a rapid return to satisfactory autonomy while limiting the morbidity and mortality associated with prolonged inactivity and/or hospitalization.<sup>2</sup> Hence, the interest of surgical treatment. Recent work has demonstrated a theoretical advantage of surgical treatment in the management of UCS injuries with an improvement in quality of life and a decrease in morbidity and mortality.<sup>4</sup>

We report our series of 22 patients with UCS injuries managed with surgical intervention in order to evaluate our results and to compare them with the literature.

## Materials and Methods

We retrospectively studied over a period of three years (June 2019–May 2022) in which we included all patients who underwent surgical treatment of traumatic UCS injuries at the neurosurgery unit of the regional hospital of Thies (Senegal) and followed up for a minimum of 12 months.

Data collected included age, sex, clinical symptoms, American Spinal Injury Association (ASIA) score, type of traumatic injury, time to management, type of surgery, surgical morbidity, and mortality. Surgical fusion was assessed on a computed tomography (CT) scan performed at 3 months and 1 year after surgery. The appearance of a bone bridge between the fracture margins was considered as acquired fusion.

The outcome has been judged:

- Favorable by the complete regression of clinical symptomatology and by the achievement of bone fusion;
- Average by the persistence of clinical symptoms and/or the absence of bone fusion;
- Poor by the death of the patient.

The collected data were analyzed with the software SPSS version 21.0. The anonymity of the patients was preserved, and the study was exempted from the obligation to obtain ethical approval by the ethical committee of Thies Regional Hospital (Senegal).

## Results

Twenty-two patients were collected. They were 19 men and 3 women with a mean age of  $32.7 \pm 15.05$  years (extremes: 17 and 70 years) with a majority of young patients (►Fig. 1). The mechanism of injury was mainly due to RTA, in which 19 cases were victim of 14 motorcycle accidents and 5 car accidents, and two elderly falls at the home and one case fall from a tree. The symptoms were predominantly neck

pain, which was present in all patients. Only two patients had an associated neurological deficit, tetraparesis with an ASIA score of D. In case 2, there was an associated cranial trauma. The main characteristics of the study population are summarized in ►Table 1. CT scan was performed in all patients and combined with magnetic resonance imaging (MRI) in six patients, which allowed for injury assessment (►Table 2).

Ten patients were treated surgically by the Harms technique (►Fig. 2), four by a C0–C2–C3 occipitocervical fixation (►Fig. 3), two by an anterior screw insertion of the odontoid (►Fig. 4), and six by a C2–C3 arthrodesis by anterior approach (►Fig. 5). The average time to care was  $8.7 \pm 5.7$  days (extremes: 2 days and 27 days).

The mean follow-up time was  $12.2 \pm 1.2$  months (extremes: 12 and 18 months).

In all 22 patients, we did not record any surgical morbidity or mortality. The outcome was favorable in 21 cases (complete regression of cervical pain and motor deficit after physical therapy and fusion on the 12-month CT scan) and average in 1 case (pseudoarthrosis with persistent cervical pain, requiring revision surgery).

## Discussion

Data from the literature show that traumatic cervical spine injuries occur in young adults with a male majority, which are consistent with the results of our series.<sup>1,5</sup>

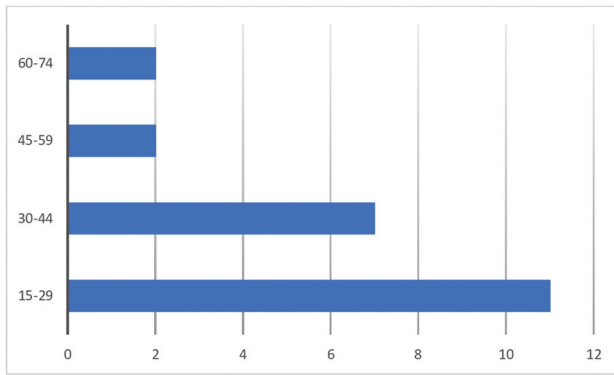
Of 231 patients with traumatic cervical spine injuries over the study period, 22 patients (9.5%) had surgery for UCS injuries, which is lower than the study by Alam et al<sup>1</sup> (22.22%) and Dickman et al<sup>6</sup> (25%).

Concerning the etiology, RAT was the most frequent etiology (19 cases). This is consistent with observations in the United Kingdom and the United States, where motor vehicle accidents top the list.<sup>6,7</sup>

The clinical presentations were typical. All patients described neck pain, associated with a neurological deficit in two patients of our series. Traumatic injuries of the UCS with neurological disorders are rare. In fact, when they do occur, they are serious and life-threatening due to compression of the medulla oblongata.<sup>1</sup>

Imaging is essential for diagnosis. The CT scan, performed in all our patients, is a key examination for the characterization of osteoarticular lesions, without overshadowing the standard radiography which, in order to be complete, must include a certain number of views: the frontal and lateral views. The open-mouth view of the face allows the study of the odontoid process.<sup>8</sup> As for MRI, it is performed urgently in case of a neurological deficit with normal radiography or CT scan, or in case of radioclinical discordance. However, its limited availability and high cost in our socioeconomic context limit its use (only 6 patients in our series). The injury assessment of our patients was performed with CT scan, which was sufficient to establish the injury assessment and surgical management in the majority of cases.

The lesions were dominated in our series by Jefferson fractures, although 8 cases were associated with an odontoid fracture, 16 cases were in the series of Kocis,<sup>9</sup> followed by



**Fig. 1** Distribution of patients by age group.

**Table 1** Characteristics of the study population

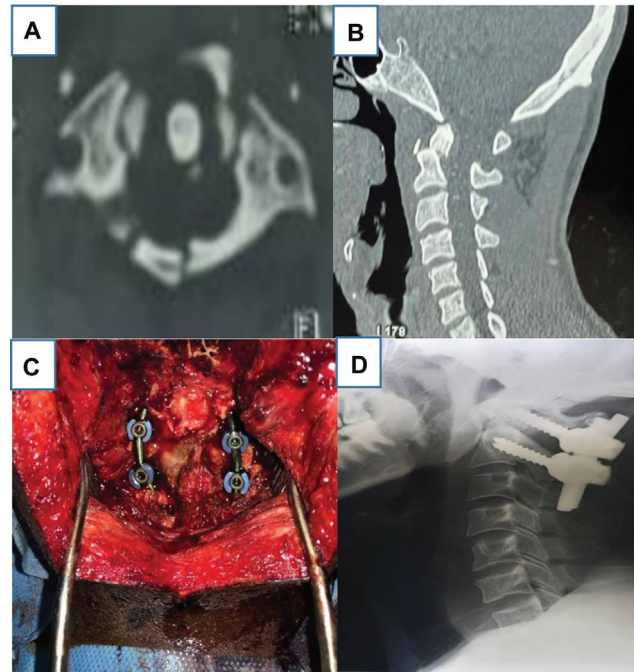
| Patients' characteristics         | n = 22      |
|-----------------------------------|-------------|
| Sex (M/F)                         | 19/3        |
| Mean age                          | 32,7 years  |
| <b>Circumstance of occurrence</b> |             |
| Road traffic accident             | 19          |
| Fall from its height              | 2           |
| Fall from a tree                  | 1           |
| <b>Clinical presentation</b>      |             |
| Neck pain                         | 22          |
| Tetraparesis ASIA D               | 2           |
| Head trauma                       | 2           |
| Average follow-up time            | 12,2 months |

**Table 2** Types of injuries

| Types of injuries                                    | n = 22 |
|------------------------------------------------------|--------|
| Jefferson fracture associated with odontoid fracture | 8      |
| C1-C2 dislocation                                    | 5      |
| Type II Anderson-Alonso (OBAR) fracture              | 2      |
| Hangman fracture (Effendi type II)                   | 5      |
| C2-C3 dislocation                                    | 1      |
| Posttraumatic basilar impression                     | 1      |

Hangman fracture (6 cases), and 24 cases were in the series of Samaha.<sup>10</sup> Contrary to our results, odontoid fractures are dominant in the geriatric series.<sup>2,4,11</sup>

Concerning the management, the literature reports different therapeutic possibilities for the treatment of traumatic injuries of the UCS: orthopaedic (external immobilization, foam cervical collar, corset, neck brace, cranial halo) or surgical (osteosynthesis). The surgery may be indicated for unstable fractures that are at neurological risk and are



**Fig. 2** Jefferson fracture associated with an odontoid fracture treated by the Harms technique: (A) Jefferson fracture, (B) odontoid fracture, and (C,D) Harms technique: intraoperative and postoperative images.

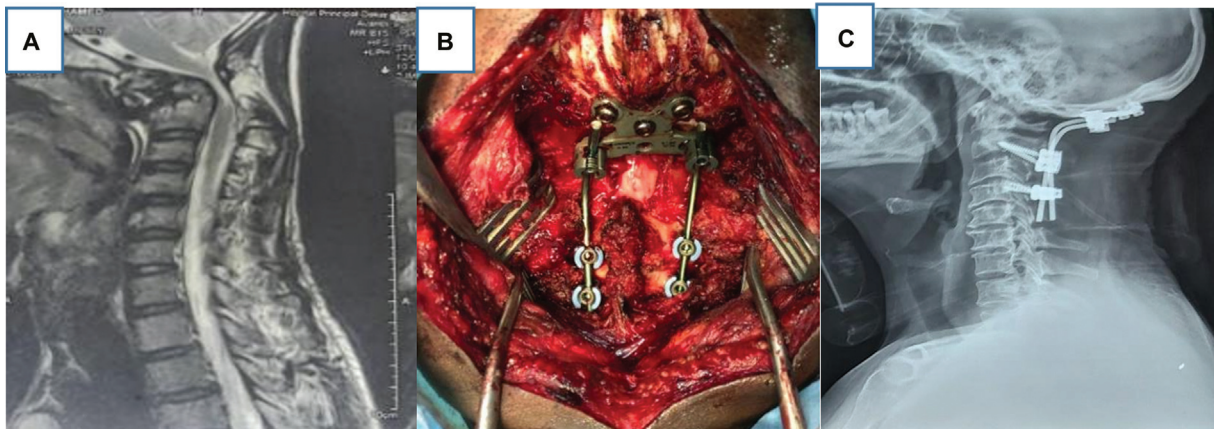
responsible for a significant rate of pseudarthrosis if not surgically corrected.<sup>11</sup>

The main indications for surgery in our series were severe neck pain and instability of the lesion. The choice of surgical technique is influenced by several parameters, notably the type of fracture, the quality of the bone, and the experience of the surgeon,<sup>4</sup> and in our context, the choice of surgical technique is influenced by the availability of osteosynthesis materials and the financial resources of the patients, most of whom do not have health insurance. Harms C1-C2 arthrodesis, used in the majority of patients in our series (45.4%), is a challenging technique, requiring a long learning curve. The main technical difficulty encountered is related to the bleeding associated with the abundance of venous plexuses around the C2 root and in front of the entry point in the lateral masses of C1. Dissection in the subperiosteal plane and the use of a drill will limit the bleeding. In the event of persistent bleeding, prolonged compression with swab is usually sufficient to control this bleeding of venous origin. Furthermore, the proximity of the C2 root, which is unprotected by a bony structure, should make the use of bipolar electrocautery preferable to monopolar one.<sup>4</sup>

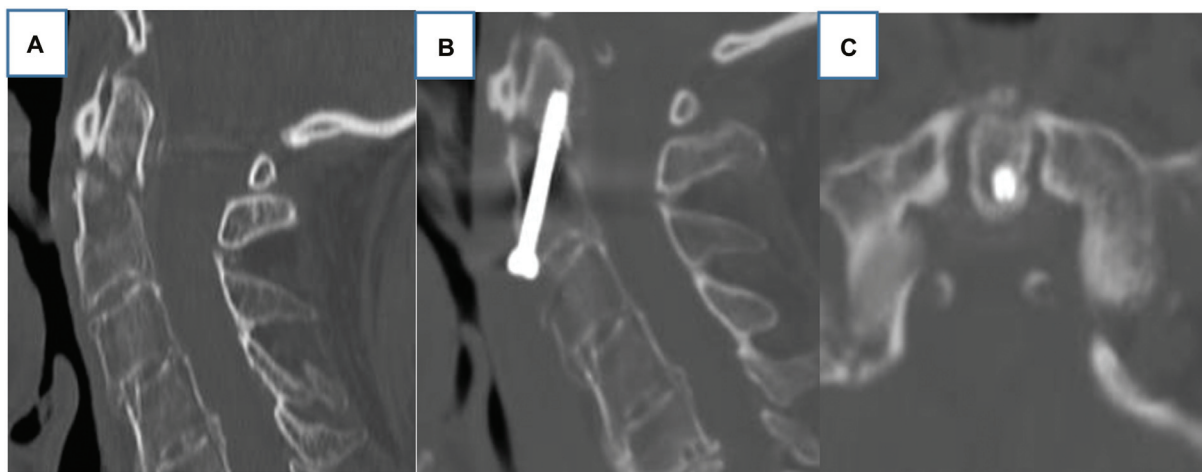
In a prospective level 2 study, Vaccaro et al<sup>12</sup> found a 95% rate of fusion in a series of patients operated on mainly using the Harms technique. In our series, the fusion rate was 95.4% at 1 year, with complete regression of neck pain and neurological deficit.

In the systematic review of the literature by Jubert et al,<sup>11</sup> 62% of the patients consolidated in the surgical group, versus 34% of the patients in the conservative treatment group.

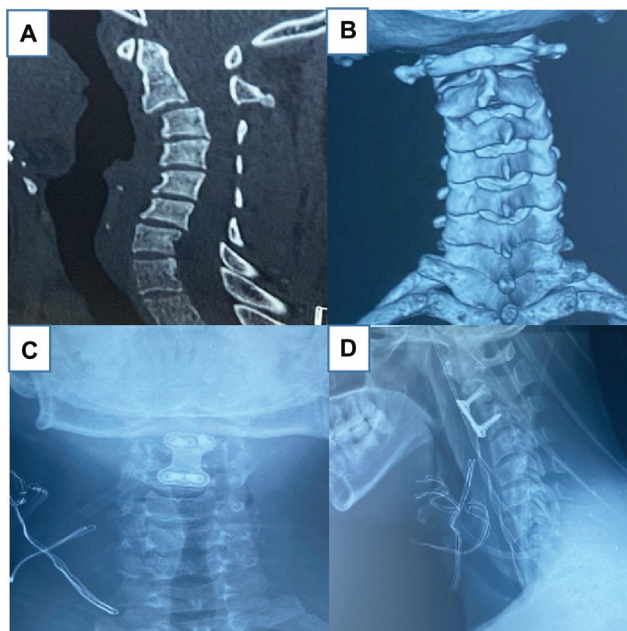




**Fig. 3** (A) Posttraumatic basilar impression. (B,C) C0-C2-C3 occipitocervical fixation: intraoperative and postoperative images.



**Fig. 4** (A) Anderson-Alonso type II odontoid fracture. (B,C) Odontoid screw insertion.



**Fig. 5** C2-C3 dislocation treated by C2-C3 arthrodesis through anterior approach. (A, B) C2-C3 dislocation, (C) frontal cervical X-ray, and (D) lateral cervical X-ray.

Morbidity was nonexistent in our series, 16 to 44% in geriatric series.<sup>4,11</sup> This absence of morbidity can be explained by the predominance of young subjects in the series.

Mortality was also zero in our series. Analysis of the survival curve of the general population shows a significant early mortality, since nearly 25% of patients die within the first three months.<sup>4</sup> Molinari et al<sup>13</sup> found a mortality rate at 3 months of 21% but their cohort contained 75% of nonoperated patients. In their group of operated patients, the 3-month mortality rate was 11%.

Limitations of this study include its retrospective nature and the lack of control group that underwent orthopaedic treatment. A comparison between surgical and orthopaedic treatment would have been illuminating, particularly with the rate of fusion and the risks of morbidity and mortality associated with each method.

### Conclusion

Traumatic injuries of the UCS are increasing, with a predominance of violent mechanism injuries in young subjects and low-energy injuries in older subjects. The surgical management of these injuries appears to be justified by the achievement of excellent

fusion rates allowing early restoration of previous autonomy. Our study shows the effectiveness of surgery for the fusion of these lesions and in the regression of the painful symptoms in these patients with a low risk of operative morbidity and mortality. The encouraging results of this study encourage us to propose further large-scale prospective evaluations of orthopaedic and surgical treatment in patients with UCS trauma.

#### Authors' Contributions

M.F., L.F.B., and R.M.I. conceptualized the article. V.N., E.C. N.S., A.D., T.Y.A.D., H.G.A., Y.C., D.W., I.B.K., and M.G. gathered the data. All the authors revised the article and approved the final draft of the article that was submitted. M.G. provided guidance toward the completion of the article.

This study was approved by the ethics committee of the regional hospital of Thies (Republic of Senegal).

#### Funding

None.

#### Conflict of Interest

None declared.

#### References

- 1 Alam N, Raziul HM, Kamaluddin M, et al. Cervical spinal injury: experience with 82 cases. *Int Congr Ser* 2002;1247:591–596
- 2 Faye M, Barry LF, Diop A, et al. [One-year evaluation of surgical treatment of upper cervical spine trauma in subjects over 80 years of age]. *Neurol Psychiatr Gériatr* 2020;21(124):243–247
- 3 Carlisle E, Truumees E, Herkowitz H. Cervical spine trauma in arthritic, stiff, or osteoporotic patients. *Semin Spine Surg* 2005; 17:1005
- 4 Faure A, Graillon T, Pesenti S, et al. [Trends in the surgical management of odontoid fractures in patients above 75 years of age: Retrospective study of 70 cases]. *Rev Chir Orthop Traumatol* 2017;103:892–899
- 5 Vieweg U, Meyer B, Schramm J. Differential treatment in acute upper cervical spine injuries. *Surg Neurol* 2000;54:203–211
- 6 Dickman CA, Hadley MN, Browner C, Sonntag VK. Neurosurgical management of acute atlas-axis combination fractures. A review of 25 cases. *J Neurosurg* 1989;70(01):45–49
- 7 Apuzzo ML, Heiden JS, Weiss MH, Ackerson TT, Harvey JP, Kurze T. Acute fractures of the odontoid process. An analysis of 45 cases. *J Neurosurg* 1978;48(01):85–91
- 8 Blery M, Rondeau Y, Tasu IP, Miquel A, Rocher I. [Cervical spine trauma in adults. An emergency imaging study]. *Feuill Radiol* 1999;39:87–98
- 9 Kocis J, Wendsche P, Visna P, Muzík V, Hart R. [Isolated fractures of the atlas]. *Acta Chir Orthop Traumatol Cech* 2004;71(01): 50–55
- 10 Samaha C, Lazennec JY, Laporte C, Saillant G. Hangman's fracture: the relationship between asymmetry and instability. *J Bone Joint Surg Br* 2000;82(07):1046–1052
- 11 Jubert P, Lonjon G, Garreau de Loubresse C. Bone and Joint Trauma Study Group GETRAUM. Complications of upper cervical spine trauma in elderly subjects. A systematic review of the literature. *Orthop Traumatol Surg Res* 2013;99:(06):S301–S312
- 12 Vaccaro AR, Kepler CK, Kopjar B, et al. Functional and quality-of-life outcomes in geriatric patients with type-II dens fracture. *J Bone Joint Surg Am* 2013;95(08):729–735
- 13 Molinari WJ III, Molinari RW, Khera OA, Gruhn WL. Functional outcomes, morbidity, mortality, and fracture healing in 58 consecutive patients with geriatric odontoid fracture treated with cervical collar or posterior fusion. *Global Spine J* 2013;3(01):21–32