



Contents lists available at ScienceDirect

International Journal of Surgery Case Reports

journal homepage: www.casereports.com

Multiple metastases after laparoscopic surgery for early-stage endometrial cancer: A case report

Saori Tsuji^{a,*}, Kensuke Hori^a, Lena Tashima^a, Michiko Yoshimura^b, Kimihiko Ito^a^a Department of Obstetrics and Gynecology, Kansai Rosai Hospital, 3-1-69, Inabaso, Amagasaki City, Hyogo Prefecture, Japan^b Department of Pathology, Kansai Rosai Hospital, 3-1-69, Inabaso, Amagasaki City, Hyogo Prefecture, Japan

ARTICLE INFO

Article history:

Received 17 July 2020

Received in revised form 3 October 2020

Accepted 3 October 2020

Available online 6 October 2020

Keywords:

Endometrial neoplasm

Surgery

Laparoscopic

Hysterectomy

Case report

ABSTRACT

INTRODUCTION: Laparoscopic surgery for early-stage endometrial cancer is associated with lower morbidity compared to open surgery and has comparable oncologic outcomes. We observed unexpected multiple metastases after laparoscopic surgery for endometrial cancer, the recurrence risk of which has previously been estimated to be low. Herein, we present this case and discuss the optimal management of endometrial cancer.

PRESENTATION OF CASE: A 58-year-old woman complaining of atypical genital bleeding lasting for 5 months was diagnosed with stage IA endometrioid carcinoma grade 1. According to our primary strategy, she underwent a total laparoscopic hysterectomy and bilateral salpingo-oophorectomy. The post-operative diagnosis was consistent with the pre-operative diagnosis. Since the recurrence risk was post-operatively revised to an intermediate level, she was administered adjuvant chemotherapy. However, multiple metastases were observed 4 months post-operatively, and despite treatment for recurrent disease, she died 2 months later. The uterine specimen was re-examined after the diagnosis of recurrence, and the post-operative diagnosis was revised to endometrioid carcinoma grade 3, indicating that her recurrence risk might have been underestimated.

DISCUSSION: The multiple metastases observed in this case, including those in the subcutaneous tissue, were presumably caused by pneumoperitoneum. Aspiration biopsy was used to confirm the histological diagnosis pre-operatively. However, dilation and curettage would have been preferable, considering aspiration biopsy provides limited diagnostic accuracy in some cases. Laparoscopic surgery is less invasive; however, it leads to a peculiar recurrence pattern, which is sometimes difficult to assess pre-operatively.

CONCLUSION: Physicians should carefully consider indications for laparoscopic surgery for malignant diseases.

© 2020 The Authors. Published by Elsevier Ltd on behalf of IJS Publishing Group Ltd. This is an open access article under the CC BY-NC-ND license (<http://creativecommons.org/licenses/by-nc-nd/4.0/>).

1. Introduction

Total laparoscopic hysterectomy (TLH) is recommended for endometrial cancer confined to the uterus because it results in lower morbidity and similar outcomes relative to total abdominal hysterectomy (TAH) [1–5]. Accordingly, our primary strategy for stage IA endometrioid carcinoma (EC) grade 1 or 2 (G1/2) was TLH and bilateral salpingo-oophorectomy (BSO). We herein report a rare case of unexpected multiple metastases after laparoscopic surgery for endometrial cancer and discuss the optimal management for endometrial cancer. This study has been reported in line with the Surgical Case Report (SCARE) 2018 criteria [6].

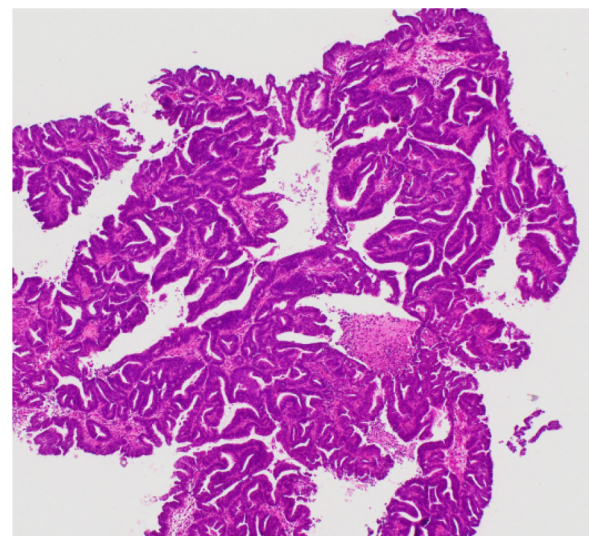


Fig. 1. Aspiration biopsy of the endometrium.

* Corresponding author.

E-mail addresses: s.tsuji@hp.pref.hyogo.jp (S. Tsuji),

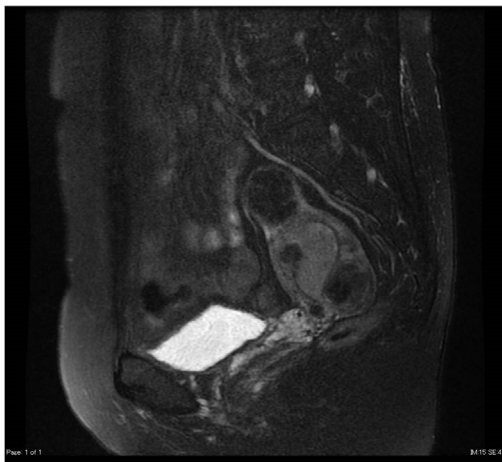
horikensuke@kansaihospital.jp (K. Hori), tashima-rina@kansaihospital.jp

(L. Tashima), yoshimuramichiko@kansaihospital.jp (M. Yoshimura),

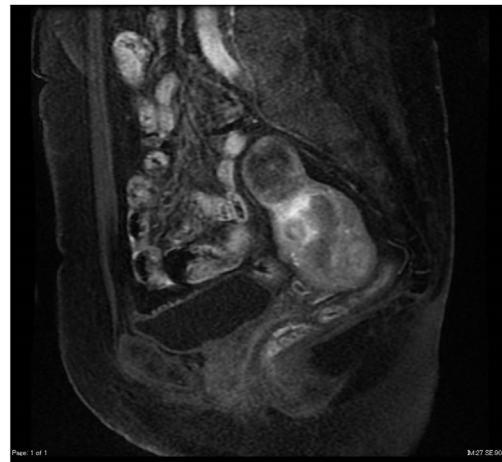
ito-kimihiko@kansaihospital.jp (K. Ito).

<https://doi.org/10.1016/j.ijscr.2020.10.003>

2210-2612/© 2020 The Authors. Published by Elsevier Ltd on behalf of IJS Publishing Group Ltd. This is an open access article under the CC BY-NC-ND license (<http://creativecommons.org/licenses/by-nc-nd/4.0/>).

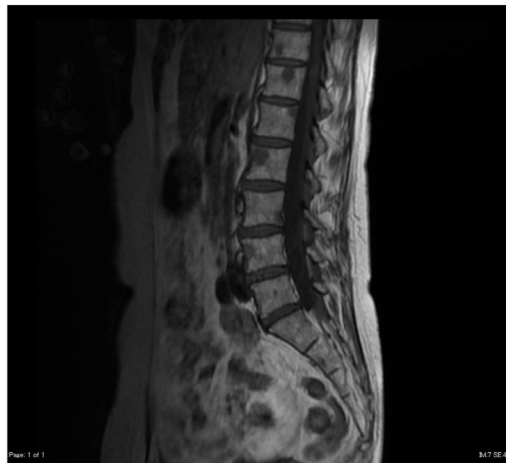

A

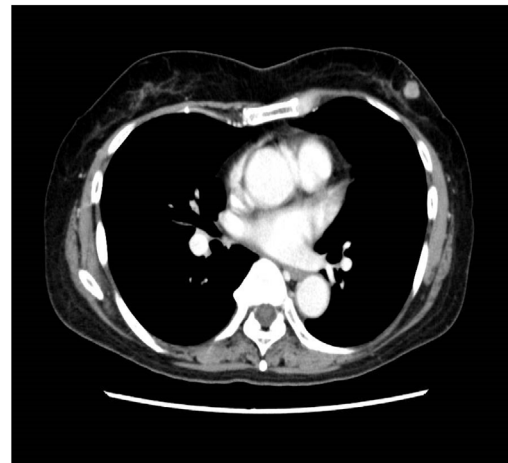


B

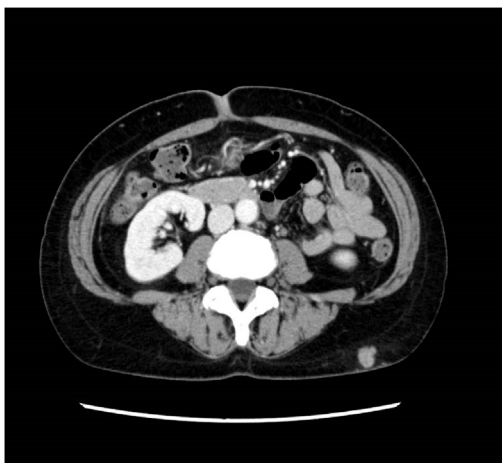Fig. 2. MRI Images Pre-operative MRI T2-weighted image (A) and contrast MRI (B). MRI, magnetic resonance imaging.



A



B



C

Fig. 3. Imaging of metastases Multiple metastases of the lumbar vertebrae (A), left mammary glands (B), and subcutaneous tissue (C).

2. Presentation of case

A 58-year-old Japanese woman presented with a complaint of atypical genital bleeding for 5 months. Her medical history included hypertension treated with cilnidipine 20 mg and valsartan 160 mg, daily. She was gravida 2 para 2 and had no relevant family history or allergies. The endometrial cytology was positive, and she was referred to our hospital. She was diagnosed with stage IA EC G1 by aspiration biopsy (Fig. 1), magnetic resonance imaging (MRI) (Fig. 2), and computed tomography (CT). Her recurrence risk was estimated to be low. According to our basic strategy, she underwent TLH and BSO, performed by a gynaecologic oncologist with 3 years of laparoscopic surgery training. The operation was performed under general anaesthesia in a lithotomy position, and we used CO₂ for pneumoperitoneum. Although the use of uterine manipulators does not reportedly influence oncologic outcomes [7–10], we still did not use them. We pre-operatively irrigated the vaginal cavity and performed the figure of eight suture on the cervix. Isolation bags were used in the course of removing the uterus through the vagina from the abdominal cavity. The operation was completed with no adverse effects. The post-operative diagnosis was stage IA EC G1. Her recurrence risk was revised post-surgery to intermediate because of lymphatic vessel invasion.

Consequently, she underwent three cycles of chemotherapy with doxorubicin (60 mg/m²) and cisplatin (50 mg/m²) every 3 weeks. She complained of back pain 4 months post-operatively,

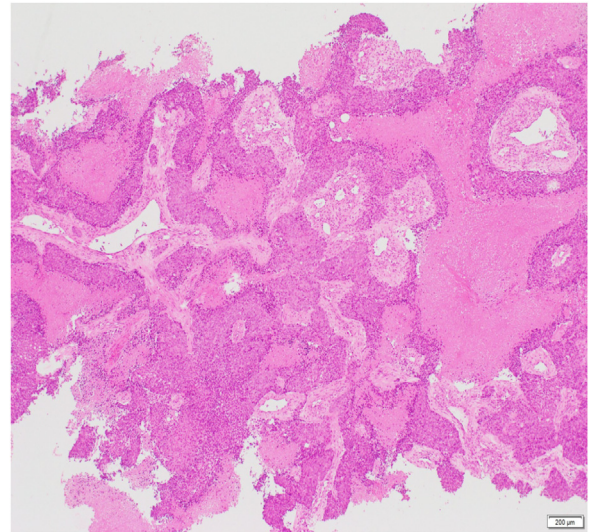


Fig. 4. Biopsy of the left mammary gland.

and multiple metastases were detected by MRI and CT (Fig. 3). The sites of recurrent disease included the lumbar vertebrae; right clavicle; left mammary glands; liver; right common iliac; internal iliac and external iliac lymph nodes; urethra; vagina; and subcutaneous

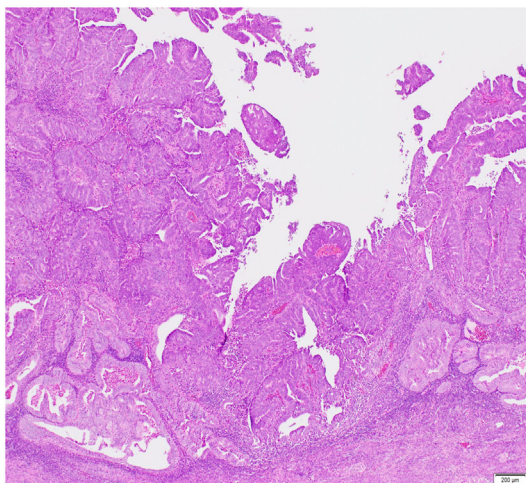
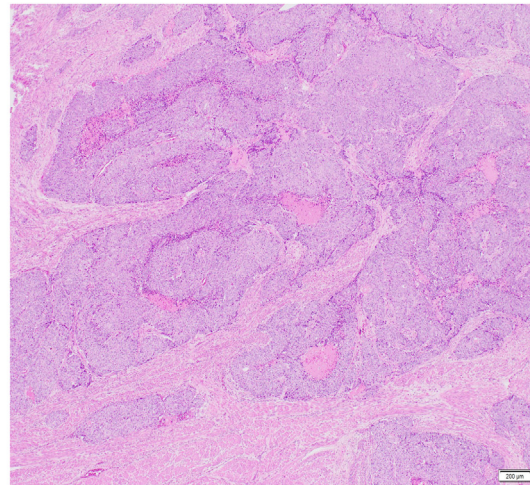
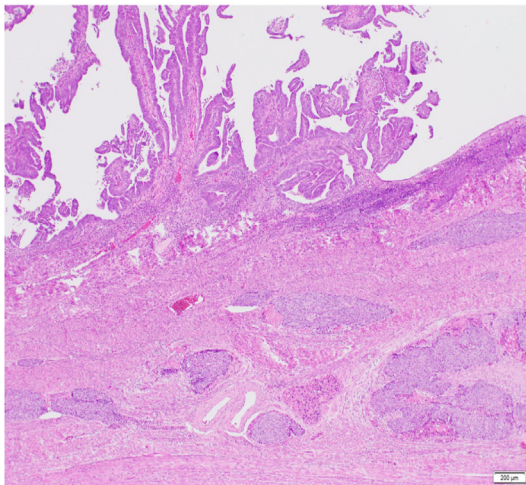


Fig. 5. Specimen of the uterus that was re-examined after recurrence.

adipose tissue. A left mammary gland biopsy confirmed recurrence (Fig. 4). Another pathologist re-examined the uterine specimen, and the patient's post-operative diagnosis was revised to EC G1+G3 (Fig. 5). She underwent one cycle of chemotherapy with paclitaxel (175 mg/m²), carboplatin (AUC = 5), and denosumab (120 mg, every 4 weeks), and radiation therapy (24 Gy/6 Fr for the right clavicle and 21 Gy/7 Fr for the right pelvis). However, she died of the disease 2 months later.

3. Discussion

We treated a patient with unexpected multiple metastases after a very short disease-free interval following laparoscopic surgery for endometrial cancer, although the recurrence risk had been estimated to be low pre-operatively. The strength of this case report is discussing such a rare pattern of recurrence. The recurrence risk is estimated based on lymphatic vessel invasion, depth of the lesion, cervical stromal invasion, extrauterine lesions, and histological type. In this case, the recurrence risk was revised post-operatively because of the occurrence of lymphatic vessel invasion, which cannot be estimated pre-operatively. However, based on the revised post-operative diagnosis, this patient should not have undergone TLH. Our primary strategies for EC G3 are TAH, BSO, pelvic lymphadenectomy, and para-aortic lymphadenectomy. Although aspiration biopsy has an accuracy nearly equal to that of dilation and curettage (D&C), it provides limited diagnostic accuracy in some cases [11,12]. Hence, the pre-operative histological diagnosis should have been confirmed with D&C. Additionally, accurately detecting the depth of the lesion and cervical stromal invasion is sometimes difficult. When opting for minimally invasive surgery, physicians should consider that the pre-operative recurrence risk might be underestimated.

Pre-operatively, our patient might have already developed metastases that could not be radiologically detected. However, it is unlikely that metastases had completely occurred pre-operatively. Oncologic outcomes depend on the stage and nature of the tumour. Considering the final diagnosis of stage IA EC G3 with lymphatic vessel invasion, which had an intermediate recurrence risk, the tumour was not estimated to be very aggressive. Therefore, factors other than the nature of the tumour itself might have affected the recurrence. Port-site metastases following robot-assisted laparoscopic surgery for gynaecological malignancies are reportedly more likely to develop in a specimen retrieval port than in a robotic port [13]. This implies that contact with the specimen is strongly associated with metastases. However, we used isolation bags, and contact with the specimen could not have occurred. Moreover, even if contact had occurred, this could only have caused metastases at the retrieval site or in the pelvic cavity. The use of pneumoperitoneum could explain the multiple metastases observed in this case, including those in the subcutaneous tissue. We pre-operatively irrigated the vaginal cavity and performed the figure of eight suture on the cervix to prevent tumour leakage from the uterine cavity. However, the complete prevention of tumour leakage from the uterine cavity remains uncertain. If the tumour had leaked into the vaginal cavity during the operation, the tumour could be scattered intraperitoneally or pushed into blood vessels and lymphatic vessels. Although no evidence has been found for pneumoperitoneum affecting tumour growth, cancer cell seeding, and metastases [14,15], it has been reported to provoke cancer cell implantation and growth in an animal model [16] and may trigger ovarian cancer cell proliferation in subcutaneous tissues [17]. It is also reported that viable tumour cells are produced in the surgical smoke from tumour dissection by powered devices, and they grow when implanted in mice [18]. Considering these factors, the pneumoperitoneum could explain why multiple metastases

occurred and grew so rapidly. However, there are no means to prove this hypothesis which is a limitation of this case report. Although metastases caused by pneumoperitoneum might be rare, especially in the early stages, they are peculiar to laparoscopic surgery, and physicians should not ignore such a possibility when opting for laparoscopic surgery to treat malignancies.

4. Conclusion

TLH is a beneficial treatment for endometrial cancer because it is minimally invasive. However, it is associated with poor oncologic outcomes when performed on patients with moderate to high recurrence risk. Physicians should be prudent when opting for TLH for malignancies because it is challenging to evaluate the recurrence risk accurately. Histological accuracy could improve if the diagnosis is confirmed with D&C. Similarly, it is noteworthy that a peculiar recurrence pattern is associated with laparoscopic surgery, although it is rare.

Declaration of Competing Interest

The authors report no declarations of interest.

Funding

This research did not receive any specific grant from funding agencies in the public, commercial, or not-for-profit sectors.

Ethical approval

This study was approved by the Institutional Review Board (Approval Number: 20180424).

Consent

Written informed consent was obtained from the patient for publication of this case report and accompanying images. A copy of the written consent is available for review by the Editor-in-Chief of this journal on request.

Author contribution

Saori Tsuji (Corresponding author): Conceptualization, Methodology, Formal analysis, Investigation, and Writing – Original Draft.
Kensuke Hori: Conceptualization, Methodology, Investigation, and Writing – Review & Editing.
Lena Tashima: Investigation.
Michiko Yoshimura: Investigation.
Kimihiro Ito: Conceptualization, Methodology, Investigation, Writing – Review & Editing, and Supervision.

Registration of research studies

N/A.

Guarantor

Saori Tsuji.

Provenance and peer review

Not commissioned, externally peer-reviewed.

Data statement

Data sharing is not applicable, as no datasets were generated or analysed during the current study.

Acknowledgements

We would like to thank Editage (www.editage.com) for English language editing. We would like to thank Michiko Yamashita, Emi Yoshioka and Mayako Goto for their contribution to the investigation.

References

- [1] J.L. Walker, M.R. Piedmonte, N.M. Spirtos, S.M. Eisenkop, J.B. Schlaerth, R.S. Mannel, et al., Recurrence and survival after random assignment to laparoscopy versus laparotomy for comprehensive surgical staging of uterine cancer: Gynecologic Oncology Group LAP2 Study, *J. Clin. Oncol.* 30 (2012) 695–700, <http://dx.doi.org/10.1200/jco.2011.38.8645>.
- [2] A.B. Kornblith, H.Q. Huang, J.L. Walker, N.M. Spirtos, J. Rotmensch, D. Cella, Quality of life of patients with endometrial cancer undergoing laparoscopic international federation of gynecology and obstetrics staging compared with laparotomy: a Gynecologic Oncology Group study, *J. Clin. Oncol.* 27 (2009) 5337–5342, <http://dx.doi.org/10.1200/jco.2009.22.3529>.
- [3] M. Janda, V. GebSKI, L.C. Davies, P. Forder, A. Brand, R. Hogg, et al., Effect of total laparoscopic hysterectomy vs total abdominal hysterectomy on disease-free survival among women with stage I endometrial cancer: a randomised clinical trial, *JAMA* 317 (2017) 1224–1233, <http://dx.doi.org/10.1001/jama.2017.2068>.
- [4] K. Galaal, A. Bryant, A.D. Fisher, M. Al-Khaduri, F. Kew, A.D. Lopes, Laparoscopy versus laparotomy for the management of early stage endometrial cancer, *Cochrane Database Syst. Rev.* (2012), CD006655, <http://dx.doi.org/10.1002/14651858.cd006655>.
- [5] M. Janda, V. GebSKI, A. Brand, R. Hogg, T.W. Jobling, R. Land, et al., Quality of life after total laparoscopic hysterectomy versus total abdominal hysterectomy for stage I endometrial cancer (LACE): a randomised trial, *Lancet Oncol.* 11 (2010) 772–780, [http://dx.doi.org/10.1016/s1470-2045\(10\)70145-5](http://dx.doi.org/10.1016/s1470-2045(10)70145-5).
- [6] R.A. Agha, M.R. Borrelli, R. Farwana, K. Koshy, A. Fowler, D.P. Orgill, et al., The SCARE 2018 statement: updating consensus Surgical Case Report (SCARE) guidelines, *Int. J. Surg.* 60 (2018) 132–136.
- [7] S. Uccella, M. Bonzini, M. Malzoni, F. Fanfani, S. Palomba, G. Aletti, et al., The effect of a uterine manipulator on the recurrence and mortality of endometrial cancer: a multi-centric study by the Italian Society of Gynecological Endoscopy, *Am. J. Obstet. Gynecol.* 216 (592) (2017) e1–11, <http://dx.doi.org/10.1016/j.ajog.2017.01.027>.
- [8] J. Marcos-Sanmartín, J.A. López Fernández, J. Sánchez-Payá, ÓC. Piñero-Sánchez, M.J. Román-Sánchez, M.A. Quijada-Cazorla, et al., Does the type of surgical approach and the use of uterine manipulators influence the disease-free survival and recurrence rates in early-stage endometrial cancer? *Int. J. Gynecol. Cancer* 26 (2016) 1722–1726, <http://dx.doi.org/10.1097/igc.0000000000000808>.
- [9] R. Tinelli, E. Cicinelli, A. Tinelli, S. Bettocchi, S. Angioni, P. Litta, Laparoscopic treatment of early-stage endometrial cancer with and without uterine manipulator: our experience and review of literature, *Surg. Oncol.* 25 (2016) 98–103, <http://dx.doi.org/10.1016/j.suronc.2016.03.005>.
- [10] M. Lee, Y.T. Kim, S.W. Kim, S. Kim, J.H. Kim, E.J. Nam, Effects of uterine manipulation on surgical outcomes in laparoscopic management of endometrial cancer: a prospective randomised clinical trial, *Int. J. Gynecol. Cancer* 23 (2013) 372–379, <http://dx.doi.org/10.1097/igc.0b013e3182788485>.
- [11] M. Sanam, M.M.K. Majid, Comparison the diagnostic value of dilation and curettage versus endometrial biopsy by Pipelle—a clinical trial, *Asian Pac. J. Cancer Prev.* 16 (2015) 4971–4975, <http://dx.doi.org/10.7314/apjcp.2015.16.12.4971>.
- [12] M. Kazandi, F. Okmen, A.M. Ergenoglu, A.O. Yeniel, B. Zeybek, O. Zekioglu, et al., Comparison of the success of histopathological diagnosis with dilation-curettage and Pipelle endometrial sampling, *J. Obstet. Gynaecol.* 32 (2012) 790–794, <http://dx.doi.org/10.3109/01443615.2012.719944>.
- [13] C. Lönnerfors, T. Bossmar, J. Persson, Port-site metastases following robot-assisted laparoscopic surgery for gynecological malignancies, *Acta Obstet. Gynecol. Scand.* 92 (2013) 1361–1368, <http://dx.doi.org/10.1111/aogs.12245>.
- [14] C. Fu, G.Y. Li, F.Y. Liu, Q.H. Lin, X.L. Fang, Effect of carbon dioxide pneumoperitoneum-laparoscopic surgery on tumor seeding and metastases in endometrial cancer, *Zhong Nan Da Xue Xue Bao Yi Xue Ban* 33 (2008) 130–137.
- [15] F. Lécureu, A. Aqositini, S. Camatte, F. Robin, M. Aggerbeck, J.P. Jaïs, et al., Impact on pneumoperitoneum on tumor growth, *Surg. Endosc.* 16 (2002) 1170–1174, <http://dx.doi.org/10.1007/s00464-001-9226-z>.
- [16] J. Volz, S. Köster, Z. Spacek, N. Paweletz, The influence of pneumoperitoneum used in laparoscopic surgery on an intraabdominal tumor growth, *Cancer* 86 (1999) 770–774, [http://dx.doi.org/10.1002/\(sici\)1097-0142\(19990901\)86:5<770::aid-cnrc11>3.0.co;2-3](http://dx.doi.org/10.1002/(sici)1097-0142(19990901)86:5<770::aid-cnrc11>3.0.co;2-3).
- [17] J.W. Lee, Y.A. Park, Y.J. Cho, K.H. Kang, J.J. Choi, Y.Y. Lee, et al., The effect of surgical wound on ovarian carcinoma growth in an animal model, *Anticancer Res.* 33 (2013) 3177–3184.
- [18] S.M. In, D.Y. Park, I.K. Sohn, C.H. Kim, H.L. Lim, S.A. Hong, et al., Experimental study of the potential hazards of surgical smoke from powered instruments, *Br. J. Surg.* 102 (12) (2015) 1581–1586, <http://dx.doi.org/10.1002/bjs.9910>.

Open Access

This article is published Open Access at sciedirect.com. It is distributed under the [IJSCR Supplemental terms and conditions](#), which permits unrestricted non commercial use, distribution, and reproduction in any medium, provided the original authors and source are credited.