

CASE REPORT

A case of reversible hyperoxaluria nephropathy early after roux-en-y-gastric bypass induced by vitamin C intake

Said Farhat^{1,*}, Abtar Houssam², Ali Ghassaoui³, El Ajami Khaled¹, and Mansour El Khoury³

¹Gastroenterology Division, Saint Georges Hospital University Medical Center, University of Balamand, Beirut, Lebanon, ²General Surgery Division, Central Military Hospital, Beirut, Lebanon, and ³General Surgery Division, Saint Georges Hospital University Medical Center, University of Balamand, Beirut, Lebanon

*Corresponding address. Saint Georges Hospital University Medical Center, University of Balamand, P.O. Box 166 378, Achrafieh, Beirut 11 00 2807, Lebanon. Tel: +961-1-441-000 or +961-1-575-700; Fax: +961-1-582-560; E-mail: saidfarhat@hotmail.com

Abstract

Roux-en-y-gastric bypass (RYGB) is the most commonly performed bariatric procedure worldwide which is taking the lead in resolving of comorbid conditions. Short- and long-term complications of RYGB procedure have been recognized, including osteopenia, osteomalacia and more rarely neurological disorders. Oxalate nephropathy is a complication of RYGB that has been described earlier in the literature and may end with renal failure and dialysis if not recognized and treated early. The etiology of this phenomenon is still unclear, but the length of common limb remains the theory that mostly contributed to its development. We believe that this limb should be more than 100 cm to prevent severe malabsorption. Here, we report a reversible case of oxalate nephropathy 3 months after RYGB in a 51-year-old patient.

INTRODUCTION

Nearly 35% of adults aged 20 years and over were overweight in 2008, and 11% were obese according to the World Health Organization (WHO); this percentage will continue to increase with time. Roux-en-y-gastric bypass (RYGB) is the most common procedure done and leads to improvements in weight, sugar levels, insulin resistance, cardiovascular risk factors and sleep apnea. Although both short- and long-term complications of RYGB procedure have been recognized, including osteopenia, osteomalacia, and more rarely neurological disorders, the procedure has been deemed relatively safe and effective [1].

Recent data suggest that modern bariatric procedures, such as RYGB, may also impart a 2-fold increased risk of nephrolithiasis,

whereas 20–75% of patients may have hyperoxaluria, including 20% with very high urine oxalate levels, also putting them at considerable risk of oxalate nephropathy [2].

CASE REPORT

We report a case of RYGB that leads to oxalate nephropathy 3 months after the procedure: a 51-year-old male patient with type 2 diabetes mellitus and a body mass index (BMI) of 42 kg/m² (Table 1). A standard RYGB procedure was performed, and a 30–50 ml gastric pouch was created; the length of the Roux segment was 150 cm, and the length of the jejunum from the ligament of Treitz to the jejuno-jejunal anastomosis was 40 cm.

Received: November 25, 2015. Revised: May 24, 2016. Accepted: May 31, 2016

© The Author 2016. Published by Oxford University Press.

This is an Open Access article distributed under the terms of the Creative Commons Attribution Non-Commercial License (<http://creativecommons.org/licenses/by-nc/4.0/>), which permits non-commercial re-use, distribution, and reproduction in any medium, provided the original work is properly cited. For commercial re-use, please contact journals.permissions@oup.com

Three months after the procedure, the patient started complaining of productive cough, chills and bilateral flank pain over a period of 2 days associated with decreased fluid intake and low urine output. He was found to have elevated creatinine on laboratory workup (8.42 mg/dl). He was admitted for further investigation and was started on the appropriate antibiotics for the diagnosis of pneumonia. During history taking, the patient was found to be on non-steroidal anti-inflammatory drugs (NSAIDs) (ibuprofen) and high-dose vitamin C, 1 g/day which is much higher than the normal dose (75 mg for women and 90 mg for men) on his own. His creatinine continued to increase during his stay at the hospital reaching 9.5 mg/dl and was oliguric. Twenty-four-hour urine oxalate level was 80 mg (normal range = 4–31 mg/24 h), and CT scan was done to rule out obstructive nephropathy. Kidney biopsy specimen was obtained, and it showed deposition of calcium oxalate crystals in the lumen of few tubules compatible with oxalate nephropathy (Fig. 1). He was started on intravenous (IV) hydration, high oral calcium supplementation (1500 mg/day), low oxalate diet and steroid therapy (20 mg/day) as treatment for acute interstitial nephritis (AIN). After this regimen, the urine volume increased and his creatinine level decreased. Progressively creatinine decreased to reach 1.9 mg/dl 10 days after (Fig. 2). During a period of 3 months, the patient got readmitted twice: once for gastroenteritis and once for bilateral lower limbs edema, and investigations revealed low total protein, albumin levels and generalized fatigue. For this reason, decision was taken to reverse the RYGB.

Table 1. Patient's demographics and biochemical results

Characteristics	
Sex	Male
Age (year)	51
BMI (kg/m ²)	42
Renal function	Normal
Diabetes mellitus	Yes
Hypertension	No
Hyperlipidemia	No
Chronic obstructive pulmonary disease	No
Smoker	Yes
Biochemical results on admission	
Serum creatinine (mg/dl)	8.42
24 h Urine oxalate level (mg)	80

DISCUSSION

Oxalate nephropathy is a complication of RYGB that has been described earlier in the literature and will be encountered more frequently clinically, in our opinion, as the number of bariatric operations is increasing, especially RYGB. In the study done by Nasr et al. [3], 11 patients presented with acute kidney injury (AKI) 6 months after RYGB and were diagnosed with oxalate nephropathy. In another study done by Sinha et al. [1], 31 patients had oxalate nephropathy 2.2 years post RYGB. Oxalate nephropathy was seen also in kidney transplant recipient patients 27 and 7 years, respectively, after RYGB as described by Troxell et al. [2]. Matlaga et al. [4] showed that nephrolithiasis incidence after RYGB is 7.65% (in a study with 4639 RYGB patients) when compared with 4.63% in the same number of patients that did not undergo bariatric operation. Our patient presented with AKI (creatinine = 8.42 mg/dl) 3 months after the operation, which has never been reported before.

We think that the etiology of this early formation of oxalate deposits was multifactorial including: RYGB by itself as a malabsorptive factor, high dose of vitamin C intake, NSAIDs that the patient was taking to relieve the flank pain, high oxalate diet (coffee, chocolates, cocoa) and low fluid intake by the patient over 24 h that led to low urinary volumes.

According to several studies, the use of traditional NSAIDs is well established to be associated with AKI with relative risks compared with non-user ranging from 1.6 to 2.2. Indomethacin users account for the highest risk ratio of developing AKI. NSAIDs can cause AKI by two different mechanisms: hemodynamically mediated [decrease in prostaglandin (PG) synthesis due to inhibition of cyclooxygenase (COX-1) enzymes in combination with renal vasoconstriction] and AIN [5].

Vitamin C is believed to result in a hyperoxaluric state. The recommended daily intake of vitamin C is between 75 and 90 mg/day. Several cases of oxalate nephropathy have been reported with vitamin C intake <2 g/day [6]. The mechanism of oxalate deposit formation is contributed by the increased fat malabsorption which leads to increased colonic fat that binds to free calcium, increasing unbound oxalate that is able to cross the colonic mucosa. In malabsorptive states (like after RYGB), the percentage of oxalate absorbed from the gut and excreted in urine can be markedly increased and hyperoxaluria often correlates with steatorrhea [7].

The pathogenesis of hyperoxaluria after RYGB is not completely understood, but the length of the common channel is

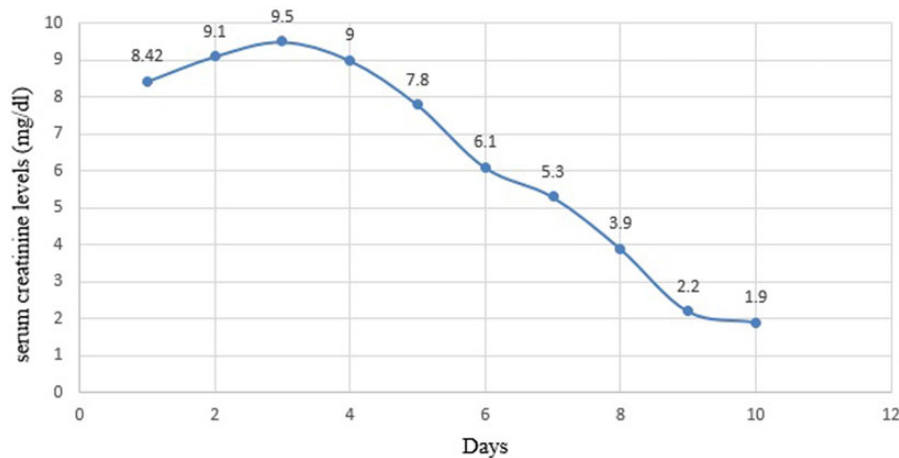


Figure 2. Serum creatinine level changes during hospital stay.

one of the most important factors leading to significant fat malabsorption in some, causing enteric hyperoxaluria. Although RYGB operation with a Roux limb of <150 cm in length is generally believed not to cause fat malabsorption, data suggest that hyperoxaluria may indeed occur, and represent a risk for calcium oxalate nephrolithiasis [1].

Some earlier studies of patients with inflammatory bowel disease correlate the degree of hyperoxaluria with the degree of steatorrhea; this pathogenesis might explain why patients who have had distal RYGB (through creation of a longer Roux limb and subsequently shorter common channel for nutrient absorption) can be at higher risk for developing calcium oxalate kidney stones compared with standard RYGB patients [8].

The goal of management is to reach normal creatinine levels and normal diuresis. Many treatments can be applied starting with oxalate-free diet, limit fat intake, appropriate hydration to maintain urine output of at least 2 l, oral calcium supplementation and reversal of the surgery [9]. This strategy, if applied early, can reverse the nephropathy and can prevent irreversible tubular damage leading to dialysis. More recent treatments like supplementation of *Oxalobacter formigenes* bacteria, a normal commensurate part of the human gut microflora which metabolizes oxalate as an energy source have been applied and showed promising results by reducing the urinary oxalate levels [1].

In conclusion, surgeons should be aware of this complication and be aggressive in their treatment strategies in order not to reach dialysis. We suggest counting accurately the length of the common channel during each gastric bypass as well as maintaining oxalate-free and fat-free diet with oral calcium supplementation postoperatively.

CONFLICT OF INTEREST STATEMENT

None declared.

FUNDING

There were no sources of funding.

ETHICAL APPROVAL

No ethical approval is required.

CONSENT

Written informed consent was obtained from the patient for the publication of this case report.

GUARANTORS

F.S. and H.A. are guarantors of this study.

REFERENCES

1. Sinha MK, Collazo-Clavell ML, Rule A, Milliner DS, Nelson W, Sarr MG, et al. Hyperoxaluric nephrolithiasis is a complication of roux-en-y gastric bypass surgery. *Kidney Int* 2007;72:100–7.
2. Troxell ML, Houghton DC, Hawkey M, Batiuk TD, Bennett WM. Enteric oxalate nephropathy in the renal allograft: an under-recognized complication of bariatric surgery. *Am J Transplant* 2013;13:501–9.
3. Nasr SH, D'Agati VD, Said SM, Stokes MB, Largoza MV, Radhakrishnan J, et al. Oxalate nephropathy complicating roux-en-y gastric bypass: an underrecognized cause of irreversible cause of irreversible renal failure. *Clin J Am Soc Nephrol* 2008;3:1676–83.
4. Matlaga BR, Shore AD, Magnuson T, Clark JM, Johns R, Makary MA. Effect of gastric bypass surgery on kidney stone disease. *J Urol* 2009;181:2573–7.
5. Ungprasert P, Cheungpasitporn W, Crowson CS, Matteson EL. Individual non-steroidal anti-inflammatory drugs and risk of acute kidney injury: a systematic review and meta-analysis of observational studies. *Eur J Intern Med* 2015;26:285–91.
6. Sunkara V, Pelkowski TD, Dreyfus D, Satoskar A. Acute kidney disease due to excessive vitamin C ingestion and remote roux-en-y gastric bypass surgery superimposed on CKD. *Am J Kidney Dis* 2015;66:721–4.
7. Kumar R, Lieske JC, Collazo-Clavell ML, Sarr MG, Olson ER, Vrtiska TJ et al. Fat malabsorption and increased intestinal absorption are common after roux-en-y gastric bypass surgery. *Surgery* 2011;149:654–61.
8. Duffey BG, Pedro RN, Makhlof A, Kriedberg C, Stessman M, Hinck B, et al. Roux-en-y gastric bypass is associated with early increased risk factors for development of calcium oxalate nephrolithiasis. *J Am Coll Surg* 2008;206:1145–53.
9. Whitson J, Stackhouse G, Stoller M. Hyperoxaluria after modern bariatric surgery: case series and literature review. *Int Urol Nephrol*. 2010;42:369–74.