

Case Report

Skin and mucosal ischemia as a complication after inferior alveolar nerve block

Pedro Christian Aravena¹, Camila Valeria², Nicolás Nuñez², Francisco Perez-Rojas³, Cesar Coronado⁴

¹Department of Anatomy, Histology and Patology, Faculty of Medicine, Austral University of Chile, Valdivia, ²Dental School, Faculty of Medicine, School of Dentistry, Austral University of Chile, Valdivia, ³Department of Human Anatomy, Faculty of Health Science, Autónoma University of Chile, Talca, ⁴Department of Morphofuntion, Faculty of Medicine, Universidad Diego Portales, Santiago, Chile

ABSTRACT

The anesthetic block of the inferior alveolar nerve (IAN) is one of the most common techniques used in dental practice. The local complications are due to the failures on the anesthetic block or to anatomic variations in the tap site such as intravascular injection, skin ischemia and ocular problems. The aim of this article is to present a case and discuss the causes of itching and burning sensation, blanching, pain and face ischemia in the oral cavity during the IAN block.

Key Words: Anesthesia, inferior alveolar, ischemia, local, mandibular nerve, nerve block

Received: November 2015
Accepted: August 2016

Address for correspondence:
Dr. Pedro Christian Aravena,
Rudloff Street, #1640,
Valdivia, Chile.
E-mail: paravena@uach.cl

INTRODUCTION

The troncular anesthetic technique to the inferior alveolar nerve (IAN) or “Halstead technique,”^[1] is the block of the IAN and lingual nerve through the deposit of local anesthetic in the pterygomandibular space, making possible the development of surgical and dental procedures in the hemimandible.^[2] The local complications are due to the failures in the anesthetic technique or to anatomic variations.^[3] One of the most common local complications associated with the anatomic site is the intravascular tap, which is reported as a rate of blood-positive aspiration from 0.5%^[4] to 31.3% in a second injection.^[5] This intravascular tap can cause complications such as dizziness,^[6] blanching and skin pain,^[6-8] and ocular problems.^[8-11] These complications are temporary, reporting a resolution between 5 and 45 min after the injection.^[8]

The reported cases^[6-8,10,11] are consistent in pointing out the superficial effect of the anesthetic block of

IAN on the skin and attached neighbouring orbital structures. However, there are very few reports^[12] about the presence of itching and burning sensations, blanching, pain, and face ischemia in the oral cavity during the IAN block. The aim of this article is to present an unusual case of troncular anesthesia of the IAN that included temporary ischemia in the branches of the maxillary artery. The present report was based on the Case Report Guideline (CARE)^[13] instruction and was approved for its dissemination by the Medicine Faculty Ethics Committee of the Universidad Austral de Chile.

CASE REPORT

A 21-year-old female, Caucasian, ASA I with no associated comorbidity, university student, presented at the dental service of the Universidad Austral de

This is an open access article distributed under the terms of the Creative Commons Attribution-NonCommercial-ShareAlike 3.0 License, which allows others to remix, tweak, and build upon the work non-commercially, as long as the author is credited and the new creations are licensed under the identical terms.

For reprints contact: reprints@medknow.com

How to cite this article: Aravena PC, Valeria C, Nuñez N, Perez-Rojas F, Coronado C. Skin and mucosal ischemia as a complication after inferior alveolar nerve block. Dent Res J 2016;13:560-3.

Access this article online



Website: www.drj.ir
www.drjjournal.net
www.ncbi.nlm.nih.gov/pmc/journals/1480

Chile on January 5, 2014, to get fillings treatment for superficial dental caries in teeth 35 and 36. Her clinical history did not show surgical interventions under general anesthesia. It reported previous dental filling treatments with the use of local anesthetic with no manifestation of any complication. The intraoral examination showed a good rate of oral hygiene, with no presence of gingivitis or any other injury of the delicate tissues. For the treatment, the dentist decided to use the troncular technique to the IAN or the Halstead technique according to the one described by Malamed^[2] using a carpule syringe with a 27-gauge 0.4 mm × 25 mm needle (Terumo Corporation, Japan) and only one vial of articaine hydrochloride 4% with epinephrine 1:100,000 (Nova-FL®, Brazil). The dental crown notch, pterygomandibular raphe, and the occlusal plane of the left mandibular molars were considered for the point of injection. Setting the body of the carpule on the opposite side, the dentist set the tip of the needle to the level of the retromolar space and injected approximately 0.3 ml of anesthetic solution into the mouth nerve and then penetrated with the needle into delicate tissue 25 mm approximately until osseous contact. Blood content was observed in the rest of anesthesia cartridge, verifying the positive aspiration of the intravascular tap [Figure 1].

At the moment of the injection, the patient immediately informed of an itching and burning feeling in the nasal and palatine mucosa, without the pain and dizziness associated with the tap. In the clinical examination, numbness was recorded in the left genial region, endangering the lower eyelid, wing of the nose, and upper lip on the left side of the face. The intraoral examination revealed an ischemia of the left mouth mucosa, end of vestibule of the left upper lip, loose and stuck gum between the maxillary teeth 21 and 28 [Figure 2], and palatine mucosa from the median raphe to the palatal alveolar processes [Figure 3]. Due to the clinical picture, the intervention was partially suspended. After 5 min, the patient showed dysesthesia of the lower lip, gum and half of the tongue on the left side; she did not have any visual or nasal complications. She did not present any ocular complications such as double vision, blepharoptosis, miosis, anhidrosis, anisocoria, or others.

After 10 min, gradual recovery was observed of the normal skin color and a pale pink at the end of the buccal space and palatine mucosa. Fifteen minutes after administration of the anesthesia, the anesthetic




Figure 1: Anesthetic cartridge with blood after the tap.

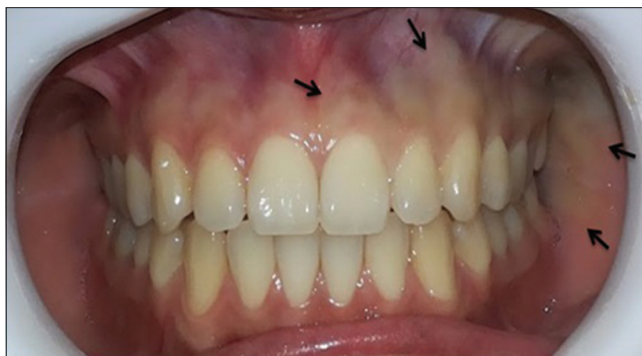

Figure 2: Ischemic zone (arrow) from the middle line of the buccal gum and mucosa to the left cheek.

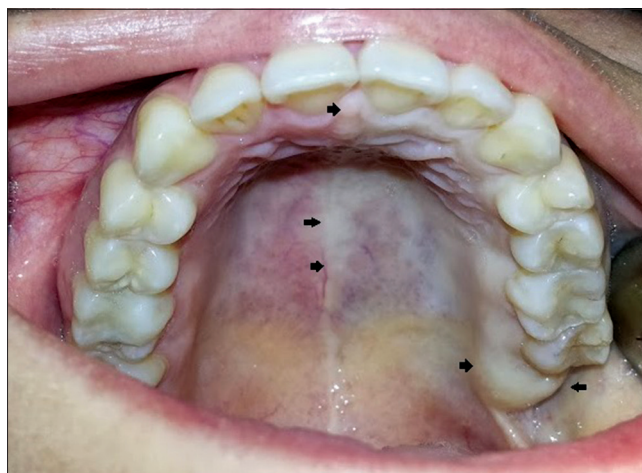


Figure 3: The arrows indicate the ischemic mucosal of palatal that covers the left hemi-maxillary and internal cheek.

effect on the IAN was verified through a caries probe in the gingival crevice of tooth 36. After the reported complication, the decision was made to treat teeth 35 and 36. Once completed, the patient received some oral instructions about preventive measures to consider with the lip and tongue anesthesia, soft diet, and to return for a check-up 3 days later. In light of the interesting nature of the case, the patient gave her informed consent to study the case and present it in this article.

DISCUSSION

A case about the complications of ischemia of the skin, buccal mucosa, and left-sided palatal mucosa

associated with the vascular territory of the maxillary artery after an IAN block is presented.

The intravascular injection on an IAN block is variable, reporting a frequency of 0.5%^[4] to 20% of the cases^[14] and 31.3% after the first positive aspiration.^[3] There is currently no consensus regarding the exact cause of the associated complications after the administration of anesthesia to IAN.^[11] However, similar reports about intravascular injections in the IAN block^[6-8,10,11] have linked the complications to the location of the injection, the patient's anatomic variations, and the type of drug. Several hypotheses have been proposed to explain how a local anesthetic applied in the pterygomandibular region for the IAN block of the mandible can reach and affect the skin of the face and other regions of the head.^[7,8,11,12]

Similar to what Paul *et al.* exposed it,^[12] this case presents blanching and a burning sensation in the mucosa of the region irrigated by branches of the maxillary artery on the skin as oral mucosa. The skin blanching and mucosal ischemia are due to the epinephrine vasoconstrictor effect on the alpha-adrenergic receptors of the blood vessels that irrigate the skin and mucosa as well as to a sympathetic effect from the impact of the needle on sympathetic fibers of the tunica adventitia of the artery, causing a vasospasm in the sympathetic plexus around the internal carotid artery.^[6,10,15] This would trigger a general vascular reaction to the arterial branches of the maxillary artery, manifesting peripherally with skin blanching and mucosal ischemia on its branches, as in this case.

On the other hand, it is suggested that the intravascular deposit of the drug could have generated an ascendant diffusion from the inferior alveolar artery to the maxillary arterial branch placed deep in the infratemporal region and then extend its branches to the facial region and oral or orbital cavity.^[8,10,11,16,17] This artery passes mainly behind the IAN,^[18] and although the initial positive aspiration can be negative, the movement of the patient's head or the operator's hand can cause the needle to penetrate the arterial wall.^[10] Another theoretical explanation could be anatomic variations that approach the maxillary artery in the pterygomandibular region,^[18] which would serve as a precedent to explain the intravascular injection directly into the maxillary artery and the observed ischemia that coincides with the topographic distribution of its branches.

According to what was observed in this and other previously reported cases, it is recommended that an aspiration should be conducted and blood content inside the cartridge should be observed during IAN block as these could demonstrate an intravascular injection into the inferior alveolar artery or into the tap of the pterygoid plexus placed in the infratemporal region.^[2]

In this case, the anatomic variations and the vasoconstrictor effect on the perivascular sympathetic plexus of the branches of the maxillary artery must be considered to be the possible causes of this complication. Fortunately, these complications were temporary, and permanent management and communication with the patient will enable a successful dental treatment.

Financial support and sponsorship

Nil.

Conflicts of interest

The authors of this manuscript declare that they have no conflicts of interest, real or perceived, financial or non-financial in this article.

REFERENCES

- Holliday R, Jackson I. Superior position of the mandibular foramen and the necessary alterations in the local anaesthetic technique: A case report. *Br Dent J* 2011;210:207-11.
- Malamed SF. *Handbook of Local Anesthesia*. St Louis: Elsevier Health Sciences, 2004.
- Khoury J, Mihailidis S, Ghabriel M, Townsend G. Anatomical relationships within the human pterygomandibular space: Relevance to local anesthesia. *Clin Anat N Y N* 2010;23:936-44.
- Martis C, Karabouta-Voulgaropoulou E, Marti K. Aspiration in inferior alveolar nerve block. *Stomatologia (Bucur)* 1986;43:273-8.
- Lustig JP, Zusman SP. Immediate complications of local anesthetic administered to 1,007 consecutive patients. *J Am Dent Assoc* 1999;130:496-9.
- Webber B, Orlansky H, Lipton C, Stevens M. Complications of an intra-arterial injection from an inferior alveolar nerve block. *J Am Dent Assoc* 2001;132:1702-4.
- Scott JK, Moxham BJ, Downie IP. Upper lip blanching and diplopia associated with local anaesthesia of the inferior alveolar nerve. *Br Dent J* 2007;202:32-3.
- Uckan S, Cilasun U, Erkman O. Rare ocular and cutaneous complication of inferior alveolar nerve block. *J Oral Maxillofac Surg Off J Am Assoc Oral Maxillofac Surg* 2006;64:719-21.
- Peñarrocha-Diago M, Sanchis-Bielsa JM. Ophthalmologic complications after intraoral local anesthesia with articaine. *Oral Surg Oral Med Oral Pathol Oral Radiol Endod* 2000;90:21-4.
- Steenen SA, Dubois L, Saeed P, de Lange J. Ophthalmologic

- complications after intraoral local anesthesia: Case report and review of literature. *Oral Surg Oral Med Oral Pathol Oral Radiol* 2012;113:e1-5.
11. Huang RY, Chen YJ, Fang WH, Mau LP, Shieh YS. Concomitant horner and harlequin syndromes after inferior alveolar nerve block anesthesia. *J Endod* 2013;39:1654-7.
 12. Paul R, Anand R, Wray P, D'sa S, Brennan PA. An unusual complication of an inferior dental nerve block: A case report. *Br Dent J* 2009;206:9-10.
 13. Gagnier JJ, Kienle G, Altman DG, Moher D, Sox H, Riley D, *et al.* The CARE guidelines: Consensus-based clinical case reporting guideline development. *Headache J Head Face Pain* 2013;53:1541-7.
 14. Frangiskos F, Stavrou E, Merenditis N, Tsitsogianis H, Vardas E, Antonopoulou I. Incidence of penetration of a blood vessel during inferior alveolar nerve block. *Br J Oral Maxillofac Surg* 2003;41:188-9.
 15. Kronman JH, Giunta JL. Reflex vasoconstriction following dental injections. *Oral Surg Oral Med Oral Pathol* 1987;63:542-4.
 16. Freuen ND, Feil BA, Norton NS. The clinical anatomy of complications observed in a posterior superior alveolar nerve block. *Faseb J* 2007;21:A967.
 17. Boynes SG, Echeverria Z, Abdulwahab M. Ocular complications associated with local anesthesia administration in dentistry. *Dent Clin North Am* 2010;54:677-86.
 18. Khoury JN, Mihailidis S, Ghabriel M, Townsend G. Applied anatomy of the pterygomandibular space: Improving the success of inferior alveolar nerve blocks. *Aust Dent J* 2011;56:112-21.