

Primary non-Hodgkin lymphoma of the chiasm and optic tract in a nonimmunocompromised patient: illustrative case

Hassan Kadri, MD,¹ Ghiath Hamed, MD,² and Anas Anbari, MD³

Departments of ¹Neurosurgery and ³Ophthalmology, MSRC Damascus, Damascus, Syria; and ²Amana Pathology Laboratory, Damascus, Syria

BACKGROUND Chiasmatic and optic tract lymphoma as the primary lesion of the central nervous system (CNS) is extremely rare.

OBSERVATIONS The authors report a case of a previously healthy 62-year-old woman who presented with quick and progressive visual impairment leading to bilateral blindness. Brain imaging studies suggested glioma or lymphoma of the chiasm and the posterior visual pathway. Postoperative examination revealed low-grade malignant B-cell lymphoma. No evidence of extracranial lymphoma was found, so a final diagnosis of primary CNS lymphoma (PCNSL) was made.

LESSONS To the authors' knowledge, PCNSL confined to the optic chiasm has rarely been reported in nonimmunocompromised patients. The present case of lymphoma affecting the optic chiasm and optic tract is extremely rare.

<https://thejns.org/doi/abs/10.3171/CASE22340>

KEYWORDS primary central nervous system lymphoma; chiasmatic involvement; non-Hodgkin lymphoma; optic nerve involvement

Lymphoma affects every organ in the body and presents with a variety of symptoms.¹ Primary central nervous system lymphoma (PCNSL) is a rare intracranial lesion with a prevalence that increased by 10 times between 1973 and 1992.^{2,3} The cause of this increase is unknown. In systemic lymphoma, optic nerve involvement (ONI) has been reported as a primary symptom⁴ or with recurrence.^{5,6} Diagnosis has been made by optic nerve biopsy, according to some case reports.^{7,8}

Eye lesions that normally affect the retina, vitreous, or optic disc are found in approximately 20% of patients with PCNSL.¹ Sporadic case reports on isolated ONI as the initial manifestation of PCNSL have been published,^{9,10} but isolated lymphoma of the chiasm and optic tract is extremely rare.^{11–14} Due to the location of the tumor, resection is generally ineffective.

In addition, chemotherapy, radiotherapy, and treatment with corticosteroids often produce only partial remission, and tumors recur in more than 90% of patients.^{9,15} The median survival is 10–18 months in immunocompetent patients and shorter in patients with acquired immunodeficiency syndrome.¹⁶ This report describes a case of isolated optic

chiasm and optic tract lymphoma that was diagnosed postoperatively in an immunocompetent patient. There was no brain, retina, or vitreous infiltration or extracranial evidence of non-Hodgkin lymphoma (NHL).

Illustrative Case

A 62-year-old woman with a brain lesion was referred to our neurosurgery department from ophthalmology. In the 3 months prior, she had had bilateral progressive painless vision loss that resulted in blindness. She had no previous history of vascular disease but had a short history of diabetes. She had been doing well until 3 months before our appointment, when she began complaining of hazy vision.

The patient developed headaches and nausea over time with no vomiting. Then, without warning, anopsia began in the left eye and quickly spread to the right. There were no signs of redness of the eyes or swelling. Upon neurological evaluation, there was no sense of light in both eyes and no direct or indirect light reflections. The remaining cranial nerves were normal, and no other deficits were observed.

ABBREVIATIONS CNS = central nervous system; CSF = cerebrospinal fluid; MRI = magnetic resonance imaging; NHL = non-Hodgkin lymphoma; ONI = optic nerve involvement; PCNSL = primary central nervous system lymphoma.

INCLUDE WHEN CITING Published November 14, 2022; DOI: 10.3171/CASE22340.

SUBMITTED August 16, 2022. **ACCEPTED** September 19, 2022.

© 2022 The authors, CC BY-NC-ND 4.0 (<http://creativecommons.org/licenses/by-nc-nd/4.0/>).

Blood tests revealed a glucose (fasting) level of 170 mg/dl (normal range 70–110 mg/dl), triglyceride level of 186 mmol/L (normal range up to 150 mmol/L), vitamin B₁₂ level of 998 pg/ml (normal range 180–900 pg/ml), 25-hydroxyvitamin (D₃ and D₄) level of 29.52 ng/ml (normal range 32–150 ng/ml), thyroid-stimulating hormone level of 7.92 μ IU/ml (normal range 0.3–5 μ IU/ml), C-reactive protein level of 21.84 mg/L (normal range up to 5 mg/dl), and complete blood count within normal limits. The result of a human immunodeficiency virus test was negative, and cerebrospinal fluid (CSF) analysis revealed no abnormalities. Magnetic resonance imaging (MRI) revealed a large hypothalamic chiasmatic lesion measuring 24 \times 10 mm with significant homogeneous enhancement of the optic tracts involving the chiasm. Equal signal strength of the cortex was observed on T1- and T2-weighted MRI scans, and a slight enhancement was observed in the infundibulum and pituitary stalk (Fig. 1).

The lateral geniculate nucleus and the intracanal and intraorbital optic nerves were unaffected. On the chiasm, diffusion tensor imaging with monovoxel spectroscopy with an echo time of 35 and 144 ms (3-T MRI) revealed a rise in myoinositol and choline with a decrease in normal brain metabolites, but there was no evidence of lactic anaerobic metabolites. The optic nerves were spared by this broad infiltrating lesion.

Computed tomography scans of the neck, chest, abdomen, and pelvis with contrast revealed no signs of systemic abnormalities. Optic nerve exploration showed moderate fundus edema with a nearly normal macula. Optical coherence tomography of the optic nerve was suggestive of bilateral partial axonal loss (Fig. 2). We conducted a biopsy using a minor subfrontal approach, and the chiasm seemed to be enlarged and fixed with a normal microscopic shape of the optic nerves.

Histopathology confirmed the presence of malignant B-cell lymphoma in the visual pathway. Histological slides were stained with hematoxylin and eosin and showed dense aggregates of small lymphocytes with interstitial and perivascular distribution (Fig. 3A). Immunohistochemical staining showed that cells were positive for leukocyte common antigen and B-cell marker (CD20), whereas they were negative for T-cell marker (CD3) and glial fibrillary acidic protein (Fig. 3). The CD5 marker result was positive, suggesting chronic lymphocytic leukemia/lymphoma (Fig. 3D). The Ki-67

proliferative activity marker level was low. Therefore, the final diagnosis was PCNSL (Fig. 3).

The patient has been alive for 9 months. She underwent 6 chemotherapy sessions and is prepared to receive 10 sessions of radiotherapy according to the advice of our oncologists.

Discussion

Observations

PCNSL is an uncommon and intense extranodal NHL that is limited to the brain, eyes, spinal cord, or leptomeninges without systemic association.¹⁷ It can be classified into four categories: isolated ONI, optic nerve associated with CNS lesion, ONI with systemic disease, and ONI with essential intraocular lymphoma.¹⁸ To our knowledge, no isolated chiasmatic and optic tract lesion has been reported previously. This isolated form is extremely rare. In this report, we describe a case of isolated lymphoma of the chiasm and optic tracts in a 62-year-old woman.

Related optic symptoms are described as slow, progressive, mildly blurred vision, floaters, or diminished vision acuity. The duration of prediagnosis symptoms is 3–6 months.^{19,20} Our patient had only blindness, which had developed over the course of 3 months. The visual deterioration in patients with PCNSL is usually caused by intraocular lymphoma, which happens in 25% of patients. The intraocular lymphoma manifests most commonly as vitreoretinal lymphoma, less commonly as uveal lymphoma, and rarely as iris lymphoma.^{20,21} Our patient had no ocular lesions.

Delayed diagnosis of intraocular lymphoma is mainly due to the insidious progression of the disease. It is characterized by a subacute onset that lasts for several days and is associated with severe vision loss.²² Therefore, early diagnosis is essential to maintain the optic nerve.²³

Diagnosis of lymphomatous ONI is relatively straightforward if associated with parenchymal CNS lesions or lymphomatous meningitis. Solitary lymphoma ONI is more difficult to diagnose, especially if the lymphoma first develops in only the optic system.⁹ Clinical work-up should include comprehensive laboratory and neuroimaging investigations. MRI generally plays a fundamental part in the diagnosis of optic neuropathies.¹² Contrast uptake is found in MRI in most patients with optic nerve lymphoma.⁹

Orbital MRI systematically complemented by brain MRI should focus on both optic nerves and should include a high-resolution fat suppression sequence. A lack of signs of vitreous retinal lymphoma and the presence of contrast-enhancing lesions of the optic nerve are useful for diagnosis.^{24,25} Some cases could be misdiagnosed as inflammatory changes.¹³ The optic enlargement can mimic ONI with lymphoma, but the inflammation should resolve with time.¹⁰ Our patient's blood work result was normal, and the MRI showed chiasmatic and optic tract enhancement, as described above.

PCNSL CSF biomarkers may be particularly useful in the diagnosis and differentiation of inflammatory diseases. Recently, several biomarkers have been reported.^{19,26} At least one of the routine CSF indicators is abnormal in more than 80% of CNS lymphomas.⁵ A series of tests for CSF in various lymphomas involving the CNS showed that CSF cell counts were normal in 33%–60% of patients, and protein was normal in 33%–55%.²⁵ The CSF analysis was normal in our patient.

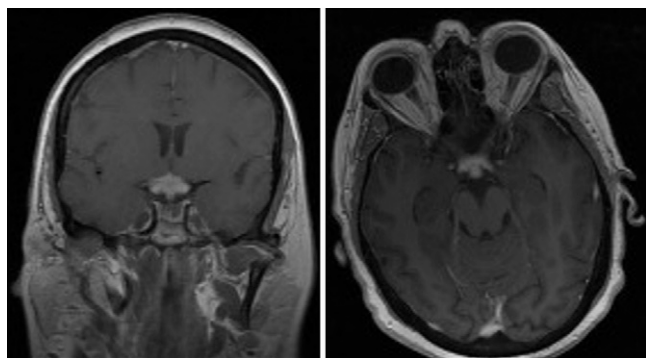


FIG. 1. Coronal (left) and axial (right) postcontrast T1-weighted MRI showing mass lesions with homogeneous enhancement of the optic tracts involving the chiasm with slight enhancement of the infundibulum.

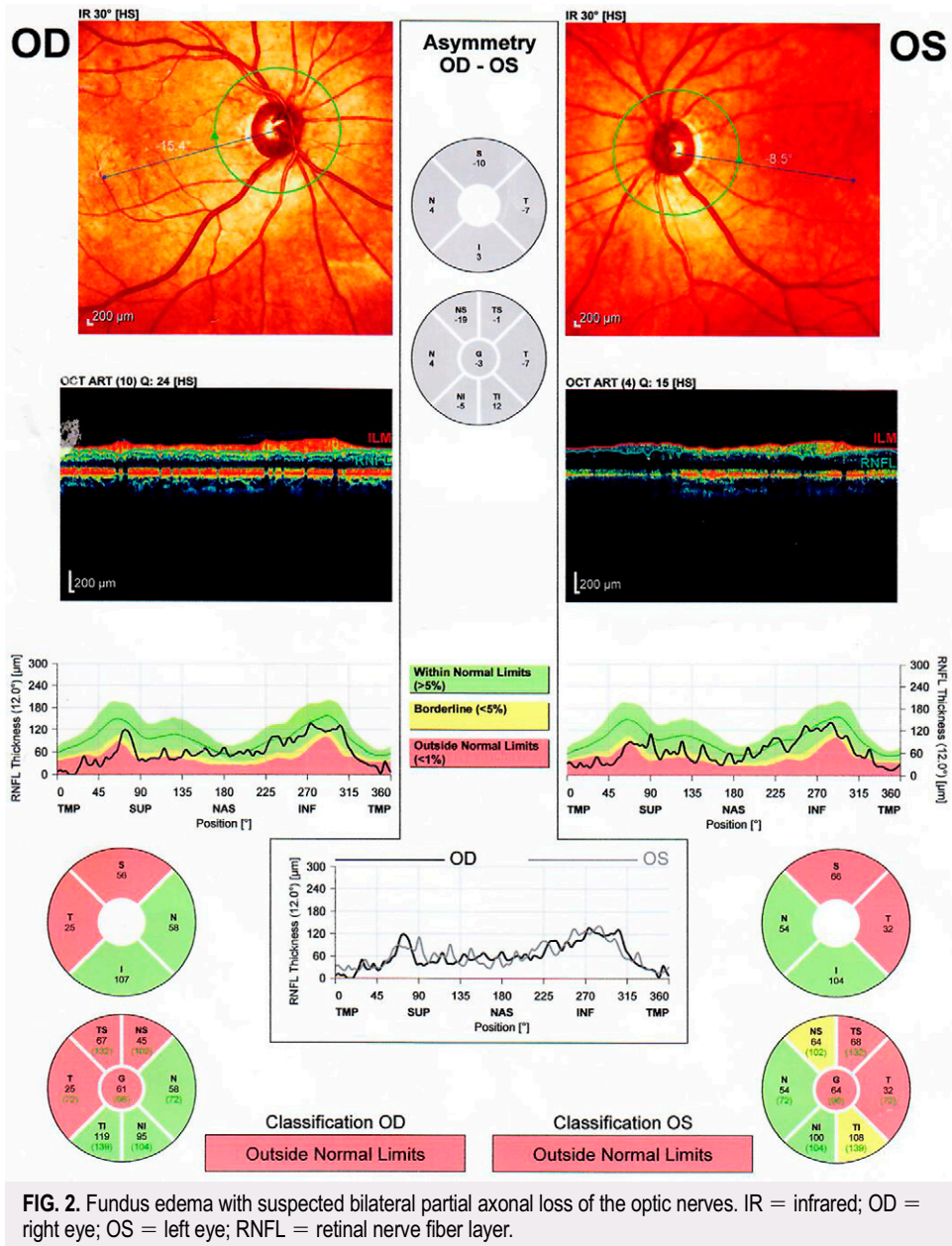
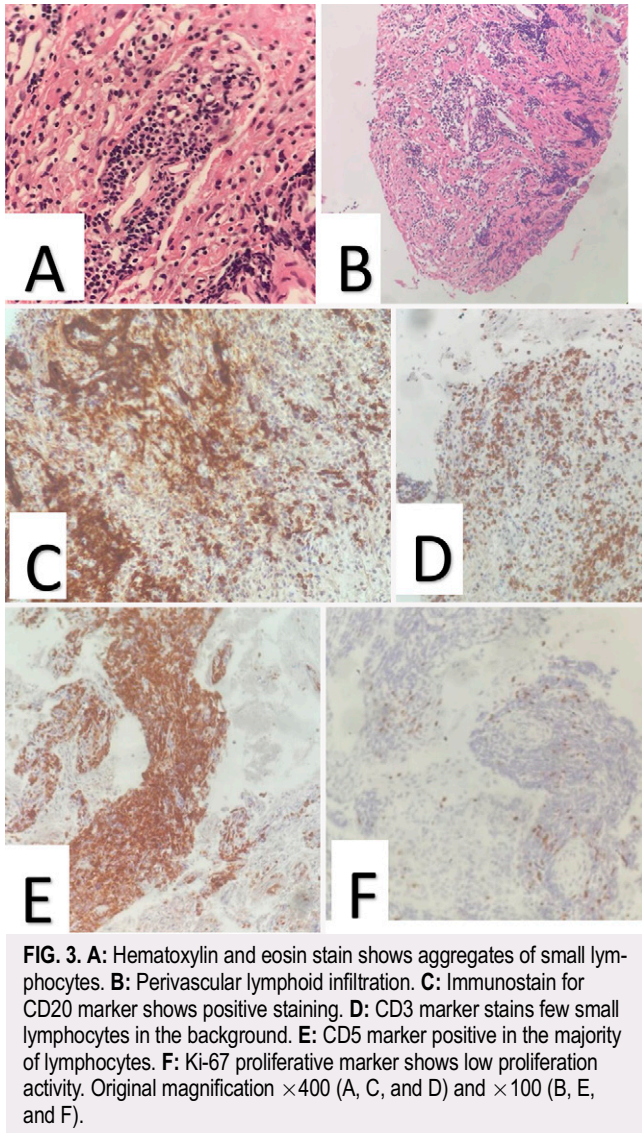


FIG. 2. Fundus edema with suspected bilateral partial axonal loss of the optic nerves. IR = infrared; OD = right eye; OS = left eye; RNFL = retinal nerve fiber layer.

Optic nerve biopsy may be unavoidable as the final diagnostic option.^{24,27} It carries a risk of permanent loss of vision,^{7,9} and the size of the biopsy material is limited by the need to maintain vision.² In surgery, optic nerve lymphoma normally appears as an enormous enlarging nerve.^{7,28} We performed our biopsy using a minor subfrontal approach, and the result was conclusive.

Lessons

Chiasm and optic tract invasion is an atypical and rare condition of PCNSL. It is clinically marked by a rapid, gradual visual loss and visual disability. The diagnosis is based on brain and orbital MRI scans with contrast, ophthalmology work-up, and eventual CSF analysis, but the final diagnosis is based on biopsy.



References

1. Armitage JO, Gascoyne RD, Lunning MA, Cavalli F. Non-Hodgkin lymphoma. *Lancet*. 2017;390(10091):298–310.
2. Com BW, Marcus SM, Topham A, Hauck W, Curran WJ Jr. Will primary central nervous system lymphoma be the most frequent brain tumor diagnosed in the year 2000? *Cancer*. 1997;79(12):2409–2413.
3. Eby NL, Grufferman S, Flannelly CM, Schold SC Jr, Vogel FS, Burger PC. Increasing incidence of primary brain lymphoma in the US. *Cancer*. 1988;62(11):2461–2465.
4. Tatsugawa M, Noma H, Mimura T, Funatsu H. Unusual orbital lymphoma undetectable by magnetic resonance imaging: a case report. *J Med Case Rep*. 2009;3:104.
5. Kim UR, Shah AD, Arora V, Solanki U. Isolated optic nerve infiltration in systemic lymphoma—a case report and review of literature. *Ophthal Plast Reconstr Surg*. 2010;26(4):291–293.
6. Sudhakar P, Rodriguez FR, Trobe JD. MRI restricted diffusion in lymphomatous optic neuropathy. *J Neuroophthalmol*. 2011;31(4):306–309.
7. Behbehani RS, Vacarezza N, Sergott RC, Bilyk JR, Hochberg F, Savino PJ. Isolated optic nerve lymphoma diagnosed by optic nerve biopsy. *Am J Ophthalmol*. 2005;139(6):1128–1130.
8. Tsutsumi K, Horiuchi T, Aoyama T, Hongo K. Isolated primary malignant lymphoma arising from the optic chiasm. *J Clin Neurosci*. 2013;20(12):1783–1786.
9. Ahle G, Touitou V, Cassoux N, et al. Optic nerve infiltration in primary central nervous system lymphoma. *JAMA Neurol*. 2017;74(11):1368–1373.
10. Kwon YJ, Kim YH, Baek SH, Son MH, Lee JH, Kim BJ. Transorbital ultrasonography in acute optic neuritis: can it be a supportive diagnostic tool? *Mult Scler Relat Disord*. 2019;31:54–58.
11. Cantore GP, Raco A, Artico M, Ciappetta P, Delfini R. Primary chiasmatic lymphoma. *Clin Neurol Neurosurg*. 1989;91(1):71–74.
12. Gill MK, Jampol LM. Variations in the presentation of primary intraocular lymphoma: case reports and a review. *Surv Ophthalmol*. 2001;45(6):463–471.
13. Matsuyama J, Ichikawa M, Oikawa T, et al. Primary CNS lymphoma arising in the region of the optic nerve presenting as loss of vision: 2 case reports, including a patient with a massive intracerebral hemorrhage. *Brain Tumor Pathol*. 2014;31(3):222–228.
14. Zelefsky JR, Revercomb CH, Lantos G, Warren FA. Isolated lymphoma of the anterior visual pathway diagnosed by optic nerve biopsy. *J Neuroophthalmol*. 2008;28(1):36–40.
15. Deangelis LM, Hormigo A. Treatment of primary central nervous system lymphoma. *Semin Oncol*. 2004;31(5):684–692.
16. Sierra Del Rio M, Rousseau A, Soussain C, Ricard D, Hoang-Xuan K. Primary CNS lymphoma in immunocompetent patients. *Oncologist*. 2009;14:526–539.
17. Löw S, Han CH, Batchelor TT. Primary central nervous system lymphoma. *Ther Adv Neurol Disord*. 2018;11:1756286418793562.
18. Kim JL, Mendoza PR, Rashid A, Hayek B, Grossniklaus HE. Optic nerve lymphoma: report of two cases and review of the literature. *Surv Ophthalmol*. 2015;60(2):153–165.
19. Hong JT, Chae JB, Lee JY, Kim JG, Yoon YH. Ocular involvement in patients with primary CNS lymphoma. *J Neurooncol*. 2011;102(1):139–145.
20. Grimm SA, McCannel CA, Omuro AM, et al. Primary CNS lymphoma with intraocular involvement: International PCNSL Collaborative Group report. *Neurology*. 2008;71(17):1355–1360.
21. Choi JY, Kafkala C, Foster CS. Primary intraocular lymphoma: a review. *Semin Ophthalmol*. 2006;21(3):125–133.
22. Chan CC, Rubenstein JL, Coupland SE, et al. Primary vitreoretinal lymphoma: a report from an International Primary Central Nervous System Lymphoma Collaborative Group symposium. *Oncologist*. 2011;16(11):1589–1599.
23. Zaman AG, Graham EM, Sanders MD. Anterior visual system involvement in non-Hodgkin's lymphoma. *Br J Ophthalmol*. 1993;77(3):184–187.
24. Baraniskin A, Zaslavska E, Nöpel-Dünnebacke S, et al. Circulating U2 small nuclear RNA fragments as a novel diagnostic biomarker for primary central nervous system lymphoma. *Neuro Oncol*. 2016;18(3):361–367.
25. Nguyen-Them L, Costopoulos M, Tanguy ML, et al. The CSF IL-10 concentration is an effective diagnostic marker in immunocompetent primary CNS lymphoma and a potential prognostic biomarker in treatment-responsive patients. *Eur J Cancer*. 2016;61(5):69–76.
26. Rubenstein JL, Wong VS, Kadoch C, et al. CXCL13 plus interleukin 10 is highly specific for the diagnosis of CNS lymphoma. *Blood*. 2013;121(23):4740–4748.
27. Dayan MR, Elston JS, McDonald B. Bilateral lymphomatous optic neuropathy diagnosed on optic nerve biopsy. *Arch Ophthalmol*. 2000;118(10):1455–1457.

28. Wong D, Danesh-Meyer H, Pon JA. Infiltrative lymphomatous optic neuropathy in non-Hodgkin lymphoma. *J Clin Neurosci*. 2015;22(9):1513–1515.

Disclosures

The authors report no conflict of interest concerning the materials or methods used in this study or the findings specified in this paper.

Author Contributions

Conception and design: Kadri, Hamed. Acquisition of data: Kadri. Analysis and interpretation of data: all authors.

Correspondence

Hassan Kadri: MSRC Damascus, Damascus, Syria. drkadri@yahoo.com.