



ELSEVIER

Contents lists available at [ScienceDirect](https://www.sciencedirect.com)

Trauma Case Reports

journal homepage: www.elsevier.com/locate/tcr

Unexpected blunt neck trauma resulting in laryngeal fracture, the case of the dangerous wooden box: A case report

Melissa Mortensen^{a,*}, Nicholas Browne^b, Robert Hutnik^b, Sina Mehraban Far^b

^a Albany Medical College, Department of Otolaryngology, Albany, NY, United States of America

^b Stony Brook Medicine, Department of Surgery, Stony Brook, NY, United States of America

ARTICLE INFO

Keywords:

Blunt laryngeal trauma
Laryngeal fracture

ABSTRACT

Background: Laryngeal fracture is a rare condition but is potentially lethal. These injuries are usually caused by major blunt trauma from motor vehicle accidents, physical assaults, or sports injuries. The high mortality associated with these injuries requires prompt recognition and treatment.

Case report: We present a case of laryngeal fracture caused by falling from standing height and landing onto the edge of a wooden box– a seemingly minor blunt trauma. The patient fractured her thyroid lamina and had a comminuted fracture of the cricoid cartilage. The patient was able to be decannulated and required injection augmentation for return of normal voice.

Conclusion: This case highlights the importance of maintaining a high level of suspicion for laryngeal fracture in a patient that falls and strikes the anterior neck. Early identification of laryngeal fractures not only allows for airway protection but helps ensure the preservation of voice, swallowing and airway functions.

Introduction

Laryngeal fractures are a rare occurrence, seen only in 1 out of 30,000 patients treated at tertiary care trauma centers [1]. While laryngeal fractures are rare, they can be extremely deadly. These injuries are usually caused by major blunt trauma from motor vehicle accidents, physical assaults, or sports injuries. These injuries can be missed by clinicians secondary to their low incidence and physician familiarity with the diagnosis [2,3]. The mortality associated with laryngeal fractures has been reported as high as 80% in the pre-hospitalization setting [4] to an overall reported mortality rate of 17.9% [5]. Once a secure airway is established and the laryngeal injury is correctly diagnosed the mortality rate does decrease to less than 5% [6]. Early recognition and treatment have also been associated with improved voice, airway and swallowing outcomes [2,3,5–8].

When evaluating trauma patients that present with blunt neck trauma from motor vehicle accidents or physical assaults clinicians typically have a higher degree of suspicion for possible laryngeal trauma. Laryngeal injuries are heterogenous and vary from mild laryngeal edema to significant endolaryngeal soft tissue disruption with or without laryngeal fracture. Our case highlights the importance of clinicians maintaining a high suspicion for laryngeal trauma when the etiology is falling from a standing position on a stationary, solid object where the neck is unprotected. The purpose of this report is to emphasize how prompt diagnosis by our emergency room physicians and prompt referral to Otolaryngology for management of acute laryngeal trauma from an uncommon injury presentation is important because it prevents long-term sequela in patients. As reported previously in the literature early

* Corresponding author at: Department of Otolaryngology, 50 New Scotland Avenue, 4th Floor, Albany, NY 12208, United States of America.
E-mail address: mortenm1@amc.edu (M. Mortensen).

<https://doi.org/10.1016/j.tcr.2021.100439>

Accepted 17 February 2021

Available online 20 February 2021

2352-6440/© 2021 Published by Elsevier Ltd. This is an open access article under the CC BY-NC-ND license

(<http://creativecommons.org/licenses/by-nc-nd/4.0/>).

intervention results in improved voice, deglutination and breathing in patients versus delayed treatment. [8]

Case report [1–14]

A 66-year-old female presented to the emergency department (ED) after falling from a standing position while carrying a wooden garden box, landing onto her left arm and hitting her neck on the edge of the box (Fig. 1). The patient went to the emergency room for increasing anterior neck pain. Upon physical examination in the ED, her neck was found to be edematous and tender to palpation around the thyroid and cricoid cartilage, however there was no hematoma, subcutaneous emphysema, or lacerations found. She became acutely cyanotic and hypoxic and was intubated. A CT scan of the neck was then performed. The CT revealed a displaced midline thyroid cartilage fracture and a comminuted cricoid cartilage fracture (Schaefer Fuhrman's Group IV) (Fig. 2). The patient was also found to have a non-displaced radial forearm fracture. The patient was transferred to our tertiary care center for further care and management. The following morning the patient was taken to the operating room for diagnostic laryngoscopy, tracheostomy, open reduction and internal fixation of her laryngeal fractures (See Fig. 3). On laryngoscopy, the vocal folds were noted to be edematous bilaterally with a copious bleeding seen in the anterior larynx. During surgical exploration of the neck, bleeding and ecchymosis were noted around the infrahyoid muscles. The thyroid fracture was repaired with a low-profile fixation plate while the cricoid cartilage was sutured and stented with a modified Montgomery T-tube (See Figs. 3 and 4). The T-tube stent was removed 10 days later. The patient was decannulated 6 weeks later (See Fig. 5). Prior to decannulation patient underwent injection augmentation of her left vocal fold. The patient did not require any further intervention for her voice or airway. At one year her voice was adequate for her needs and her subglottis showed no narrowing (See Fig. 5).

Discussion

The protection afforded to the laryngeal skeleton by the bony structures of the sternum, mandible and cervical spine and its own mobility provides an explanation to the infrequent occurrence of laryngeal fractures [2,8]. The most common causes of laryngeal fracture are from motor vehicle accidents, sports related trauma, assault and strangulation [3,8]. In cases where there is high velocity impact to the larynx directly a laryngeal fracture can occur secondary to compression of the larynx against the spine [9]. This was more commonly seen before the advent of air bags in automobile crashes where the extended neck would hit the steering wheel and column. Experimental studies show that non-ossified cartilage may spring back after an anterior blow, but ossified cartilage can shatter, resulting in hematoma and massive soft tissue edema with potential airway compromise. In low-velocity trauma cases, fractures of the hyoid bone and soft tissue injury can be observed. In high-velocity trauma cases, thyroid and cricoid fractures with major soft tissue lacerations are observed [13]. As presented above, the patient sustained a high velocity concentrated impact to the larynx causing the fracture. Based on the compressive forces involved in this trauma a high degree of suspicion for a laryngeal fracture is warranted.

Once there is a suspicion for a laryngeal fracture the patient can be evaluated and managed proficiently. Common signs and symptoms of laryngeal fracture are dyspnea, stridor, subcutaneous emphysema, hemoptysis, hematoma, neck ecchymosis, laryngeal tenderness, voice changes, and loss of laryngeal landmarks [11]. Blunt trauma to the larynx can present with subtle and variable clinical signs, which can manifest up to 48 h post-injury [12]. The only symptom our patient presented with was laryngeal tenderness, which might have not aroused the suspicion despite the mechanism of injury. Analyzation of the compressive forces to the larynx may have recognized the patient's need for a surgical airway, however the patient was intubated successfully and transferred to a tertiary care center where a higher level of care could be administered in a relatively quick amount of time.

The ER clinician can initiate an Otolaryngology team consultation early in the evaluation of a suspected injury and a flexible laryngoscopy of the airway should be performed to assess the airway for stability prior to any imaging. If the airway is compromised



Fig. 1. Wooden garden box that the patient fell onto. Patient hit her neck on the edge of the wooden handle.

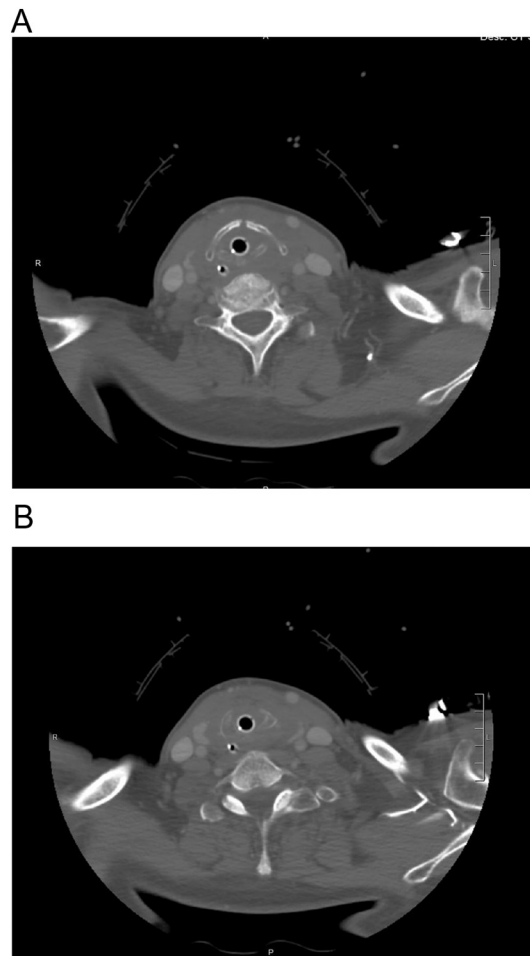


Fig. 2. A. Axial Computed Tomography (CT) of the neck. Image demonstrates a displaced midline thyroid cartilage fracture. The airway is edematous and an endotracheal tube (ET) is in place. B. Axial Computed Tomography (CT) of the neck. Image shows discontinuity involving the left central aspect of the cricoid cartilage indicating a comminuted cricoid cartilage fracture (Schaefer Fuhrman's Group IV).

the patient can be immediately transferred to the operating room for open tracheostomy followed by diagnostic laryngoscopy and repair of the fractures and other injuries. Open tracheostomy is considered the safest option for securing the airway. Typically, intubation and cricothyrotomy are not recommended in these injuries, because they can destabilize the airway. Intubation in this scenario has been thought to aggravate the injury or cause further obstruction [10]. If there is an unidentified partial laryngotracheal separation cricothyrotomy could worsen that injury [10]. There are some recent advocates for intubation depending on the availability of certain personnel and equipment. The skilled endoscopist along with advances in endoscopic imaging and video-assisted equipment in certain cases may perform safe airway management with awake fiber-optic or Glide Scope assisted orotracheal intubation [14].

If the airway is stable imaging can be performed to evaluate for any fractures and possible subsequent treatment can be initiated based on the injury. If there is no fracture or lacerations patients are often just observed for any airway swelling and medically managed with steroids and airway observation. If there is a displaced fracture on imaging or disruption of the internal laryngeal structures this should be repaired within 48 h. Early recognition and treatment, typically within 48 h of the onset of injury, leads to improved outcomes in voice, swallowing, and airway [2,3,5–8]. In Butler et al. they demonstrated that for voice outcomes, in the delayed treatment group, only 27.7% of patients had a good result, as compared to a 78.3% good result in the early treatment group [8]. Similar differences were demonstrated regarding the airway. In the delayed treatment group, only 73.3% had good airway function, as compared to 93.3% who had good airway function in the early treatment group [8]. Our patient was in the Operating room within 36 h of her injury and was successfully managed regarding her voice and airway long term. She was decannulated within 6 weeks of the injury and only required an injection augmentation of the vocal fold for successful voice restoration. At one year post injury her subglottis was normal and her voice was adequate for her needs.

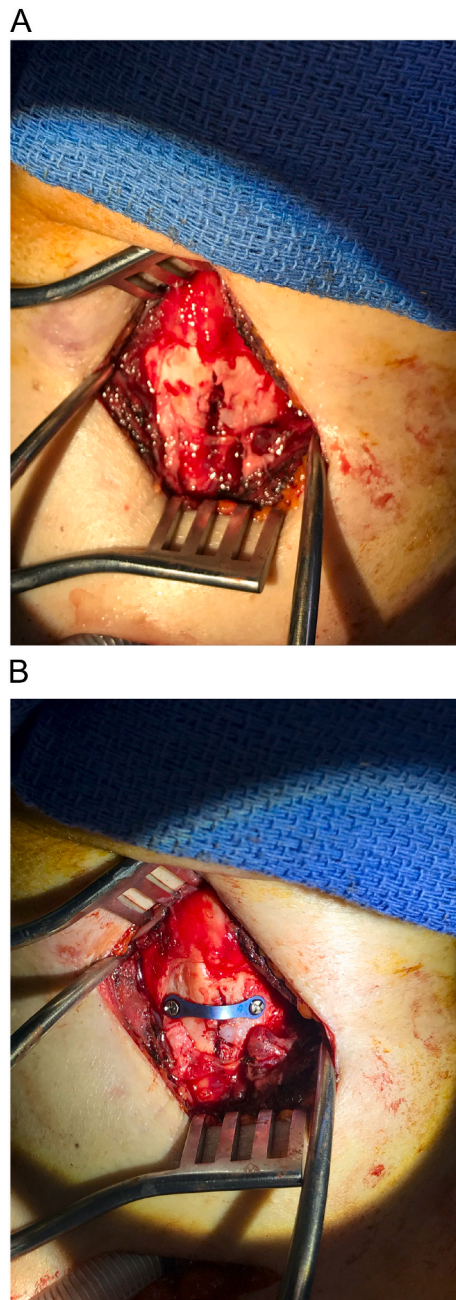


Fig. 3. A. Intra-operative picture showing a thyroid lamina fracture B. Intra-operative picture showing a 2-hole low profile plate which was bent to accommodate the shape of the thyroid lamina and fixated with 2 low-profile screws used to reduce the thyroid cartilage fracture.

Conclusion

This case report highlights the importance of early recognition of laryngeal fracture from an uncommon mechanism of injury. A high degree of suspicion should be maintained by the clinician for a laryngeal fracture when a patient falls from a stationary position onto a hard-fixed object along the anterior neck. Early recognition and treatment of laryngeal fractures leads to improved outcomes regarding voice, airway and swallowing.

Funding

This research did not receive any specific grant from funding agencies in the public, commercial, or not-for-profit sectors.

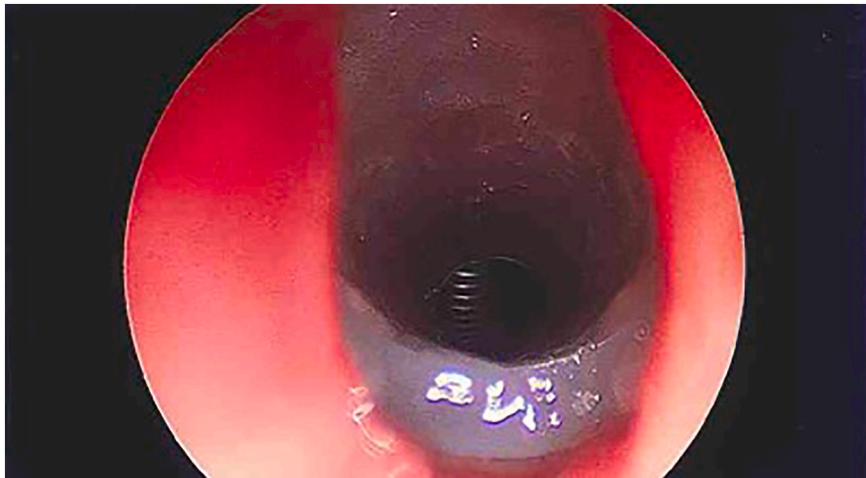


Fig. 4. Endoscopic Picture of Modified T-Tube as laryngeal stent for the cricoid.

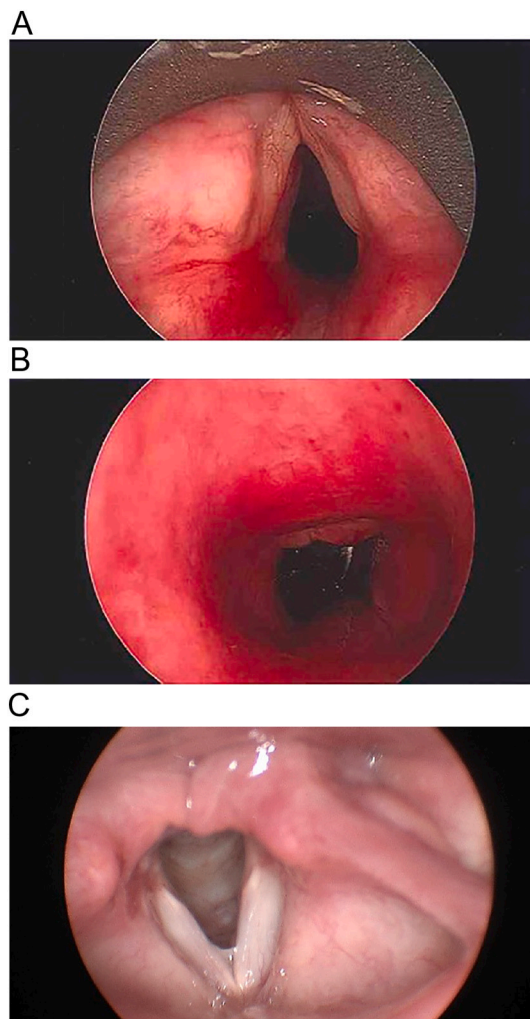


Fig. 5. A. Intra-operative picture 6 weeks after stent removal at the level of glottis before decannulation B. At the level of subglottis before decannulation C. One year post-injury flexible laryngoscopy in clinic.

Declaration of conflicting interest

The authors declare that there is no conflict of interest.

References

- [1] N. Schaefer, A. Griffin, B. Gerhardy, P. Gochee, Early recognition and management of laryngeal fracture: a case report, *Ochsner J.* 14 (2014) 264–265.
- [2] Bent JP 3rd, Silver JR, Porubsky ES. Acute laryngeal trauma a review of 77 patients. *Otolaryngology Head and Neck Surgery* 1993 Sep; 109 (3 Pt 1): 441–449.
- [3] Jalisi S, Zoccoli M. Management of laryngeal fractures-a 10 year experience. *J of Voice* 2011 Jul;25(4):473–479.
- [4] J.E. Mandel, G.E. Weller, S.K. Chennupati, N. Mirza, Transglottic high frequency jet ventilation for management of laryngeal fracture associated with air bag deployment injury, *J. Clin. Anesth.* 20 (5) (2008) 369–371.
- [5] A.H. Mendelsohn, D.R. Sidell, G.S. Berke, M.S. John, Optimal timing of surgical intervention following adult laryngeal trauma, *Laryngoscope.* 121 (10) (2011 Oct) 2122–2127.
- [6] B.S. Jewett, W. Shockley, R. Rutledge, External laryngeal trauma analysis of 392 patients, *Arch. Otolaryngol. Head Neck Surg.* 125 (8) (1999) 877–880.
- [7] D. Leopold, Laryngeal trauma. A historical comparison of treatment methods, *Arch. Otolaryngol.* 109 (1983) 106–111.
- [8] Butler AP, O'Rourke AK, Wood BP and Porubsky ES. Acute external laryngeal trauma: experience with 112 patients. *Annals of Otolology, Rhinology and Laryngology*, 2005; 114, no 5, pp 361–368.
- [9] Becker M, Leuchter, Platon A, Becker C, Dulguerov P, Varoquaz A. Imaging of laryngeal trauma. *European Journal of Radiology* 83(2014) 142–154.
- [10] S.D. Schaefer, The acute management of external laryngeal trauma. A 27-year experience, *Arch. Otolaryngol. Head Neck Surg.* 118 (1992) 598–604.
- [11] D. Verschuereen, B. Bell, S. Bagheri, E. Dierks, B. Potter, Management of laryngotracheal injuries associated with craniomaxillofacial trauma, *J. Oral Maxillofac. Surg.* 64 (2006) 203–214.
- [12] S.A. Paluska, C.D. Lansford, Laryngeal trauma in sport, *Curr Sports Med Rep* 7 (2008) 16–21.
- [13] A. Beckera, I. Leuchterb, A. Platona, C.D. Beckera, P. Dulguerovb, A. Varoquauxa, Imaging of laryngeal trauma, *Eur. J. Radiol.* 83 (2014) 142–154.
- [14] K.F. Cheong, G.H. Yau, Acute laryngeal trauma, *J. Anesth.* 9 (1995) 360–362.