

Contents lists available at [ScienceDirect](http://www.sciencedirect.com)

International Journal of Surgery Case Reports

journal homepage: www.casereports.com

Early anastomotic stricture occurring after colectomy that responded well to Transanal decompression and local steroid therapy: A case report



Masanori Hayashi*, Atsushi Ikeda, Mitsuo Yokota, Hiroyuki Sako, Hiroshi Uchida, Ken Ikeda, Sejiro Okusawa

Department of Surgery, Sano Kosei General Hospital, Japan

ARTICLE INFO

Article history:

Received 23 February 2017

Received in revised form 13 June 2017

Accepted 13 June 2017

Available online 16 June 2017

Keywords:

Intralesional injection

Hand-sewn anastomoses

Intraluminal steroid instillation

Case report

ABSTRACT

INTRODUCTION: Anastomotic strictures occurring after colectomy are a most challenging postoperative complication for gastroenterological surgeons. Reports documenting anastomotic strictures developing in the early postoperative phase are scant, and no established treatment is available.

PRESENTATION OF CASE: A 78-year-old man who had undergone a laparoscopic left hemicolectomy for lower colon cancer presented on postoperative day 12 because of abdominal pain and no bowel movement. Endoluminal decompression was performed with a transanal decompression tube, and local steroid treatment was administered by concurrent intralesional steroid injection (ILe-SI) and intraluminal steroid instillation (ILu-SI). The anastomotic stricture promptly improved. The patient recovered uneventfully, with no recurrence of anastomotic stricture.

DISCUSSION: A transanal decompression tube should be inserted and placed in a cautious manner within a short period of time. ILe-SI in the large intestine requires an understanding of potential adverse events and complications, as well as fully informed consent from the patient. ILu-SI has been reported to be an effective treatment for the management of strictures in various regions. To the best of our knowledge, however, this is the first report to document the treatment of an anastomotic stricture of the colorectum by ILu-SI.

CONCLUSION: Transanal decompression therapy combined with local steroid local treatment might promptly improve anastomotic strictures occurring after colectomy.

© 2017 The Author(s). Published by Elsevier Ltd on behalf of IJS Publishing Group Ltd. This is an open access article under the CC BY-NC-ND license (<http://creativecommons.org/licenses/by-nc-nd/4.0/>).

1. Introduction

Anastomotic strictures occurring after colectomy are one of the most difficult-to-treat postoperative complications for gastroenterological surgeons. Most anastomotic strictures develop more than several months after surgery and are usually treated by digital dilatation, balloon dilatation, or incision of the stricture [1]. On the other hand, anastomotic strictures developing in the early postoperative phase have rarely been reported, and there is no established treatment for the anastomosis during the healing phase. We report our experience with a patient who had an anastomotic stricture that developed soon after colectomy and responded well to transanal decompression therapy combined with local steroid treatment by intralesional steroid injection (ILe-SI) and intraluminal steroid instillation (ILu-SI). The work has been reported in line with the SCARE criteria [2].

2. Presentation of case

A 78-year-old man was referred to our hospital because the patient tested positive for fecal occult blood on a routine medical check-up. Lower gastrointestinal endoscopy and computed tomography (CT) were performed, and the preoperative diagnosis was stage I lower colon cancer (T1N0M0). A laparoscopic left hemicolectomy with extended lymph-node dissection was performed in accordance with the Japanese Society for Cancer of the Colon and Rectum Guidelines 2014 for the treatment of colorectal cancer [3]. The patient had no postoperative complications and was discharged from the hospital on the ninth postoperative day. However, he presented at the emergency outpatient clinic because of abdominal pain and no bowel movement 3 days after discharge. On admission, the abdomen was distended, with no tenderness. Blood tests showed slightly elevated levels of inflammatory markers (white blood cells, 12100/ μ L; C-reactive protein, 0.12 U/L) and liver dysfunction (aspartate aminotransferase, 109 U/L; alanine aminotransferase, 142 U/L). A plain radiograph of the abdomen showed niveau formation in the small intestine (Fig. 1). CT of the abdomen

* Corresponding author.

E-mail address: outenn@knh.biglobe.ne.jp (M. Hayashi).

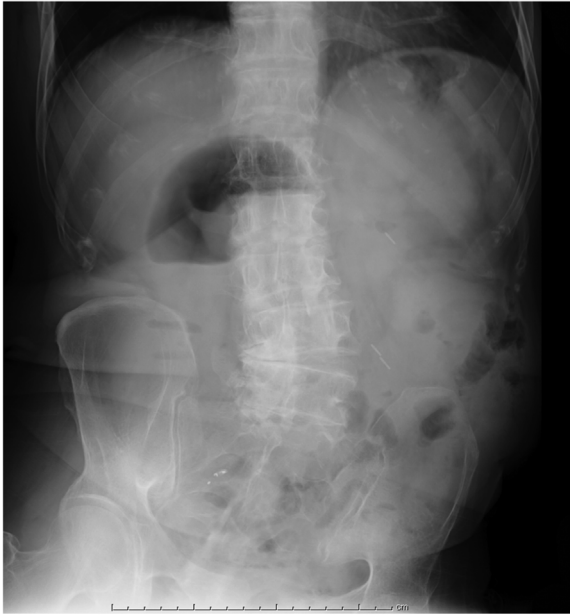

Fig 1. A plain abdominal radiograph obtained on re-admission, showing a small amount of intestinal gas in the upper abdomen.

showed thickening of the intestinal wall at the anastomosis and marked dilatation of the proximal intestine. There was no evidence of abscess formation, suture failure, internal hernia, or strangulated bowel obstruction (Fig. 2). CT on the fourth hospital day showed that dilatation of the colon proximal to the anastomosis had further worsened (Fig. 3). Subsequently, there was no bowel movement, and abdominal symptoms did not improve. Lower gastrointestinal endoscopy was therefore performed on the sixth hospital day (post-operative day 17, Fig. 4). Lower gastrointestinal endoscopy revealed a marked edematous circumferential stricture of the anastomosis. Therefore, after obtaining fully informed consent from the patient, the anastomotic stricture was treated by intralesional steroid injection (Ile-SI) (4 mg of betamethasone plus 9 mL of physiological saline solution; total volume, 10 mL), and a transanal decompression tube was placed in the colon proximal to the anastomosis (Fig. 5A and B). In addition, intraluminal steroid instillation (Ilu-SI, 3 mg of betamethasone/100 mL) was performed near the anasto-

mosis via a transanal decompression tube from the 7th to the 14th hospital days. Bowel movement resumed from the ninth hospital day. Colonography performed via the transanal decompression tube showed that the anastomotic stricture had further improved, and the transanal decompression tube was removed on the 14th hospital day (Fig. 5C and D). Subsequently, the patient had no flare-ups of abdominal symptoms and was discharged in good condition on the 32nd hospital day. Lower gastrointestinal endoscopy performed 5 months after surgery and showed no evidence of anastomotic stricture or anastomotic recurrence. The patient recovered uneventfully (Fig. 6). He has had an uneventful course after hospital discharge without recurrence of bowel obstruction and anastomotic stricture for more than 2 years.

3. Discussion

The incidence of stricture after colorectal anastomosis ranges from 0% to 30%, although only 5% of patients become symptomatic [4]. Anastomotic stricture can be caused by a wide range of factors, such as impaired blood flow, suture failure, adhesion, mesenteric panniculitis, a history of radiotherapy, and diverting stomas. In a study comparing the incidences of strictures between handsewn anastomoses and stapled anastomoses, there was no difference between these procedures in patients who underwent ileocolostomy. However, in patients who underwent colectomy or proctectomy, stapled anastomoses had a higher incidence of strictures and have been reported to have no advantages over handsewn anastomoses [5]. Anastomotic stricture is commonly diagnosed more than 3 months after surgery, and most cases are diagnosed while asymptomatic on routine lower gastrointestinal endoscopy. Very few studies have reported anastomotic strictures occurring in the early postoperative phase, such as in our patient. Anastomotic strictures are usually treated by digital dilatation or balloon dilatation, depending on the stricture site and degree. Refractory anastomotic strictures are treated by incision of the stricture site or stent placement to avoid the need for reoperation and colostomy [1]. At present, reoperation is performed in 4% to 28% of patients with refractory strictures [6].

In the present study, we treated severe anastomotic strictures occurring soon after surgery by 2 techniques. One technique was luminal decompression therapy performed via a transanal

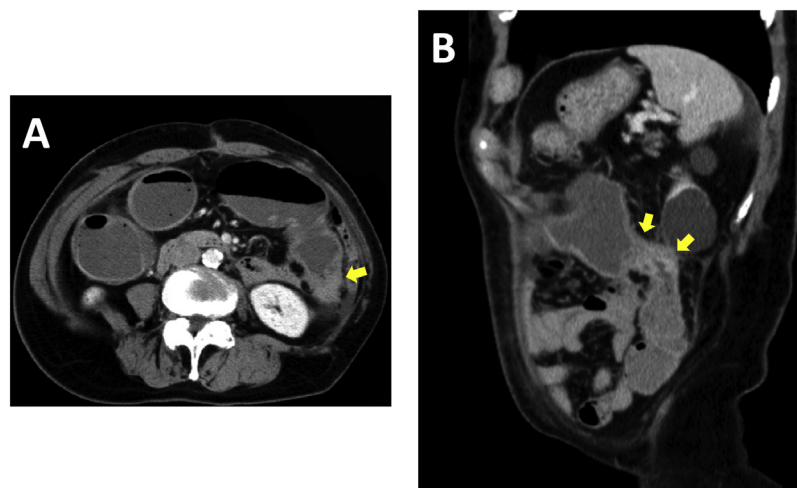


Fig. 2. Contrast-enhanced abdominal computed tomographic scans of the abdomen obtained on re-admission, showing contrast enhancement and thickening of the intestinal wall at the anastomosis (yellow arrow) and stenosis of the anastomotic lumen. There was no evidence of findings such as abscess formation or mesenteric panniculitis around the anastomosis.

A: Axial section, B: Sagittal section.

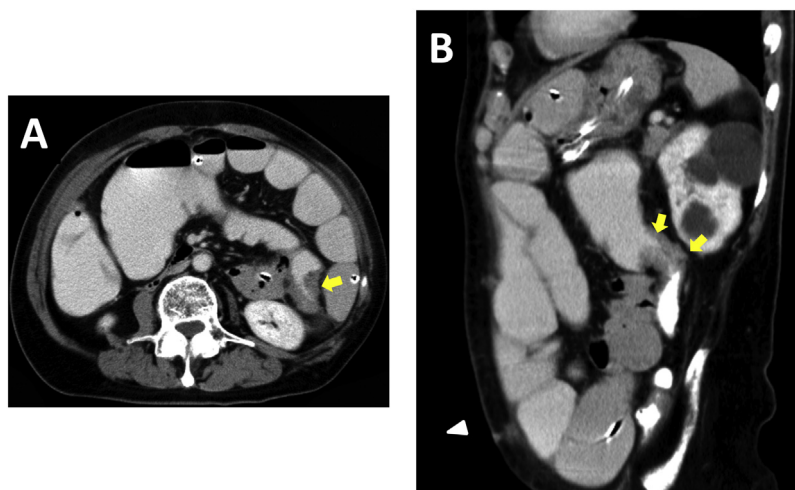


Fig. 3. Contrast-enhanced computed tomographic scans of the abdomen obtained on the fourth day after re-admission, showing that the intestinal wall at the anastomosis (yellow arrow) and the surrounding region were unchanged, as compared with the status at the time of re-admission. However, dilatation of the colon proximal to the anastomosis had markedly worsened.

A: Axial section, B: Sagittal section.

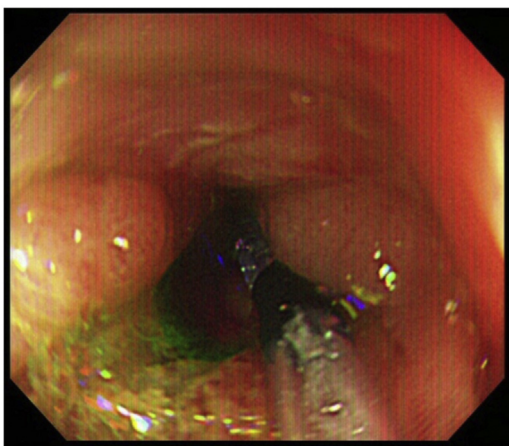


Fig. 4. Lower gastrointestinal endoscopy on the sixth day after re-admission showed an edematous circumferential stricture of the anastomosis. There was no irregularity of the mucosal surface.

approach or a transanal approach to decompress the intestine. The other technique was local treatment with long-acting steroids.

The first technique for decompression of anastomotic strictures, decompression therapy, can be performed by transnasal techniques or transanal techniques. Decompression performed with a transnasal decompression tube is often effective in patients who have undergone right hemicolectomy. In general, transnasal decompression therapy is considered ineffective for bowel obstruction caused by rectal lesions arising from the left side of the colon. However, in our patient, who had undergone a left hemicolectomy, transnasal decompression therapy was performed as first-line treatment because severe abdominal distension had been caused by dilatation of the small intestine, and there was the risk that endoscopic procedures would damage the anastomosis. First-line treatment improved small-bowel dilatation and abdominal symptoms, but did not improve dilatation of the colon proximal to the anastomosis. We therefore switched to direct decompression performed with a transanal decompression tube. In patients such as ours who are established to have a severe edematous anastomotic stricture after the differential diagnosis of suture failure, mesenteric panniculitis, and internal hernia, in whom the stricture extends from the left side of the colon to the rectum,

similar to our patient, decompression performed with the use of a transanal decompression tube is considered the treatment of choice. However, because the insertion and placement of a transanal decompression tube requires endoscopic procedures, there is the risk of ulceration and intestinal perforation. Transanal decompression therapy should therefore be performed as carefully as possible within a short period of time [7].

Second-line local treatment with long-acting steroids was performed to minimize the placement time of the transanal decompression tube. Local steroid treatment has been established as a treatment for keloids in the field of dermatology and can inhibit inflammatory-cell infiltration, producing local anti-inflammatory activity [8]. A recent study reported that ILe-SI is a useful procedure in the field of urology [9]. In the field of gastroenterology, ILe-SI has been reported to be effective for preventing strictures after endoscopic submucosal dissection (ESD) in the upper gastrointestinal tract or the colorectum. ILe-SI combined with endoscopic biliary drainage (EBD) might be an effective treatment for anastomotic strictures occurring after esophagectomy [10]. Phase II and III clinical trials (JCOG 1207 and 1217) supervised by the Japan Clinical Oncology Group (JCOG) are ongoing to examine whether ILe-SI combined with EBD or esophageal ESD is an effective treatment for anastomotic strictures occurring after esophagectomy [11,12]. However, some studies have reported that ILe-SI is an effective treatment for strictures or anastomotic strictures in patients with Crohn's disease, for strictures in children, and in combination with EBD [13,14]. Other studies have reported that ILe-SI was ineffective and tended to shorten the time to retreatment or reoperation. ILe-SI must therefore be performed in the small and large intestines after understanding the risk of adverse effects and complications and obtaining fully informed consent from patients [15–17].

A search of PubMed (from 1950 through June 2017) using the key words “intralesional steroid injection,” “colon or rectum,” and “stricture,” (excluding inflammatory bowel disease); identified 6 patients who had received ILe-SI (anastomotic stricture in 4; radiation-induced stricture in 1; and ischemic colitis in 1) [6,18]. All previous studies reported that ILe-SI was useful for improving colorectal strictures. Lucha et al. performed ILe-SI in 3 patients who had undergone EBD for anastomotic strictures that developed 3 months to 2 years after surgery and reported that the strictures resolved [6]. ILe-SI is considered a straightforward; safe technique with few complications. However; a problem associated with the

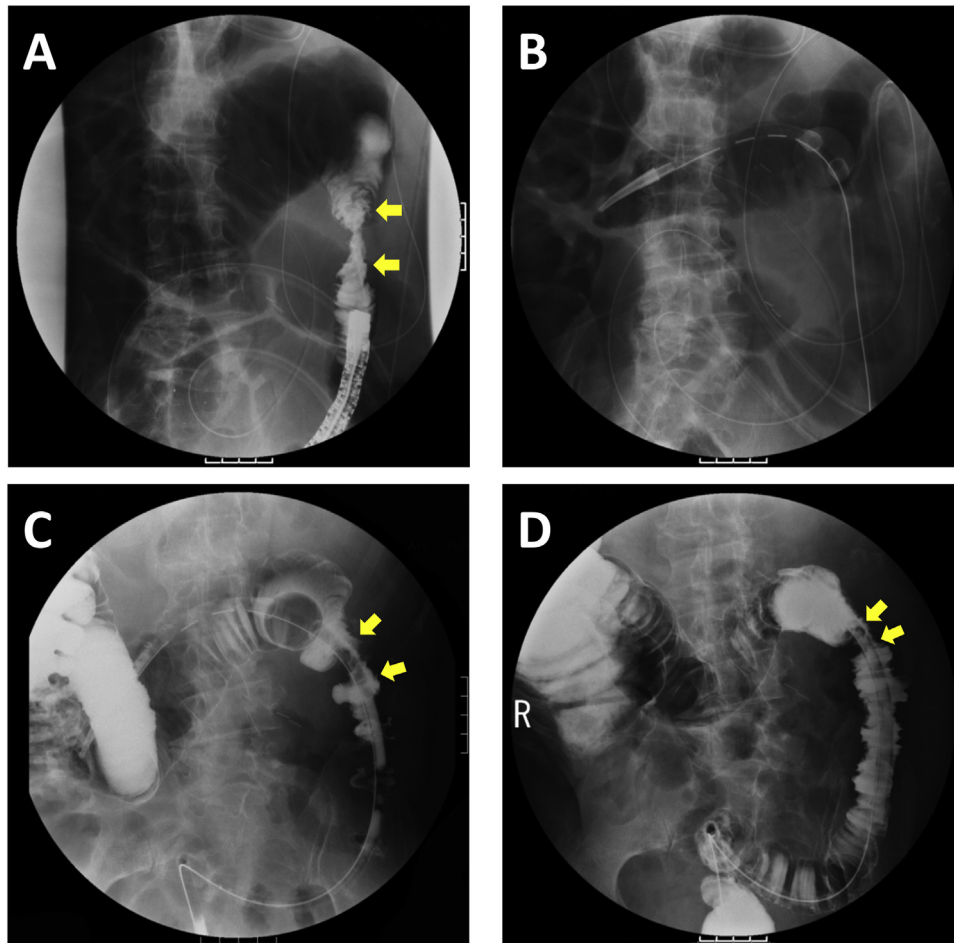


Fig. 5. (A) Colonography performed with Gastrografin on the sixth day after re-admission showed an anastomotic stricture (yellow arrow) and dilatation of the proximal colon. (B) A transanal ileus tube was placed in the intestine proximal to the anastomosis. (C) Colonography on the 10th day after re-admission showed that the anastomotic stricture (yellow arrow) and dilated proximal colon had improved slightly. However, contrast media infused proximally to the anastomosis poorly flowed to the distal intestine. (D) Colonography on the 14th day after re-admission showed that the anastomotic stricture (yellow arrow) had further improved, and contrast media infused proximally to the anastomosis smoothly flowed distally.

treatment of anastomotic strictures occurring after colectomy is that multiple treatments

are often required because the biological half-life of long-acting steroids ranges from 36 to 56 h, and each treatment session requires the insertion of an endoscope. In patients who receive maintenance therapy with steroids by continuous intravenous infusion or with oral steroids, caution is required for the development of adverse reactions caused by systemic steroid treatment.

We studied whether ILu-SI can be used to treat severe anastomotic strictures of the colon and additionally performed a new steroid local treatment using a transanal decompression tube. Several studies have evaluated the effectiveness of ILu-SI for strictures arising in the respiratory tract and the esophagus, and periodic ILu-SI was consistently found to prevent stricture formation [19,20]. In particular, Mori et al. combined steroids with a jelly-like substance in an attempt to develop techniques for prolonging the local retention time of steroids [19]. To our knowledge, however, no study has reported that ILu-SI was an effective treatment for anastomotic strictures of the colorectum. We injected 3 mg of betamethasone (Steronema®) in a retrograde manner through a transanal decompression tube, and performed ILu-SI once daily, using a technique in which the tube is spontaneously released after 2 h of clamping. Luminal decompression therapy promptly improved symptoms as well as anastomotic stricture, leading to bowel movement. The transanal tube could be removed on day 7

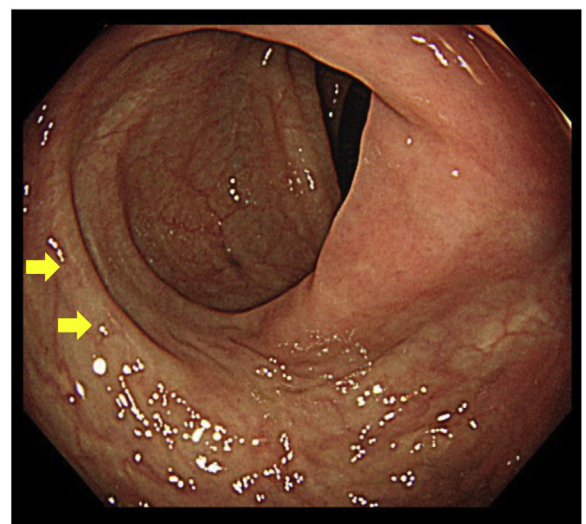


Fig. 6. Lower gastrointestinal endoscopy performed 5 months after surgery showed no anastomotic stricture (yellow arrow). A fiberscope passed smoothly through the site.

after placement. This technique produced direct luminal decompression via the transanal decompression tube and facilitated the daily administration of steroids around the stricture site. It is thus considered a new technique that can be used to effectively treat local inflammation.

In our patient, anastomotic stricture might have been improved by transanal decompression therapy alone. Because we only studied 1 patient, treatment effectiveness could not be accurately evaluated. However, we believe that ILe-SI and ILu-SI can be used as an option for additional treatment to prevent secondary complications caused by the long-term placement of a transanal decompression tube.

4. Conclusions

In patients with anastomotic strictures occurring after colectomy or proctectomy, symptoms can be promptly improved by direct transanal decompression therapy combined with local steroid treatment, thereby avoiding reoperation and shortening the hospital stay.

Conflicts of interest

The authors report that there are no conflicts of interest.

Funding

This research did not receive any specific grant from funding agencies in the public, commercial, or not-for-profit sectors.

Ethical approval

Written informed consent was obtained from the patient for publication of this case report and accompanying images. A copy of the written consent form is available for review by Editor-in-Chief of this journal on request.

Consent

Does not apply.

Author contribution

Masanori Hayashi, Atsushi Ikeda, Mitsuo Yokota, Hiroyuki Sako, Hiroshi Uchida, Ken Ikeda, Seiji Okusawa: writing.

10. Guarantor

Guarantor is Atsushi Ikeda.

References

- [1] B. Davis, D.E. Rivadeneira, Complications of colorectal anastomoses: leaks, strictures, and bleeding, *Surg. Clin. North Am.* 93 (2013) 61–87.
- [2] R.A. Agha, A.K. Fowler, A. Saetta, I. Barai, S. Rajmohan, D.P. Orgill, S.C.A.R.E. Group, The SCARE statement: consensus-based surgical case report guidelines, *Int. J. Surg.* 34 (2016) 180–186.

- [3] T. Watanabe, M. Itabashi, Y. Shimada, S. Tanaka, Y. Ito, Y. Ajioka, T. Hamaguchi, I. Hyodo, M. Igarashi, H. Ishida, S. Ishihara, M. Ishiguro, Y. Kanemitsu, N. Kokudo, K. Muro, A. Ochiai, M. Oguchi, Y. Ohkura, Y. Saito, Y. Sakai, H. Ueno, T. Yoshino, N. Boku, T. Fujimori, N. Koinuma, T. Morita, G. Nishimura, Y. Sakata, K. Takahashi, O. Tsuruta, T. Yamaguchi, M. Yoshida, N. Yamaguchi, K. Kotake, K. Sugihara, Japanese Society for Cancer of the Colon and Rectum (JSCCR) Guidelines 2014 for treatment of colorectal cancer, *Int. J. Clin. Oncol.* 20 (2015) 207–239.
- [4] A. Hiranyakas, G. Da Silva, P. Denoya, S. Shawki, S.D. Wexner, Colorectal anastomotic stricture: is it associated with inadequate colonic mobilization? *Tech. Coloproctol.* 17 (2013) 371–375.
- [5] C.B. Neutzling, S.A. Lustosa, I.M. Proenca, E.M. da Silva, D. Matos, Stapled versus handsewn methods for colorectal anastomosis surgery, *Cochrane Database Syst. Rev.* 2 (2012).
- [6] P.A. Lucha, J.E. Fticsar, M.J. Francis, The strictured anastomosis: successful treatment by corticosteroid injections—report of three cases and review of the literature, *Dis. Colon Rectum.* 48 (2005) 862–865.
- [7] K. Yokohata, K. Sumiyoshi, K. Hirakawa, Merits and faults of transanal ileus tube for obstructing colorectal cancer, *Asian J. Surg.* 29 (2006) 125–127.
- [8] M.V. Heppt, H. Breuninger, M. Reinholz, G. Feller-Heppt, T. Ruzicka, G.G. Gauglitz, Current strategies in the treatment of scars and keloids, *Facial Plast. Surg.* 31 (2015) 386–395.
- [9] M.E. rol Yıldırım, M. Kaynar, E. Ozyuvali, H. Badem, M. Cakmak, E. Kosem, The effectiveness of local steroid injection after internal urethrotomy to avoid recurrence, *Arch. Ital. Urol. Androl.* 87 (2015) 295–298.
- [10] H. Takahashi, Y. Arimura, S. Okahara, J. Kodaira, K. Hokari, H. Tsukagoshi, A randomized controlled trial of endoscopic steroid injection for prophylaxis of esophageal stenoses after extensive endoscopic submucosal dissection, *BMC Gastroenterol.* 15 (2015) 1–10.
- [11] K. Kataoka, I. Aoyama, J. Mizusawa, J. Eba, K. Minashi, T. Yano, M. Tanaka, N. Hanaoka, H. Katayama, K. Takizawa, H. Fukuda, M. Muto, A randomized controlled Phase II/III study comparing endoscopic balloon dilation combined with steroid injection versus radial incision and cutting combined with steroid injection for refractory anastomotic stricture after esophagectomy: Japan Clinical Oncology Group Study JCOG1207, *Jpn. J. Clin. Oncol.* 45 (2015) 385–389.
- [12] T. Mizutani, M. Tanaka, J. Eba, J. Mizusawa, H. Fukuda, N. Hanaoka, M. Takeuchi, I. Aoyama, T. Kojima, K. Takizawa, H. Ono, M. Muto, A Phase III study of oral steroid administration versus local steroid injection therapy for the prevention of esophageal stricture after endoscopic submucosal dissection (JCOG1217, Steroid EESD P3), *Jpn. J. Clin. Oncol.* 45 (11) (2015) 1087–1090.
- [13] J.C. Brooker, C.G. Beckett, B.P. Saunders, M.J. Benson, Long-acting steroid injection after endoscopic dilation of anastomotic Crohn's strictures may improve the outcome: a retrospective case series, *Endoscopy* 35 (2003) 333–337.
- [14] G. Di Nardo, S. Oliva, M. Passariello, N. Pallotta, F. Civitelli, S. Frediani, G. Gualdi, P. Gandullia, S. Mallardo, S. Cucchiara, Intralesional steroid injection after endoscopic balloon dilation in pediatric Crohn's disease with stricture: a prospective randomized, double-blind, controlled trial, *Gastrointest. Endosc.* 72 (2010) 1201–1208.
- [15] J.E. East, J.C. Brooker, M.D. Rutter, B.P. Saunders, A pilot study of intrastricture steroid versus placebo injection after balloon dilatation of Crohn's strictures, *Clin. Gastroenterol. Hepatol.* 5 (2007) 1065–1069.
- [16] A. Atreja, A. Aggarwal, S. Dwivedi, F. Rieder, R. Lopez, B.A. Lashner, A. Brzezinski, J.J. Vargo, B. Shen, Safety and efficacy of endoscopic dilation for primary and anastomotic Crohn's disease strictures, *J. Crohn's Colitis.* 8 (2014) 392–400.
- [17] L. Lian, L. Stocchi, B. Shen, X. Liu, J. Ma, B. Zhang, F. Remzi, Prediction of need for surgery after endoscopic balloon dilation of ileocolic anastomotic stricture in patients with Crohn's disease, *Dis. Colon Rectum.* 58 (2015) 423–430.
- [18] M. Karanikas, P. Touzopoulos, A. Mitrakas, P. Zezos, P. Zarogoulidis, N. Machairiotis, E. Efremidou, N. Liratzopoulos, A. Polychronidis, G. Kouklakis, Benign post-radiation rectal stricture treated with endoscopic balloon dilation and intralesional triamcinolone injection, *Case Rep. Gastroenterol.* 6 (2012) 583–589.
- [19] H. Mori, K. Rafiq, H. Kobara, S. Fujihara, N. Nishiyama, M. Oryuu, Y. Suzuki, T. Masaki, Steroid permeation into the artificial ulcer by combined steroid gel application and balloon dilatation: prevention of esophageal stricture, *J. Gastroenterol. Hepatol.* 28 (2013) 999–1003.
- [20] A. Agarwal, D. Singh, Bronchoscopic topical steroid instillation in prevention of tracheal stenosis, *J. Anaesthesiol. Clin. Pharmacol.* 30 (2014) 91.

Open Access

This article is published Open Access at [sciencedirect.com](https://www.sciencedirect.com). It is distributed under the [IJSCR Supplemental terms and conditions](#), which permits unrestricted non commercial use, distribution, and reproduction in any medium, provided the original authors and source are credited.