



Role of endoscopic ultrasound in vascular interventions: Where are we now?

Alessandro Fugazza, Kareem Khalaf, Matteo Colombo, Silvia Carrara, Marco Spadaccini, Glenn Koleth, Edoardo Troncone, Roberta Maselli, Alessandro Repici, Andrea Anderloni

Specialty type: Gastroenterology and hepatology

Provenance and peer review: Invited article; Externally peer reviewed.

Peer-review model: Single blind

Peer-review report's scientific quality classification

Grade A (Excellent): 0
Grade B (Very good): 0
Grade C (Good): C
Grade D (Fair): D
Grade E (Poor): 0

P-Reviewer: Altonbary AY, Egypt; Pal P, India

A-Editor: Liu X, China

Received: December 27, 2021

Peer-review started: December 27, 2021

First decision: February 21, 2022

Revised: March 8, 2022

Accepted: May 16, 2022

Article in press: May 16, 2022

Published online: June 16, 2022



Alessandro Fugazza, Matteo Colombo, Silvia Carrara, Marco Spadaccini, Glenn Koleth, Roberta Maselli, Alessandro Repici, Andrea Anderloni, Division of Gastroenterology and Digestive Endoscopy, Department of Gastroenterology, Humanitas Research Hospital, Rozzano 20089, Italy

Kareem Khalaf, Alessandro Repici, Department of Biomedical Sciences, Humanitas University, Pieve Emanuele 20090, Italy

Edoardo Troncone, Department of Systems Medicine, University of Rome "Tor Vergata", Roma 00133, Italy

Corresponding author: Alessandro Fugazza, MD, Division of Gastroenterology and Digestive Endoscopy, Department of Gastroenterology, Humanitas Research Hospital, Via Manzoni 56, Rozzano 20089, Italy. alessandro.fugazza@humanitas.it

Abstract

From a mere diagnostic tool to an imperative treatment modality, endoscopic ultrasound (EUS) has evolved and revolutionized safer efficient options for vascular interventions. Currently it is an alternative treatment option in the management of gastrointestinal bleeding, primarily variceal type bleeding. Conventional treatment option prior to EUS incorporation had limited efficiency and high adverse events. The characterization and detail provided by EUS gives a cutting edge towards a holistically successful management choice. Data indicates that EUS-guided combination therapy of coil embolization and glue injection has the higher efficacy for the treatment of varices. Conversely, similar treatment options that exist for esophageal and other ectopic variceal bleeding was also outlined. In conclusion, many studies refer that a combination therapy of coil and glue injection under EUS guidance provides higher technical success with fewer recurrence and adverse events, making its adaptation in the guideline extremely favorable. Endo-hepatology is a novel discipline with a promising future outlook, we reviewed topics regarding portal vein access, pressure gradient measurement, and thrombus biopsy that are crucial interventions as alternative of radiological procedures. The purpose of this review is to provide an update on the latest available evidence in the literature regarding the role of EUS in vascular interventions. We reviewed the role of EUS in variceal bleeding in recent studies, especially gastric varices and novel approaches aimed at the portal vein.

Key Words: Endoscopic ultrasound; Cyanoacrylate; Coil injection; Gastric varices; Gastrointestinal bleeding; Vascular endoscopic treatments

©The Author(s) 2022. Published by Baishideng Publishing Group Inc. All rights reserved.

Core Tip: Currently endoscopic ultrasound (EUS) is an alternative treatment option in the management of gastrointestinal bleeding, primarily variceal type bleeding. This manuscript tackles a comprehensive review for the uses of EUS in the majority of vascular interventions with regard to gastrointestinal bleeding and offers a directive for the technical aspects in carrying out a procedural treatment of combination coil and glue therapy for gastric varices.

Citation: Fugazza A, Khalaf K, Colombo M, Carrara S, Spadaccini M, Koleth G, Troncone E, Maselli R, Repici A, Anderloni A. Role of endoscopic ultrasound in vascular interventions: Where are we now? *World J Gastrointest Endosc* 2022; 14(6): 354-366

URL: <https://www.wjgnet.com/1948-5190/full/v14/i6/354.htm>

DOI: <https://dx.doi.org/10.4253/wjge.v14.i6.354>

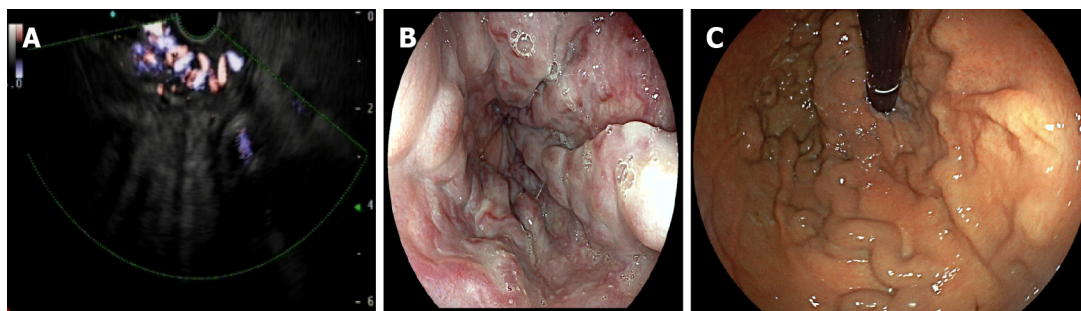
INTRODUCTION

The endoscopic ultrasound (EUS) technology has dramatically evolved since its conception in the 80s, transforming from a supplementary add-on of the diagnostic process to a core modality in the diagnosis and therapy in a wide range of diseases[1]. EUS diagnostic capability has evolved immensely in recent years primarily enhancing fine needle aspiration (FNA) and fine needle biopsy, the acquisition of particularly gastrointestinal (GI) and pancreato-biliary lesions, providing cytohistologic sampling[2]. Having the diagnostic sensitivity of 85% to 95% in detecting malignant pancreatic tumors and specificity of 100%, EUS guided FNA is being regarded as a main staple if not a gold standard by many experts[1]. Further extending the reach towards lesions of the pancreas, mediastinal adenopathy, GI tract submucosal lesions and retroperitoneal masses, EUS provides a detailed image and obtains tissue samples in a minimally invasive manner that is safe and accurate for diagnosis[3,4]. On the other hand, therapeutic EUS-guided drainage is a favored option in the management of pancreatic fluid collections, biliary and gallbladder diseases[5-7]. Moreover, the indications for interventional EUS grow more and more having nowadays a central role in the management of biliary diseases in altered anatomy, gastric outlet obstruction and post-surgical abdominopelvic fluid collection drainage[8-11].

Under the scope, focusing on various GI conditions, initially EUS provided clinicians with valuable information pertaining to clinical and anatomic information. Aspects such as the appearance, size and location of a structure indicated variable descriptive factors regarding a plethora of conditions[12]. Due to the proximity of the GI system to vascular structures, EUS today can provide precise interventions that target inaccessible, or less accessible surrounding vascular sites[12]. EUS has advanced as alternative treatment option in the management of GI bleeding providing an efficient treatment modality and offering fewer adverse events (AEs). Effective treatment options that are EUS guided exist, such as sclerotherapy, tissue adhesive injections, and coil embolization. Recently, the employment of glue injection and coil embolization techniques with EUS seem to be thriving in clinical practice. Stand-alone therapy options present with variable risk factors and complications, ultimately delegating to clinicians and technicians in the field to utilize a combination of both glue injection and coil embolization under the guidance of EUS[13]. The purpose of this review is to provide an update on the latest available evidence in the literature regarding the role of EUS in vascular interventions.

TECHNICAL FEATURES

Primarily, prior to the promotion of EUS, definitive understanding of the technical strengths and limitation it encompasses is key to its adoption into clinical practice. First and foremost, EUS provides precise targeting of vascular structure in direct proximity for the GI wall (Figure 1A). It further allows visualization reducing the risk of injection out of site[12]. It is also worth mentioning, the precision regarding biopsies of tissues is much higher than the conventional method. Furthermore, EUS provides a sort of 'check-up' following procedures such as the obliteration of a varix, that grants validity for a clinician achieving technical success. Conversely, nothing is without limitations and EUS is not short of either, ultrasonography remains to have a steep learning curve. Additionally, following the transmural access into deeper tissue, bleeding from the extra-luminal side is not accessible by endoscopy, causing



DOI: 10.4253/wjge.v14.i6.354 Copyright ©The Author(s) 2022.

Figure 1 Endoscopic images. A: Endoscopic ultrasound-Doppler detecting gastroesophageal varices; B: Endoscopic view of large esophageal varices (classified as grade 2 at Westaby classification)[19]; C: Endoscopic view in retroversion of gastro-esophageal varices (classified as gastroesophageal varix 2 at Sarin classification)[22].

urgent surgical or radiological therapy. Likewise, AEs exist with the use of EUS, although at a much lower rate than the conventional therapy, the risk still exists and may be fatal. The caliber of the EUS aspiration channel is restrictive and multiple predicaments arise[14]. Firstly, luminal contents may not be aspirated creating artifacts that hinder the sonographic image during the procedure. Secondly, the reduction in caliber size limits the apparatus from removing blood clots that not only obstruct the view but may lead to further thromboembolic events that may be fatal[15]. A larger range of accessories and devices designed for ultrasonography, miniature apparatus, correct antibiotic prophylaxis may tackle some of the limitations mentioned. Ultimately the standardization of a technique of injection, volume of injection, size of coils, and speed of injection are challenges to confront while adapting a universal methodology for any EUS-guided procedure[15].

Initially, a prior conventional endoscopic examination is necessary to confirm varix type and concomitant esophageal varices with gastric varices. The procedure should be performed with the patient under deep or conscious sedation, according to each institution protocol. Using a linear echoendoscope for the evaluation of varix size and treatment evaluation is the mode of choice[16]. Once the varix is identified under EUS, it is necessary to characterize the total diameter of the widest varix which should be punctured by a 19G needle[17]. It is important to choose the size of the coil depending on the size of the widest varix. More importantly, the size of the coil should not exceed the caliber of the vessel it is injected into. In case of glue injection, following the deployment of the coil, 2 mL of distilled water followed by 0.5 mL of N-butyl-2-cyanoacrylate, followed by another 2 mL of distilled water was injected and then the needle removed[17]. Lastly, EUS with Doppler flow is important for technical success evaluation. The presence or absence of flow within the varix is what is evaluated[6,16,17].

TYPE OF BLEEDING

Variceal bleeding

Variceal bleeding is known to be the most feared lethal complication of portal hypertension. Whilst gastric varices tend to be the most problematic; esophageal, rectal, and other ectopic locations present with serious complications. As described in further detail below, guidelines offer a wide range of therapeutic options depending on location of the varix, whether offering standard endoscopic, surgical, or interventional radiologic therapies, each come with strengths and weaknesses. While centering our focus on standard endoscopic treatments, we find major limitation in the addressed therapies, whether it's a matter of severe AEs and high risk or a high recurrence rate of the varix rebleeding and a low clinical outcome. Under EUS guidance, coincidentally due to higher precision of vascular targeting, the treatment options deemed more efficient with an overall higher success rate and clinical outcome[18]. Furthermore, the recommendation enclosed reports that EUS is a feasible safe option for patients who were unsuccessful candidates for conventional therapies[18].

Variceal classification

Different classifications for esophageal varices have been created, to mention a few: Dagradi, Conn's, Paquet's, Westaby, Calès and Soehendra[16]. The most used one are the Westaby and Dagradi's classification.

Westaby's offers a three-grade system classification of identifying the progression of esophageal varices classified as[19]: Grade 1 varices appearing as slight protrusion from the mucosa, which can be depressed with insufflation [20]; Grade 2 varices occluding less than 50% of the lumen (Figure 1B); Grade 3 varices occupying more than half of the lumen and are extremely close to one another with a confluent appearance.

Alternatively, the Dagradi classification is a five-grade system for esophageal varices classified as [20,21]: Grade 1 varices less than 2 mm in diameter that are linear or sigmoid in shape and appear with compression of the wall with the scope, they usually present as blue or red in color; Grade 2 are blue varices sized between 2-3 mm in diameter and are mildly tortuous or straight and elevated; Grade 3 are blue tortuous or straight varices sized between 3-4 mm in diameter; Grade 4 are varices larger than 4 mm that surround the esophageal lumen and are closely neighboring each other around the wall with or without mucosal cover; Grade 5 are grape like varices that occlude the lumen and present as red varices overlying blue varices; 'varices over varices'.

Similarly, the most used classification for gastric varices is the 'Sarin's' classification[22]. Four different types based on their location in the stomach are classified as two types of gastroesophageal varix (GOV) and two types of isolated gastric varix (IGV)[23]. Type GOV1 are varices that extend in the cardia to lesser curvature of the stomach. Type GOV2 are varices that extend from the cardia towards the greater curvature of the stomach, terminating at the gastric fundus (Figure 1C). Type IGV1 are varices in the gastric fundus that do not extend to the esophagus. Type IGV2, also referred to as ectopic gastric varices occur in other parts of the stomach. To a certain degree many clinicians regard esophageal varices and type GOV1 as gastroesophageal varices whilst GOV2 and IGV1 are fundal varices[20,23].

ESOPHAGEAL VARICES

Esophageal variceal bleeding is much more common than gastric varices, with high morbidity and mortality but fortunately carries less detrimental complications. In essence esophageal varices is a collateral circulation that develops due to portal hypertension[13]. Esophageal varices hemodynamics differ from patient to another, thus making their treatment problematic[14]. Guidelines state that first line treatment of esophageal bleeding is to be treated by endoscopic band ligation followed by trans-jugular intrahepatic portosystemic shunt (TIPS) or endoscopic sclerotherapy, both pose significant risk to the patient[12]. Endoscopic preventative bleeding measures for esophageal varices include endoscopic injection sclerotherapy (EIS) and endoscopic variceal ligation (EVL)[18]. Primarily EIS, a much older technique, involved the embolization of the feeder veins by injecting a sclerosing agent that maintained the regression of the collateral circulation. Thus, by inhibiting the hemodynamics of the varices' the recurrence remained low[24]. Unfortunately, the complexity of delineating the circulations hemodynamics and the high complication risk associated, EIS remains a challenging option for the treatment of variceal esophageal bleeding. In efforts to a more effective treatment with less complications, EVL was developed[24]. EVL as the name suggests ligates the varices and thus blocks the flow of blood in the collateral area. Since the technique doesn't target the feeder vessel, recurrence rate is high. In hindsight EVL's main limitation is the lack of clinical and anatomical information on the hemodynamics of the circulation and the feeder vessel[25]. On the other hand, EUS provides a selective safe effective treatment option that can predict variceal recurrence, estimate the circulation's hemodynamics, and provide follow-up screening and management[26]. A study with the aim of studying the relationship of both treatments (EVL and EIS) recurrence used 3D-EUS and defined four main variceal circulation patterns as: cardial inflow without paraesophageal veins, cardial inflow with paraesophageal veins, azygos-perforating pattern, and a complex pattern. The study concluded the use of EVL to be limited to collaterals running parallel to the varices whilst sclerotherapy to be used for paraesophageal veins with a larger diameter and a perforation pattern[18]. Furthermore, the utilization of EUS technology provided effective directed treatment option of pattern types that aided a successful clinical outcome[27]. Moreover, in one study that utilized a sclerosing agent targeted under EUS guidance, an average of 2 to 3 sessions required to achieve complete obliteration. The study further reported in their cohort of 5 patients; no bleeding recurrence or death and one patient developed an esophageal stricture that was treated with balloon dilation[28].

GASTRIC VARICES

Standard therapy for gastric varices by current guidelines recommends the use of endoscopic cyanoacrylate (CYA)[29]. High bleeding rates and fatal AEs mandates the need for a more feasible option such as EUS guided. EUS-guided therapy provides high technical success and an overall better safety profile [24,29]. Romero-Castro *et al*[30] in a retrospective analysis that aimed at a direct comparison of the variable EUS-guided methods showed similar obliteration rate of gastric varices in both CYA injection and coil embolization (Table 1). Mohan *et al*[18] carried a meta-analysis that presented that the combination of EUS-coil/CYA had significantly fewer instances of gastric varices recurrence than EUS guided CYA injection (5.2% vs 15%). Furthermore, McCarty *et al*[31] reviewed a meta-analysis of 11 studies compared EUS-guided methods and discovered similar advantages to the combined approach. Their results showed that EUS-coil/CYA had a significantly higher rate of GV obliteration than either EUS-CYA (98% vs 96%) or EUS-coil (98% vs 90%). Moreover, the combination of EUS-coil/CYA had a

Table 1 Comparison of the main studies reporting data of endoscopic ultrasound guided treatments for gastric varices

Ref.	Study design	Number of patients	Technical success	Clinical success	Adverse events
Romero-Castro <i>et al</i> [30], 2013	Retrospective analysis of a prospectively maintained database	30 total patients, 11 ECA, 19 CYA	27/30 (90%)	18/19 (96.7%) CYA; 10/11 (90.9%) ECA	40% total AEs; CYA 11/19 (57.9%); ECA 1/11 (9.1%)
Lóbo <i>et al</i> [17], 2019	Randomized Controlled Trial	32 total patients; 16 ECA + CYA, 16 CYA	-	-	Early AEs: 8 (50%) ECA + CYA; 10 (62.5%) CYA. Pulmonary embolism: 4 (25%) ECA + CYA; 8 (50%) CYA
Robles-Medrand <i>et al</i> [29], 2019	Randomized Controlled Trial	60 total patients, 30 ECA + CYA; 30 ECA	60/60 (100%) in both groups	ECA + CYA 30/30 (100%), ECA 27/30 (90%)	ECA + CYA 2/30 (6.7%); ECA 1/30 (3.3%)
Bazarbashi <i>et al</i> [16], 2020	Prospective Study	40 total patients; 10 ECA, 30 CYA	10/10 (100%) ECA; 29/30 (96.7%) CYA	10/10 (100%) ECA; 26/30 (87%) CYA	10% ECA; 20% CYA

ECA: Endoscopic coil application; CYA: Cyanoacrylate; AE: Adverse event.

lower recurrence rate than their singular respective modalities. The combination modality had lower rebleeding rate and frequency of AE than EUS-CYA[29,32]. Data indicates that EUS-guided combination therapy of coil embolization and glue injection has the higher efficacy for the treatment of varices. Similarly, another interesting study reported that although combined therapy had a superior safety profile over EUS-guided CYA injection, when compared to EUS coil injection similar results were obtained[29]. However, an interesting notion to point out is that coil embolization is technically demanding when compared EUS-guided glue injection[14]. In efforts to reassess a proper direction for the leading choice of treatment, multiple factors come into play. Evaluating technical success, AEs, recurrence rate and clinical outcomes shape the best decision in moving forward[14].

A meta-analysis and systematic review that aimed to evaluate the effectiveness of the above-mentioned outcome measures, studied comparative groups of mono and combination modalities[31]. Overall technical success, clinical success, and AEs for EUS treatments was 100%, 97% and 14%, respectively. Moreover, EUS-guided CYA + coil embolization resulted in a better technical and clinical success compared to CYA alone (100% *vs* 97% and 98% *vs* 96%) and coil embolization alone (99% *vs* 97% and 96% *vs* 90%)[18]. Similar results coming from a single center observational study outlines primary preventative prophylactic treatment of gastric varices and the use of combination EUS of coil and CYA glue injection as the preferred modality achieving 100% technical success, 96.7% gastric varices obliteration on EUS confirmation and post-treatment recurrence was at 2.5% and AEs at 4.9%[33].

EUS further provides an advantage in the use of CYA injection in the obliteration of gastric varices as an overall lower mean volume of the glue is needed to reach similar technical success with the same safety profile of rebleeding rates being (8.8% *vs* 23.7%)[32]. One study mentioned less incidence of pulmonary embolism for EUS guided coil embolization when compared to EUS CYA therapy[29]. Coil based therapy for the treatment of gastric varices was reported to be superior to traditional endoscopic therapy with CYA injection[16]. In another study, EUS guided coil therapy exhibited high technical success rates, low AE rates, superior time to rebleed, time to repeat transfusion, and time to repeat intervention when compared to endoscopic CYA injection[16]. The study further concluded that the rate of rebleeding in the CYA arm was 38% which was higher than what was that literature 20%-30%. A single center parallel RCT studied efficacy and safety of EUS-guided coil embolization and CYA injection *vs* EUS-guided coil embolization alone in the managing gastric varices. Interestingly, the immediate disappearance of varices was observed in 86.7% of patients treated with coils and CYA, *vs* 13.3% of patients treated with coils alone indicating the combination therapy to offer an immediate surveillance feature within the procedure. Likewise, the combined treatment, had 83.3% of patients free from reintervention when compared to coil alone 60%[34]. One study reported no statistical difference between EUS guided coils plus CYA *vs* conventional CYA technique in relation to the incidence of embolism. The study concluded a larger tendency of patients to develop embolism when compared to the conventional endoscopic technique without EUS[18]. With regards to the choice of tissue glue/adhesives, CYA, one study aims to evaluate the safety in applying EUS-guided modality of hydro coils in gastric varices. Hydro coils are coils coated with different types of expandable hydrogel polymers, causing rapid occlusion of vessels, and favoring thrombus formation. The study reported fewer recurrences 8.6% and no differences with regard to side effects when compared to CYA[31].

ECTOPIC VARICES

Following the recommendation of current guidelines, endoscopic band ligation and glue injection are

the established techniques for managing ectopic variceal bleeding[18]. One example are duodenal varices, common in end-stage patients with decompensated cirrhosis, current treatment options include TIPS, endoscopic band ligation or sclerotherapy. Commonly patients presenting with duodenal varices are referred to endoscopic treatment for bleeding prevention and EUS guided situations the clinicians technical outcome at an advantage[35]. EUS provides superior characterization of the variceal complex and offers higher obliteration with a lower recurrence rate in compared to the conventional treatments. Thus, offering a feasible safe option to manage these patients[14].

Rectal varices are a well-recognized complication of portal hypertension[36]. The perforator vein supplies the variceal circulation, which invaginates superficially and bleeds. Common treatment options include interventional radiology and surgery with a mortality rate documented as high as 80%[36]. Well regarded recommendation in a previous study showed that the injection 2 mL of N-butyl 2-CYA into the varix, thrombosed the collaterals and bleeding subsided in 2 wk[37]. In attempts to further reduce conventional interventional radiology mortality rates in the treatment of rectal varices, a study suggested the added benefit of EUS-guided treatment that provides an overall better diagnostic approach and higher technical success in targeting the perforator vein directly thus achieving homeostasis with less coils and hence overall less AE rates[36].

Additionally, most of the literature evaluating EUS guided techniques focus on upper GI bleeds. One study reported overall clinical outcome success in patients with rectal bleeding in all mono and combination modalities[37]. Authors recommend targeting the feeder vein in patients referred for endoscopic management if unfit for surgical or interventional radiological treatment[37]. Likewise, duodenal ectopic varices usually present in patients with end-stage liver disease, which are referred for endoscopic treatment to prevent bleeding. In one study authors recommended EUS-guided interventions, specifically combined therapy as it offers a superior complete obliteration rate to monotherapy[35].

Non-variceal bleeding

Upper GI bleeding not attributed to varices is common having multiple etiologies, peptic ulcer disease, erosive diseases, Mallory-weiss syndrome, Dieulafoy's lesions, gastric antral vascular ectasia, peripancreatic pseudoaneurysm and others (Figure 2). Definitive management measures involving EUS-guided therapies provide a novel treatment option with optimal efficacy. As a result of the steep learning curve and the need of extensive training programs in endosonography, EUS-guided angiotherapy for acute GI bleeding is limited to tertiary centers. EUS-guided management of non-variceal upper GI bleeding is an innovative option especially in cases of recurrence. Simultaneous characterization of the bleed and intra-procedural ensuring of therapy effectiveness provides an extra edge in comparison to conventional therapy[15]. That being said, literature on the matter is limited and no randomized controlled trials are available. Further studies need to clarify efficacy and safety in larger robust trials.

PSEUDOANEURYSM EMBOLIZATION

Pseudoaneurysms are blood collections that surround injured tissue, commonly known as false aneurysms and differ from true aneurysms, which form a blood-filled sac and bulge from the vessel wall[38]. With a prevalence of 0.04-0.1%, pseudoaneurysms are commonly associated with the splenic artery. Importantly, pseudoaneurysms usually occur following abdominal infections or post-pancreatitis[39]. Pseudoaneurysms are asymptomatic in most cases and usually appear as an incidental finding on radiological graphs. Due to the detrimental high rupture risks of up to 20%, allow for EUS-guided therapy to be an effective option for patients[40]. Many case-reports and series outlined good outcomes with obliteration of pseudoaneurysm following EUS-guided treatment, as reported by Mann *et al*[27], in a recent review of the literature. Recently, one study by Rai *et al*[41], aimed to study EUS-guided glue and coil injection in six patients who failed angiographic embolization of splenic artery pseudoaneurysm. Complete obliteration was achieved in all patients with larger aneurysms, requiring a 'larger' injection of coils and glue (1-2 mL). Moreover, no AEs occurred in any of these patients. Looking forward, this may provide an effective technique for the treatment of pseudoaneurysm in different abdominal segment accessible under EUS-guidance. Table 2 outline technical features from case report series on therapeutic management of pseudoaneurysms under EUS-guidance.

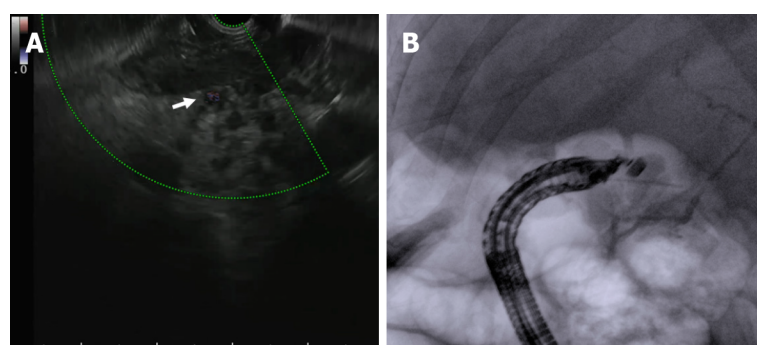
ENDO-HEPATOLOGICAL INTERVENTIONS

Nearing the last decade, a sub discipline of endoscopy named "Endo-hepatology", was introduced. In an aim to move towards a more accurate diagnosis, former procedures such as diagnostic biopsies and pressure measurements were advanced. Body habitus always posed as a challenging limitation whilst performing a biopsy of the liver however, using EUS, circumventing this problem became feasible and furthermore, simultaneous bi-lobar biopsies were possible[42]. EUS also improved patients' perception

Table 2 Case reports on endoscopic ultrasound-guided treatment of pseudoaneurysms

Ref.	Design	Technical success (%)	Adverse events	Recurrence	Needle size	Treatment
Robb <i>et al</i> [61], 2012	Case Report	100	None	None after 5 mo follow-up	19G	Pseudoaneurysm embolization
Gamanagatti <i>et al</i> [62], 2015	Case Report	100	None	Recurrence; asymptomatic	22G	Thrombin injection 300-500 units
Mann <i>et al</i> [27], 2017	Case Report	100	Not reported	None after 2 wk follow-up	19G	5 coils of 10 mm size were placed, 3000 units of thrombin injected
Jhajharia <i>et al</i> [63], 2018	Case Report	100	Not reported	None in all three patients	Not reported	1000 units of thrombin
Gunjan <i>et al</i> [63], 2018	Case Report	100	Not reported	None after 9 mo follow-up	19G	3 mL of undiluted N-butyl-cyanoacrylate
Sharma <i>et al</i> [65], 2019	Case Report	100	None	Full obliteration on 2-wk follow-up	19G	Five 10 mm coils placed, 6 mL of 3000 units of thrombin injected in six boluses of 500 units each

G: Gauge.



DOI: 10.4253/wjge.v14.i6.354 Copyright ©The Author(s) 2022.

Figure 2 Embolization of the gastroduodenal artery with cyanoacrylate glue due to active bleeding. A: Ultrasound view of the gastroduodenal artery (arrow); B: Fluoroscopic view of the gastroduodenal artery.

of undergoing a biopsy, due to the decreased recovery time and better tolerance overall. The added benefit did not revolve around technical expertise, as previous options required less technical training. The advantage lies with the reduction in sampling error due to the bi-lobar biopsies[42]. Additionally, EUS biopsies can be concurrently carried out with portal pressure measurements in a singular procedure, providing a more appealing option to patients than the trans-jugular approach. That anatomic proximity of the stomach and duodenum to major vascular structures, make EUS a vital technique in accessing structures such as the portal vein (PV). Existing applications of PV interventions using EUS include sampling, embolization, thrombolysis, and stent placement[27].

PV interventions: Sampling, pressure measurement and embolization

Circulating tumor cells (CTC) in the PV offer a positive predictive value of liver metastasis from pancreatic and colorectal cancers. The sampling of CTC under EUS guided access is vital, as CTC are more prevalent in the PV than in the peripheral blood. This provides an advantage with EUS, in order to sample tumor cells for further analysis[43]. The first report of EUS-guided PV sampling was in 2015, followed by another study in 2017 that similarly reported the safety and technical feasibility of the technique[43]. Chapman and Waxman[44] studied the propensity of CTCs as compared to sampling the PV under EUS guidance (19 gauge) with peripheral blood. In 18 patients, 100% sampling of CTC from the PV was achieved in comparison to 22.2% from the peripheral blood. Methodologically, the literature suggests multiple levels of consideration for PV sampling under EUS-guidance, due to limited data on safety and insubstantial unanimity of the technical feature of the procedure. Primarily, all bleeding risk should be addressed prior to the procedure and monitored anesthesia is an advocated preference in many studies. Secondly, pre-assessing the PV under ultrasonography and FNA vein sampling was reviewed. The EUS-FNA needles available in today's market are the 19, 22, and 25 gauge sizes[44]. Chapman and Waxman[43], recommended the use of a 19-gauge FNA needle to allow adequate blood flow, that minimizes the time within the vessel to decreases clotting as compared to the smaller needles.

Ultimately, there is a lack of studies that assess the viability of the specimens obtained and the feasibility of the methodology. It is crucial to assess the patency of the vasculature with ultrasonographic doppler prior to the FNA access, in order to better reduce AEs.

Portal pressure gradient is an important measurement for the diagnosis of portal hypertension. Regardless of clinical evidence, a hepatic venous pressure gradient of 10 mmHg or more defines the presence of portal hypertension and is an important indicator of PH complication, most often for cirrhosis. Currently, a percutaneous approach exists for measuring PV pressure through a trans jugular access to the PV *via* the hepatic veins. Reduced conformity from patients due to catheterization makes an EUS-guided option more favorable[45].

Following the development of the compact manometer, EUS-guided portal pressure gradient measurement with a needle in the PV and manometer, accurately reflect an indicator of liver disease [27]. Under EUS, a 22-gauge FNA needle connected to a compact manometer, accurate hepatic venous pressure gradient measurement can be attained[46]. In a recent study by Hajifathalian *et al*[47], a simultaneous EUS-guided portosystemic pressure measurement and liver biopsy sampling in 24 patients with suspected liver disease or cirrhosis, was performed. Twenty-three patients reached technical success (96%) for portosystemic gradient measurement and 100% technical success for liver biopsy. The study concluded that EUS portosystemic gradient measurement and liver biopsy sampling provided a safe and feasible option in clinical practice. Table 3 lists studies on PV pressure gradient measurement, outlining technical success, features and complications, adapted from[48].

In the management of liver diseases, PV embolization (PVE) is a possible intervention aimed at inducing atrophy of a lobe of the liver. This is advantageous, as it reduces the volume of the injured lobe prior to resection and concomitantly hypertrophies other healthy lobes, to decrease hepatic dysfunction and aiding preoperative preparations to liver lobectomy[27]. PVE is limited in multiple studies to animal models, due to the high-risk association with AEs, such as liver dysfunction. Loffroy *et al*[49] outlined PVE technique by accessing the portal system under EUS. Puncturing the peripheral branch by way of puncturing the left and embolizing the right branch is advantageous over puncturing and embolizing the right branch, due to easier catheterization. This method is conversely disadvantageous due to a high risk of damaging healthy liver remnants. Cirrhotic patients with portal pressure gradient larger than 12 mmHg, should avoid PVE due to detrimental AEs. Regarding the choice of the embolic agent, the authors suggested the use of a mixture of n-butyl-cyanoacrylate and iodized oil due to its rates of low morbidity. In anticipation to future advances, PVE under EUS-guidance can be appealing intervention in managing patients prior to surgical lobectomy.

Angiography

The direct access to the PV during an angiography may provide valuable clinical information. Unfortunately, routine practice avoids its implementation due to its invasive nature and high risk of complications[50]. A preliminary study in this field highlighted this fact in greater detail, as it showed that puncturing the PV with a 22-gauge needle led to high-risk bleeding measures in a porcine model[51]. In one study that evaluated the feasibility and safety of EUS-guided PV angiography with a smaller-caliber (25 gauge) FNA needle using carbon dioxide (CO₂) as a contrast agent in a porcine model. In 6 animal experimental trials, the authors achieved (19.83 ± 1.68 s) opacification of the entire portal system (visualization score 4.33 ± 0.52). The study reported no complications intraoperatively or at post-mortem examination, concluding that the study was feasible, safe, and technically simple. It is imperative to note that a major limitation to such studies is that they are acute animal models[52]. Replication into human disease remains confined in a plethora of possible complications and high bleeding risk.

Thrombus FNA

A large majority of patients suffering from hepatocellular carcinoma (HCC), have PV thrombosis. PV tumor thrombosis (PVTT) is essential as it is a poor prognostic sign and a contraindication for surgical hepatic resection. Extrahepatic PV access under EUS guidance, manages to access the thrombus without puncturing liver parenchyma, a favorable option for patients[27]. In 2015, Kayar *et al*[53] presented a case series of three cases that failed the normal route of imaging diagnosis of PV thrombus. Alternatively, from prior case reports, the patients were diagnosed with EUS-FNA of the PV thrombus as a first line diagnostic option. In all three cases presented, the authors used a 25-gauge FNA needle to biopsy the thrombus. Table 4 reports recent studies that highlighted cases of thrombus FNA-biopsy under EUS, notably when failed radiological diagnosis was unable to accurately stage HCC. Interestingly, Gimeno Garcia *et al*[54] in a multicenter study found that post EUS-FNA of thrombus, upstaging of HCC was prevalent up to 85.70%. In accordance with this finding, EUS-FNA biopsy of PVTT provides the most accurate staging diagnosis of HCC. High prospects for an EUS-guided intervention in diagnosing PVTT in patients that failed prior routes exist and should be studied in large RCT for a more widespread adaptation in everyday practice.

Drug administration

Even since the conception of curvilinear array echoendoscope in the 90's, the possibility to access structures with a needle under ultrasonographic visualization made treatment options to inaccessible

Table 3 Table summarizing technical features, success, and complications of studies on portal vein pressure gradient measurement

Ref.	Design	Technical success (%)	Adverse events	Post-procedural necropsy	Gauge needle used
Lai <i>et al</i> [51], 2004	Comparative Study - Animal Model	90	Subserosal hematoma in one porcine subject	After 4 d	22
Giday <i>et al</i> [52], 2007	Comparative Study - Animal Model	100	None	Day 0 and after 2 wk	19
Buscaglia <i>et al</i> [66], 2008	Comparative Study - Animal Model	100	None	Postprocedural	19
Huang <i>et al</i> [67], 2016	Comparative Study - Animal Model	100	None	Not reported	25
Schulman <i>et al</i> [68], 2016	Comparative Study - Animal Model	100	None	Postprocedural	25
Garg and Rustagi [48], 2017	Human Pilot Study	100	None	Not reported	25
Garg and Rustagi [48], 2017	Human Pilot Study	100	None	Occured on day 0, 1 and 7	25
Huang <i>et al</i> [69], 2017	Human Pilot Study	100	None	Not reported	25
Zhang <i>et al</i> [46], 2021	Prospective Study	91.70	None	Not reported	22

Table 4 Table summarizing studies and case reports of portal vein thrombus biopsy

Ref.	Design	Technical success (%)	Adverse events	Upstaging post EUS-FNA	Cytological analysis
Gimeno Garcia <i>et al</i> [54], 2018	Multicenter Study	87.50	None	85.70%	Used to determine final diagnosis
Rustagi <i>et al</i> [70], 2017	Prospective Study	100	None	37.50%	Malignant cytology in 12 patients out of 17 (70.6%; 10 positive, 2 suspicious)
Kayar <i>et al</i> [53], 2015	Case Report	100	None	Not reported	Invasion of PV by HCC
Moreno <i>et al</i> [71], 2014	Case Report	100	None	Not reported	Invasion of PV by HCC
Michael <i>et al</i> [72], 2011	Case Report	100	None	Not reported	Malignant cells consistent with poorly differentiated HCC

HCC: Hepatocellular carcinoma; EUS: Endoscopic ultrasound; PV: Portal vein; FNA: Fine needle aspiration.

structures possible. Further evolving into a therapeutic tool, being a minimally invasive approach for treating benign lesions, relieving compartmental pain, and controlling growth in unresectable malignancies is cutting edge[55]. EUS-guided therapeutic administration has been implemented apart from its varying levels of efficacy[56]. These ablative therapies under EUS-guidance are not a sole alternative to surgical resection, especially for metastatic tumors, but represent an option for patients that are not eligible for surgery. Moreover, recent studies show that chemotherapeutic administration into the PV increases the drug concentration in hepatic tissue than its systemic counterpart[57]. In 2016, an EUS-guided intervention for the injection of the PV was studied in a porcine model. Using a 22-gauge needle, 100mg of irinotecan, albumin-bound paclitaxel nanoparticles and doxorubicin loaded microbeads were injected into the PV. The study reported technical success in all animals, with no acute AEs occurring, suggesting a possible future avenue to be explored in human diseases[58].

CONCLUSION

Regrettably, to the best of our knowledge, EUS-guided treatment still has limitations and further studies are needed to demonstrate superiority over conventional medical and radiological therapies[18]. Primarily the steep learning curve and the need for expertise that may not be dispersed in all centers make it extremely difficult for guidelines to adapt strict recommendations in clinical practice[59]. Moreover, due to this revolutionary technology still being in the premature stages of adaptation into

clinical practice, a unified or standardized methodology doesn't exist. Whether the type of echo-endoscope, the positioning during therapy or the type of equipment used, a non-universal approach makes room for variable clinical outcomes and technical success rates[60]. On the other hand, EUS-guided therapy has potential to improve and become a main staple in the management of gastric varices [32]. In conclusion, EUS is without a doubt a novel diagnostic and therapeutic option for a variety of vascular complications, principally at the moment gastric variceal hemorrhage[59]. EUS offers a better understanding of the anatomic and hemodynamic components associated with the variceal system and offers advanced therapeutic options with sounder clinical outcomes. Although limited to major tertiary centers and operator dependence with a long learning curve, the adoption of EUS into clinical practice is plausible if EUS procedures were standardized, enhanced training tools for clinicians and better universal image interpretation methodology[26]. Artificial intelligence in aiding clinical technicians with image interpretation may be a captivating step in the right direction in the evolution of this vital technology.

FOOTNOTES

Author contributions: Fugazza A and Khalaf K conceived the design of the work, writing the article and acquiring data; Colombo M, Carrara S, Spadaccini M, Koleth G, Troncone E and Maselli R acquired data and prepared the figures; Repici A and Anderloni A revised it critically for important intellectual content; all authors reviewed and approved the final version of the paper.

Conflict-of-interest statement: Fugazza A is a consultant for Boston Scientific and Olympus. Repici A is a consultant for Boston Scientific, Fujifilm, ERBE. Anderloni A is a consultant for Boston Scientific and Olympus. The remaining authors have no conflict of interest.

Open-Access: This article is an open-access article that was selected by an in-house editor and fully peer-reviewed by external reviewers. It is distributed in accordance with the Creative Commons Attribution NonCommercial (CC BY-NC 4.0) license, which permits others to distribute, remix, adapt, build upon this work non-commercially, and license their derivative works on different terms, provided the original work is properly cited and the use is non-commercial. See: <https://creativecommons.org/licenses/by-nc/4.0/>

Country/Territory of origin: Italy

ORCID number: Alessandro Fugazza 0000-0003-0485-4903; Kareem Khalaf 0000-0002-5534-7533; Matteo Colombo 0000-0003-0715-8233; Silvia Carrara 0000-0003-4206-9463; Marco Spadaccini 0000-0003-3909-9012; Edoardo Troncone 0000-0003-4520-6865; Roberta Maselli 0000000172919110; Alessandro Repici 0000-0002-1621-6450; Andrea Anderloni 0000-0002-1021-0031.

S-Editor: Gao CC

L-Editor: A

P-Editor: Gao CC

REFERENCES

- 1 **Simons-Linares CR**, Chahal P. Advances in Interventional Endoscopic Ultrasound (EUS): A Technical Review. *J Clin Gastroenterol* 2020; **54**: 579-590 [PMID: 32301834 DOI: 10.1097/MCG.0000000000001337]
- 2 **Di Leo M**, Crinò SF, Bernardoni L, Rahal D, Auriemma F, Correale L, Donato G, Massidda M, Anderloni A, Manfrin E, Armellini E, Poliani L, Fugazza A, Semeraro R, Occhipinti P, Repici A, Carrara S. EUS-guided core biopsies of pancreatic solid masses using a new fork-tip needle: A multicenter prospective study. *Dig Liver Dis* 2019; **51**: 1275-1280 [PMID: 31010744 DOI: 10.1016/j.dld.2019.03.025]
- 3 **Fugazza A**, Bizzarri B, Gaiani F, Manfredi M, Ghiselli A, Crafa P, Carra MC, de'Angelis N, de'Angelis GL. The role of endoscopic ultrasound in children with Pancreatobiliary and gastrointestinal disorders: a single center series and review of the literature. *BMC Pediatr* 2017; **17**: 203 [PMID: 29212476 DOI: 10.1186/s12887-017-0956-z]
- 4 **Tamanini G**, Cominardi A, Brighi N, Fusaroli P, Lisotti A. Endoscopic ultrasound assessment and tissue acquisition of mediastinal and abdominal lymph nodes. *World J Gastrointest Oncol* 2021; **13**: 1475-1491 [PMID: 34721779 DOI: 10.4251/wjgo.v13.i10.1475]
- 5 **Parsa N**, Nieto JM, Powers P, Mitsuhashi S, Abdelqader A, Hadzinakos G, Anderloni AA, Fugazza A, James TW, Arlt A, Ellrichmann M, Aparicio JR, Trindade AJ, Stevens TK, Chahal P, Shah SL, Messallam AA, Lang G, Fejleh MP, Benias PC, Sejpal DV, Jones J, Mir FF, Aghaie Meybodi M, Ichkhanian Y, Vosoughi K, Novikov AA, Irani SS, Pawa R, Ahmed AM, Sedarat A, Hsueh W, Hampe J, Sharaiha RZ, Berzin TM, Willingham FF, Kushnir VM, Brewer Gutierrez OI, Ngamruengphong S, Huggett MT, Baron TH, Repici A, Adler DG, Nasr JT, Kowalski TE, Kumbhari V, Singh VK, Khashab MA. Endoscopic ultrasound-guided drainage of pancreatic walled-off necrosis using 20-mm vs 15-mm lumen-apposing metal stents: an international, multicenter, case-matched study. *Endoscopy* 2020; **52**: 211-219 [PMID: 32000275 DOI: 10.1055/a-1096-3299]

- 6 **Fugazza A**, Colombo M, Repici A, Anderloni A. Endoscopic Ultrasound-Guided Gallbladder Drainage: Current Perspectives. *Clin Exp Gastroenterol* 2020; **13**: 193-201 [PMID: [32523368](#) DOI: [10.2147/CEG.S203626](#)]
- 7 **Fugazza A**, Fabbri C, Di Mitri R, Petrone MC, Colombo M, Cugia L, Amato A, Forti E, Binda C, Maida M, Sinagra E, Repici A, Tarantino I, Anderloni A; i-EUS Group. EUS-guided choledochoduodenostomy for malignant distal biliary obstruction after failed ERCP: a retrospective nationwide analysis. *Gastrointest Endosc* 2022; **95**: 896-904.e1 [PMID: [34995640](#) DOI: [10.1016/j.gie.2021.12.032](#)]
- 8 **Troncone E**, Fugazza A, Cappello A, Del Vecchio Blanco G, Monteleone G, Repici A, Teoh AYB, Anderloni A. Malignant gastric outlet obstruction: Which is the best therapeutic option? *World J Gastroenterol* 2020; **26**: 1847-1860 [PMID: [32390697](#) DOI: [10.3748/wjg.v26.i16.1847](#)]
- 9 **Mudireddy PR**, Sethi A, Siddiqui AA, Adler DG, Nieto J, Khara H, Trindade A, Ho S, Benias PC, Draganov PV, Yang D, Mok S, Confer B, Diehl DL. EUS-guided drainage of postsurgical fluid collections using lumen-apposing metal stents: a multicenter study. *Gastrointest Endosc* 2018; **87**: 1256-1262 [PMID: [28843581](#) DOI: [10.1016/j.gie.2017.08.011](#)]
- 10 **Tanisaka Y**, Mizuide M, Fujita A, Ogawa T, Suzuki M, Katsuda H, Saito Y, Miyaguchi K, Tashima T, Mashimo Y, Ryozaawa S. Recent Advances of Interventional Endoscopic Retrograde Cholangiopancreatography and Endoscopic Ultrasound for Patients with Surgically Altered Anatomy. *J Clin Med* 2021; **10** [PMID: [33921247](#) DOI: [10.3390/jcm10081624](#)]
- 11 **Fugazza A**, Anderloni A, Paduano D, Badalamenti M, Maselli R, Carrara S, Gabbiadini R, Colombo M, Spadaccini M, Cappello A, Haber G, Repici A. Underwater cap-assisted endoscopic retrograde cholangiopancreatography in patients with surgically altered anatomy: a pilot study. *Endoscopy* 2021; **53**: 927-931 [PMID: [33197940](#) DOI: [10.1055/a-1311-9779](#)]
- 12 **Anastasiou J**, Berzin TM. Endoscopic Ultrasound-Guided Vascular Interventions: From Diagnosis to Treatment. *Saudi J Med Sci* 2018; **6**: 61-67 [PMID: [30787823](#) DOI: [10.4103/sjmmms.sjmmms_131_17](#)]
- 13 **Pavic T**, Mikolasevic I, Kralj D, Blazevic N, Skrtic A, Budimir I, Lerotic I, Hrabar D. Role of Endoscopic Ultrasound in Liver Disease: Where Do We Stand? *Diagnostics (Basel)* 2021; **11** [PMID: [34829368](#) DOI: [10.3390/diagnostics11112021](#)]
- 14 **Fujii-Lau LL**, Law R, Wong Kee Song LM, Gostout CJ, Kamath PS, Levy MJ. Endoscopic ultrasound (EUS)-guided coil injection therapy of esophagogastric and ectopic varices. *Surg Endosc* 2016; **30**: 1396-1404 [PMID: [26139494](#) DOI: [10.1007/s00464-015-4342-3](#)]
- 15 **De Angelis CG**, Cortegoso Valdivia P, Rizza S, Venezia L, Rizzi F, Gesualdo M, Saracco GM, Pellicano R. Endoscopic Ultrasound-Guided Treatments for Non-Variceal Upper GI Bleeding: A Review of the Literature. *J Clin Med* 2020; **9** [PMID: [32245209](#) DOI: [10.3390/jcm9030866](#)]
- 16 **Bazarbashi AN**, Wang TJ, Jirapinyo P, Thompson CC, Ryou M. Endoscopic Ultrasound-Guided Coil Embolization With Absorbable Gelatin Sponge Appears Superior to Traditional Cyanoacrylate Injection for the Treatment of Gastric Varices. *Clin Transl Gastroenterol* 2020; **11**: e00175 [PMID: [32677809](#) DOI: [10.14309/ctg.000000000000175](#)]
- 17 **Lôbo MRA**, Chaves DM, DE Moura DTH, Ribeiro IB, Ikari E, DE Moura EGH. Safety and efficacy of EUS-guided coil plus cyanoacrylate versus conventional cyanoacrylate technique in the treatment of gastric varices: a randomized controlled trial. *Arq Gastroenterol* 2019; **56**: 99-105 [PMID: [31141079](#) DOI: [10.1590/S0004-2803.201900000-08](#)]
- 18 **Mohan BP**, Chandan S, Khan SR, Kassab LL, Trakroo S, Ponnada S, Asokkumar R, Adler DG. Efficacy and safety of endoscopic ultrasound-guided therapy vs direct endoscopic glue injection therapy for gastric varices: systematic review and meta-analysis. *Endoscopy* 2020; **52**: 259-267 [PMID: [32028533](#) DOI: [10.1055/a-1098-1817](#)]
- 19 **Westaby D**, Macdougall BR, Melia W, Theodossi A, Williams R. A prospective randomized study of two sclerotherapy techniques for esophageal varices. *Hepatology* 1983; **3**: 681-684 [PMID: [6352448](#) DOI: [10.1002/hep.1840030509](#)]
- 20 **Abby Philips C**, Sahney A. Oesophageal and gastric varices: historical aspects, classification and grading: everything in one place. *Gastroenterol Rep (Oxf)* 2016; **4**: 186-195 [PMID: [27324725](#) DOI: [10.1093/gastro/gow018](#)]
- 21 **Dagradi AE**, Stempien SJ, Owens LK. Bleeding esophagogastric varices. An endoscopic study of 50 cases. *Arch Surg* 1966; **92**: 944-947 [PMID: [5295832](#) DOI: [10.1001/archsurg.1966.01320240132029](#)]
- 22 **Sarin SK**, Lahoti D, Saxena SP, Murthy NS, Makwana UK. Prevalence, classification and natural history of gastric varices: a long-term follow-up study in 568 portal hypertension patients. *Hepatology* 1992; **16**: 1343-1349 [PMID: [1446890](#) DOI: [10.1002/hep.1840160607](#)]
- 23 **Jakab SS**, Garcia-Tsao G. Evaluation and Management of Esophageal and Gastric Varices in Patients with Cirrhosis. *Clin Liver Dis* 2020; **24**: 335-350 [PMID: [32620275](#) DOI: [10.1016/j.cld.2020.04.011](#)]
- 24 **Al-Khazraji A**, Curry MP. The current knowledge about the therapeutic use of endoscopic sclerotherapy and endoscopic tissue adhesives in variceal bleeding. *Expert Rev Gastroenterol Hepatol* 2019; **13**: 893-897 [PMID: [31389265](#) DOI: [10.1080/17474124.2019.1652092](#)]
- 25 **Van Stiegmann G**, Goff JS. Endoscopic esophageal varix ligation: preliminary clinical experience. *Gastrointest Endosc* 1988; **34**: 113-117 [PMID: [3259195](#) DOI: [10.1016/s0016-5107\(88\)71274-2](#)]
- 26 **Nagashima K**, Irisawa A, Tominaga K, Kashima K, Kunogi Y, Minaguchi T, Izawa N, Yamamiya A, Yamabe A, Hoshi K, Goda K, Iijima M. The Role of Endoscopic Ultrasound for Esophageal Varices. *Diagnostics (Basel)* 2020; **10** [PMID: [33255736](#) DOI: [10.3390/diagnostics10121007](#)]
- 27 **Mann R**, Goyal H, Perisetti A, Chandan S, Inamdar S, Tharian B. Endoscopic ultrasound-guided vascular interventions: Current insights and emerging techniques. *World J Gastroenterol* 2021; **27**: 6874-6887 [PMID: [34790012](#) DOI: [10.3748/wjg.v27.i40.6874](#)]
- 28 **Lahoti S**, Catalano MF, Alcocer E, Hogan WJ, Geenen JE. Obliteration of esophageal varices using EUS-guided sclerotherapy with color Doppler. *Gastrointest Endosc* 2000; **51**: 331-333 [PMID: [10699783](#) DOI: [10.1016/s0016-5107\(00\)70363-4](#)]
- 29 **Robles-Medrand C**, Oleas R, Del Valle R, Binmoeller KF. EUS-guided therapy of gastric varices (with video). *Endosc Ultrasound* 2020; **9**: 280-283 [PMID: [32913153](#) DOI: [10.4103/eus.eus_55_20](#)]
- 30 **Romero-Castro R**, Ellrichmann M, Ortiz-Moyano C, Subtil-Inigo JC, Junquera-Florez F, Gornals JB, Repiso-Ortega A, Vila-Costas J, Marcos-Sanchez F, Muñoz-Navas M, Romero-Gomez M, Brullet-Benedi E, Romero-Vazquez J, Caunedo-Alvarez A, Pellicer-Bautista F, Herrerias-Gutierrez JM, Fritscher-Ravens A. EUS-guided coil vs cyanoacrylate therapy for the treatment of gastric varices: a multicenter study (with videos). *Gastrointest Endosc* 2013; **78**: 711-721 [PMID: [23913153](#) DOI: [10.1016/j.gie.2013.05.011](#)]

- 23891417 DOI: [10.1016/j.gie.2013.05.009](https://doi.org/10.1016/j.gie.2013.05.009)]
- 31 **McCarty TR**, Bazarbashi AN, Hathorn KE, Thompson CC, Ryou M. Combination therapy *versus* monotherapy for EUS-guided management of gastric varices: A systematic review and meta-analysis. *Endosc Ultrasound* 2020; **9**: 6-15 [PMID: [31417066](https://pubmed.ncbi.nlm.nih.gov/31417066/) DOI: [10.4103/eus.eus_37_19](https://doi.org/10.4103/eus.eus_37_19)]
 - 32 **Thiruvengadam SS**, Sedarat A. The Role of Endoscopic Ultrasound (EUS) in the Management of Gastric Varices. *Curr Gastroenterol Rep* 2021; **23**: 1 [PMID: [33389241](https://pubmed.ncbi.nlm.nih.gov/33389241/) DOI: [10.1007/s11894-020-00801-2](https://doi.org/10.1007/s11894-020-00801-2)]
 - 33 **Kouanda A**, Binmoeller K, Hamerski C, Nett A, Bernabe J, Shah J, Bhat Y, Watson R. Safety and efficacy of EUS-guided coil and glue injection for the primary prophylaxis of gastric variceal hemorrhage. *Gastrointest Endosc* 2021; **94**: 291-296 [PMID: [33539908](https://pubmed.ncbi.nlm.nih.gov/33539908/) DOI: [10.1016/j.gie.2021.01.025](https://doi.org/10.1016/j.gie.2021.01.025)]
 - 34 **Robles-Medrand C**, Oleas R, Valero M, Puga-Tejada M, Baquerizo-Burgos J, Ospina J, Pitanga-Lukashok H. Endoscopic ultrasonography-guided deployment of embolization coils and cyanoacrylate injection in gastric varices *vs* coiling alone: a randomized trial. *Endoscopy* 2020; **52**: 268-275 [PMID: [32126576](https://pubmed.ncbi.nlm.nih.gov/32126576/) DOI: [10.1055/a-1123-9054](https://doi.org/10.1055/a-1123-9054)]
 - 35 **Bahdi F**, George R, Patel K. EUS-guided coiling and cyanoacrylate injection of ectopic duodenal varices. *VideoGIE* 2021; **6**: 35-37 [PMID: [33490754](https://pubmed.ncbi.nlm.nih.gov/33490754/) DOI: [10.1016/j.vgie.2020.09.007](https://doi.org/10.1016/j.vgie.2020.09.007)]
 - 36 **Bazarbashi AN**, Thompson CC, Ryou M. Targeting the perforator vein: EUS-guided coil embolization for the treatment of bleeding rectal varices. *VideoGIE* 2020; **5**: 434-436 [PMID: [32954109](https://pubmed.ncbi.nlm.nih.gov/32954109/) DOI: [10.1016/j.vgie.2020.05.008](https://doi.org/10.1016/j.vgie.2020.05.008)]
 - 37 **Rana SS**, Sharma R, Gupta R. Refractory rectal variceal bleeding treated with EUS-guided coil embolization. *Endosc Ultrasound* 2021; **10**: 141-142 [PMID: [33539904](https://pubmed.ncbi.nlm.nih.gov/33539904/) DOI: [10.4103/eus.eus_63_20](https://doi.org/10.4103/eus.eus_63_20)]
 - 38 **Rivera PA**, Dattilo JB. Pseudoaneurysm. Treasure Island (FL): StatPearls Publishing, 2022
 - 39 **Berceli SA**. Hepatic and splenic artery aneurysms. *Semin Vasc Surg* 2005; **18**: 196-201 [PMID: [16360576](https://pubmed.ncbi.nlm.nih.gov/16360576/) DOI: [10.1053/j.semvasc.surg.2005.09.005](https://doi.org/10.1053/j.semvasc.surg.2005.09.005)]
 - 40 **Cordova AC**, Sumpio BE. Visceral Artery Aneurysms and Pseudoaneurysms—Should They All be Managed by Endovascular Techniques? *Ann Vasc Dis* 2013; **6**: 687-693 [PMID: [24386016](https://pubmed.ncbi.nlm.nih.gov/24386016/) DOI: [10.3400/avd.ra.13-00045](https://doi.org/10.3400/avd.ra.13-00045)]
 - 41 **Rai P**, Kc H, Goel A, Aggarwal R, Sharma M. Endoscopic ultrasound-guided coil and glue for treatment of splenic artery pseudo-aneurysm: new kid on the block! *Endosc Int Open* 2018; **6**: E821-E825 [PMID: [29978000](https://pubmed.ncbi.nlm.nih.gov/29978000/) DOI: [10.1055/a-0608-4402](https://doi.org/10.1055/a-0608-4402)]
 - 42 **Rudnick SR**, Conway JD, Russo MW. Current state of endohepatology: Diagnosis and treatment of portal hypertension and its complications with endoscopic ultrasound. *World J Hepatol* 2021; **13**: 887-895 [PMID: [34552695](https://pubmed.ncbi.nlm.nih.gov/34552695/) DOI: [10.4254/wjh.v13.i8.887](https://doi.org/10.4254/wjh.v13.i8.887)]
 - 43 **Chapman CG**, Waxman I. EUS-guided portal vein sampling. *Endosc Ultrasound* 2018; **7**: 240-245 [PMID: [30117486](https://pubmed.ncbi.nlm.nih.gov/30117486/) DOI: [10.4103/eus.eus_28_18](https://doi.org/10.4103/eus.eus_28_18)]
 - 44 **Chapman CG**, Waxman I. EUS-Guided Portal Venous Sampling of Circulating Tumor Cells. *Curr Gastroenterol Rep* 2019; **21**: 68 [PMID: [31813055](https://pubmed.ncbi.nlm.nih.gov/31813055/) DOI: [10.1007/s11894-019-0733-2](https://doi.org/10.1007/s11894-019-0733-2)]
 - 45 **Groszmann R**, Vorobioff JD, Gao H. Measurement of portal pressure: when, how, and why to do it. *Clin Liver Dis* 2006; **10**: 499-512, viii [PMID: [17162225](https://pubmed.ncbi.nlm.nih.gov/17162225/) DOI: [10.1016/j.cld.2006.08.005](https://doi.org/10.1016/j.cld.2006.08.005)]
 - 46 **Zhang W**, Peng C, Zhang S, Huang S, Shen S, Xu G, Zhang F, Xiao J, Zhang M, Zhuge Y, Wang L, Zou X, Lv Y. EUS-guided portal pressure gradient measurement in patients with acute or subacute portal hypertension. *Gastrointest Endosc* 2021; **93**: 565-572 [PMID: [32615178](https://pubmed.ncbi.nlm.nih.gov/32615178/) DOI: [10.1016/j.gie.2020.06.065](https://doi.org/10.1016/j.gie.2020.06.065)]
 - 47 **Hajifathalian K**, Westerveld D, Kaplan A, Dawod E, Herr A, Ianelli M, Saggese A, Kumar S, Fortune BE, Sharaiha RZ. Simultaneous EUS-guided portosystemic pressure measurement and liver biopsy sampling correlate with clinically meaningful outcomes. *Gastrointest Endosc* 2022; **95**: 703-710 [PMID: [34890694](https://pubmed.ncbi.nlm.nih.gov/34890694/) DOI: [10.1016/j.gie.2021.11.037](https://doi.org/10.1016/j.gie.2021.11.037)]
 - 48 **Garg R**, Rustagi T. Endoscopic Ultrasound-guided Portal Venous Access: Diagnostic and Therapeutic Implications. *J Clin Gastroenterol* 2017; **51**: 677-682 [PMID: [28742731](https://pubmed.ncbi.nlm.nih.gov/28742731/) DOI: [10.1097/MCG.0000000000000897](https://doi.org/10.1097/MCG.0000000000000897)]
 - 49 **Loffroy R**, Favelier S, Chevallier O, Estivalet L, Genson PY, Pottecher P, Gehin S, Krausé D, Cercueil JP. Preoperative portal vein embolization in liver cancer: indications, techniques and outcomes. *Quant Imaging Med Surg* 2015; **5**: 730-739 [PMID: [26682142](https://pubmed.ncbi.nlm.nih.gov/26682142/) DOI: [10.3978/j.issn.2223-4292.2015.10.04](https://doi.org/10.3978/j.issn.2223-4292.2015.10.04)]
 - 50 **Armonis A**, Patch D, Burroughs A. Hepatic venous pressure measurement: an old test as a new prognostic marker in cirrhosis? *Hepatology* 1997; **25**: 245-248 [PMID: [8985299](https://pubmed.ncbi.nlm.nih.gov/8985299/) DOI: [10.1053/jhep.1997.v25.ajhep0250245](https://doi.org/10.1053/jhep.1997.v25.ajhep0250245)]
 - 51 **Lai L**, Poneros J, Santilli J, Brugge W. EUS-guided portal vein catheterization and pressure measurement in an animal model: a pilot study of feasibility. *Gastrointest Endosc* 2004; **59**: 280-283 [PMID: [14745408](https://pubmed.ncbi.nlm.nih.gov/14745408/) DOI: [10.1016/s0016-5107\(03\)02544-6](https://doi.org/10.1016/s0016-5107(03)02544-6)]
 - 52 **Giday SA**, Ko CW, Clarke JO, Shin EJ, Magno P, Jagannath SB, Buscaglia JM, Kantsevov SV. EUS-guided portal vein carbon dioxide angiography: a pilot study in a porcine model. *Gastrointest Endosc* 2007; **66**: 814-819 [PMID: [17905028](https://pubmed.ncbi.nlm.nih.gov/17905028/) DOI: [10.1016/j.gie.2007.05.056](https://doi.org/10.1016/j.gie.2007.05.056)]
 - 53 **Kayar Y**, Turkdogan KA, Baysal B, Unver N, Danalioglu A, Senturk H. EUS-guided FNA of a portal vein thrombus in hepatocellular carcinoma. *Pan Afr Med J* 2015; **21**: 86 [PMID: [26491529](https://pubmed.ncbi.nlm.nih.gov/26491529/) DOI: [10.11604/pamj.2015.21.86.6991](https://doi.org/10.11604/pamj.2015.21.86.6991)]
 - 54 **Gimeno Garcia AZ**, Aparicio JR, Barturen A, Moreno M, Nicolas-Perez D, Quintero E. Short article: Endoscopic ultrasound-guided fine-needle aspiration of portal vein thrombosis in patients with chronic liver disease and suspicion of hepatocellular carcinoma. *Eur J Gastroenterol Hepatol* 2018; **30**: 418-423 [PMID: [29420366](https://pubmed.ncbi.nlm.nih.gov/29420366/) DOI: [10.1097/MEG.0000000000001094](https://doi.org/10.1097/MEG.0000000000001094)]
 - 55 **Zhang WY**, Li ZS, Jin ZD. Endoscopic ultrasound-guided ethanol ablation therapy for tumors. *World J Gastroenterol* 2013; **19**: 3397-3403 [PMID: [23801831](https://pubmed.ncbi.nlm.nih.gov/23801831/) DOI: [10.3748/wjg.v19.i22.3397](https://doi.org/10.3748/wjg.v19.i22.3397)]
 - 56 **Moyer MT**, Maranki JL, DeWitt JM. EUS-Guided Pancreatic Cyst Ablation: a Clinical and Technical Review. *Curr Gastroenterol Rep* 2019; **21**: 19 [PMID: [31016391](https://pubmed.ncbi.nlm.nih.gov/31016391/) DOI: [10.1007/s11894-019-0686-5](https://doi.org/10.1007/s11894-019-0686-5)]
 - 57 **Faigel D**, Lake D, Landreth T, Kelman C, Marler R. Endoscopic ultrasonography-guided portal injection chemotherapy for hepatic metastases. *Endosc Ultrasound* 2014; **3**: S1 [PMID: [26425503](https://pubmed.ncbi.nlm.nih.gov/26425503/)]
 - 58 **Faigel DO**, Lake DF, Landreth TL, Kelman CC, Marler RJ. EUS-guided portal injection chemotherapy for treatment of hepatic metastases: feasibility in the acute porcine model. *Gastrointest Endosc* 2016; **83**: 444-446 [PMID: [26358330](https://pubmed.ncbi.nlm.nih.gov/26358330/) DOI: [10.1016/j.gie.2015.08.064](https://doi.org/10.1016/j.gie.2015.08.064)]

- 59 **Philips CA**, Ahamed R, Rajesh S, George T, Mohanan M, Augustine P. Beyond the scope and the glue: update on evaluation and management of gastric varices. *BMC Gastroenterol* 2020; **20**: 361 [PMID: [33126847](#) DOI: [10.1186/s12876-020-01513-7](#)]
- 60 **Yokoyama K**, Miyayama T, Uchida Y, Fukuda H, Yamauchi R, Tsuchiya N, Umeda K, Takata K, Tanaka T, Inomata S, Morihara D, Takeyama Y, Shakado S, Sakisaka S, Hirai F. Novel Endoscopic Therapy for Gastric Varices Using Direct Forward-Viewing Endoscopic Ultrasonography. *Case Rep Gastroenterol* 2021; **15**: 28-34 [PMID: [33613160](#) DOI: [10.1159/000510132](#)]
- 61 **Robb PM**, Yeaton P, Bishop T, Wessinger J. Endoscopic Ultrasound Guided Embolization of a Pancreatic Pseudoaneurysm. *Gastroenterology Res* 2012; **5**: 239-241 [PMID: [27785215](#) DOI: [10.4021/gr500w](#)]
- 62 **Gamanagatti S**, Thingujam U, Garg P, Nongthombam S, Dash NR. Endoscopic ultrasound guided thrombin injection of angiographically occult pancreatitis associated visceral artery pseudoaneurysms: Case series. *World J Gastrointest Endosc* 2015; **7**: 1107-1113 [PMID: [26421108](#) DOI: [10.4253/wjge.v7.i13.1107](#)]
- 63 **Jhajharia A**, Wanjari S, Ashdhir P, Sharma D, Pokharna R, Nijhawan S. Endoscopic ultrasound-guided thrombin injection for management of visceral artery pseudoaneurysm: A novel approach. *Indian J Gastroenterol* 2018; **37**: 271-275 [PMID: [29971689](#) DOI: [10.1007/s12664-018-0865-6](#)]
- 64 **Gunjan D**, Gamanagatti S, Garg P. Endoscopic ultrasonography-guided obliteration of a left inferior phrenic artery pseudoaneurysm in a patient with alcoholic chronic pancreatitis. *Endoscopy* 2018; **50**: 449-450 [PMID: [29351702](#) DOI: [10.1055/s-0043-124867](#)]
- 65 **Sharma M**, Somani P, Sunkara T, Prajapati R, Talele R. Endoscopic ultrasound-guided coil embolization and thrombin injection of a bleeding gastroduodenal artery pseudoaneurysm. *Endoscopy* 2019; **51**: E36-E37 [PMID: [30537784](#) DOI: [10.1055/a-0790-8134](#)]
- 66 **Buscaglia JM**, Shin EJ, Clarke JO, Giday SA, Ko CW, Thuluvath PJ, Magno P, Dray X, Kantsevoy SV. Endoscopic retrograde cholangiopancreatography, but not esophagogastroduodenoscopy or colonoscopy, significantly increases portal venous pressure: direct portal pressure measurements through endoscopic ultrasound-guided cannulation. *Endoscopy* 2008; **40**: 670-674 [PMID: [18561105](#) DOI: [10.1055/s-2008-1077341](#)]
- 67 **Huang JY**, Samarasena JB, Tsujino T, Chang KJ. EUS-guided portal pressure gradient measurement with a novel 25-gauge needle device vs standard transjugular approach: a comparison animal study. *Gastrointest Endosc* 2016; **84**: 358-362 [PMID: [26945557](#) DOI: [10.1016/j.gie.2016.02.032](#)]
- 68 **Schulman AR**, Thompson CC, Ryou M. EUS-guided portal pressure measurement using a digital pressure wire with real-time remote display: a novel, minimally invasive technique for direct measurement in an animal model. *Gastrointest Endosc* 2016; **83**: 817-820 [PMID: [26684600](#) DOI: [10.1016/j.gie.2015.11.038](#)]
- 69 **Huang JY**, Samarasena JB, Tsujino T, Lee J, Hu KQ, McLaren CE, Chen WP, Chang KJ. EUS-guided portal pressure gradient measurement with a simple novel device: a human pilot study. *Gastrointest Endosc* 2017; **85**: 996-1001 [PMID: [27693644](#) DOI: [10.1016/j.gie.2016.09.026](#)]
- 70 **Rustagi T**, Gleeson FC, Chari ST, Abu Dayyeh BK, Farnell MB, Iyer PG, Kendrick ML, Pearson RK, Petersen BT, Rajan E, Topazian MD, Truty MJ, Vege SS, Wang KK, Levy MJ. Remote malignant intravascular thrombi: EUS-guided FNA diagnosis and impact on cancer staging. *Gastrointest Endosc* 2017; **86**: 150-155 [PMID: [27773725](#) DOI: [10.1016/j.gie.2016.10.025](#)]
- 71 **Moreno M**, Gimeno-García AZ, Corriente MM, Nicolás-Pérez D, Brito-García A, García-Castro C, Quintero E. EUS-FNA of a portal vein thrombosis in a patient with a hidden hepatocellular carcinoma: confirmation technique after contrast-enhanced ultrasound. *Endoscopy* 2014; **46** Suppl 1 UCTN: E590-E591 [PMID: [25502254](#) DOI: [10.1055/s-0034-1390734](#)]
- 72 **Michael H**, Lenza C, Gupta M, Katz DS. Endoscopic Ultrasound -guided Fine-Needle Aspiration of a Portal Vein Thrombus to Aid in the Diagnosis and Staging of Hepatocellular Carcinoma. *Gastroenterol Hepatol (N Y)* 2011; **7**: 124-129 [PMID: [21475421](#)]



Published by **Baishideng Publishing Group Inc**
7041 Koll Center Parkway, Suite 160, Pleasanton, CA 94566, USA

Telephone: +1-925-3991568

E-mail: bpgoffice@wjgnet.com

Help Desk: <https://www.f6publishing.com/helpdesk>

<https://www.wjgnet.com>

