

What is Essential is (No More) Invisible to the Eyes: The Introduction of BlocDoc in the Digital Pathology Workflow

Vincenzo L'Imperio¹, Fabio Gibilisco², Filippo Fraggetta³

¹Department of Medicine and Surgery, Pathology, ASST Monza, University of Milano-Bicocca, Monza, Italy, ²Department of Medical and Surgical Sciences and Advanced Technologies, "G.F. Ingrassia", Anatomic Pathology, University of Catania, Catania, Italy, ³Department of Pathology, "Gravina" Hospital, Caltagirone, Italy

Submitted: 25-May-2021

Revised: 07-Jul-2021

Accepted: 13-Jul-2021

Published: 16-Sep-2021

Abstract

Background: The implementation of a fully digital workflow in any anatomic pathology department requires a complete conversion to a tracked system. Ensuring the strict correspondence of the material submitted for the analysis, from the accessioning to the reporting phase, is mandatory in the anatomic pathology laboratory, especially when implementing the digital pathology for primary histological diagnosis. The proposed solutions, up to now, rely on the verification that all the materials present in the glass slide are also present in the whole slide images (WSIs). Although different methods have already been implemented for this purpose (e.g., the "macroimage" of the digital slide, representing the overview of the glass slide), the recent introduction of a device to capture the cut surface of paraffin blocks put the quality control of the digital workflow a step forward, allowing to match the digitized slide with the corresponding block. This system may represent a reliable, easy-to-use alternative to further reduce tissue inconsistencies between material sent to the lab and the final glass slides or WSIs. **Methods:** The Anatomic Pathology of the Gravina Hospital in Caltagirone, Sicily, Italy, has implemented the application of the BlocDoc devices (SPOT Imaging, Sterling Heights, USA) in its digital workflow. The instruments were positioned next to every microtome/sectioning station, with the possibility to capture the "normal" and the polarized image of the cut surface of the blocks directly by the technician. The presence of a monitor in the BlocDoc device allowed the technician to check the concordance between the cut surface of the block and the material on the corresponding slide. The link between BlocDoc and the laboratory information system, through the presence of the 2D barcode, allowed the pathologists to access the captured image of the cut surface of the block at the pathologist workstation, thus enabling the direct comparison between this image and the WSI (thumbnail and "macroimage"). **Results:** During the implementation period, more than 10.000 (11.248) blocks were routinely captured using the BlocDoc. The employment of this approach allowed a drastic reduction of the discordances and tissue inconsistencies. The implementation of the BlocDoc in the routine allowed the detection of two different types of "errors," the so-called "systematic" and "occasional" ones. The first type was intrinsic of some specific specimens (e.g., transurethral resection of the prostate, nasal polypectomies, and piecemeal uterine myomectomies) characterized by the three-dimensional nature of the fragments and affected almost 100% of these samples. On the other hand, the "occasional" errors, mainly due to inexperience or extreme caution of the technicians in handling tiny specimens, affected 98 blocks (0.9%) of these samples and progressively reduced with the rising confidence with the BlocDoc. One of these cases was clinically relevant. No problems in the recognition of the 2D barcodes were encountered using a laser cassette printer. Finally, rare failures have been recorded during the period, accounting for <0.1% of all the cases, mainly due to network connection issues. **Conclusions:** The implementation of BlocDoc can further improve the effectiveness of the digital workflow, demonstrating its safety and robustness as a valid alternative to the traditional, nontracked analogic workflow.

Keywords: BlocDoc, digital pathology, macroimage, paraffin block, quality control, whole slide image

INTRODUCTION

The digitization of the physical glass slides in a whole slide image (WSI) is just one of the steps required for the transition toward a digital pathology workflow.^[1] For a complete conversion of the anatomic pathology laboratory activity to an automated, digital working process, the implementation of an

Address for correspondence: Dr. Filippo Fraggetta,
Pathology Unit, Via Portosalvo, 1, 95041, Caltagirone, Italy.
E-mail: filippofra@hotmail.com

This is an open access journal, and articles are distributed under the terms of the Creative Commons Attribution-NonCommercial-ShareAlike 4.0 License, which allows others to remix, tweak, and build upon the work non-commercially, as long as appropriate credit is given and the new creations are licensed under the identical terms.

For reprints contact: WKHLRPMedknow_reprints@wolterskluwer.com

How to cite this article: L'Imperio V, Gibilisco F, Fraggetta F. What is essential is (no more) invisible to the eyes: The introduction of blocdoc in the digital pathology workflow. *J Pathol Inform* 2021;12:32.

Available FREE in open access from: <http://www.jpathinformatics.org/text.asp?2021/12/1/32/326167>

Access this article online

Quick Response Code:



Website:
www.jpathinformatics.org

DOI:
10.4103/jpi.jpi_35_21

adequate tracking system (e.g., through the employment of 2D barcodes)^[2] is mandatory. In a final glassless workflow, the 2D barcode implementation is a prerequisite for a correct scanning and matching of the WSI to a case and automatic delivery of the WSIs to the pathologists. This model is characterized by the introduction of different checkpoints and quality control (QC) steps to ensure the adequacy of the final results (e.g. WSI), allowing the integration of each phase in a smooth process. This would lead to the drastic reduction of potential issues that can impair the final fidelity of the WSI, finally resulting in potential tissue inconsistencies if not adequately controlled. One of these crucial steps consists in the evaluation of the appropriate correspondence among the material submitted for the analysis. Indeed, one of the basic requirements in the employment of WSI in the primary diagnostic setting is represented by the high fidelity of these digital reproductions as compared to the original glass slides. In this setting, one of the possible issues encountered during the scanning phase is represented by the possible skipping of small as well as barely stained tissue fragments that could lead to a lack of correspondence among the physical and digital slides obtained. Quality assurance programs as well as the employment of the “macroimage” during the sign-out phase could address this issue, giving the possibility to every pathologist to compare the available material on the WSI with the entire specimen sent for scanning.^[3] However, even with the implementation of the “macroimage,” some cases can still suffer from material inconsistencies and omissions, with obvious diagnostic repercussions in the routine.

Here is proposed a possible solution for this unsolved issue, by the introduction of a specific device (BlocDoc) in the routine workflow of a fully digital anatomic pathology laboratory in Sicily, Italy.

METHODS

The “Gravina” Hospital represents the Pathology Laboratory Hub of the Azienda Sanitaria Provinciale of Catania in Sicily (South of Italy), collecting specimens (mainly surgical and bioptic samples) from seven different hospitals distributed along the Catania area. Starting from the previous experience of one of the authors (FF),^[4] the anatomic pathology laboratory of this hospital dramatically changed its workflow to convert the entire activity to the digital pathology paradigm. Following the introduction of different basic requirements for such a transition (e.g., 2D barcodes, dedicated network, integrated laboratory information system [LIS]), a specific instrument for the capture of the cut surface of tissue blocks, namely, BlocDoc (SPOT Imaging, Sterling Heights, USA) has been added to every sectioning station, next to the microtomes [Figure 1a]. This choice allowed the insertion of this device in the routine activity of the sectioning technicians, without a significant impact on their habits or time waste. In this laboratory, cassettes are routinely produced with a printed 2D barcode through the employment of either laser system (Fa-Tech NOVA laser printer, Fa-Tech Diagnostic Europe, Duiven, The Netherlands) or a thermal transfer (Signature Cassette Printer,

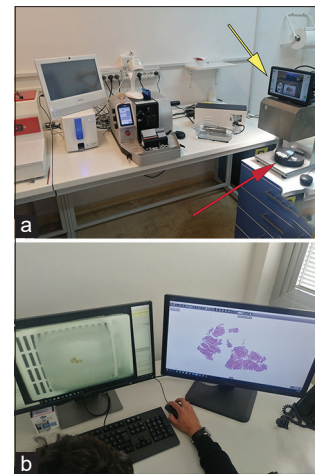


Figure 1: The BlocDoc instrument can be installed directly in the sectioning station, next to the microtome, allowing the position of the tissue block (red arrow) and the rapid visualization of the cut surface (yellow arrow) in real time by the technician (a). During the sign-out phase, the pathologist is able to access the obtained picture of the block surface directly from the case, checking whether all the materials (especially small fragments) on the block have been reported on the final whole slide images (b). WSI: Whole slide images

Primera Technology Inc., Plymouth, MN, United States). After cutting the block and collecting the sections on the glass slide, the tissue block is routinely positioned in the dedicated space of the BlocDoc [Figure 1a, red arrow], on the right side of the technician station, who can then start sectioning the subsequent block. Meanwhile, the device scans both the 2D barcode and the cut surface of the block, showing a preview on the dedicated screen [Figure 1a, yellow arrow]. This allows the technician to check whether the material on the block appeared in its entirety on the glass slide as well as the adequacy of the cut surface picture. The system acquires at the same time both “regular” and “polarized” images in a double layer. TIFF file, which can lead to a further increase in the detection of tissue inconsistencies as compared to the “eye check.” If the final result is adequate and the check is done, the surface scan is approved, and the technician can continue his sectioning activity. The obtained image is directly linked to the case page through a full integration with the LIS (Pathox, version 13.22.0, Tesi Elettronica e Sistemi Informativi S.P.A., Milan, Italy) using the implemented tracking system based on 2D barcodes. By matching the image (the double TIFF layer) of the cut surface of the block with the barcode, the pathologist, at his workstation, can easily access the saved images integrated within the LIS.

To assess the impact of the BlocDoc introduction in the reduction of tissue inconsistencies and possible diagnostic issues, the following evaluations have been made:

1. How frequently tissue was present in the block but not on the glass slide and on the WSI
2. Of those samples, how frequently was the unsampled tissue recognized manually by the technician and corrected without the use of the BlocDoc
3. How frequently was the unsampled tissue missed by

manual inspection but displayed by the BlocDoc and then recognized by the technician

- How frequently the detection of that missed tissue resulted in the avoidance of a possible diagnostic error.

RESULTS

Since its introduction at the end of 2020, the BlocDoc routinely digitized more than 10.000 (11.248) cut surfaces of paraffin blocks.

The complete procedure of scanning the 2D barcode of the block and the acquisition of the two level images, including their saving, took about 4 s on average and did not affect the usual workflow of the technician at the cutting station. No failure in the recognition of the 2D barcode was reported in the subset of cases ($n = 9134$) printed with the laser system, while 6 out of 2114 cases (0.3%) obtained with the thermal transfer experienced a failure in this step. The possibility to insert the code manually solved the error in this subset of cases.

The scanning of the block was not affected by the use of different waxes or by the presence of the ink used for highlighting the margins of the specimen. The integration with the LIS using the barcode allowed to allocate the image within the corresponding case. This gives the access to the cut surface of the block even for the pathologists directly from the case page in the LIS [Figure 1b]. Moreover, thanks to the employment of two monitors in each workstation, the contemporary visualization of the block surface, the “macroimage” of the case and the WSI allowed a direct inspection of eventual material inconsistencies, moving the QC checkpoint from the “macroimage” of the WSI (corresponding to the material present in the glass slide) to the tissue present in the block.

The retrospective review of the possible errors detected thanks to the BlocDoc employment demonstrated that almost all the samples were affected, at least in a minimal part, by tissue inconsistencies among the block surface and the obtained glass slide/WSI. However, a more careful analysis allowed the distinction between two different types of issues, the so-called “systematic” and “occasional” errors. The first category encompasses the discrepancies that can be highlighted in samples characterized by multiple large fragments of tissue, such as in the case of transurethral resection of the prostate, nasal polypectomies, and piecemeal uterine myomectomies. Indeed, due to their intrinsic three-dimensional nature, these specimens are more prone to material discrepancies among block and glass slide/WSI, as demonstrated by the anecdotal case reported in Figure 2a. For these reasons, the “systematic” error affected almost the entire set of these specimens (100%), promptly detected by the employment of the BlocDoc. Of these, roughly half (50%) would have been detected by the manual inspection of the block surface by the technician without the need to check the captured image obtained from the BlocDoc. However, this would result in a

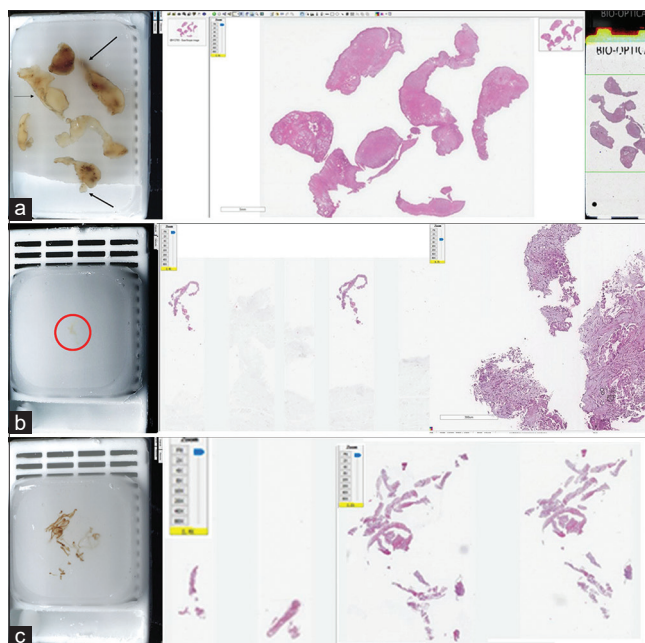


Figure 2: Examples of the different types of inconsistencies detected thanks to the employment of BlocDoc. (a) the typical “systematic” error characterized by the incomplete sectioning of numerous, large, three-dimensional tissue fragments are demonstrated by the comparison of the original block (left, arrows) with the WSI (center) and the “macroimage” (right). (b) On the other hand, the so-called “occasional” error can be typically encountered with small fragments/biopsies, which can be barely visible by naked eye on the block (left, red circle), although the inspection by the pathologist can lead to order further diagnostic stainings, as demonstrated by the appearance of an adenocarcinoma in the WSI (right). (c) This can happen with small multiple biopsies as well, in which the multiple sections ordered by the pathologist can reveal additional tissue (center before the BlocDoc picture inspection, right after the inspection). WSI: Whole slide images

time-consuming process that would not lead to the detection of all the systematic errors in this series. Among these blocks (belonging to the “systematic” errors), 20 were recut in order to verify the potential clinical impact. However, no major differences were found between the first and the deeper cuts. On the other hand, the “occasional” type of errors are more related to the inexperience and extreme caution of the technicians in handling tiny specimens [Figure 2b and c], accounting for 98 out of 11.248 blocks, thus representing 0.9% of the cases. As compared to the “systematic” errors, these types of tissue inconsistencies were almost never detected (<0.1% of cases) by the manual inspection performed by the sectioning technician, with a progressive slight decrease of the error rate with the rising confidence in the use of BlocDoc. Moreover, thanks to the possibility to visualize the polarized cut surface of the tissue block, some slight discrepancies can be further detected, increasing the error detection rate of this instrument [Figure 3]. As compared to the “systematic” errors that never resulted in a potential diagnostic issue, the “occasional” ones were related (in 1 case) to a clinically relevant issue [no tissue vs. adenocarcinoma

after recut, Figure 2b]. Since they were more susceptible to be overlooked by the manual inspection of the technician, in this setting, the BlocDoc demonstrated the most relevant impact in the routine workflow. Finally, some rare failures in the image acquisition and attachment to the case in the LIS have been recorded since the beginning of the BlocDoc employment, although these issues accounted for <0.1% of all the cases and were mainly due to internet connection problems.

DISCUSSION

The digital pathology revolution is progressively being adopted by different pathology centers, although relatively few laboratories are already fully converted for the primary diagnosis worldwide.^[1,5,6] Different guidelines have been produced to manage this transition in a step-by-step fashion,^[7,8] mainly focused on the validation of WSI. The different recommendations underlined the importance of assuring that all the materials present in the glass slide are also present in the WSI.^[8] It is well known that more or less all the scanners present in the market can sometime fail to include all the tissues in the WSI,^[3,8] and it has been suggested to refer to the “macroimage” for the final checking, since manual (human) verification may not be efficient enough in avoiding potential clinically relevant errors. In the present report, we demonstrated that the use of a new device matching the cut surface of the block with the WSI (either thumbnail or “macroimage”) can represent a step forward for the safe implementation of a digital workflow. This device can highlight missing material that can be overlooked (although rarely) even by the human check of the technician. In their step-by-step analysis of the possible key steps that can impact on the digital transformation of the lab, Dash *et al.* have recently discussed the delicate role of the WSI as accurate reproductions of the original glass slides, especially in the

implementation of digital pathology for primary diagnosis purposes.^[9] As explained by the authors, physical glass slides are generated by sectioning the paraffin block and “classic” QC checks generally consist in the case-by-case comparison of the obtained tissue section with the cut surface of the block. Although this is a consolidated practice in every pathology laboratory, it represents a time-consuming task for both pathologists and technicians, with extremely low compliance and as a consequence, a still elevated risk of tissue inconsistencies in the analogical/traditional workflow. In an automated workflow, this practice should be carried out without physically retrieving the paraffin blocks from the archive every time it is needed, with the possibility to systematically capture and catalog the cut surface of the tissue block for later comparison to the microscopic (or digital) image. Moreover, according to the authors,^[9] this important (and today, entirely manual) QC check remains a gap in the market today. However, the recent introduction of BlocDoc drastically changed the routine practice of an already digital-oriented laboratory in Sicily, Italy,^[4] with more than 10.000 block surfaces captured and different potential material discrepancies detected. The technology employed by the instrument allows the detection of rough discrepancies even by the technicians during the sectioning phase, as well as subtle and slight differences that would not otherwise be detected by the pathologists from the mere WSI analysis. Moreover, the possibility to visualize the polarized cut surface of the blocks can further increase the error detection rate, highlighting even barely perceptible discrepancies, as in the case of more transparent tissues such as adipose tissue or cell blocks. As a further application, the instrument can even allow the measurement of excess or lack of cutting of the block surface by comparing the pictures of the block before and after the sectioning process. In the Caltagirone Laboratory, we are also testing other different uses of this instrument: at the accessioning it could be used to acquire in and out blocks for consultation reasons, thus documenting all the materials received or sent. The instrument can also be used at the grossing station to acquire a picture of the material put in the block for the processing. Thanks to the recognition of the 2D barcode, the acquired image can be used and retrieved at the embedding step by the technician, further expanding the availability of archived step-by-step images in a fully digital workflow. The possibility to access all these pictures potentially increases the quality and safety of the pathology workflow, highlighting how safe the conversion to a digital laboratory is. Finally, it can represent a possible solution for the contamination problem, especially for those deriving from the subsequent phases, representing a reliable repository for the comparison of the final WSI product [Figure 4].

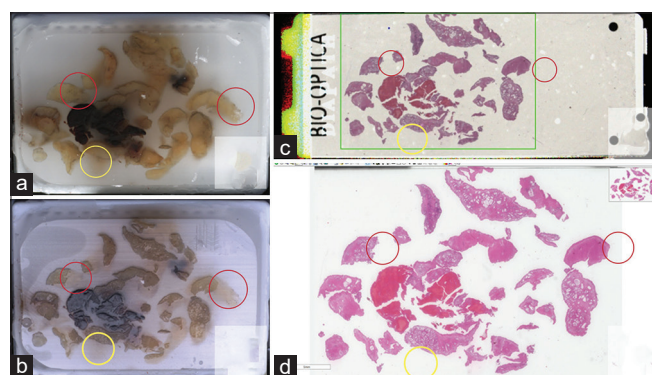


Figure 3: The possibility to visualize the polarized cut surface of the block allows to detect further inconsistencies that are not readily visible through the “standard” block image. In the case depicted, some discrepancies are visible through the comparison of the classic cut surface picture (a) and the “macroimage” (c) or WSI (d), as in the case reported in the yellow circle. On the other hand, some discordances can only be suspected on the “standard” cut surface picture, being much more evident using the same image under polarized light (b), as demonstrated by the details in the red circles. WSI: Whole slide images

CONCLUSIONS

The introduction of BlocDoc represents a further, crucial technical advancement, allowing us to progressively obtain a secure and fully digital alternative to the old, nontracked,

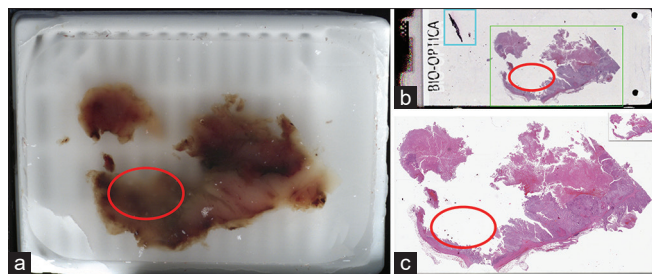


Figure 4: Possible application of the BlocDoc to detect contamination problems. In the exemplificative case, the cut surface picture of the tissue block (a) demonstrates the presence of a “systematic” error due to the incomplete sectioning of a portion of the sample (red circle), as demonstrated by the “macroimage” (b) and WSI (c). Moreover, the one of the fragments in the upper left corner of the “macroimage” (blue square), which has been discarded during the scanning process of the WSI, is completely absent in the picture obtained with the BlocDoc, suggesting the contaminant nature of this tissue, probably picked up erroneously during the sectioning phase. WSI: Whole slide images

routine pathology practice, and what is essential could be no more invisible to the eye.

Financial support and sponsorship

Nil.

Conflicts of interest

Fraggetta F is one of the inventors of “Sample imaging and

imagery archiving for imagery comparison Merlo PT *et al.* US patent 16/688/613 2020.”

REFERENCES

1. Fraggetta F, Pantanowitz L. Going fully digital: Utopia or reality? *Pathologica* 2018;110:1-2.
2. Hanna MG, Pantanowitz L. Bar coding and tracking in pathology. *Surg Pathol Clin* 2015;8:123-35.
3. Fraggetta F, Yagi Y, Garcia-Rojo M, Evans AJ, Tuthill JM, Baidoshvili A, *et al.* The importance of eSlide macro images for primary diagnosis with whole slide imaging. *J Pathol Inform* 2018;9:46.
4. Fraggetta F, Garozzo S, Zannoni GF, Pantanowitz L, Rossi ED. Routine digital pathology workflow: The Catania experience. *J Pathol Inform* 2017;8:51.
5. Thorstenson S, Molin J, Lundström C. Implementation of large-scale routine diagnostics using whole slide imaging in Sweden: Digital pathology experiences 2006-2013. *J Pathol Inform* 2014;5:14.
6. Stathonikos N, Veta M, Huisman A, van Diest PJ. Going fully digital: Perspective of a Dutch academic pathology lab. *J Pathol Inform* 2013;4:15.
7. Chong Y, Kim DC, Jung CK, Kim DC, Song SY, Joo HJ, *et al.* Medical informatics study group of the Korean society of pathologists. Recommendations for pathologic practice using digital pathology: Consensus report of the Korean Society of Pathologists. *J Pathol Transl Med* 2020;54:437-52.
8. Evans AJ, Brown RW, Bui MM, Chlipala EA, Lacchetti C, Milner DA, *et al.* Validating whole slide imaging systems for diagnostic purposes in pathology: Guideline Update from the College of American Pathologists in Collaboration with the American Society for Clinical Pathology and the Association for Pathology Informatics. *Arch Pathol Lab Med.* 2021 May 18. doi: 10.5858/arpa.2020-0723-CP. Epub ahead of print. PMID: 34003251.
9. Dash RC, Jones N, Merrick R, Haroske G, Harrison J, Sayers C, *et al.* Integrating the health-care enterprise pathology and laboratory medicine guideline for digital pathology interoperability. *J Pathol Inform* 2021;12:16.