

Evaluation of limbal transplantation in eyes with bilateral severe ocular surface damage secondary to chemical injury

This article was published in the following Dove Medical Press journal:
Clinical Ophthalmology

Abdel Hamid El-Hofi
Hany Ahmed Helaly

Department of Ophthalmology,
Faculty of Medicine, Alexandria
University, Alexandria, Egypt

Purpose: To evaluate the outcome of limbal transplantation in eyes with bilateral severe ocular surface damage secondary to chemical injury.

Patients and methods: This was a retrospective case series that included 20 patients who had undergone living related limbal transplantation due to the presence of bilateral severe stem cell deficiency resulting from chemical injury. Medical records of the selected patients were reviewed. The following data were recorded and analyzed: gender; age at the time of the surgery; duration of follow-up; corrected distance visual acuity (CDVA); symptoms; intraocular pressure (IOP); any complications; postoperative treatment; and other surgical procedures needed.

Results: The mean age of the included patients was 27.4 ± 9.3 years. The causative agent was an alkali in 14 patients. Fifteen patients (75%) had a stable ocular surface (ie, complete corneal re-epithelization and resolution of postoperative inflammation) after the first limbal transplantation, while the other five patients (25%) needed re-grafting. As regards the IOP; five patients (25%) needed Ahmed's valve implantation to control the IOP. Other surgical procedures needed were penetrating keratoplasty (PKP) in three patients (15%), cataract surgery in six patients (30%), and lid surgery in one patient (5%).

Conclusion: In conclusion, living related conjunctival limbal allograft transplantation, especially when combined with amniotic membrane transplantation, yielded good results in the management of cases with bilateral severe chemical eye injuries.

Keywords: living related, limbal stem cells, transplantation, chemical injury

Introduction

Limbal stem cells of the corneal epithelium, as their name denotes, are located at the corneoscleral limbus. They are important for maintaining a healthy clear corneal surface.^{1,2} Their damage or loss results in "limbal stem cell deficiency", which can be partial or complete, and can be documented by impression cytologic examination.³⁻⁵ The first classification of ocular surface damage was introduced by Ballen⁶ in 1964, which was modified by Roper-Hall⁷ in 1965. This classification provided prognostic guidelines based on two factors; the degree of limbal ischemia and the corneal appearance. Dua et al⁸ introduced a new classification of ocular surface burns based on the extent of limbal involvement in hours and the percentage of conjunctival involvement.

Limbal stem deficiency can be primary, eg, aniridia, or secondary, which is more common, eg, chemical or thermal injuries, Stevens-Johnson Syndrome, ocular cicatricial pemphigoid (OCP), multiple surgeries or cryotherapies, contact lens wear, or severe microbial infections.^{9-12,33} Signs of severe limbal stem cell deficiency include

Correspondence: Hany Ahmed Helaly
Faculty of Medicine, Alexandria
University, Kartoum Square,
Alexandria, Egypt
Tel +2 122 546 6733
Email hany209209@yahoo.com

conjunctival epithelial ingrowth (subconjunctivization), neo-vascularization, chronic inflammation, and recurrent or persistent corneal epithelial defects.^{13–16}

Limbal stem cell auto- or allo-transplantation is indicated for ocular surface reconstruction in cases of severe limbal stem cell deficiency. This procedure transplants a new source of epithelium for the affected ocular surface, together with the removal of damaged corneal epithelium and pannus.¹⁷ The source of limbal transplantation can be “limbal autograft”, which is harvested from the other eye in the case of unilateral disease, or “limbal allograft” in the case of bilateral disease. Limbal allograft can be harvested from a cadaver donor or from a living related donor, who usually gives a better tissue match.^{18–20} A successful limbal transplantation results in regression of corneal vascularization, restoring a smooth ocular surface with improved optical quality, and rapid ocular surface healing with no recurrent erosions or persistent epithelial defects. Amniotic membrane transplantation (AMT) was also used in association with limbal transplantation in cases with total stem cell deficiency.^{21–23,29,30}

The aim of the current study was to evaluate the outcome of living related conjunctival limbal allograft (lr-CLAL) transplantation in eyes with bilateral severe ocular surface damage secondary to chemical injury.

Patients and methods

This was a retrospective interventional non-comparative case series that included 20 patients who had undergone living related limbal transplantation due to the presence of bilateral severe stem cell deficiency resulting from chemical injury. The donor was best human leukocyte antigen (HLA) matched available relative (one of the parents was preferred or else a sibling). The HLA system is a gene complex encoding the major histocompatibility complex (MHC) proteins in humans. Included patients had corrected distance visual acuity (CDVA) one logMAR or worse, age ≥ 18 years, bilateral severe old chemical eye injury that resulted in limbal stem cell deficiency (LSCD) with a Dua grading⁸ not less than IV during the acute phase of the old chemical injury, and at least 6 hours extent of ocular surface damage (ie, abnormal corneal epithelium and/or superficial corneal vascularization). Patients with systemic autoimmune disorders, incomplete data in their records, or associated ocular injuries were excluded.

Donor graft preparation and placement

Two donor grafts were harvested, each with a 4-hour size, to be transplanted to two opposite quadrants of the recipient ocular surface. The preparation of the recipient bed included conjunctival peritomy at the limbus to expose the adjacent

scleral area where the donor tissue will be placed, then the perilimbal subconjunctival scarred and inflamed tissues were removed up to 5–6 mm from the limbus, and then the abnormal corneal epithelium and superficial vascularized scar were removed by blunt dissection. The bed size was 4 (clock) hours to match the donor graft size. The donor graft is then placed in position and sutured by interrupted 10/0 nylon sutures. The donor site was left open to heal with no sutures. For both donors and patients, postoperative topical antibiotics (0.3% Moxifloxacin) and topical steroids (1% Prednisolone acetate) were given together with preservative free lubricant eye drops until complete re-epithelization and resolution of postoperative inflammation. Patients were referred to an internal medicine specialist to prescribe a 6–12 months course of systemic immunosuppressive drugs followed by a lower maintenance dose during the whole period of follow-up. The oral immunosuppressive drugs were in the form of oral corticosteroids 1 mg/kg in divided doses then tapered gradually and oral cyclosporin A (10 mg/kg in divided doses then tapered to 3–5 mg/kg as a maintenance dose). The patients were counseled about the use and adverse effects of systemic immunotherapy. Complete hematologic and liver profile assessment were investigated by the internal medicine specialist. Patients were followed up by the internal medicine specialist in a regular way to ensure compliance and to manage adverse effects if any.

Amniotic membrane preparation

Amniotic membrane is a thick basement membrane and avascular stromal matrix. It is helpful for a successful grafting as it aids the migration of the epithelial cells, reinforces the adhesions of the basal epithelial cells, and promotes epithelial differentiation. It was obtained after a cesarean section delivery from a lady who was previously tested for infectious diseases such as hepatitis, syphilis, and human immunodeficiency virus (HIV). The placenta is then washed with sterile phosphate buffered saline solution containing penicillin G 50 mg/mL, streptomycin 50 mg/mL, neomycin 100 mg/mL, and amphotericin B 2.5 mg/mL. This is followed by separation of the amnion by blunt dissection. The amnion is then put onto cellulose paper, with the side of the basement membrane up. The cellulose paper is divided into small sheets, which can be stored before grafting at -800°C in a sterile vial containing Dulbecco's Modified Eagle's Medium and glycol. AMT was performed in a similar way to limbal transplantation. Preparation of the recipient bed included same steps mentioned above including peritomy, perilimbal conjunctival excision, and superficial keratectomy. This was followed by applying the preserved amniotic membrane to the ocular surface defect

with basement membrane side up. The amniotic membrane was sutured by 10/0 nylon sutures and covered by a bandage contact lens. AMT was performed at least once for all the cases before limbal transplantation at around 2–4 months to minimize the inflammation and to reduce scarring and neovascularization. It also helped to prepare the ocular surface for limbal transplantation if symblepharon was present and needed release in a step before the limbal transplantation. Sometimes, it was repeated two or three times if its effect was not enough after the first AMT (eg, cases with extensive inflammation, scarring, or neovascularization) or in cases of delayed re-epithelization after limbal transplantation.^{29,30}

All the surgeries were performed by the same surgeon (A.E.). The study was approved by the local ethics committee at the Faculty of Medicine, Alexandria University, Egypt. Tenets of the Declaration of Helsinki were followed. All included signed an informed consent form.

Medical records of the selected patients were reviewed. All patients were recalled for a final follow-up visit. The following data were recorded and analyzed: gender; causative agent of the chemical injury; age at the time of the surgery; duration of follow-up; CDVA; intraocular pressure (IOP); any complications; postoperative treatment; and other surgical procedures needed, eg, cataract surgery, keratoplasty, and glaucoma surgery. The age of the donor and the relationship of the donor to the recipient were also recorded. Donors were tested for infectious diseases, eg, hepatitis B and C, and HIV infection. The outcome after the surgery was followed up by recording the percentage of patients with a stable ocular surface (see below), improvement of CDVA, and success/failure rate of the graft. Also, patients who had undergone another intervention were recorded.

The primary outcome measure was clinical success to obtain a stable ocular surface characterized by a completely epithelized corneal surface with or without mild residual corneal epithelial irregularities, resolution of the inflammation, and regression of corneal neovascularization (minimal vascularization of less than 3 hours circumference is acceptable as a success). Failure was considered as failure of complete corneal epithelialization or presence of corneal vascularization more than 3–4 hours. An episode of acute graft rejection was characterized by pain, decreased vision, photophobia, intense ciliary injection, and edema of the graft. Acute graft rejection was treated aggressively by increasing both topical and systemic treatment. More frequent topical steroid eyedrops (1% Prednisolone acetate) were applied, subconjunctival injection of triamcinolone, oral corticosteroids with tapering over several months, and increasing the dose of the oral immunosuppressive agent.

Dua grading⁸ for classifying the old ocular surface burns during the acute phase was applied to the included patients in the current study. This grading included six grades from I to VI according to the extent of limbal involvement rather than limbal ischemia (ranging from grade I with zero involvement to grade VI with 100% involvement) and the percentage of bulbar conjunctival involvement including the fornices (ranging from grade I with zero involvement to grade VI with 100% involvement). Grade IV included limbal involvement between 6 and 9 hours and conjunctival involvement between 50% and 75%. Grade V included limbal involvement between 9 and 12 hours and conjunctival involvement between 75% and 100%. Grade VI included limbal involvement of 100% and conjunctival involvement of 100%.

Statistical analyses

Clinical findings were statistically evaluated using Excel 2007 (Microsoft Corporation, Redmond, WA, USA) and SPSS software version 16.0 (SPSS Inc., Chicago, IL, USA). Means and standard deviations were calculated. The percentages of different variables were also calculated. Kaplan–Meier was used for survival analysis.

Ethics statement

The study was approved by the local ethics committee at the Faculty of Medicine, Alexandria University, Egypt. Tenets of the Declaration of Helsinki were followed. All included patients were recalled for final -p visit and signing an informed consent form.

Results

The mean age of the included patients was 27.4 ± 9.3 years (range=18–54 years). Fifteen patients were males (75%) and five patients were females. The causative agent of the chemical injury was an alkali in 14 patients (70%), an acid in four patients (20%), and was undetermined in two patients (10%). The mean follow-up period was 29.3 ± 10.5 months (range=18–42 months). Table 1 shows the characteristics of the included patients.

The presenting CDVA before any surgical intervention was hand motion (HM) in nine patients (45%), ie, 3 logMAR, counting fingers at 1 meter or less in seven patients (35%), ie, 2 logMAR, and counting fingers at 2–3 meters in four patients (20%), ie, 1.3–1.6 logMAR. None of the cases with acid injury presented with visual acuity of HM. Table 2 shows the postoperative best corrected visual acuity of the included patients. The mean of the extent of limbal involvement was 8.8 ± 1.9 hours (range=6–12 hours) and the mean percentage of conjunctival involvement was $70.0\% \pm 19.2\%$ (range=25%–100%). By applying Dua grading, nine patients

Table 1 Characteristics of the included patients

| | Age (years) | Gender | Cause | Preop. best corrected vision (logMAR) | Affected conjunctiva (%) | Affected limbus (hours) | Dua grading ⁸ |
|----|-------------|--------|---------|---------------------------------------|--------------------------|-------------------------|--------------------------|
| 1 | 18 | Female | Acid | 2/60 (1.6) | 50 | 6 | IV |
| 2 | 21 | Male | Alkali | HM (3.0) | 75 | 7 | IV |
| 3 | 34 | Male | Alkali | HM (3.0) | 75 | 8 | IV |
| 4 | 54 | Male | Alkali | HM (3.0) | 100 | 11 | V |
| 5 | 22 | Male | Acid | 1/60 (2.0) | 75 | 8 | IV |
| 6 | 18 | Male | Acid | 2/60 (1.6) | 50 | 6 | IV |
| 7 | 18 | Female | Alkali | 2/60 (1.6) | 50 | 7 | IV |
| 8 | 32 | Male | Alkali | 1/60 (2.0) | 75 | 9 | V |
| 9 | 24 | Male | unknown | HM (3.0) | 100 | 10 | V |
| 10 | 19 | Male | Alkali | HM (3.0) | 75 | 12 | V |
| 11 | 34 | Male | Alkali | 1/60 (2.0) | 75 | 9 | V |
| 12 | 40 | Male | Acid | 3/60 (1.3) | 25 | 7 | IV |
| 13 | 33 | Female | Alkali | HM (3.0) | 50 | 9 | IV |
| 14 | 24 | Female | Alkali | HM (3.0) | 75 | 12 | V |
| 15 | 19 | Male | Alkali | HM (3.0) | 75 | 12 | V |
| 16 | 27 | Male | ?? | 1/60 (2.0) | 75 | 9 | V |
| 17 | 26 | Female | Alkali | 1/60 (2.0) | 50 | 7 | IV |
| 18 | 21 | Male | Alkali | HM (3.0) | 100 | 9 | V |
| 19 | 30 | Male | Alkali | 1/60 (2.0) | 75 | 9 | V |
| 20 | 34 | Male | Alkali | 1/60 (2.0) | 75 | 9 | V |

Table 2 Outcome of the included patients

| | Donors | Intervention timing (months) | Regrafting | IOP | Postop. best corrected vision (logMAR) |
|----|---------|------------------------------|------------|-------|--|
| 1 | Brother | 15 | – | – | 6/60 (1.0) |
| 2 | Father | 14 | – | – | 2/60 (1.6) |
| 3 | Brother | 16 | – | Valve | 2/60 (1.6) |
| 4 | Father | 13 | 2 | Valve | 1/60 (2.0) |
| 5 | Father | 12 | – | – | 5/60 (1.1) |
| 6 | Father | 12 | – | – | 5/60 (1.1) |
| 7 | Father | 12 | – | Drops | 5/60 (1.1) |
| 8 | Sister | 17 | – | – | 3/60 (1.3) |
| 9 | Brother | 14 | 2 | – | 2/60 (1.6) |
| 10 | Father | 14 | 2 | Valve | 1/60 (2.0) |
| 11 | Brother | 14 | – | – | 2/60 (1.6) |
| 12 | Father | 12 | – | – | 6/60 (1.0) |
| 13 | Father | 12 | – | – | 4/60 (1.2) |
| 14 | Sister | 18 | – | Drops | 4/60 (1.2) |
| 15 | Brother | 15 | 2 | – | 3/60 (1.3) |
| 16 | Father | 14 | – | – | 2/60 (1.6) |
| 17 | Father | 14 | – | – | 3/60 (1.3) |
| 18 | Sister | 14 | 2 | Valve | 2/60 (1.6) |
| 19 | Father | 12 | – | Valve | 4/60 (1.2) |
| 20 | Brother | 12 | – | – | 4/60 (1.2) |

Abbreviation: IOP, intraocular pressure.

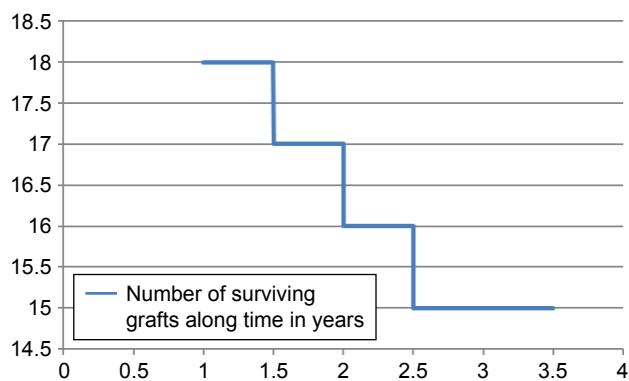


Figure 1 Limbal graft survival over time in years.

were grade IV and 11 patients were grade V. As regards AMT; 12 patients (60%) underwent AMT once, six patients (30%) underwent AMT twice, and two patients (10%) underwent AMT three times.

The mean duration from the chemical injury to the timing of limbal transplantation was 13.8 ± 1.7 months (range=12–18 months). The donor was the father in 11 patients (55%), the brother in six patients (30%), and the sister in three patients (15%). The mean age of the donor was 44.2 ± 12.2 years (range=22–59 years). Five patients (25%) needed regrafting (Table 2). As regards the IOP; five patients (25%) needed Ahmed's valve implantation to control the IOP, two patients (10%) needed medical treatment to control the IOP, and 13 patients (65%) had normal IOP. Other surgical procedures needed were penetrating keratoplasty (PKP) in three patients (15%), cataract surgery in six patients (30%), and lid surgery in one patient (5%). Two patients out of the three who required PKP had also undergone cataract surgery in the same sitting. All cases had postoperative systemic immunosuppressive therapy in the form of systemic steroids or cyclosporine (see above).

Fifteen patients (75%) had a stable ocular surface (ie, complete corneal re-epithelialization and resolution of postoperative inflammation) after the first limbal transplantation, while the other five patients (25%) needed regrafting. Figure 1 shows the limbal graft survival with time. Three patients of those five required PKP due to large corneal perforations. Twelve patients (60%) had a final CDVA ranging between 3/60 and 6/60 (1.3–1.0 logMAR). The other eight patients had a final CDVA ranging from 1/60 to 2/60 (2.0–1.6 logMAR). The mean re-epithelialization time was 19 ± 7.2 days. All cases had less pain and improvement in symptoms. Five eyes (25%) were highly inflamed, which necessitated a second AMT. Acute graft rejection occurred in three cases (15%) during the first 6 months postoperative and was treated (see above). No major complications were reported in donor eyes. Figures 2 and 3 shows example of the included cases before and after limbal transplantation.

Discussion

Patients presenting with ocular surface complications following bilateral severe chemical injuries present a challenge in the management. The problem of bilateral cases is that there is no available source for conjunctival-limbal autograft (CLAU) from the other eye, thus necessitating another source for the limbal stem cells. In the current study, two-thirds of the included patients were males in the second to fourth decade of life. This could be explained by the fact that males, especially younger age, are an active group, making them more liable to trauma and injuries. Janicijevic Petrovic et al²⁴ and Midelfart et al²⁵ also showed that chemical eye injuries occurred more among males. In the case series, alkali burns were more common than acid burns. Alkali burns can be caused by lye (a bleaching agent for wooden materials), lime (calcium oxide), or ammonia, while acid burns can be due

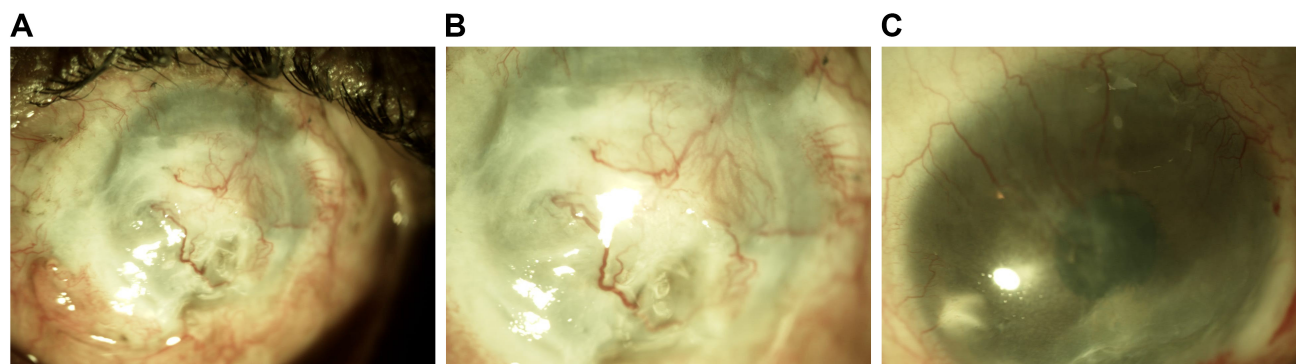


Figure 2 (A–C) Ocular surface status before limbal transplantation, with scarring and vascularization of the cornea.

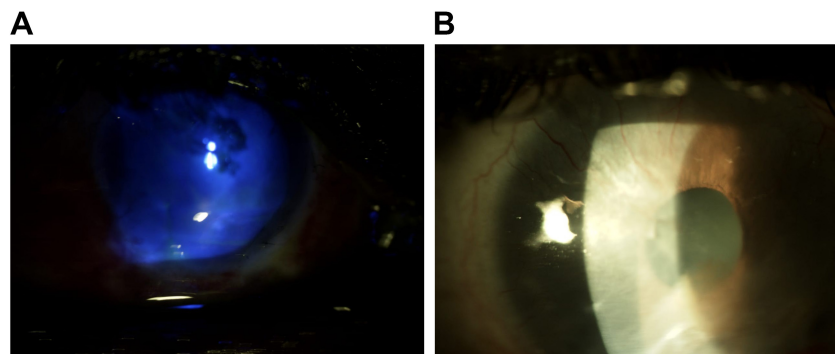


Figure 3 (A–B) Ocular surface re-epithelization and regression of corneal neovascularization after limbal transplantation.

to sulphuric acid or acetic acid. In the literature, there are different reports as regards the frequency of the causative agent of a chemical injury to the eye. In the current study, most of the cases were due to alkali injury. This is because the selected patients suffered from severe bilateral injury. An Alkali is known to have more severe effects on the ocular surface, with more penetration and damage than an acid. This explains why the number of acid injuries is less.^{26–28}

Most of the cases had poor vision at presentation and after the first aid management of the chemical injury, with 40% of the cases presenting with HM visual acuity. None of the cases with acid injury presented with visual acuity of HM (3.0 logMAR). All cases showed improvement in corrected distance visual acuity after surgical interventions. Patients with acid injury had postoperative best corrected visual acuity ranging between 5/60 and 6/60. Amniotic membrane transplantation was used in all the cases to prepare the ocular surface stroma for the limbal transplantations. It promoted healing, allowed for rapid recovery, decreased scarring and vascularization, and quieted the eye inflammation.^{21,30} Cases with delayed re-epithelialization after limbal transplantation needed another AMT to promote the regrowth of the epithelium. All five eyes with second AMT were alkali burns and were highly inflamed, in contrast to eyes with previous acid burns that didn't require a second AMT.

Vazirani et al³¹ reported the outcome of autologous simple limbal epithelial transplantation for unilateral cases. It was a multicenter study that included 68 eyes. They reported clinical success in 83% of the cases with a median follow-up of 12 months. The clinical success in the current study was 90% in the first year and 85% in the first 18 months. This was a comparable, if not slightly better outcome, despite the more severe nature and bilaterality of the cases that required a living related donor. This may be attributed to the use of prior AMT. However, the visual outcome in the current study was poorer than that achieved by the abovementioned

study (they reported 65% of cases with visual acuity 20/200 or better). Again, this is explained by the severe nature of included cases of the current study.

As regards, the timing of the limbal transplantation, the majority of the cases were done after the first year after chemical injury, in order to give time for the ocular surface to be more stable and less inflamed. The donor was the best HLA matched available donor (one of the parents was preferred, or else a sibling). The donor had to be screened for infectious diseases, eg, syphilis, hepatitis, and HIV before proceeding with the transplantation to avoid transfer of any diseases. Graft failure could still occur and in the current series we had five cases representing 25% of the cases with the need of regrafting. The donor in those cases was the father in two cases, the brother in two cases, and the sister in one case.

Arora et al³² compared the outcomes of simple limbal epithelial transplantation with conjunctival-limbal autologous transplantation in severe unilateral ocular chemical burns. Patients were followed up for 6 months and assessed for a stable epithelialized ocular surface and visual acuity. They concluded that both procedures were equally effective in achieving a stable ocular surface and regression of corneal vascularization. In their study, symblepharon due to scar tissue formation was graded from 0–4. A score of 1 was given for every 3-hour involvement. They reported better visual outcome, despite the shorter duration of follow-up (6 months).

Tsiklis et al³⁴ evaluated long-term results of limbal transplantation in patients with unilateral LSCD following chemical burns. They included 22 eyes of 22 patients. Twenty patients were males, a similar proportion to in our study. The mean time from surgery to corneal epithelization was 17.18 ± 9.8 days (which was comparable to our study). They had a higher success rate than our case series (95.4% vs 75%), despite their longer follow-up time (7.8 ± 3.5 years

vs 29.3±10.5 months). This might be due to the more complex nature of our included bilateral severe cases. Also, auto limbal transplantation lacked the problem of rejection faced by the allograft, even in the presence of systemic immunosuppression.

Cheung et al³⁵ presented two cases with combined conjunctival limbal autograft and living related conjunctival limbal allograft procedure to treat severe unilateral ocular surface failure. Systemic immunosuppression of oral Tacrolimus and mycophenolate mofetil were used. They concluded that combining both techniques maximized the amount of healthy limbal stem cells while minimizing the antigenic burden.

The intraocular pressure rise in our cases might be due to the use of steroids postoperative or due to the complications of the chemical injury itself. Two-third of the included cases did not have IOP problems, while the other third needed management in the form of either medications or surgery. Fifteen patients (75%) had a final visual acuity ranging between counting fingers at 4 meters and 20/200, which is a good result according to the presenting situation of the patients. Also, there were no major complications reported among the donor eyes, which denotes that harvesting a limbal stem cell on a conjunctival vehicle is a simple safe procedure for the donor.

Patients with Dua grade IV did not need regrafting (all five cases that needed regrafting were grade V). As regards the intraocular pressure, only one patient with grade IV needed a valve procedure and another patient needed eye drops. As regards the final visual outcome, patients with grade IV showed better best corrected visual acuity than patients with grade V (Table 2).

The retrospective nature was one of the limitations of the current study. However, the long follow-up period and collection of data for such a good number of cases with bilateral severe chemical injury necessitated the retrospective nature. Another limitation was the lack of a control group. The strength of the current study was the long follow-up period and the inclusion of a good number of cases that present a challenge in the current practice to manage such difficult cases.

In conclusion, living related conjunctival limbal allograft transplantation, especially when combined with amniotic membrane transplantation, yielded good results in the management of cases with bilateral severe chemical eye injuries.

Abbreviations

IOP, intra ocular pressure; PKP, penetrating keratoplasty; OCP, ocular cicatricial pemphigoid; AMT, amniotic

membrane transplantation; CDVA, corrected distance visual acuity; HIV, human immunodeficiency virus; HM, hand motion; LSCD, limbal stem cell deficiency; lr-CLAL, living related conjunctival limbal allograft.

Data sharing statement

Available in Tables 1 and 2 of the paper (any further data is available upon request).

Acknowledgments

The manuscript has been read and approved by all the authors, the requirements for authorship as stated have been met, and each author believes that the manuscript represents honest work.

Author contributions

All authors contributed toward data analysis, drafting and revising the paper, gave approval of the final version to be published and agree to be accountable for all aspects of the work.

Disclosure

The authors report no conflicts of interest in this work.

References

1. Dua HS, Azuara-Blanco A. Limbal stem cells of the corneal epithelium. *Surv Ophthalmol.* 2000;44(5):415–425.
2. Lavker RM, Tseng SC, Sun TT. Corneal epithelial stem cells at the limbus: looking at some old problems from a new angle. *Exp Eye Res.* 2004;78(3):433–446.
3. Puangricharn V, Tseng SC. Cytologic evidence of corneal diseases with limbal stem cell deficiency. *Ophthalmology.* 1995;102(10):1476–1485.
4. Poli M, Burillon C, Auxenfans C, Rovere MR, Damour O. Immunocytochemical diagnosis of limbal stem cell deficiency: comparative analysis of current corneal and conjunctival biomarkers. *Cornea.* 2015;34(7):817–823.
5. Dudakova L, Cheong SS, Merjava SR, et al. Familial limbal stem cell deficiency: clinical, cytological and genetic characterization. *Stem Cell Rev.* 2018;14(1):148–151.
6. Ballen PH. Treatment of chemical burns of the eye. *Eye Ear Nose Throat Mon.* 1964;43:57–61.
7. Roper-Hall MJ. Thermal and chemical burns. *Trans Ophthalmol Soc U K.* 1965;85:631.
8. Dua HS, King AJ, Joseph A. A new classification of ocular surface burns. *Br J Ophthalmol.* 2001;85(11):1379–1383.
9. Kim KH, Mian SI. Diagnosis of corneal limbal stem cell deficiency. *Curr Opin Ophthalmol.* 2017;28(4):355–362.
10. Vazirani J, Mariappan I, Ramamurthy S, Fatima S, Basu S, Sangwan VS. Surgical management of bilateral limbal stem cell deficiency. *Ocul Surf.* 2016;14(3):350–364.
11. Pfister RR. Corneal stem cell disease: concepts, categorization, and treatment by auto- and homotransplantation of limbal stem cells. *CLAO J.* 1994;20(1):64–72.
12. Dua HS. Stem cells of the ocular surface: scientific principles and clinical applications. *Br J Ophthalmol.* 1995;79(11):968–969.
13. Holland EJ. Management of limbal stem cell deficiency: a historical perspective, past, present, and future. *Cornea.* 2015;34(Suppl 10):S9–S15.

14. Haagdoorens M, van Acker SI, van Gerwen V, et al. Limbal stem cell deficiency: current treatment options and emerging therapies. *Stem Cells Int.* 2016;2016(4):1–22.
15. Rovere MR, Rousselle P, Haftek M, et al. Preserving basement membranes during detachment of cultivated oral mucosal epithelial cell sheets for the treatment of total bilateral limbal stem cell deficiency. *Cell Transplant.* 2018;27(2):264–274.
16. Dua HS, Forrester JV. The corneoscleral limbus in human corneal epithelial wound healing. *Am J Ophthalmol.* 1990;110(6):646–656.
17. Kenyon KR, Tseng SC. Limbal autograft transplantation for ocular surface disorders. *Ophthalmology.* 1989;96(5):709–722.
18. Fernandes M, Sangwan VS, Rao SK, Basti S, Sridhar MS, Bansal AK. Limbal stem cell transplantation. *Indian J Ophthalmol.* 2004;52(1):5–22.
19. Holland EJ, Djalilian AR, Schwartz GS. Management of aniridic keratopathy with keratolimbal allograft: a limbal stem cell transplantation technique. *Ophthalmology.* 2003;110(1):125–130.
20. Tsubota K, Satake Y, Kaido M, et al. Treatment of severe ocular-surface disorders with corneal epithelial stem-cell transplantation. *N Engl J Med.* 1999;340(22):1697–1703.
21. Tseng SCG, Prabhasawat P, Barton K, Gray T, Meller D. Amniotic membrane transplantation with or without limbal allografts for severe ocular surface disorders. *Ophthalmology.* 1995;102:1486–1496.
22. Dua HS, Azuara-Blanco A. Amniotic membrane transplantation. *Br J Ophthalmol.* 1999;83(6):748–752.
23. Tseng SC, Prabhasawat P, Lee SH. Amniotic membrane transplantation for conjunctival surface reconstruction. *Am J Ophthalmol.* 1997;124(6):765–774.
24. Janicijevic Petrovic M, Sarenac T, Janicijevic K, Vujic D, Vulovic D. Chemical eye injuries. *Acta MEDICA Saliniana.* 2014;42:544–548.
25. Midelfart A, Hagen YC, Myhre GB. [Chemical burns to the eye]. *Tidsskr Nor Laegeforen.* 2004;124(1):49–51. Norwegian.
26. Sharma N, Kaur M, Agarwal T, Sangwan VS, Vajpayee RB. Treatment of acute ocular chemical burns. *Surv Ophthalmol.* 2018;63(2):214–235.
27. Ramponi DR. Chemical burns of the eye. *Adv Emerg Nurs J.* 2017;39(3):193–198.
28. Koh DH, Lee SG, Kim HC. Incidence and characteristics of chemical burns. *Burns.* 2017;43(3):654–664.
29. Kim JC, Tseng SC. Transplantation of preserved human amniotic membrane for surface reconstruction in severely damaged rabbit corneas. *Cornea.* 1995;14(5):473–484.
30. Lee SH, Tseng SC. Amniotic membrane transplantation for persistent epithelial defects with ulceration. *Am J Ophthalmol.* 1997;123(3):303–312.
31. Vazirani J, Ali MH, Sharma N, et al. Autologous simple limbal epithelial transplantation for unilateral limbal stem cell deficiency: Multicentre results. *Br J Ophthalmol.* 2016;100(10):1416–1420.
32. Arora R, Dokania P, Manudhane A, Goyal JL. Preliminary results from the comparison of simple limbal epithelial transplantation with conjunctival limbal autologous transplantation in severe unilateral chronic ocular burns. *Indian J Ophthalmol.* 2017;65(1):35–40.
33. Vazirani J, Nair D, Shanbhag S, Wurity S, Ranjan A, Sangwan V. Limbal stem cell Deficiency-Demography and underlying causes. *Am J Ophthalmol.* 2018;188:99–103.
34. Tsiklis NS, Siganos DS, Lubbad A. Long term follow-up of limbal transplantation for unilateral chemical injuries: 1997–2014. *J Clin Exp Ophthalmol.* 2016;07(06):2.
35. Cheung AY, Sarnicola E, Govil A, Holland EJ. Combined conjunctival limbal autografts and living-related conjunctival limbal allografts for severe unilateral ocular surface failure. *Cornea.* 2017;36(12):1570–1575.

Clinical Ophthalmology

Publish your work in this journal

Clinical Ophthalmology is an international, peer-reviewed journal covering all subspecialties within ophthalmology. Key topics include: Optometry; Visual science; Pharmacology and drug therapy in eye diseases; Basic Sciences; Primary and Secondary eye care; Patient Safety and Quality of Care Improvements. This journal is indexed on

Submit your manuscript here: <http://www.dovepress.com/clinical-ophthalmology-journal>

Dovepress

PubMed Central and CAS, and is the official journal of The Society of Clinical Ophthalmology (SCO). The manuscript management system is completely online and includes a very quick and fair peer-review system, which is all easy to use. Visit <http://www.dovepress.com/testimonials.php> to read real quotes from published authors.