



Transpyloric optic navigation of tumor using a laparoscope during totally laparoscopic distal gastrectomy for gastric cancer

Sola Lee¹, Ho Goon Kim¹, Dong Yeon Kang¹, Dong Yi Kim¹, Seong Yeob Ryu²

¹Department of Surgery, Chonnam National University Hospital, Chonnam National University Medical School, Gwangju, Korea

²Department of Surgery, Chosun University Hospital, University of Chosun College of Medicine, Gwangju, Korea

Purpose: The purpose of this study was to describe the technique of intraoperative transpyloric optic navigation (TPON) and determine its efficacy and feasibility during totally laparoscopic distal gastrectomy (TLDG) in patients with gastric cancer.

Methods: Seventy-nine patients who underwent laparoscopic gastrectomy with transpyloric optic localization of the tumor from January 2016 through December 2018 were enrolled in this study. After resecting the first portion of the duodenum, the distal part of the stomach was exteriorized through an extended supraumbilical trocar site, and a balloon trocar was introduced from the pylorus to determine the location of tumor and determine its resection margin. The clinicopathologic and surgical outcomes were analyzed.

Results: The tumor was located in the lower third of the stomach in 39 cases, the middle third in 34 cases, and the upper-third in six cases. Tumor localization was successful in 67 patients. The mean proximal margin was 41.7 ± 26.8 mm. There was no morbidity related to the technique. By the fifth postoperative day, the average white blood cell count was within the normal range and the average level of C-reactive protein showed a decreasing pattern.

Conclusion: TPON of the tumor during TLDG is an effective and feasible method to determine the tumor location and to obtain an adequate resection margin.

Keywords: Stomach neoplasms, Gastrectomy, Laparoscopy, Tumor localization

This is an Open Access article distributed under the terms of the Creative Commons Attribution Non-Commercial License (<http://creativecommons.org/licenses/by-nc/4.0/>) which permits unrestricted non-commercial use, distribution, and reproduction in any medium, provided the original work is properly cited.

Received October 26, 2020

Revised November 16, 2020

Accepted November 18, 2020

Corresponding author

Ho Goon Kim

Department of Surgery, Chonnam National University Hospital, Chonnam National University Medical School, 42 Jebong-ro, Dong-gu, Gwangju 61469, Korea

Tel: +82-62-220-6456

Fax: +82-62-227-1635

E-mail: dr4477@hanmail.net

ORCID:

<https://orcid.org/0000-0002-8451-0061>

Copyright © The Korean Society of Endoscopic and Laparoscopic Surgeons.

INTRODUCTION

Gastric cancer is the most common cancer in men and the fourth most common cancer in women in South Korea [1]. Recently, the rate of stage I gastric cancer was reported to be 64% [2]. Since the introduction of laparoscopy-assisted distal gastrectomy in 1994 [3], the laparoscopic surgical approach for stage I gastric cancer has been shown to enhance the patients' quality of life. Hence, it has largely replaced open gastrectomy for early gastric cancer surgery [4–6]. An increasing number of surgeons have adopted

the totally laparoscopic approach with intracorporeal resection and anastomosis, instead of creating a mini-laparotomy incision. Compared to laparoscopy-assisted surgery, the totally laparoscopic approach has been shown to reduce postoperative pain, achieve faster recovery, and provide better cosmetic outcome [7,8].

Obtaining a safety margin is essential for curative gastric surgery. In stage T1 or T2 gastric cancer without serosal involvement, identifying the tumor location and determining the resection margin through laparoscopic view can be difficult even for an experienced surgeon [9,10]. Lesions in the middle to upper

thirds of the stomach can also be challenging for surgeons while performing distal or total gastrectomy. Many methods for tumor localization have been reported, such as intraoperative gastroscopy, preoperative endoscopic clipping, autologous blood tattooing, and preoperative fluorescence marking [10–13]. These methods require additional procedures besides the planned surgery, which might cause discomfort to patients and increase the cost of treatment. Moreover, preoperative clipping is not covered by the national health insurance in South Korea.

We used a laparoscope to determine the tumor location and safety margin in patients scheduled to undergo totally laparoscopic distal gastrectomy (TLGD) for cancer located in the gastric body. This is performed within the surgical field without the use of additional instruments. This study describes the technique of intraoperative transpyloric optic navigation (TPON), which was used to localize the lesion during laparoscopic gastrectomy and analyzes its efficacy and safety.

MATERIALS AND METHODS

Patients

At our institution, laparoscopic gastrectomy is performed in patients with cT1-2N0M0 and T3N0M0 gastric cancer, according to the patient's preference. For patients with T2 or T3 cancer with lymph node involvement, we consider performing open surgery. In these patients, final method of approach would be decided after discussing options with patients. However, these patients were excluded from this study regardless of surgical approach to ensure that difficulty of surgical procedure is comparable. Laparoscopic gastrectomy was also performed for patients with high-grade dysplasia when endoscopic submucosal dissection (ESD) was impossible or failed. In all, 167 patients underwent laparoscopic gastrectomy from January 2016 through December 2018. Patients who received laparoscopic total gastrectomy or with other clinical stages were excluded from this analysis. Among them, the distribution of the tumor location in the stomach was as follows; lower third in 100 patients, middle third in 42 patients, and upper third in 25 patients.

Preoperative imaging was evaluated by a single surgeon who would consider following indications for tumor localization. TPON was indicated for gastric cancers difficult for tactile perception with the laparoscopic instrument and under the following conditions: (1) location in the lower third of the stomach requiring visual confirmation of the safety margin, (2) location in the middle third of the stomach, or (3) location in the upper third of the stomach with an opportunity to perform distal gastrectomy if the safety margin can be secured. Based on these criteria, 39 patients with tumors located in the lower third, 34 with tumors in the middle third, and six with tumors located in the

upper third of the stomach underwent TPON during TLGD.

Preoperative esophagogastroduodenoscopy (EGD) and abdominal computed tomography (CT) were performed in all patients. In preparation for general anesthesia, chest radiograph, electrocardiogram, pulmonary function test, and routine investigations including complete blood count, blood chemistry, electrolyte, and coagulation profiles were checked. Chest CT or positron emission tomography were performed only for selected patients.

General surgical procedure

Under general anesthesia, the patient was positioned in the reverse Trendelenburg with split-leg position. Following the Hasson method, a supraumbilical port was inserted, and pneumoperitoneum was maintained between 12 to 14 mmHg. The scopist stood between the patient's legs and used a 30° rigid scope through the supraumbilical port, while the surgeon stood on the right side of the patient and used a 5-mm port in the right subcostal area, and a 12-mm port located about 8 to 10 cm caudal to the 5-mm port. Most of the surgeries were performed using three ports according to the method previously reported by our institution [14]. In cases of dense adhesions or difficult lymph node dissection, an additional 5-mm port was inserted through the left side of the abdomen for assistance.

D1+ or D2 lymphadenectomy was performed as described in the Japanese Gastric Cancer Treatment Guidelines 2014 (version 4) [15]. Surgery was performed in the following sequence. First, omentectomy including lymph nodes No. 4 and 6 along with ligation of the left and right gastroepiploic vessels were performed. The duodenum was then divided after dissection of lymph nodes No. 5 and 12, and the right gastric artery was ligated. Next, lymph nodes No. 8, 9, and 11 were resected and the left gastric artery was ligated. Following the completion of lymphadenectomy, gastric resection was performed after direct visual confirmation of the tumor location and safety margin using the technique described in the next section. According to the Japanese Gastric Cancer Treatment Guidelines, the safety margin for T2 and T1 tumors should be at least 3 and 2 cm, respectively. Intraoperative frozen biopsy was performed if the safety margin was equal or less than 2 cm, and additional resection was performed if the frozen biopsy showed positive tumor involvement. If an adequate safety margin could not be obtained, total gastrectomy was performed even if distal gastrectomy was planned preoperatively. In all patients, intracorporeal anastomosis was performed using Billroth II or Roux-en-Y gastrojejunostomy.

Tumor localization

After completion of adequate lymph node dissection, the expected proximal margins were clamped using a laparoscopic clamp

from the lesser curvature of the stomach (Fig. 1A). The blunt-tip balloon trocar was removed from the supraumbilical port and the incision was elongated for an additional 2 to 3 cm, and a small-sized wound retractor was inserted. The proximal part of the divided duodenum was mobilized through the extended incision using intestinal clamp (Fig. 2B). Using Bovie electrocautery, an approximately 2-cm-sized duodenotomy was performed on the exteriorized part, and the previously removed balloon trocar was inserted through the opening into the pylorus (Fig. 2B, C). The balloon was inflated with 30 mL of air to anchor the pylorus to the port site (Fig. 2D). The gastric lumen was inflated with CO₂ at a pressure of 12 mmHg, and the tumor was visually located with the laparoscope. Under direct visual inspection, the

distance between the tumor (blue arrow) and the clamp (red arrow) was evaluated for adequate safety margin (Fig. 3). The balloon trocar was deflated and removed from the pylorus, and the duodenal opening was closed with vicryl 1-0. The wound retractor was closed with a wound retractor cover, and intraabdominal pneumoperitoneum was created again. The clamp was removed, and the stomach was resected with a linear stapler along the indentation made from the removed clamp (Fig. 1B, red arrow). If the margin was judged to be insufficient, the clamp was adjusted under intraabdominal pneumoperitoneum and the above-mentioned procedure was repeated. The laparoscope was irrigated with normal saline, each time it was removed from the stomach.

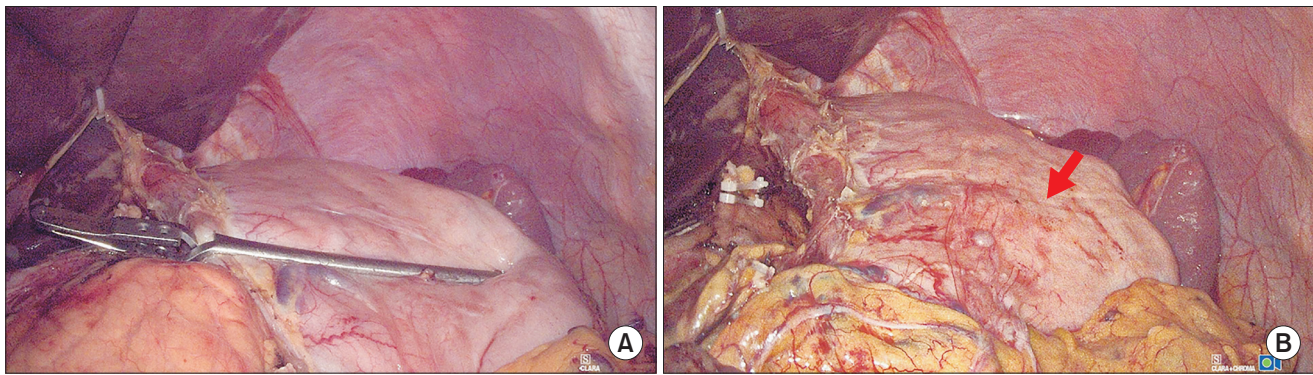


Fig. 1. Laparoscopic view of clamping the proximal margin. (A) A laparoscopic clamp is applied from the lesser curvature of the stomach at the expected proximal resection margin. (B) Indentation from the laparoscopic can be observed (arrow). Linear stapler is applied along this line.

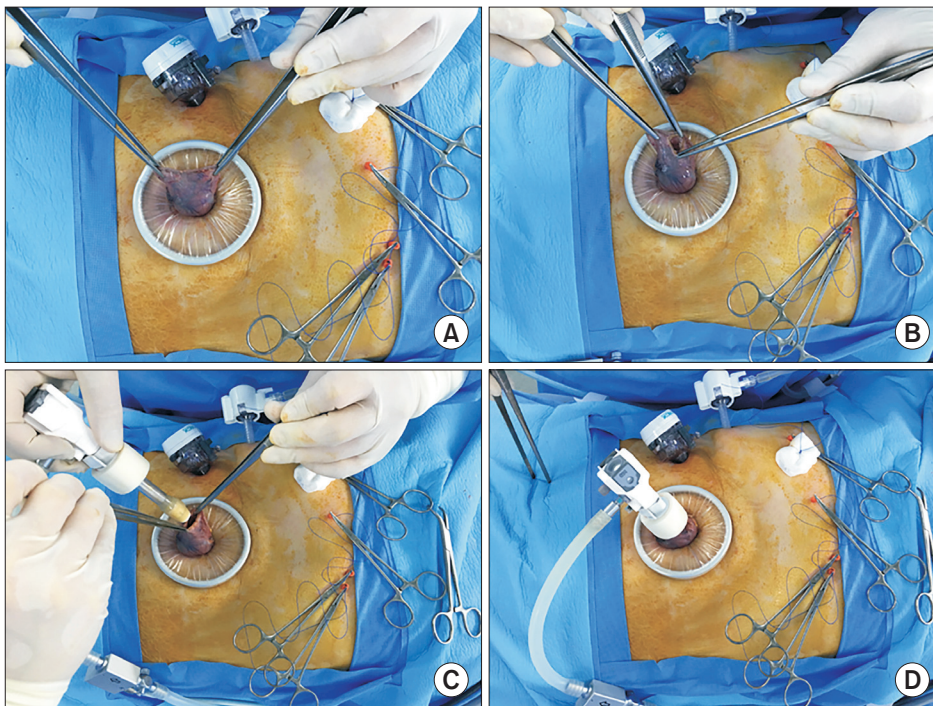


Fig. 2. Obtaining transpyloric view. (A) Resected duodenum is exteriorized using atraumatic forceps. (B) Using Bovie electrocautery, 2-cm-sized duodenotomy is performed. (C) Balloon trocar is introduced into the stomach. (D) Balloon is inflated with 30 mL of air and anchored to the extended umbilical port.

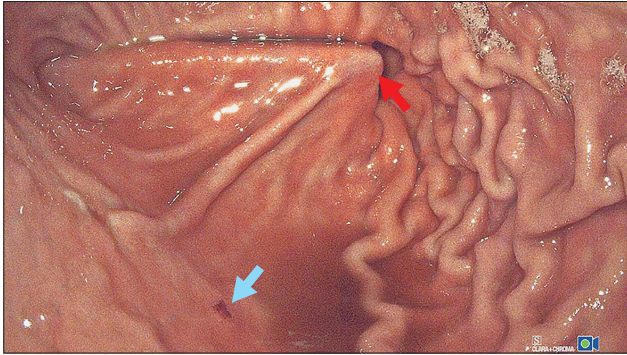


Fig. 3. Stomach is inflated with CO₂ gas and the tumor (blue arrow) is directly observed. The distance between the tumor and the clamp (red arrow) was evaluated for adequate safety margin.

RESULTS

Patient and tumor characteristics

The clinicopathological characteristics are summarized in Table 1. During the study period, 79 patients underwent TPON for gastric cancer as indicated. The study population comprised 56 male and 23 female patients with a mean age of 64.6 ± 11.6 years. All the patients were scheduled to undergo TLDG. Seventy-two patients (91.1%) were clinically diagnosed with early gastric cancer, and in most cases, the tumor was in the lower third (39 patients, 49.4%) or in the middle third (34 patients, 43.0%) of the stomach. Mean proximal margin was 41.7 ± 26.8 mm.

Surgical outcome

The operative results are summarized in Table 2. All eligible patients underwent tumor localization using the procedure described previously. There were three cases of cholecystectomy and one case of hepatic cyst unroofing for a simple hepatic cyst as a combined resection. The mean duration of surgery was 207 minutes (range, 130–305 minutes). Tumor localization was successful in 67 patients (84.8%).

There were no morbidities related to the TPON procedure. By the fifth postoperative day (POD), the average white blood cell (WBC) counts normalized, and the average C-reactive protein (CRP) level showed a decreasing trend (Table 3).

Postoperative morbidity and 30-day mortality are summarized in Table 4. Thirteen patients developed medical or surgical complications, and the overall morbidity was 16.5%. Surgical complications were graded on the basis of the Clavien-Dindo classification [16].

One patient required mechanical ventilation owing to aspiration pneumonitis after a vomiting event resulting from severe

Table 1. Patient's characteristics and tumor clinicopathological characteristics

Characteristic	Value
Patient	79 (100)
Age (yr)	64.6 ± 11.6
Sex	
Male	56 (70.9)
Female	23 (29.1)
Body mass index (kg/m ²)	24.8 ± 3.9
ASA PS classification	
I	29 (36.7)
II	48 (60.8)
III	2 (2.5)
Previous abdominal surgery	12 (15.2)
Preoperative ESD	10 (12.7)
No. of tumors	
1	75 (94.9)
2	4 (5.1)
Tumor location	
Lower third	39 (49.4)
Middle third	34 (43.0)
Upper third	6 (7.6)
Pathological tumor size (mm)	20.3 ± 11
Pathological proximal margin (mm)	41.7 ± 26.8
Pathological distal margin (mm)	78.0 ± 41.6
Clinical stage ^{a)}	
0 (Tis)	6 (7.6)
T1NOMO	66 (83.5)
T2NOMO	7 (8.0)
Depth of invasion ^{a)}	
Tis	4 (5.1)
T1	71 (89.9)
T2	1 (1.3)
T3	2 (2.5)
T4	1 (1.3)
Node metastasis ^{a)}	
N0	70 (88.6)
N1	5 (6.3)
N2	2 (2.5)
N3	1 (1.3)
TNM stage ^{a)}	
LGD/HGD	4 (5.1)
I	70 (88.6)
II	2 (2.5)
III	3 (3.8)

Values are presented as number (%) or mean \pm standard deviation. ASA PS, American Society of Anesthesiologists physical status; ESD, endoscopic submucosal dissection; LGD, low-grade dysplasia; HGD, high-grade dysplasia.

^{a)}According to the 8th edition of the American Joint Committee on Cancer TNM classification of gastric carcinoma.

Table 2. Operative results

Outcome	Value (n = 79)
Anastomosis	
Billroth II	71 (89.9)
Roux-en-Y	8 (10.1)
Lymph node dissection	
D1+	45 (57.0)
D2	34 (43.0)
Combined resection	4 (5.0)
Operation time (min)	207 ± 38
Bleeding (mL)	62.1 ± 113.5
No. of retrieved lymph nodes	34 ± 16.5
No. of successful TPON	67 (84.8)

Values are presented as number (%) or mean ± standard deviation. TPON, transpyloric optic navigation.

Table 3. Postoperative inflammatory markers

Marker	Level
WBC ($\times 10^3/\text{mm}^3$)	
POD 2	10.5 ± 3.4
POD 5	6.3 ± 2.4
Neutrophil count ($\times 10^3/\text{mm}^3$)	
POD 2	8.3 ± 3.3
POD 5	4.3 ± 2.2
CRP (mg/dL)	
POD 2	11.2 ± 5.1
POD 5	6.9 ± 6.0

Values are presented as mean ± standard deviation. WBC, white blood cell; POD, postoperative day; CRP, C-reactive protein.

postoperative ileus. The patient was successfully weaned from the ventilator after 1 day. He was discharged on the POD 12. Four cases of postoperative ileus and one case of gastric stasis resulted in delayed feeding at least for 3 days, and parenteral nutrition was administered. There were four cases of ascites. Three patients were either clinically observed or treated with diuretics, while in one patient, the abdominal drain was removed after 10 days. Non-surgical site infection (SSI), pneumonia, and urinary tract infection were treated with antibiotics. Grade I complication of pulmonary edema improved on administration of diuretics. There was no mortality during the 30-day perioperative period.

Table 4. Postoperative surgical outcomes

Outcome	Value (n = 79)
First flatus (POD)	3.2 ± 0.9
Diet resumption (POD)	2.0
Length of hospital stay (POD)	7.9 ± 3.8
Overall morbidity ^{a)}	13 (16.5)
Grade I	
Ascites	3
Pulmonary	1
Grade II	
Gastric stasis	1
Ileus	4
Ascites	1
Renal	1
Pulmonary	1
Grade III	0
Grade IV	
Ileus	1
Mortality ^{b)}	0 (0)

Values are presented as mean ± standard deviation, number (%), or number only.

POD, postoperative day.

^{a)}According to Clavien-Dindo classification. ^{b)}Mortality within 30 days after surgery.

DISCUSSION

Laparoscopic surgery plays a vital role in the treatment of gastric cancer. For the most part of gastric cancer treatment, totally laparoscopic surgery is performed to optimize the benefits of laparoscopy, such as reduced postoperative pain and complications, with better cosmesis. However, under laparoscopic view, it is difficult to determine the location and safety margin of the tumor unless there is serosal involvement. To overcome this challenge, many surgeons have explored numerous methods [10–13,17–20]. These methods require additional preoperative or intraoperative procedures. Intraoperative gastroscopy is commonly performed; however, it requires the presence of an endoscopist or surgeon who can perform the EGD. Deciding on an appropriate timing for the endoscopist to perform a gastroscopy can be difficult and might require waiting time. Alternatively, the surgeon must move away from the surgical field for the gastroscopy to be performed. Preoperative clipping requires EGD before surgery and intraoperative radiography or laparoscopic ultrasonography, which requires an intraoperative portable X-ray or ultrasound machines. From experience, it can be stated that locating the

clip can be tiresome or inaccurate. Preoperative tattooing can be difficult when the fluorescent dye or autologous blood spreads beyond the intended area. These methods also increase the economic burden for the patient.

At our center, we used the laparoscope without the aid of any additional instruments. It is a relatively simple and cost-effective way of assessing the tumor location and safety margin during TLDG. After extending the supraumbilical trocar incision, the resected stomach was exteriorized, and the withdrawn balloon trocar was inserted from the pylorus. During TPON, tumor dissemination through the created opening and by the laparoscope without sterilization should be considered. In this procedure, the laparoscope is inserted into the gastric lumen to localize the lesion but does not directly manipulate the cancer lesion. Our technique is presupposed that the risk of cancer dissemination will be low even with saline irrigation of the instrument. To maintain adequate intragastric luminal distension and prevent possible tumor cell seeding, the opening is directed toward the extracorporeal area when positive pressure is applied in the stomach. In addition, gastric perforation during ESD, which directly manipulates cancer, has been reported that does not lead to peritoneal recurrence in the long term [21]. *In vitro* simulation of tumor cell aerosolization was experimented with in effort to investigate port-site tumor recurrence. However, CO₂ pressure at 15 or 30 mmHg did not produce tumor cell aerosolization of B16 melanoma tumor cell [22]. To the best of our knowledge tumor cell does not disseminate through aerosolization. Therefore, it is presumed that cancer seeding is not increased by creating an opening. A long-term follow-up study might be necessary to demonstrate the risk of cancer seeding or recurrence with this technique.

This study involving gastric cancer patients undergoing TLDG with TPON of tumors confirmed the efficacy of this technique, as the mean proximal margin length was 41.7 ± 26.8 mm. The minimal proximal margin length was reported to be 5 mm. The actual surgical proximal margin at the time of resection was about 10 mm; however, during the surgery, the surgical proximal margin was incised for intraoperative frozen section biopsy in order to confirm a negative tumor margin. The data reflect the result of the pathological biopsy, which measured the remaining specimen. From our short-term study, we propose that this technique is effective and feasible for determining the location of the tumor and the resection margin.

Furthermore, this technique can be informative when deciding the extent of surgery for a tumor located in the upper third of the stomach. When the tumor is in the upper third, but a distal gastrectomy is planned, a total gastrectomy should be performed if the cancer lesion is present in the proximal than expected from the preoperative examinations. However, if an adequate proximal margin is confirmed through TPON, distal gastrectomy can be

performed.

There is a possibility of increased postoperative inflammation or infection following TPON. During the navigation process, the laparoscope is placed into the gastric lumen and is later placed back into the intraabdominal cavity without sterilization. Okholm et al. [23] compared the level of inflammatory markers between patients of gastric cancer undergoing laparoscopic-assisted distal gastrectomy or open distal gastrectomy reported in ten separate studies. In this review article, the WBC count on the POD 2 or 3 was between 7.2 ± 2.1 to $9.7 \pm 3.0 \times 10^3/\text{mm}^3$. On the POD 5, it decreased to 5.4 ± 1.4 to $6.9 \pm 2.4 \times 10^3/\text{mm}^3$. The CRP level on the POD 2 or 3 was 5.1 ± 4.0 to 8.4 ± 5.3 mg/dL. On the POD 5, the CRP level decreased to 1.4 ± 1.7 to 4.7 ± 3.8 mg/dL. Our data showed comparable WBC counts (POD 2, $10.5 \pm 3.4 \times 10^3/\text{mm}^3$; POD 5, $6.3 \pm 2.4 \times 10^3/\text{mm}^3$) and a relatively higher CRP level (POD 2, 11.2 ± 5.1 mg/dL; POD 5, 6.9 ± 6.0 mg/dL). Since there was no incidence of SSI, we consider the risk of infection from TPON technique to be low. A study with a large sample size might be necessary to evaluate the rate of SSI associated with the procedure.

In our experience, this procedure might be limited to some tumor locations. Even with this technique, it was difficult to determine the tumor location in 12 patients. Of the 12 patients, seven patients had tumors located in the middle third, three patients in the upper third, and two patients at the lower third of the stomach. In seven patients, tumors were not visually detectable with laparoscope. In one case, after performing TPON and inspection of extracted specimen, additional resection was performed upon surgeon's judgment. Although TPON was successful it was considered as failed case. For two patients with tumor located distal to the gastric angle and two other patients with tumor in the antral greater curvature, lesions were obscured as the stomach was distended and antrum was folded. In such cases, we could not confirm the lesion directly. We indirectly confirmed the adequate proximal margin by ensuring that the lesion was not present between the clamped gastric resection line and the visible tumor-free distal area. Nevertheless, this procedure is an effective and convenient method to localize gastric cancer located in the upper-third or middle-third of the stomach.

This study has some limitations. The series of surgeries were performed by a single surgeon at a single center. A randomized controlled study comparing distal gastrectomy with or without TPON is further warranted for confirmation of safety of the procedure, and a future multicenter study evaluating long-term results of survival or disease-free survival is also required.

In conclusion, TPON of tumor during TLDG is an effective and feasible method to determine the tumor location and determine an adequate safety margin. Although a totally laparoscopic approach has many advantages, it can be challenging to localize the tumor under the laparoscope. We believe that TPON can

overcome this difficulty while reducing the time and cost required for additional instrument or personnel.

NOTES

Ethical statements

This study was approved by the Institutional Review Board of Chonnam National University Hospital in Gwangju, Korea, with a waiver of informed consent (No. BTMP-2019-348).

Authors' contributions

Conceptualization: SL, HGK, DY Kim

Formal analysis: SL, DY Kang

Methodology: SYR, HGK

Writing-original draft: SL, HGK, DY Kim

Writing-review & editing: SL, HGK

Conflict of interest

All authors have no conflicts of interest to declare.

ORCID

Sola Lee, <https://orcid.org/0000-0001-6791-5668>

Ho Goon Kim, <https://orcid.org/0000-0002-8451-0061>

Dong Yeon Kang, <https://orcid.org/0000-0003-1995-9599>

Dong Yi Kim, <https://orcid.org/0000-0002-1510-908X>

Seong Yeob Ryu, <https://orcid.org/0000-0002-2739-9192>

REFERENCES

- Oh CM, Won YJ, Jung KW, et al. Cancer statistics in Korea: incidence, mortality, survival, and prevalence in 2013. *Cancer Res Treat* 2016;48:436-450.
- Information Committee of Korean Gastric Cancer Association. Korean Gastric Cancer Association nationwide survey on gastric cancer in 2014. *J Gastric Cancer* 2016;16:131-140.
- Kitano S, Iso Y, Moriyama M, Sugimachi K. Laparoscopy-assisted Billroth I gastrectomy. *Surg Laparosc Endosc* 1994;4:146-148.
- An JY, Cheong JH, Hyung WJ, Noh SH. Recent evolution of surgical treatment for gastric cancer in Korea. *J Gastric Cancer* 2011;11:1-6.
- Kim HH, Han SU, Kim MC, et al. Prospective randomized controlled trial (phase III) to comparing laparoscopic distal gastrectomy with open distal gastrectomy for gastric adenocarcinoma (KLASS 01). *J Korean Surg Soc* 2013;84:123-130.
- Kitano S, Shiraishi N. Current status of laparoscopic gastrectomy for cancer in Japan. *Surg Endosc* 2004;18:182-185.
- Kinoshita T, Shibasaki H, Oshiro T, Ooshiro M, Okazumi S, Katoh R. Comparison of laparoscopy-assisted and total laparoscopic Billroth-I gastrectomy for gastric cancer: a report of short-term outcomes. *Surg Endosc* 2011;25:1395-1401.
- Song KY, Park CH, Kang HC, et al. Is totally laparoscopic gastrectomy less invasive than laparoscopy-assisted gastrectomy?: prospective, multicenter study. *J Gastrointest Surg* 2008;12:1015-1021.
- Lee CM, Park S, Park SH, et al. A comparison between two methods for tumor localization during totally laparoscopic distal gastrectomy in patients with gastric cancer. *Ann Surg Treat Res* 2016;91:112-117.
- Ushimaru Y, Omori T, Fujiwara Y, et al. The feasibility and safety of preoperative fluorescence marking with indocyanine green (ICG) in laparoscopic gastrectomy for gastric cancer. *J Gastrointest Surg* 2019;23:468-476.
- Jeong O, Cho SB, Joo YE, Ryu SY, Park YK. Novel technique for intraoperative tumor localization during totally laparoscopic distal gastrectomy: endoscopic autologous blood tattooing. *Surg Endosc* 2012;26:1778-1783.
- Park DH, Moon HS, Sul JY, et al. Role of preoperative endoscopic clipping in laparoscopic distal gastrectomy for early gastric cancer. *Medicine (Baltimore)* 2018;97:e13165.
- Xuan Y, Hur H, Byun CS, Han SU, Cho YK. Efficacy of intraoperative gastroscopy for tumor localization in totally laparoscopic distal gastrectomy for cancer in the middle third of the stomach. *Surg Endosc* 2013;27:4364-4370.
- Kim HG, Kim DY, Jeong O. Transition from conventional to reduced-port laparoscopic gastrectomy to treat gastric carcinoma: a single surgeon's experience from a small-volume center. *J Gastric Cancer* 2018;18:172-181.
- Japanese Gastric Cancer Association. Japanese gastric cancer treatment guidelines 2014 (ver. 4). *Gastric Cancer* 2017;20:1-19.
- Dindo D, Demartines N, Clavien PA. Classification of surgical complications: a new proposal with evaluation in a cohort of 6336 patients and results of a survey. *Ann Surg* 2004;240:205-213.
- Gunji H, Horibe D, Uesato M, et al. Gastric resection under retroflexed endoscopic guidance: a reliable procedure for totally laparoscopic subtotal gastrectomy. *Dig Surg* 2017;34:12-17.
- Kim BS, Yook JH, Kim BS, Jung HY. A simplified technique for tumor localization using preoperative endoscopic clipping and radioopaque markers during totally laparoscopic gastrectomy. *Am Surg* 2014;80:1266-1270.
- Kim HI, Hyung WJ, Lee CR, et al. Intraoperative portable abdominal radiograph for tumor localization: a simple and accurate method for laparoscopic gastrectomy. *Surg Endosc* 2011;25:958-963.
- Matsuda T, Iwasaki T, Hirata K, et al. Simple and reliable method for tumor localization during totally laparoscopic gastrectomy: intraoperative laparoscopic ultrasonography combined with tattooing. *Gastric Cancer* 2017;20:548-552.
- Ikehara H, Gotoda T, Ono H, Oda I, Saito D. Gastric perforation during endoscopic resection for gastric carcinoma and the risk of peritoneal dissemination. *Br J Surg* 2007;94:992-995.

22. Sellers GJ, Whelan RL, Allendorf JD, et al. An in vitro model fails to demonstrate aerosolization of tumor cells. *Surg Endosc* 1998;12:436-439.
23. Okholm C, Goetze JP, Svendsen LB, Achiam MP. Inflammatory response in laparoscopic vs. open surgery for gastric cancer. *Scand J Gastroenterol* 2014;49:1027-1034.