

Case Report

Spontaneous Spinal Epidural Haematoma Secondary to Autoimmune Acquired Haemophilia

Fardad T. Afshari Dhruv Parikh Vladimir Petrik

Department of Neurosurgery, Birmingham University Hospital, Birmingham, UK

Keywords

Acquired haemophilia · Autoimmune condition · Spinal epidural haematoma

Abstract

Spontaneous spinal epidural haematoma is a rare entity associated with high morbidity. Although there are previous reports of spinal haematoma secondary to X-linked genetic haemophilia, there are no such cases secondary to acquired autoimmune haemophilia. We report the case of a 71-year-old patient who presented with sudden quadriplegia secondary to cervical (C2 to T1) epidural haematoma as a result of undiagnosed autoimmune acquired haemophilia A. She underwent emergency cervical laminectomy and evacuation of spinal haematoma with significant recovery in upper limb function. This case highlights the importance of haematological investigations in patients with spontaneous spinal haematoma.

© 2018 The Author(s)
Published by S. Karger AG, Basel

Introduction

Spontaneous spinal epidural haematoma is a rare but devastating condition that can lead to significant morbidity and functional loss. This condition has an estimated incidence of 0.1 in 100,000 and can occur in patients with coagulopathies or underlying vascular malformations [1–3]. Epidural haematomas mostly occur in the cervicothoracic spine. Spontaneous spinal epidural haematomas have largely been described in the paediatric population in

association with X-linked genetic factor deficiencies such as haemophilia A and B [3]. Acquired haemophilia on the other hand is extremely rare, autoimmune coagulopathy secondary to loss of factor VIII or IX with an incidence of 1.4 in 1,000,000 in the UK. This predominantly affects adults as opposed to paediatric population. There are no reports of spontaneous spinal epidural bleed from autoimmune haemophilia A. We report a rare case of spontaneous cervical epidural haematoma in a patient presenting with sudden-onset quadriplegia secondary to autoimmune haemophilia and highlight the importance of haematological investigations in such patients.

Case Report

A 71-year-old female with a background of rheumatoid arthritis with no previous history of bleeding disorder presented to her local hospital with sudden onset of neck pain and quadriplegia. On examination, she was found to have a power of 3/5 on the Medical Research Council (MRC) scale in the left upper limb with 0/5 in the right upper limb. The power in lower limbs was 1/5 in the left lower limb with 0/5 in the right lower limb. She underwent whole-spine magnetic resonance imaging (MRI) which revealed a long segment of epidural bleed extending from C2 down to T1 (Fig. 1). In addition, MRI did not reveal any underlying vascular anomalies. She underwent emergency cervical laminectomy and evacuation of epidural bleed. No excessive intraoperative bleeding was encountered. While in the intensive care unit post-operatively, she developed intermittent episodes of bleeding from the tracheal tube site over the course of few weeks. In light of ongoing bleeding episodes, she was further reviewed and investigated by the haematology team. She was found to have an elevated activated partial thromboplastin time (APTT) at 1.6 with a normal international normalised ratio (INR) of 1 and a platelet count of 245. Further haematological investigations demonstrated factor VIII levels of 6 U/dL (reference 57–158) with presence of factor VIII inhibitor in the blood, and the diagnosis of autoimmune acquired haemophilia A was established. She was therefore commenced on steroids and mycophenolate immunosuppressive therapy. Factor VIII levels responded to immunosuppressive therapy with levels improving to 125 U/dL over the course of 1.5 months. She made a significant recovery in the upper limb with the power improving from 0/5 to +4/5 in the right upper limb and from 3/5 to +4/5 in the left upper limb. She was able to hold objects and regain the ability to feed herself independently. Left lower limb power improved from 1/5 to 2/5. No improvement was observed in the right lower limb with a power of 0/5.

Discussion

Spinal epidural haematoma secondary to acquired haemophilia is a rare condition that has not been previously reported. Haemophilia is an umbrella term for rare bleeding disorders secondary to inherited blood clotting disorders caused by inactive or deficient clotting factors. There are three major types of inherited haemophilia: haemophilia A (factor VIII deficiency), haemophilia B (factor IX deficiency), and haemophilia C (factor XI deficiency). Both haemophilia A and B are inherited as X-linked recessive genetic disorders, while haemophilia C is an autosomal recessive genetic disorder.

Acquired haemophilias on the other hand are autoimmune conditions mostly affecting elderly population. The majority of cases involve factor VIII deficiency, although rare cases involving factor IX have also been described [4].

Although X-linked hereditary haemophilia cases present in childhood with various bleeding episodes leading to early diagnosis, the majority of patients with acquired haemophilia have no significant previous history of bleeding, and a high index of suspicion is required when spontaneous epidural bleeds are encountered. Intracranial haematomas following neurosurgical procedures have been described previously in patients with acquired autoimmune haemophilia [5].

Investigations for diagnosis of acquired haemophilia are directed at detection of factor VIII and IX inhibitors. Individuals with acquired haemophilia have an isolated prolonged APTT, with normal PT. Specialised APTT tests can be performed to allow differentiation of genetic factor deficiencies from autoimmune cases where presence of autoantibodies inhibits factor function and levels.

Treatment of acquired haemophilia has two facets which include control of acute bleeding and long-term control of factor inhibitors to prevent further bleeding episodes. Acute treatment can involve agents that directly bypass the factor deficiency. These include agents such as activated prothrombin complex concentrate. As a long-term solution to reduce the factor inhibitors, corticosteroids alone or in combination with immunosuppressive therapy such as mycophenolate or azathioprine or cyclophosphamide can be used. In our patient, a combination of steroids and mycophenolate was used with good response.

Management of epidural haematoma is predominantly surgical to decompress spinal cord and preserve any residual neurological function. The non-operative management is reserved for patients who are not surgical candidates or asymptomatic. Overall, a high index of suspicion in spontaneous spinal haematomas is recommended as such patients may have an undiagnosed coagulopathy or factor deficiency even in the absence of a clear history of bleeding disorder. Isolated prolonged APTT should prompt further investigations in this group of patients.

Statement of Ethics

The patient has given full consent for publication of this article.

Disclosure Statement

The authors declare that they have no conflicts of interest.

Funding Sources

This work did not receive any specific grant from funding agencies.

References

- 1 Figueroa J, DeVine JG. Spontaneous spinal epidural hematoma: literature review. *J Spine Surg*. 2017 Mar;3(1):58–63.

- 2 Mathais Q, Esnault P, Cruc M, Bernard C, Prunet B, Gaillard PE. Spontaneous Cervical Spinal Epidural Hematoma Associated with Dabigatran. *World Neurosurg.* 2018 Apr;112:264–6.
- 3 Rois PV, López MR, de Vergara BC, de la Lama Zaragoza A, García JG, Uxo JM. Spinal epidural hematoma in hemophilic children: controversies in management. *Childs Nerv Syst.* 2009;25(8):987–91; discussion 993, 995.
- 4 Kruse-Jarres R, Kempton CL, Baudo F, Collins PW, Knoebl P, Leissing CA, et al. Acquired hemophilia A: updated review of evidence and treatment guidance. *Am J Hematol.* 2017 Jul;92(7):695–705.
- 5 Akamatsu Y, Hayashi T, Yamamoto J, Karibe H, Kameyama M, Tominaga T. Newly Diagnosed Acquired Hemophilia A Manifesting as Massive Intracranial Hemorrhage Following a Neurosurgical Procedure. *World Neurosurg.* 2018 Mar;111:175–80.

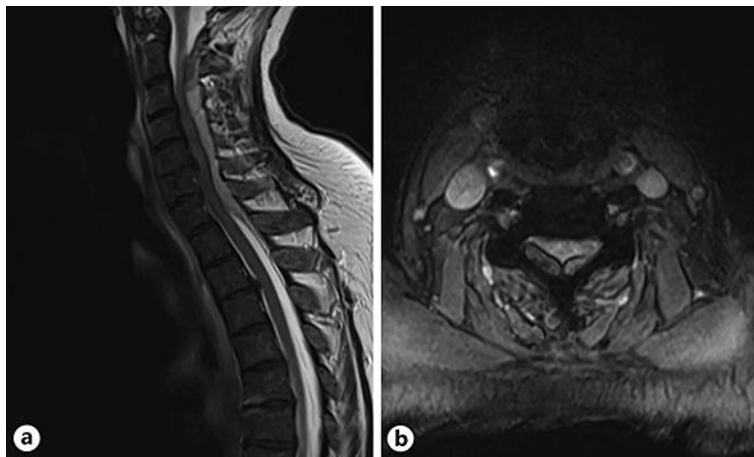


Fig. 1. MRI cervical spine T2 sagittal (a) and axial (b) views demonstrating a large epidural haematoma extending from the C2 to the T1 region with evidence of cord compression.