

# Barry shunt for treatment of a 76-hour stuttering priapism without subsequent erectile dysfunction

Daniar Kurmanbekovich  
Osmonov  
Aleksey Aksenov  
Andrea Nathaly Guerra  
Sandoval  
Almut Kalz  
Klaus Peter Juenemann

Department of Urology and  
Pediatric Urology, University  
Hospital Schleswig-Holstein,  
Campus Kiel, Kiel, Germany



Correspondence: Daniar Kurmanbekovich  
Osmonov  
Department of Urology and Pediatric  
Urology, University Hospital Schleswig-  
Holstein, Campus Kiel, Arnold Heller  
Strasse 7, 24105 Kiel, Germany  
Tel +49 0431 597 4411  
Fax +49 0431 597 1957  
Email [dosmonov@urology.uni-kiel.de](mailto:dosmonov@urology.uni-kiel.de)

**Introduction:** This paper reports treatment of a 76-hour low-flow priapism with a shunting procedure that was first described by Barry in 1976. We were able to observe the preservation of erectile function despite the long period of ischemia. A review of the literature shows that there are few reports of erectile function recovery after a priapism of similar duration.

**Materials and methods:** A 42-year-old patient presented with a 76-hour priapism, probably caused by consumption of alcohol and illegal drugs. A Barry Shunt procedure was performed. The erectile function of the patient was assessed by means of International Index of Erectile Function score over a follow-up period of 30 months. Moreover, we reviewed different surgical options for treatment of priapism in the literature.

**Results:** Partial return of erection without sexual arousal occurred on two occasions during the 10-day hospitalization, but was treated by manipulation of the penis, ie, by milking the tumescence into the shunt. After 3 months, the shunt was still palpable as a subcutaneous swelling. Six months postoperatively, the residual swelling had disappeared. The International Index of Erectile Function score was of 21 without phosphodiesterase type 5 inhibitors after a follow-up of 2.5 years.

**Conclusion:** Barry shunt is an effective alternative surgical option for the treatment of low-flow priapism. In the case of our patient, it was also effective after a 76-hour-lasting priapism.

**Keywords:** low flow priapism, erectile function, cavernovenous shunt, surgical treatment of stuttering priapism

## Introduction

The American Urological Association Guidelines describe priapism as:

a persistent penile erection that continues hours beyond, or is unrelated to, sexual stimulation. Typically, only the corpora cavernosa (CC) are affected. Subtypes of priapism include: ischemic (veno-occlusive, low flow) priapism, nonischemic (arterial, high flow) priapism, stuttering (intermittent) priapism.<sup>1</sup>

We report the case of a patient with a low-flow 76-hour-lasting priapism who was treated in our department by means of a shunting procedure first described by Barry in 1976.<sup>2</sup> Largely neglected today in favor of more distally constructed shunts, this operation anastomoses the transected superficial or deep dorsal vein of the penis to the corpora cavernosa (CC). We used the International Index of Erectile Function (IIEF score) to evaluate the treatment results in our patient. The patient was asked to answer the same five standard questions before and after surgery and during the follow-up.

The IIEF score was developed and validated in 1996–1997 as an adjunct to the sildenafil clinical trial program.<sup>3</sup> The IIEF score addresses the relevant domains of

male sexual function, ie, erectile function (EF), orgasmic function, sexual desire, intercourse satisfaction, and overall satisfaction. Moreover, the IIEF score demonstrates the sensitivity and specificity for detecting treatment-related changes in patients with erectile dysfunction (ED).<sup>3</sup>

A review of the literature shows only a small number of reports on EF recovery following 3–4 days of priapism.<sup>2–5</sup>

Alternative possibilities with the same principle of glans–CC shunt are well known. These techniques are based on a puncture or incision through the glans of the penis into the CC.<sup>6–8</sup> The incidence of ED after this type of surgery ranges between 15% and 50%.<sup>7–9</sup> Apart from the traditional ways of bridging, there are some variations of proximal shunts involving the use of a penile cavernosal–dorsal vein shunt technique using a saphenous vein graft.<sup>2–14</sup> The incidence of ED after this type of surgery is commonly 31%–66%.<sup>11,12</sup> However, the studies that describe distal and proximal shunt techniques are usually based on a limited number of patients.<sup>2–14</sup> In a study with 124 cases of priapism, only 31% of the patients who underwent conservative priapism treatment preserved their potency, compared to 69% of those treated with shunts.<sup>15</sup>

We chose the Barry shunt technique with an incision into the corpus spongiosum to avoid the relatively traumatic bridging; a further reason was that the young patient was categorically opposed to a trans-spongiosal access.

The technique of this procedure is relatively simple and allowed us, as well as the patient, to manually spread the venous flow through the Barry shunt. At 6 and 12 months after the surgery, we found no evidence of a venous leak or cavernous insufficiency. In our opinion, this easy-to-perform surgical technique carries fewer potential risks than other treatment options. Moreover, there was no evidence of either CC insufficiencies or ED after recovery.

## Materials and methods

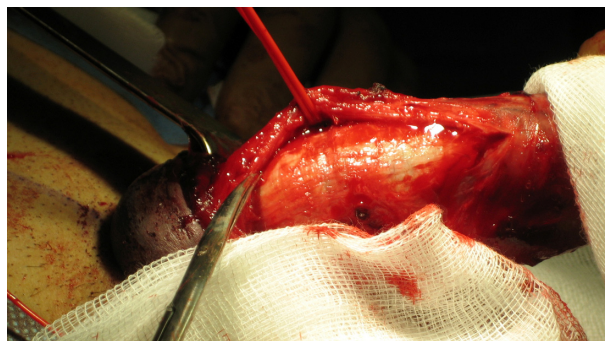
After inducement of general anesthesia, a Barry Shunt was constructed. Sulbactam and ampicillin were administered for antibiotic prophylaxis; urinary drainage was achieved with a Foley catheter; 3.5-fold magnification (Teleflex Incorporated, Research Triangle Park, NC, USA) helped to facilitate the operation. A circumcision incision was performed to deglove the penis. An 18-gauge needle was placed subcoronally and the stagnant blood was removed from the corpora. A second 18-gauge needle was passed into the proximal penis on the side contralateral to the first needle. The CC were then irrigated with heparinized saline until the effluent was bright red in contrast with the venous color of the priapism aspirate.

Buck's fascia was incised along the full length of the penis exposing the tunica albuginea and the neurovascular bundle (Figure 1). A 7 mm corporotomy between two stay sutures of 00 Vicryl (Ethicon, Johnson and Johnson, New Brunswick, NJ, USA) was performed where the previous proximal needle had been placed; the CC were irrigated again by injecting heparinized saline through the distal needle. The ipsilateral deep dorsal vein was clamped and then mobilized distal to the corporotomy over a distance of 3 cm. The vein was ligated distally and anastomosed to the corporotomy with a 5x0 PDS monofilament suture (Figure 2). After removing the clamp, the shunt's patency was determined by injecting heparinized saline through the distally placed needle (Figure 3). The penile skin was then replaced and the circumcision incision closed with a light compressive dressing.

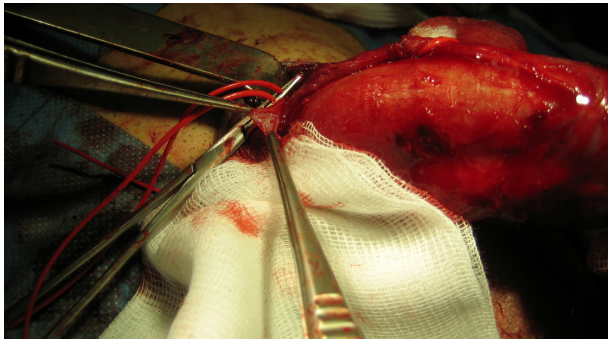
## Results

A 42-year-old patient presented with priapism that was evidently caused by consumption of alcohol and illegal drugs (Figure 4). Initially, the patient was treated by aspiration of 240 mL stagnant blood from the CC via a large bore needle. The aspiration was taken from the midshaft of the penis. Blood gas evaluation of the aspirate confirmed a low-flow priapism. In addition, serologic examination showed leucocytosis of 26,000 as well as evidence of benzodiazepine, alcohol, cannabis, and cocaine. After initial detumescence, the erection began to return, but the patient signed out against medical advice. He returned several hours later, however, with a reoccurrence of fully developed priapism. The erection had by then persisted for 76 hours. The patient reported an incidence of stuttering priapism in the past.

Partial return of erection without sexual arousal occurred on two occasions during the 10-day hospitalization, but was managed by manipulation of the penis, ie, by milking the tumescence into the shunt. After 3-months follow-up, the shunt was still palpable as a subcutaneous swelling.



**Figure 1** Preparation of the dorsal neurovascular bundle.



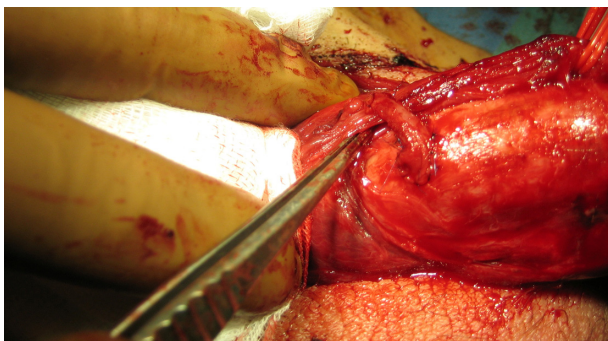
**Figure 2** Anastomosis between the penile deep dorsal vein and the corpus cavernosum.

After 6 months, the residual swelling had vanished. The IIEF-5 (international index of erectile function fifth edition) score of 21 points showed no or only mild ED, and a Doppler ultrasound examination following alprostadil did not show any evidence of vascular compromise. We recommended a low dose of phosphodiesterase type 5 inhibitors in combination with an on-demand regime to the patient.

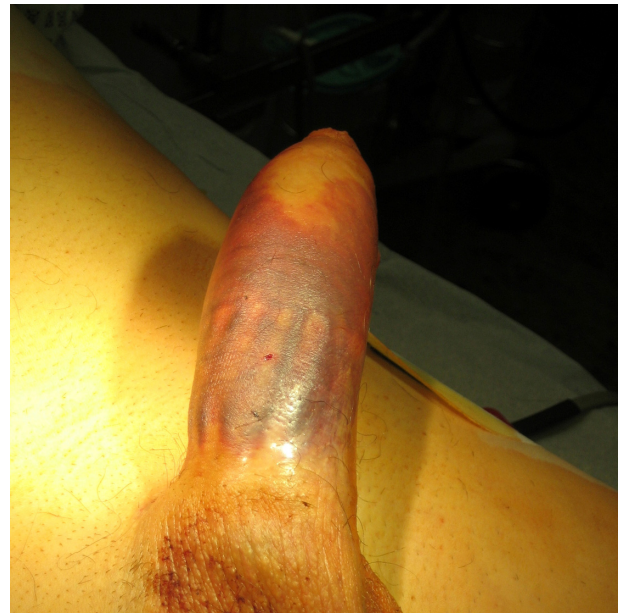No recurrence of priapism, and in particular also no stuttering priapism, was observed during the follow-up. Although the patient was not able to finance a phosphodiesterase type 5 inhibitor treatment, the patient still achieved an IIEF score of 21 points after 2.5 years.

## Discussion

In the current paper we describe a case of low-flow priapism treated after 76 hours of ischemia by a Barry shunt procedure and subsequent preservation of EF. This shunt connects the cavernosal wall to the dorsal vein of the penis and was first described in 1976.<sup>2</sup> In modern urology, utilization of this proximal shunting procedure for low-flow priapism has been largely discarded in favor of less invasive easier to perform distal shunting procedures uniting the CC with the corpus spongiosum. Simple puncturing or incision through the glans



**Figure 3** Barry shunt.



**Figure 4** Preoperative condition.

into the CC creates these shunts and they are simple enough to be accomplished under penile local anaesthesia.<sup>7,9</sup>

Most authorities believe that the period of ischemia is directly related to the incidence rate of post-priapism ED. Prolonged venous congestion causes hypoxia, glucopenia, and acidosis. These conditions cause deterioration of the erectile tissue to irreversible fibrosis.<sup>16</sup> There is no general agreement on the minimum time of ischemia causing irreversible ED; studies on rabbits have shown that conservative treatments such as alpha adrenergic drugs fail to prevent irreversible smooth muscle damage of the erectile tissue if the ischemia persists more than 4 hours.<sup>17</sup> After 4 hours, intra-cavernosus injection of vasoactive agents or a shunting procedure is required.

In clinical practice, Kulmala et al found that young patients could recover potency after 24 hours of ischemia, while only 40% of patients aged >50 years had post priapism erections.<sup>15</sup> Similar findings of El-Bahnasawy showed that only 43% of the patients preserved erections, and that this was more likely if the priapism had lasted less than 48 hours.<sup>18</sup>

There are only few reports in the literature describing preserved EF after 3–4 days of priapism.<sup>4,18,19</sup> Low-flow priapism for over 48 hours, failure to maintain complete detumescence after management, and marked penile fibrosis during the follow-up are the most significant risk factors responsible for ED.<sup>18</sup> In some institutions, this leads to immediate insertion of penile prosthesis in men presenting with 48 to >72 hour ischemic priapism that is refractory to aspiration and injection.<sup>20</sup>



We chose the Barry shunt in this young patient to improve his chances of regaining potency, and to avoid scarring the glans penis as well as the risk of disrupting the distal tunica albuginea. The latter two conditions are common in all distal shunting procedures.

There is no paper in the literature that describes an outcome of Barry shunt after 76 hours priapism. We have included this technique in our routine and use proximal shunting in a selected group of patients, especially in patients with stuttering priapism.<sup>21</sup> Data from three further patients who underwent Barry shunt procedures at our department is available. We plan to analyze the surgical outcome in these cases after pursuant follow-up. The general line of argumentation points out that distal shunting is an easier type of surgery with relatively good clinical long-term outcomes. So why propose a different way? Our aim was not to replace the more useful distal shunts by proximal ones in general. Moreover, in our daily practice we do use a T-shunt procedure with corporal tubularization and corporal snake maneuvers.<sup>7,9</sup> We just wanted to show that there is an alternative surgical technique and report a case of preserved EF after priapism lasting as long as 76 hours. The following conclusions can be drawn: 1) proximal shunting could be an alternative surgical option; 2) it has been shown to be effective even after a 76-hour priapism; and 3) this technique enables the patient to milk the tumescence into the shunt in case the priapism returns within the initial post-surgical period. The third aspect could be of particular interest for the treatment of stuttering priapism. We have been encouraged by the fact that the patency of the shunt persisted for up to 6 months in our patient during the postoperative period. At 30 months, the patient was potent and did not show any signs of vascular insufficiency on Doppler.

While recommending the distal rather than the proximal shunt in most cases of daily practice, we believe that the proximal techniques, in particular the Barry shunt technique, should be given credit. The proximal technique is generally believed to be an obsolete type of unnecessarily complex surgery compared to the distal technique. However, according to our experience, this type of surgery can easily be done by an experienced surgeon even if they have never performed the proximal technique before.<sup>2</sup> Taking into account the good long-term outcome, this method can be seen as a valid secondary alternative to the distal technique.

## Conclusion

Barry shunt is an effective alternative surgical option for treatment of low-flow priapism, especially in its stuttering form.

In our case, it was effective in a patient with an over 76-hour-lasting priapism. This surgical technique is relatively simple to perform and, in our opinion, the associated risks are lower than with other treatment options. There was no evidence of CC insufficiencies or ED after 2.5-years follow-up.

## Disclosure

The authors report no conflicts of interest in this work.

## References

1. Erectile Dysfunction Guideline Update Panel. The management of priapism. Baltimore (MD): American Urological Association, Inc.; 2003. Available from: <http://www.guideline.gov/content.aspx?id=3741>. Accessed May 29, 2014.
2. Barry JM. Priapism: treatment with corpus cavernosum to dorsal vein of penis shunts. *J Urol*. 1976;116(6):754–756.
3. Rosen RC, Riley A, Wagner G, Osterloh IH, Kirkpatrick J, Mishra A. The international index of erectile function (IIEF): a multidimensional scale for assessment of erectile dysfunction. *Urology*. 1997;49(6):822–830.
4. Minardi D, Milanese G, Galosi AB, Donatelli G, Muzzonigro G. Persistent priapism and histological modifications of the erectile tissue. Two case reports. *Arch Ital Urol Androl*. 2004;76(2):97–99.
5. Chiou RK, Aggarwal H, Mues AC, Chiou CR, Broughton FL. Clinical experience and sexual function outcome of patients with priapism treated with penile cavernosal-dorsal vein shunt using saphenous vein graft. *Urology*. 2009;73(3):556–561.
6. Winter CC. Cure of idiopathic priapism: a new procedure for creating fistula between glans penis to corpora cavernosum. *Urology*. 1976;8:389–391.
7. Garcia MM, Shindel AW, Lue TF. T-shunt with or without tunnelling for prolonged ischaemic priapism. *BJU Int*. 2008;102(11):1754–1764.
8. Sacher EC, Sayegh E, Frensilli F, Crum P, Akers R. Cavernospongiosum shunt in the treatment of priapism. *J Urol*. 1972;108:97–100.
9. Tabibi A, Abdi H, Mahmoudnejad N. Erectile function and dysfunction following low flow priapism: a comparison of distal and proximal shunts. *Urol J*. 2010;7(3):174–177.
10. Burnett AL, Pierorazio PM. Corporal “snake” maneuver: corporoglanular shunt surgical modification for ischemic priapism. *J Sex Med*. 2009;6(4):1171–1176.
11. Grayhack JT, McCullough W, O’Conor VJ Jr, Trippel O. Venous bypass to control priapism. *Invest Urol*. 1964;1:509–513.
12. Lunglmayr G, Nachtigall M, Gindl K. Long-term results of deep dorsal penile vein transection in venous impotence. *Eur Urol*. 1988;15(3–4):209–212.
13. Vázquez Alonso F, Vicente Prados FJ, Fernández Sánchez A, et al. [Low flow priapism. Treatment by sapheno-cavernous shunt]. *Arch Esp Urol*. 2007;60(3):300–303. Spanish.
14. Odelowo EO. A new caverno-spongiosum shunt with saphenous vein patch graft for established priapism. *Int Surg*. 1988;73(2):130–132.
15. Kulmala RV, Lehtonen TA, Tammela TL. Preservation of potency after treatment for priapism. *Scand J Urol Nephrol*. 1996;30(4):313–316.
16. Spycher MA, Hauri D. The ultrastructure of the erectile tissue in priapism. *J Urol*. 1986;135(1):142–147.
17. Broderick GA, Gordon D, Hypolite J, Levin RM. Anoxia and corporal smooth muscle dysfunction: a model for ischemic priapism. *J Urol*. 1994;151(1):259–262.
18. El-Bahnasawy MS, Dawood A, Farouk A. Low-flow priapism: risk factors for erectile dysfunction. *BJU Int*. 2002;89(3):285–290.
19. Nixon RG, O’Connor JL, Milam DF. Efficacy of shunt surgery for refractory low flow priapism: a report on the incidence of failed detumescence and erectile dysfunction. *J Urol*. 2003;170(3):883–886.

20. Ralph DJ, Garaffa G, Muneer A, et al. The immediate insertion of a penile prosthesis for acute ischaemic priapism. *Eur Urol.* 2009;56(6): 1033–1038.
21. Muneer A, Minhas S, Arya M, Ralph DJ. Stuttering priapism – a review of the therapeutic options. *Int J Clin Pract.* 2008;62(8): 1265–1270.

### Research and Reports in Urology

Dovepress

### Publish your work in this journal

Research and Reports in Urology is an international, peer-reviewed, open access journal publishing original research, reports, editorials, reviews and commentaries on all aspects of adult and pediatric urology in the clinic and laboratory including the following topics: Pathology, pathophysiology of urological disease; Investigation and treatment of

urological disease; Pharmacology of drugs used for the treatment of urological disease. The manuscript management system is completely online and includes a very quick and fair peer-review system, which is all easy to use. Visit <http://www.dovepress.com/testimonials.php> to read real quotes from published authors.

Submit your manuscript here: <http://www.dovepress.com/research-and-reports-in-urology-journal>