



Since January 2020 Elsevier has created a COVID-19 resource centre with free information in English and Mandarin on the novel coronavirus COVID-19. The COVID-19 resource centre is hosted on Elsevier Connect, the company's public news and information website.

Elsevier hereby grants permission to make all its COVID-19-related research that is available on the COVID-19 resource centre - including this research content - immediately available in PubMed Central and other publicly funded repositories, such as the WHO COVID database with rights for unrestricted research re-use and analyses in any form or by any means with acknowledgement of the original source. These permissions are granted for free by Elsevier for as long as the COVID-19 resource centre remains active.



ELSEVIER

**BIAM**  
British Infection Association

[www.elsevierhealth.com/journals/jinf](http://www.elsevierhealth.com/journals/jinf)

REVIEW

# Zika fever and congenital Zika syndrome: An unexpected emerging arboviral disease



Jasper F.W. Chan <sup>a,b,c,d</sup>, Garnet K.Y. Choi <sup>d</sup>, Cyril C.Y. Yip <sup>d</sup>,  
Vincent C.C. Cheng <sup>d</sup>, Kwok-Yung Yuen <sup>a,b,c,d,\*</sup>

<sup>a</sup> State Key Laboratory of Emerging Infectious Diseases, The University of Hong Kong, Hong Kong Special Administrative Region, China

<sup>b</sup> Carol Yu Centre for Infection, The University of Hong Kong, Hong Kong Special Administrative Region, China

<sup>c</sup> Research Centre of Infection and Immunology, The University of Hong Kong, Hong Kong Special Administrative Region, China

<sup>d</sup> Department of Microbiology, The University of Hong Kong, Hong Kong Special Administrative Region, China

Accepted 20 February 2016  
Available online 3 March 2016

## KEYWORDS

Zika;  
Virus;  
Flavivirus;  
Arbovirus;  
Microcephaly;  
*Aedes*;  
Mosquito

**Summary** Unlike its mosquito-borne relatives, such as dengue, West Nile, and Japanese encephalitis viruses, which can cause severe human diseases, Zika virus (ZIKV) has emerged from obscurity by its association with a suspected “congenital Zika syndrome”, while causing asymptomatic or mild exanthematous febrile infections which are dengue- or rubella-like in infected individuals. Despite having been discovered in Uganda for almost 60 years, <20 human cases were reported before 2007. The massive epidemics in the Pacific islands associated with the ZIKV Asian lineage in 2007 and 2013 were followed by explosive outbreaks in Latin America in 2015. Although increased mosquito breeding associated with the El Niño effect superimposed on global warming is suspected, genetic changes in its RNA virus genome may have led to better adaptation to mosquitoes, other animal reservoirs, and human. We reviewed the epidemiology, clinical manifestation, virology, pathogenesis, laboratory diagnosis, management, and prevention of this emerging infection. Laboratory diagnosis can be confounded by cross-reactivity with other circulating flaviviruses. Besides mosquito bite and transplacental transmission, the risk of other potential routes of transmission by transfusion, transplantation, sexual activity, breastfeeding, respiratory droplet, and animal bite is discussed. Epidemic

\* Corresponding author. State Key Laboratory of Emerging Infectious Diseases, Carol Yu Centre for Infection, Department of Microbiology, The University of Hong Kong, Queen Mary Hospital, 102 Pokfulam Road, Pokfulam, Hong Kong Special Administrative Region, China. Tel.: +852 22554892; fax: +852 28551241.

E-mail address: [kyyuen@hku.hk](mailto:kyyuen@hku.hk) (K.-Y. Yuen).

control requires adequate clearance of mosquito breeding grounds, personal protection against mosquito bite, and hopefully a safe and effective vaccine.

© 2016 The British Infection Association. Published by Elsevier Ltd. All rights reserved.

## Introduction

Globalisation and urbanisation with increasingly frequent and large-scale movements of humans, animals, and commodities by aviation and water transport has led to the spread of previously geographically-restricted microbes and vectors to distant and isolated places.<sup>1</sup> Recent examples of emerging viruses that have spilled over to other continents from their original localities via exportation of travel-related cases include coronaviruses (severe acute respiratory syndrome coronavirus and Middle East respiratory syndrome coronavirus), influenza viruses, and Ebola virus.<sup>2–11</sup> Moreover, global warming and climate changes have redefined the geographical distributions of important vectors of arthropod-borne viruses (arboviruses), such as the *Aedes* mosquitoes, and facilitated the global spread of these viruses. Dengue virus (DENV), West Nile virus (WNV), and Chikungunya virus (CHIKV), have been introduced (WNV in 1999 and CHIKV in 2013) and/or spread rapidly in the western hemisphere in the past two decades.<sup>12</sup> Zika virus (ZIKV) is an arbovirus that was little known before it caused a large outbreak on Yap Island of the Federated States of Micronesia in 2007.<sup>13</sup> Even then, ZIKV was not considered as an important emerging pathogen because clinical disease was generally mild. The recent report of a possible association between ZIKV infection and an epidemic of microcephaly among neonates in Brazil has attracted global attention.<sup>14</sup> The rapid spread of ZIKV beyond Africa and Asia to the Americas and Europe, and the potentially novel “congenital Zika syndrome” outbreak have led the World Health Organisation (WHO) to declare the ZIKV epidemic as a global public health emergency on 1 February 2016.<sup>15</sup> It would therefore be important to review the current knowledge on the epidemiology, virology, clinical manifestations, and laboratory diagnosis of ZIKV infection, and most importantly, to formulate clinical management options with special reference to perinatal care and control measures based on comparisons made with other mosquito-borne arboviruses.

## History and epidemiology

### Important historical and epidemiological events

ZIKV (strain MR 766) was first isolated from the blood of a febrile sentinel rhesus monkey (*Macaca mulatta*), Rhesus 766, during a study on yellow fever virus (YFV) in Zika Forest of Uganda in April 1947 (Table 1).<sup>16</sup> In 1948, ZIKV was isolated from *Aedes africanus* mosquitoes caught in Zika Forest, suggesting that the virus might be mosquito-borne. In 1954, ZIKV was isolated from the serum of a 10-year-old Nigerian girl who had fever and headache, implying its role as a possible human pathogen.<sup>17</sup> Further virological and/or serological evidence of human ZIKV infection was reported in African

(Uganda, Tanzania, Egypt, Central African Republic, Sierra Leone, and Gabon) and Asian (India, Malaysia, the Philippines, Thailand, Vietnam, and Indonesia) countries.<sup>18–26</sup> ZIKV infection remained relatively restricted geographically with less than 20 sporadic cases reported in these areas in the first 60 years after its discovery.<sup>13,27</sup> In 2007, ZIKV emerged outside Africa and Asia for the first time and caused a major outbreak on Yap Island of the Federated State of Micronesia.<sup>13</sup> Over 70% of the Yap residents who were  $\geq 3$  years were infected within 4 months.<sup>13</sup> The attack rate of ZIKV infection in this outbreak was 14.6 per 1000 residents (range, 3.5–21.5 per 1000 residents). Subsequently, another major outbreak was reported in French Polynesia in October 2013. An estimated 30,000 humans ( $>11\%$  of the French Polynesian population) were infected by ZIKV. ZIKV infection then spread from French Polynesia to other Pacific Islands including New Caledonia, Cook Islands, Vanuatu, and Solomon Islands.<sup>27–30</sup> The first cases of human ZIKV infection in the western hemisphere occurred on Easter Island, Chile, in February 2014, possibly originating from French Polynesia during the annual Tapati festival.<sup>31</sup> Phylogenetic analysis revealed that the NS5 gene sequence of the Chilean strains had  $\geq 99.8\%$  nucleotide and 100% amino acid identity to the French Polynesian strains.<sup>31</sup> The epidemic continued to expand rapidly and autochthonous human cases were reported in many Latin American countries in the ensuing 2 years.<sup>32</sup>

Brazil stands out as the hardest hit Latin American country with an estimated 500,000–1,500,000 cases of ZIKV infection since March 2015.<sup>33</sup> Based on the close phylogenetic relationship between the South American strains and Asian and Oceanic strains of ZIKV, the virus might have been introduced into Brazil by Asian travellers during the World Cup or participants from the Oceanic countries of the Va'a World Sprint Championship canoe race in the summer of 2014.<sup>30,34–36</sup> The climate changes associated with El Niño in north and eastern South America in 2015 on the background trend of global warming might have facilitated the rapid spread of *Aedes* mosquitoes and ZIKV.<sup>37</sup> Currently,  $>30$  countries in Africa, Asia, South America, Oceania, and Micronesia have reported autochthonous cases of human ZIKV infection.<sup>38</sup> Travel-related cases from endemic and epidemic regions were also reported in Europe, North America, Australia, and Japan.<sup>39–50</sup>

More worryingly, the Brazil Health Ministry reported the detection of an unusual increase in the number of cases of neonates with microcephaly in northeastern Brazil in October 2015, coinciding with the expanding ZIKV infection epidemic.<sup>14</sup> Over 3000 suspected cases including some fatal cases were reported during the second half of 2015 alone.<sup>14</sup> This represented a  $>20$ -fold increase in the rate of microcephaly as compared to previous years.<sup>32</sup> On 24 November 2015, the French Polynesia health authorities also reported an unusual increase in the number of foetal and neonatal central nervous system malformations in 2014 and 2015.<sup>51</sup>

**Table 1** Sequence of events with epidemiological importance related to the ZIKV epidemic.

Dates	Locations	Events	References
April 1947	Uganda	The first isolation of ZIKV from a febrile sentinel rhesus monkey (Rhesus 766).	16
1947–1948	Uganda	The first detection of neutralising antibodies to ZIKV in sentinel rhesus monkeys.	16, 54
January 1948	Uganda	The first isolation of ZIKV from <i>Aedes africanus</i> ; mice inoculated intracerebrally with unfiltered supernatant of ZIKV-infected <i>Ae. africanus</i> became sick.	16, 59
1952 (archived samples)	Uganda	The first report of serum neutralising antibodies to ZIKV being detected in man in Uganda.	54
1954	Nigeria	The first isolation of ZIKV from human serum.	17
1956	Nigeria	ZIKV was successfully transmitted from artificially fed <i>Ae. aegypti</i> mosquitoes to mice and a monkey in laboratory setting.	55
1964	Uganda	The first well-documented report of occupationally-acquired (medical entomologist) human ZIKV infection.	117
1960–2006	Africa and Asia	<20 sporadic cases reported in the literature; all in African and Asian countries.	19, 68, 118, 146
2007–2008	Yap Island, FSM	The first major ZIKV epidemic in an urban region with ~73% of the Yap population being infected in 4 months.	13
2009–2012	Africa, Asia, Europe, North America, and Australia	A small number of cases (including travel-related cases) reported.	39–41, 43, 47, 118, 147
October 2013	French Polynesia and other Pacific islands	The second major outbreak reported in the Pacific region with an estimated 30,000 persons (>11% of the population) being infected; subsequently spread to other Pacific Islands including New Caledonia, Cook Islands, Vanuatu, Solomon Islands, and Easter Island.	28, 114, 147–149
March 2015	Brazil	The first autochthonous cases reported in Brazil; total estimated cases in Brazil ~500,000–1,500,000.	116, 121, 150, 151
October 2015	Brazil	An unusual increase in cases of neonates with microcephaly in northeastern Brazil with ~3000 cases including deaths (~20-fold increase in microcephaly rate from 2010).	14
October 2015	South America	Autochthonous cases reported in other South American countries.	51
1 February 2016	WHO	WHO declared the Zika virus epidemic as a global public health emergency.	15
5 February 2016	Global	>30 countries in Africa, Asia, Latin America, and Oceania/Pacific islands, have reported autochthonous cases; and imported cases are reported in Europe and North America.	32, 38, 121

Abbreviations: FSM, Federated State of Micronesia; WHO, World Health Organisation; ZIKV, Zika virus.

## Routes of transmission

Like other flaviviruses, ZIKV is mainly transmitted by mosquitoes. In addition to the sylvatic (enzootic) transmission cycle between the haematophagous mosquito vectors and susceptible primary vertebrate hosts, the recent large-scale epidemics suggest that ZIKV is also adapting to an urban transmission cycle.<sup>52,53</sup> Among the various mosquito species, *Aedes* (*Stegomyia*) mosquitoes appear to be the most important vector for ZIKV transmission, although some *Anopheles*, *Culex*, *Eretmapodites*,

and *Mansonia* species have also been proposed as possible vectors (Table 2).<sup>25,52,54–69</sup> The animal reservoirs of ZIKV are unclear. Non-human primates including *M. mulatta*, *Cercopithecus aethiops*, *C. ascanius schmidtii*, *C. mona denti*, *C. albigena johnstoni*, *Chlorocebus sabaeus*, *Colobus abyssinicus*, *Erythrocebus patas*, and *Pongo pygmaeus*, and other mammals including zebras, elephants, and rodents, have been suggested as possible vertebrate hosts of ZIKV in Africa and Asia, based on virological and/or serological evidence of infection.<sup>16,54,65,68,70–72</sup> *Ae. africanus* is the first mosquito species from which ZIKV was isolated, and

**Table 2** Mosquito species which are potential vectors for the transmission of ZIKV.

Mosquito species	Findings	References
<b>Genus <i>Aedes</i></b>		
<i>Ae. aegypti</i>	Considered as the primary vector for ZIKV transmission; natural infection reported. <i>In vitro</i> : susceptible to ZIKV infection with a short extrinsic incubation period of 5 days.	25, 55–58
<i>Ae. africanus</i>	Natural infection: first mosquito species from which ZIKV was isolated from.	52, 54, 59
<i>Ae. albopictus</i>	Natural infection: <i>Ae. albopictus</i> reported (Gabon). <i>In vitro</i> : can be infected by and transmit >20 different arboviruses including ZIKV.	61–64
<i>Ae. apicoargenteus</i> , <i>Ae. flavicollis</i> , <i>Ae. fowleri</i> , <i>Ae. furcifer</i> , <i>Ae. grahami</i> , <i>Ae. hirsutus</i> , <i>Ae. jamoti</i> , <i>Ae. metallicus</i> , <i>Ae. minutus</i> , <i>Ae. neoaffricanus</i> , <i>Ae. opok</i> , <i>Ae. taeniarostris</i> , <i>Ae. tarsalis</i> , <i>Ae. taylori</i> , <i>Ae. vittatus</i>	Natural infection reported.	25, 52, 57, 69, 100
<i>Ae. dalzieli</i>	Natural infection reported; phylogenetic analysis shows evidence to support its role as an important vector for ZIKV transmission in West Africa.	52
<i>Ae. hensilli</i>	Susceptible to ZIKV infection <i>in vitro</i> ; the most abundant mosquito species on Yap Island (but no virus isolation was made from field-collected mosquitoes).	67
<i>Ae. luteocephalus</i> , <i>Ae. vittatus</i>	Natural infection reported; exhibited potential to transmit ZIKV <i>in vitro</i> .	25, 52, 57
<i>Ae. unilineatus</i>	Natural infection reported; susceptible to ZIKV infection <i>in vitro</i> .	25, 52
<b>Genus <i>Anopheles</i></b>		
<i>An. coustani</i> , <i>An. gambiae s.l.</i>	Natural infection reported.	25, 52
<b>Genus <i>Culex</i></b>		
<i>Cx. perfuscus</i>	Natural infection reported.	52
<b>Genus <i>Mansonia</i></b>		
<i>Ma. uniformis</i>	Natural infection reported.	52
<b>Genus <i>Eretmapodites</i></b>		
<i>Er. inornatus</i> , <i>Er. quinquevittatus</i>	Natural infection reported.	100

Abbreviations: ZIKV, Zika virus.

is likely an important vector in the sylvatic transmission cycle of ZIKV.<sup>16,54</sup> Inoculation of unfiltered supernatant of ZIKV-infected *Ae. africanus* into mice and rhesus macaques led to clinical disease and/or neutralising antibody response.<sup>16,54</sup> *Ae. hensilli* is the most commonly found mosquito species on Yap Island, but no virus isolate was made from field-collected mosquitoes to ascertain its role as a vector for ZIKV transmission during the outbreak.<sup>67</sup> *Ae. aegypti* and *Ae. albopictus*, which have much wider geographical distributions than other *Aedes* mosquitoes, are considered to be more important vectors in the urban transmission cycle of ZIKV.<sup>73</sup> These *Aedes* mosquitoes are highly susceptible to ZIKV infection *in vitro* with potential for further transmission after an extrinsic incubation period of 5–10 days.<sup>58,63</sup> They bite both indoors and outdoors, and mostly during daytime.<sup>74</sup>

Non-vector-borne transmission routes of ZIKV have been proposed (Table 3). Like other arboviruses, blood transfusion-related transmission of ZIKV is possible, especially in endemic regions or where blood products obtained from infected travellers immediately returning from endemic regions are used. ZIKV RNA was detected in the blood of 2.8% of the donors in French Polynesia during the epidemic.<sup>75</sup> Sexual transmission of ZIKV appears highly probable, especially in patients presenting with haematospermia with infectious viral particles and RNA in semen.<sup>76,77</sup> Notably, no other arboviruses have been associated with haematospermia or isolated from human semen.<sup>76</sup> This might further complicate the control of the ZIKV epidemic, since most infected patients are asymptomatic. Inadvertent sexual transmission of ZIKV to the female partner may then lead to virus transmission to the foetus, which may be potentially associated with severe congenital anomalies. Besides transplacental transmission, perinatal transmission of ZIKV may also occur during delivery, via breastfeeding, and/or close contact after birth via exchange of saliva and other bodily fluids. ZIKV RNA could be detected in breast milk and saliva of infected women, although replicative virus particles have not been demonstrated.<sup>78,79</sup> Perinatal transmission of other arboviruses, including DENV, CHIKV, WNV, and YFV, has also been reported.<sup>80–90</sup> Other suspected routes of transmission of ZIKV infection are those reported for other flaviviruses. These include mucocutaneous exposure to the virus in infected blood or via monkey bite, haemodialysis, or organ transplantation.<sup>91–96</sup> Particularly, as ZIKV may be shed in the urine of infected patients for more than 30 days, the risk to recipients of donated kidneys from donors at or returning from endemic areas has to be considered.<sup>40,41,49,50,97</sup> It is unknown whether ZIKV could be transmitted via respiratory droplets as viral RNA could occasionally be detected in nasopharyngeal swab and saliva samples.<sup>40,78,79,96</sup>

## Virology and pathogenesis

ZIKV is an enveloped, positive-sense, single-stranded RNA virus belonging to the genus *Flavivirus* in the family *Flaviviridae*. It is closely related to Spondweni virus and the 2 viruses represent the only members of their clade within the mosquito-borne cluster of flaviviruses (Fig. 1).<sup>98,99</sup>

Phylogenetic analysis suggests that ZIKV has likely emerged between 1892 and 1943 in Uganda.<sup>66</sup> The two major lineages of ZIKV are the African (subdivided into West and East African) and Asian lineages, which are responsible for causing the majority of infections in Africa and Asia (as well as the Pacific and Americas), respectively.<sup>34,69,100</sup> The single-stranded RNA genome of ZIKV has a size of 10,794 nucleotides encoding 3419 amino acids, with 2 flanking untranslated regions (5' and 3' UTRs) and a single long open reading frame encoding a polyprotein, which is cleaved into capsid (C), precursor of membrane (prM), envelope (E), and 7 non-structural (NS) proteins (5'-C-prM-E-NS1-NS2A-NS2B-NS3-NS4A-NS4B-NS5-3').<sup>66,101</sup> Reverse transcription-polymerase chain reaction (RT-PCR) using primers targeting the E or NS5 gene is a key laboratory diagnostic tool for ZIKV infection in the recent outbreaks.<sup>13,102,103</sup> The E protein is a major virion surface protein that is involved in receptor binding and membrane fusion. The domain III of E protein contains a panel of antigenic epitopes that are important targets of serological assays, neutralising antibodies, and vaccines.<sup>104,105</sup> Loss of the N154 glycosylation site in the E protein may be associated with adaptation to mosquito vectors and thus facilitate transmission.<sup>66</sup> A single amino acid mutation in the E protein (E1-A226V) of CHIKV has been reported to be associated with increased fitness of the virus in *Ae. albopictus* and allows CHIKV to disseminate in regions lacking the typical *Ae. aegypti* vector.<sup>106</sup> The recent spread of the Asian lineage of ZIKV to Oceania and the Americas may be associated with significant NS1 codon usage adaptation to human housekeeping genes, which could facilitate viral replication and increase viral titres.<sup>107</sup> Mutations in the E and NS1 genes should be detected in ZIKV strains causing the current epidemic.

When an infected *Aedes* mosquito bites an infected patient, it ingests a blood meal containing ZIKV. As in other flaviviruses, ZIKV likely replicates in the midgut epithelial cells and subsequently the salivary gland cells. After an extrinsic incubation period of 5–10 days, ZIKV can be found in the mosquito's saliva which can then infect human.<sup>58,63</sup> Moreover, the virus can likely be vertically transmitted transovarially as other flaviviruses. When the mosquito's saliva containing ZIKV is inoculated into human skin, the virus can infect epidermal keratinocytes, skin fibroblasts in the subcutaneous layer, and the Langerhans cells.<sup>108</sup> The keratinocytes and fibroblasts contain AXL, Tyro3, and TIM-1, which can serve as attachment factors or receptors for ZIKV. The Langerhans cells contain DC-SIGN, which can also serve as a receptor for virus entry.<sup>108</sup> ZIKV infection of primary skin fibroblasts is associated with the upregulation with TLR3 mRNA expression, and enhanced transcription of RIG-I and MDA5, which are known innate immune responses to RNA virus infection. This is followed by enhanced expression of interferon-alpha and -beta, and their downstream pathways of immune activation. Both types I and II interferons can suppress the viral load of infected cells. Moreover, ZIKV is capable of increasing its replication by the induction of autophagy in host cells. Thus, autophagy inhibitors can decrease the viral load of infected cells.<sup>109</sup> Infected cells of human skin explant exhibits cytoplasmic vacuolation, pyknotic nuclei, and oedema in the stratum granulosum.<sup>108</sup> After replication in



**Table 3** Potential non-vector-borne routes of transmission of ZIKV.

Transmission routes	Findings	Specific control measures	References
Blood transfusion	<ul style="list-style-type: none"> <li>• 2.8% (42/1505) of asymptomatic blood donors in French Polynesia (21 November 2013–17 February 2014) tested positive for ZIKV by RT-PCR.</li> </ul>	<ul style="list-style-type: none"> <li>• Endemic/epidemic areas: <ul style="list-style-type: none"> <li>◦ Universal nucleic acid testing of blood donors.</li> <li>◦ Temporary discontinuation of blood donation (Importation of blood products from blood bank centres in non-endemic regions).</li> </ul> </li> <li>• Non-endemic/epidemic areas: <ul style="list-style-type: none"> <li>◦ Pre-donation questionnaire to identify donors with recent travel history to endemic/epidemic areas.</li> <li>◦ Deferral of blood donors who have travelled to endemic areas within the preceding <math>\geq 14</math> days.</li> <li>◦ Self-reporting of symptoms after blood donation (11/42 ZIKV-RT-PCR-positive donors developed symptoms 3–10 days after blood donation).</li> </ul> </li> </ul>	75
Semen	<ul style="list-style-type: none"> <li>• ZIKV was isolated by RT-PCR and viral culture (Vero cells) from the semen of a patient from French Polynesia (Tahiti) who presented with haematospermia.</li> <li>• An American scientist acquired ZIKV infection in Senegal and developed prostatitis and haematospermia. After he returned to USA, his wife (never travelled to Africa and Asia) developed symptoms and serological evidence of ZIKV infection after having sexual intercourse with the index patient.</li> <li>• The viral load in semen (<math>10^7</math> copies/ml) may be higher than that in the concomitant urine (<math>10^3</math> copies/ml) and serum (undetectable) samples, and may last for <math>\geq 62</math> days.</li> </ul>	<ul style="list-style-type: none"> <li>• Endemic/epidemic areas: <ul style="list-style-type: none"> <li>◦ Use barrier methods unless trying to conceive.</li> </ul> </li> <li>• Non-endemic/epidemic areas: <ul style="list-style-type: none"> <li>◦ Individuals returning from endemic/epidemic areas should use barrier methods.</li> </ul> </li> </ul>	76, 77
Perinatal/Transplacental	<ul style="list-style-type: none"> <li>• At least 2 episodes of perinatal transmission reported in French Polynesia.</li> <li>• Preliminary epidemiological and virological evidence support transplacental transmission of ZIKV leading to microcephaly and other congenital anomalies.</li> </ul>	<ul style="list-style-type: none"> <li>• Endemic/epidemic areas: <ul style="list-style-type: none"> <li>◦ Avoid mosquito bites.</li> <li>◦ Interval ultrasound assessment for prompt detection of intrauterine complications.</li> <li>◦ Some authorities advise women to delay becoming pregnant for at least 6–12 months.</li> </ul> </li> <li>• Non-endemic/epidemic areas: <ul style="list-style-type: none"> <li>◦ Avoid or defer travelling to endemic/epidemic areas.</li> <li>◦ Avoid mosquito bites.</li> </ul> </li> </ul>	14, 78, 144
Breastfeeding	<ul style="list-style-type: none"> <li>• Breast milk samples of infected women inoculated on Vero cells were positive for viral RNA by RT-PCR, but replicative virus particles were not detected.</li> </ul>	<ul style="list-style-type: none"> <li>• Defer breastfeeding in infected mothers until virus clearance in breast milk and bodily fluids (eg: blood, urine, and saliva).</li> </ul>	78
Saliva	<ul style="list-style-type: none"> <li>• Viral RNA can be detected in saliva of infected patients, but it is unknown whether replicative virus particles can be detected.</li> </ul>	<ul style="list-style-type: none"> <li>• Avoid exposure to saliva of infected patients until virus clearance.</li> </ul>	78, 79

Monkey bite			96
Others (reported for other flaviviruses)	<ul style="list-style-type: none"> <li>• Suspected transmission after monkey bite.</li> <li>• Mucocutaneous: DENV and WNV</li> <li>• Haemodialysis: WNV</li> <li>• Organ transplantation (HSCT and SOT): DENV and WNV</li> </ul>	<ul style="list-style-type: none"> <li>• Avoid contact with infected animals.</li> <li>• Avoid mucocutaneous exposure to infected patients' blood and bodily fluids.</li> <li>• Questionnaire to identify patients with recent travel history to endemic areas.</li> <li>• Virological testing ± use of a separate haemodialysis machine.</li> <li>• Donated organs, especially kidneys, from individuals with travel history to affected areas should be tested for ZIKV as the virus may persist in the genitourinary tract for an undetermined period.</li> </ul>	91, 92 95 93, 94
Abbreviations: DENV, Dengue virus; HSCT, haematopoietic stem cell transplantation; SOT, solid organ transplantation; WNV, West Nile virus; ZIKV, Zika virus.			

these local tissue cells and the regional lymph nodes, ZIKV may then disseminate from the lymphatics and bloodstream to reach other organs/tissues, including the central nervous system, the skeletal muscles, myocardium, and perhaps transplacentally to the foetus. ZIKV was highly neurotropic in infected suckling mice. The brains of infected suckling mice show neuronal degeneration, cellular infiltration, and softening in the brain with virus replication in astroglial cells and neurons on histopathological examination.<sup>16,54,110</sup> Moreover, evidence of inflammation in skeletal muscles and myocardium has also been demonstrated in infected suckling mice.<sup>111</sup> AXL and Tyro3 are members of the TAM family of receptor tyrosine kinases (RTKs). They are also present in neurons and under the influence of gonadotropin releasing hormone (GrH), which in turn may affect neuronal survival and migration. Furthermore, flaviviruses such as YFV may persist for up to 159 days after intracerebral inoculation in rhesus macaques.<sup>112</sup> The neurotropism and persistence of ZIKV may therefore partially explain microcephaly and predominantly neurological complications and foetal anomalies in this suspected entity of congenital ZIKV infection.

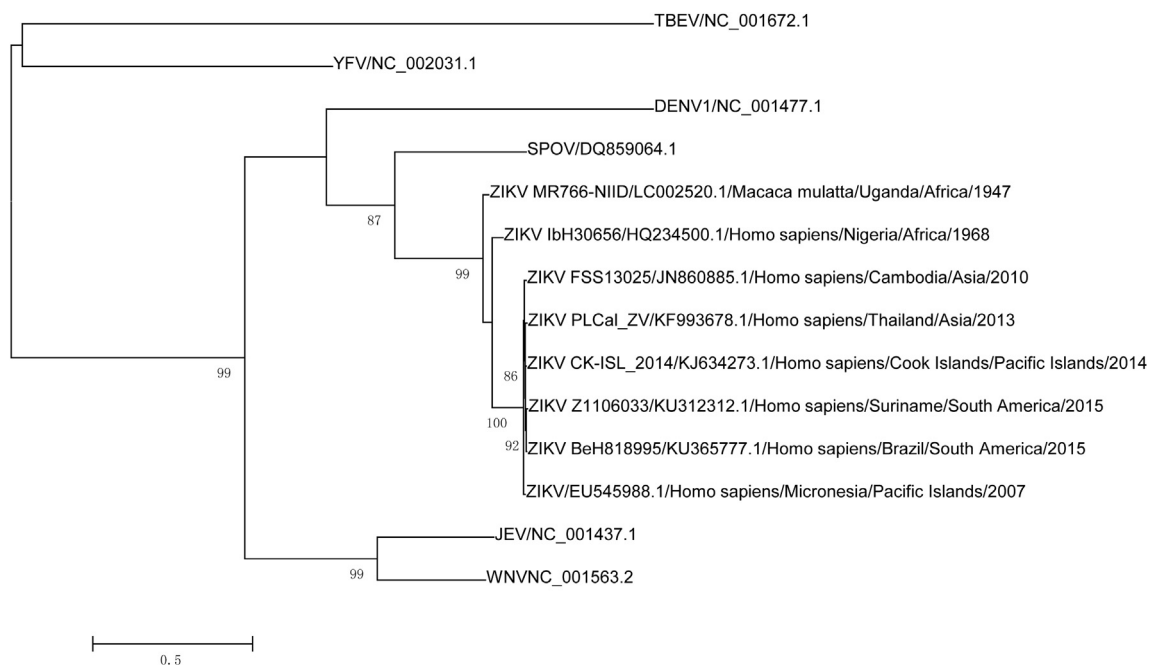
## Clinical features and complications

Most patients with ZIKV infection are asymptomatic. In the outbreak of ZIKV infection on Yap Island, only 18% of cases were estimated to be symptomatic.<sup>13</sup> The incubation period of ZIKV infection is unclear, but is estimated to be similar to other mosquito-borne flaviviruses (2–14 days).<sup>76,113</sup> The clinical syndromes of symptomatic ZIKV infection can be broadly divided into Zika fever and congenital infection (“congenital Zika syndrome”) (Table 4).

## Zika fever

Zika fever is an acute “dengue fever-like” illness characterized by low-grade fever (37.8–38.5 °C), rash, retro-orbital headache, bilateral non-purulent conjunctivitis, myalgia, and arthritis/arthralgia with periarticular oedema of the small joints of hands and feet.<sup>13</sup> The rash in Zika fever is typically described as a generalized, erythematous, maculopapular rash that spreads downward from the face to the limbs.<sup>30</sup> Less commonly, some patients may have more prominent systemic symptoms including high-grade fever, chills, rigours, sore throat, hypotension, and cervical, submandibular, axillary, and/or inguinal lymphadenopathies.<sup>74</sup> Digestive tract symptoms including nausea, vomiting, diarrhoea, constipation, abdominal pain, and aphthous ulcers may also be present.<sup>13,17,19</sup> Patients with genitourinary symptoms including haematuria, dysuria, perineal pain, and haemospermia often have detectable viral RNA or infectious virus particles in urine and/or semen.<sup>76,77</sup> Haematological and biochemical laboratory parameters are usually normal. However, some patients may have transient and mild leucopenia, neutropenia, lymphopenia or activated lymphocytes, monocytosis, thrombocytopenia, and elevated serum levels of lactate dehydrogenase, aspartate aminotransferase,  $\gamma$ -glutamyl transferase, fibrinogen, ferritin, C-reactive protein, and erythrocyte sedimentation rate during the viraemic phase.<sup>29,41–43,45,97,114</sup> Recovery from ZIKV infection is





**Figure 1** Phylogenetic tree of selected ZIKV strains with partial nucleotide sequences of Envelope gene. The tree was constructed by the maximum likelihood method using PhyML with automatic model selection by SMS (beta version, online execution <http://www.atgc-montpellier.fr/phyml-sms/>). The best model in each tree was calculated and selected automatically. aLRT was applied and only those branches with over 75% aLRT values are shown in the trees. Viruses are labelled as follow: virus name/strain/accension number/host/location/region/year. DENV1, Dengue virus 1; JEV, Japanese encephalitis virus; SPOV, Spondweni virus; TBEV, tick-borne encephalitis virus; WNV, West Nile virus; YFV, Yellow fever virus; ZIKV, Zika virus.

associated with restoration of normal number of peripheral immune cells and normal function of antigen-presenting cells.<sup>45</sup> Notably, the clinical manifestations of Zika fever are non-specific and may mimic those seen in infectious diseases caused by other arthropod-borne pathogens, especially DENV and CHIKV. Some suggest that Zika fever may be distinguished from dengue fever and Chikungunya fever by more prominent oedema of the extremities, less severe headache and malaise, and milder degree of thrombocytopenia seen in the former.<sup>13,115</sup> Moreover, haemorrhagic complications seen in dengue fever have not been reported in Zika fever, and arthralgia in Zika fever is less severe than that in Chikungunya fever.<sup>13</sup> However, none of these features are pathognomonic and laboratory confirmation is required to exclude co-infections with these arboviruses and other causes of acute febrile illness in returned travellers from endemic regions, such as malaria.

Zika fever is usually self-limiting with most clinical manifestations resolving completely within 3–7 days.<sup>13,49,116</sup> No death, hospitalisation, or haemorrhagic complication was reported during the outbreak on Yap Island.<sup>13</sup> However, some patients may experience more protracted symptoms and other non-haemorrhagic complications. Zika fever-related rash usually resolve within the first week, but may last for up to 14 days and may be pruritic.<sup>13</sup> Other exanthematous diseases, such as DENV, CHIKV, rubella virus, measles virus, parvovirus B19, adenovirus, enterovirus, and rickettsial infection, should be excluded. The median duration of arthralgia is 3.5 days, but some patients may develop persistent or recurrent arthralgia for more than a month after symptom onset,

mimicking the post-infectious chronic arthritis seen in Chikungunya fever and Lyme disease.<sup>13,76</sup> Lymphadenopathies may be present for 2 weeks after symptom onset, and alternative diagnoses such as infectious mononucleosis-like syndrome, *Streptococcus pyogenes* infection, and toxoplasmosis should be considered in refractory cases.<sup>45</sup> A post-infection asthenia appears to be frequent and further investigations may be necessary to determine possible association between ZIKV infection and chronic fatigue syndrome.<sup>13,117,118</sup> Immune-thrombocytopenic purpura and cardiac complication have also been reported in a few cases.<sup>114</sup> Jaundice was observed in patients with virological and/or serological evidence of ZIKV infection in Eastern Nigeria in the 1950s who had co-infections (malaria and microfilaremia) and a patient with sickle cell anaemia.<sup>17,119</sup>

A possible association between ZIKV infection and severe neurological complications has been proposed during the recent epidemics in Oceania and South America, during which the incidence of Guillain–Barré syndrome has increased by 8–20 times in French Polynesia.<sup>115,120</sup> 74/8750 (0.8%) patients with suspected ZIKV infection in the French Polynesia outbreak developed neurological syndromes after presenting with a Zika fever-like illness.<sup>120</sup> Forty-two of these 74 (56.8%) patients were diagnosed with Guillain–Barré syndrome.<sup>12,51,121</sup> Similarly, Guillain–Barré syndrome has been reported among patients with Zika fever-like illness in South America.<sup>51,121</sup> Other neurological complications potentially linked to ZIKV infection include encephalitis, meningoencephalitis, myelitis, paraesthesia, vertigo, facial paralysis, and

**Table 4** Clinical features and complications of ZIKV infection.

Clinical features	Comments	References
Asymptomatic	>80% of infected human are asymptomatic.	13
Zika fever		
Systemic	Fever, chills, rigours, malaise, headache, retro-orbital pain, anorexia, sore throat, lymphadenopathy (cervical, submandibular, axillary, and/or inguinal), hypotension, and conjunctivitis.	19, 45, 76, 150
Neurological/ Ophthalmological	Guillain–Barré syndrome, encephalitis, meningoencephalitis, paraesthesia, photophobia, vertigo, hypertensive iridocyclitis, auditory (bilateral dull and metallic hearing), facial paralysis, and myelitis.	48, 76, 114, 115, 120, 121, 152
Musculoskeletal	Myalgia, arthralgia with periarticular oedema (wrists, knees, ankles, and small joints of the hands and feet).	13, 45, 76
Gastrointestinal	Nausea, vomiting, diarrhoea, constipation, abdominal pain, and jaundice.	13, 17, 19, 119
Genitourinary	Haematuria, prostatitis (perineal pain and mild dysuria), and haemospermia.	76, 77
Dermatological and mucocutaneous	Diffuse maculopapular rash, pruritis, aphthous ulcer, and gingival bleeding.	13, 76
Haematological	Leucopenia, neutropenia, lymphopenia or activated lymphocytes, monocytosis, thrombocytopaenia, and elevated erythrocyte sedimentation rate; and immune-thrombocytopenic purpura.	41, 43, 45, 97, 114
Biochemical	Elevated serum lactate dehydrogenase, aspartate aminotransferase, $\gamma$ -glutamyl transferase, C-reactive protein, fibrinogen, and ferritin levels.	29, 42
Death	At least 3 deaths: <ul style="list-style-type: none"> <li>• An adult male with systemic lupus erythematosus on corticosteroids, rheumatoid arthritis, and alcoholism.</li> <li>• A 15-year-old girl with sickle cell disease who developed disseminated infection with fever, respiratory distress, jaundice, and hepatosplenomegaly.</li> <li>• A neonate with microcephaly, foetal anasarca, and polyhydramnios who died within the first five minutes of birth.</li> </ul>	51, 121, 119
Suspected “congenital Zika syndrome”		
Clinical features	General: <ul style="list-style-type: none"> <li>• Low birth-weight, reduced foetal movement, excessive/redundant scalp skin, foetal anasarca, polyhydramnios, and arthrogryposis; may be associated miscarriage.</li> </ul> Neurological: <ul style="list-style-type: none"> <li>• Microcephaly, polymalformative syndromes, brainstem dysfunction, and absence of swallowing.</li> </ul> Ophthalmological: <ul style="list-style-type: none"> <li>• Cataract, asymmetrical eye sizes, intraocular calcifications, macular alterations (gross pigment mottling and/or chorioretinal atrophy), optic nerve abnormalities (hypoplasia with double-ring sign, pallor, and/or increased cup-to-disk ratio), iris coloboma, and lens subluxation.</li> </ul>	14, 51, 121, 122, 125-127
Ultrasonographic features	Brain atrophy, widespread brain calcifications (periventricular, cerebral parenchyma, thalami, and basal ganglia), lissencephaly, pachygyria, dysgenesis of corpus callosum, vermia, and thalami, enlarged cisterna magna, asymmetrical cerebral hemispheres, severe unilateral ventriculomegaly secondary to cortical/subcortical atrophy, displacement of the midline, and thinning of the parenchymal on the dilated side, thin pons and brainstem.	14, 121, 128

*(continued on next page)*

Table 4 (continued)

Clinical features	Comments	References
Histopathological features	<p><b>Brain:</b></p> <ul style="list-style-type: none"> <li>Multifocal collections of filamentous, granular, and neuron-shaped calcifications in the cortex and subcortical white matter with focal involvement of the whole cortical ribbon, occasionally associated with cortical displacement; diffuse astrogliosis with focal astrocytic outburst into the subarachnoid space; activated microglial cells; macrophages expressing HLA-DR; scattered mild perivascular infiltrates composed of T and B cells in the subcortical white matter; Wallerian degeneration of the long descending tracts in the brainstem and spinal cord; granular intracytoplasmic reaction in destroyed neuronal structures (indirect immunofluorescence test); visible virions in damaged cytoplasmic vesicles (electron microscopy).</li> </ul> <p><b>Placenta:</b></p> <ul style="list-style-type: none"> <li>Focal calcifications in villi and decidua of placenta.</li> </ul>	125

Abbreviations: ZIKV, Zika virus.

ophthalmological (photophobia and hypertensive iridocyclitis) and auditory manifestations.<sup>48,76,114,115,120–122</sup> Suspected fatalities due to ZIKV-related Guillain–Barré syndrome have been reported.<sup>123</sup> While the neurotropism of ZIKV may partially explain these neurological manifestations, more details and serial studies on their cerebrospinal fluid and magnetic resonance images by case-control studies are required to ascertain their association.

Zika fever-related death appears to be extremely rare but a number of probable cases have been reported, especially among immunocompromised patients and neonates with suspected congenital ZIKV infection.<sup>51,119,121</sup> A small number of patients with coinfection with DENV or HIV did not appear to have more severe disease.<sup>29,124</sup> Further studies should be conducted to identify patients who are at risk of severe disease or death.

### Congenital Zika syndrome

Microcephaly (head circumference  $\geq 2$  standard deviations below the mean for sex and gestational age at birth) is the most prominent and commonly reported clinical feature of suspected congenital Zika syndrome.<sup>14,125</sup> Besides microcephaly, neonates and fetuses with suspected congenital ZIKV infection also had other malformations (Table 4). General features included low birth-weight, redundant scalp skin, anasarca, polyhydramnios, and arthrogryposis. Neurological abnormalities included cerebral lesions, polymalformative syndromes, brainstem dysfunction, and absence of swallowing.<sup>51</sup> Ophthalmological defects included cataract, asymmetrical eye sizes, intraocular calcifications, macular atrophy (well-defined macular neuroretinal atrophy and/or macular pigment mottling and foveal reflex loss), optic nerve hypoplasia, iris coloboma, and lens subluxation.<sup>122,126,127</sup> Notably, other features characteristic of intrauterine infections, such as hepatosplenomegaly, rash, and chorioretinitis have not been reported.<sup>14</sup> Ultrasonographic examination revealed cerebral atrophy, intracranial calcifications especially over the white matter of frontal lobes, caudate, lentostriatal vessels, cerebellum, or around the lateral and fourth ventricles, dysgenesis of corpus callosum, vermia, and thalami, enlarged cisterna magna, asymmetrical cerebral hemispheres, severe unilateral ventriculomegaly, displacement of the midline, and thinning of the parenchyma on the dilated side, pons and brainstem.<sup>14,51,121,128</sup> ZIKV particles and RNA may be detected by electron microscopy and RT-PCR, respectively, in autopsied samples.<sup>125</sup>

Two important questions concerning congenital ZIKV infection remain unanswered. The first question is whether ZIKV is indeed the cause of microcephaly and other congenital anomalies in these patients. Severe consequences have been reported for materno-foetal transmission of other arboviruses, such as dengue virus (preterm delivery, foetal death, low birth-weight, prematurity, acute foetal distress during labour), WNV (chorioretinitis and focal cerebral destruction), and CHIKV (encephalopathy and haemorrhagic fever).<sup>80,82,86</sup> Preliminary analysis in the current epidemic of microcephaly has not yet completely excluded other infectious or environmental aetiologies.<sup>51</sup> Moreover, there is some virological evidence to support the association between congenital ZIKV infection and these anomalies. ZIKV RNA

has been detected by RT-PCR in the amniotic fluid of 2 pregnant women whose foetuses had ultrasonographic evidence of microcephaly, in the blood and foetal tissues of a neonate with microcephaly and other congenital anomalies who died within the first 5 min of birth, and in the neonatal brain tissues of a few cases of full-term miscarriages and neonates with microcephaly.<sup>14,51,121,125</sup> However, there is still no large-scale prospective cohort or case–control study to demonstrate a causal link between the presence of ZIKV in the foetus and the congenital anomalies after exclusion of other infectious and toxic causes. Some have suggested that the apparent microcephaly surge might be attributable to the intense search for cases due to the heightened awareness of a possible association with the ZIKV outbreak or the use of larvicide.<sup>129</sup> Furthermore, detailed investigations for exclusion of other pathogens associated with congenital malformations have only been reported in a small number of cases.<sup>14,125</sup> Microcephaly is well reported in congenital cytomegalovirus, rubella virus, and varicella zoster virus infection. Chorioretinitis and intracranial calcifications are common in congenital cytomegalovirus infection and toxoplasmosis, but the latter is more commonly associated with hydrocephalus. Cataract and cardiac anomalies are characteristic of congenital rubella syndrome, although cataract can also be found in congenital herpes simplex virus infection. Thus, the diagnosis of congenital Zika syndrome would depend on the exclusion of these “TORCH” infections in future studies using clinical criteria, histopathological findings, and serological, molecular and conventional cell culture techniques.

If ZIKV is eventually confirmed to be the cause of these congenital anomalies, the second key question would be whether congenital Zika syndrome actually comprises a wider spectrum of varying clinical severities than that seen in the reported cases. As with other congenital infections, it is possible that the reported cases of microcephaly represent only the tip the iceberg, focussing on the more severely affected patients, and that the timing of infection is likely to be important in determining the severity and outcome of the affected foetus. Early infection during the first or even second trimester may be associated with congenital anomalies or even intrauterine death.<sup>14,125,130</sup> Indeed, preliminary data suggested that the greatest risk of microcephaly or congenital anomalies in the affected neonates appears to be associated with ZIKV infection in the first trimester of pregnancy.<sup>51</sup> Of 35 mothers with infants born with microcephaly, 57% and 14% had a rash during the first and second trimester of pregnancy, respectively.<sup>14</sup> Besides neurological defects, cardiac and muscular abnormalities should also be excluded, as suckling mice infected with ZIKV developed evidence of central nervous system infection, myositis and myocarditis.<sup>111</sup> Some suspected cases of congenital Zika syndrome developed severe arthrogryposis.<sup>14,51,121,128</sup> It is possible that intrauterine ZIKV infections that occur at a later stage of the pregnancy may present differently, either with less severe manifestations, such as mental retardation, sensorineural deafness, and/or ophthalmological lesions, or as full-term miscarriages.<sup>14</sup> Neonates with probable perinatal transmission of ZIKV infection appear to have mild disease and favourable outcome.<sup>78</sup> Further investigations should be conducted to

better define the spectrum of manifestations in different gestational stages of congenital ZIKV infection.

## Laboratory diagnosis

Definitive diagnosis of ZIKV infection requires laboratory confirmation as there are no pathognomonic clinical, biochemical, or radiological features that reliably distinguish Zika fever from other arboviruses, and congenital ZIKV infection from other infective, toxic, or genetic causes of congenital anomalies. Successful isolation of ZIKV in viral culture, the gold-standard of laboratory diagnosis of viral infections, mainly depends on the timing of specimen collection and viral loads in the specimens. ZIKV has been isolated in Vero and Vero E6 cells inoculated with infected patients' serum, urine, and/or semen samples (Table 5).<sup>40,75,77</sup> However, infectious virus particles were not recovered by culture in most specimens with low viral loads. A positive serum immunoglobulin (Ig) M or 4-fold rise in the titre of neutralising antibodies in paired serum samples collected approximately 2 weeks apart also establishes the diagnosis of ZIKV infection. IgM may be detected by enzyme-linked immunoassay on as early as day 3 of symptom onset and may last for over 2 months.<sup>40,49</sup> IgM antibodies to DENV and WNV usually persist for  $\leq 3$  months and  $\leq 5$  months, respectively.<sup>131–134</sup> The major limitation of these serological tests is possible cross-reactivity with other flaviviruses. Neutralising antibodies detected by plaque-reduction neutralisation test may be more specific than IgM detection by ELISA for primary ZIKV infection, but may also have indeterminate results for secondary infection, including patients with previous vaccination against or exposed to other flaviviruses.<sup>13,40,102,120</sup> This is especially problematic in areas where there is co-circulation of multiple flaviviruses with the same *Aedes* mosquito vectors.<sup>13,64,102,120</sup> Patients with primary ZIKV infection and past DENV infection are more likely to have higher titre (usually  $\geq 4$ -fold) of IgM and/or neutralising antibodies against ZIKV than against DENV or other flaviviruses.<sup>13,102</sup> A positive serum DENV NS1 antigen test without serial increase in IgM or the combination of a positive IgM response to DENV and lack of an IgG seroconversion in the convalescent-phase serum sample should prompt the clinician to investigate for another flavivirus such as ZIKV. Moreover, co-infections with other mosquito-borne arboviruses, such as DENV, CHIKV, WNV, and Japanese encephalitis virus, are always possible and should be excluded by more extensive laboratory testing if clinically indicated.

Rapid and accurate diagnosis of ZIKV infection during the recent epidemics has mainly been achieved by the application of RT-PCR using primers that target the E or NS5 gene of ZIKV.<sup>13,102,103,135,136</sup> Alternatively, RT-PCR sequencing using universal primers that target the conserved regions in the genomes, such as the NS5 gene, of multiple flaviviruses, may allow simultaneous detection of  $>50$  different flaviviruses.<sup>137</sup> Serum samples should be collected in the early phase of the disease, because viraemia is usually short-lived (usually  $\leq 5$  days, rarely up to 11 days) and may be low-level ( $\leq 10^2$  copies/ml).<sup>97,102</sup> Alternatively, urine and semen samples may have higher viral RNA loads

**Table 5** Advantages, limitations, and uses of different diagnostic tests and types of specimens for laboratory diagnosis of ZIKV infection. <sup>14,40,41,49,50,75–79,96,97,102,121,125,127,137–139,153</sup>

Specimen types	Laboratory diagnostics	
	RT-PCR	Viral culture
Serum	<ul style="list-style-type: none"> <li>• Most cases have short-lived (<math>\leq 5</math> days of symptom onset) and low-level viraemia.</li> <li>• Rarely, viral RNA may be detected in serum on as late as 11 days of symptom onset.</li> </ul>	<ul style="list-style-type: none"> <li>• Infectious ZIKV has been detected in human blood collected on as early as the day of symptom onset (Vero cells)</li> <li>• 3/34 (8.8%) of archived serum samples which were RT-PCR-positive for ZIKV yielded infectious viral particles in Vero cells</li> </ul>
Urine	<ul style="list-style-type: none"> <li>• Higher viral load than concomitant serum samples.</li> <li>• Positive from day 2–3 to after day 30 of symptom onset.</li> </ul>	<ul style="list-style-type: none"> <li>• Successful isolation in Vero E6 cells; may be especially useful in patients with genitourinary symptoms.</li> </ul>
Semen	<ul style="list-style-type: none"> <li>• Higher viral load (<math>10^7</math> copies/ml) than concomitant urine (<math>10^3</math> copies/ml) and serum (undetectable) samples.</li> <li>• May be positive for <math>\geq 62</math> days of symptom onset.</li> </ul>	<ul style="list-style-type: none"> <li>• Successful isolation Vero cells; may be especially useful in patients with genitourinary symptoms.</li> </ul>
Nasopharyngeal swab	<ul style="list-style-type: none"> <li>• Positive in a patient whose concomitant serum and wound (monkey bite) samples were negative.</li> </ul>	<ul style="list-style-type: none"> <li>• May be complimentary to serum and urine for suspected ZIKV infection.</li> </ul>
Saliva	<ul style="list-style-type: none"> <li>• Viral RNA is more frequently detected in saliva than blood.</li> <li>• Positive in both neonates and adults.</li> <li>• Complimentary but cannot replace serum samples.</li> </ul>	<ul style="list-style-type: none"> <li>• May be complimentary to serum and urine for suspected ZIKV infection.</li> </ul>
Amniotic fluid	<ul style="list-style-type: none"> <li>• Positive in two pregnant women whose foetuses had ultrasonographic evidence of microcephaly.</li> </ul>	<ul style="list-style-type: none"> <li>• May be useful in infants with suspected congenital ZIKV infection.</li> </ul>
Foetal/placental/umbilical cord tissue	<ul style="list-style-type: none"> <li>• Positive in a neonate with congenital anomalies (microcephaly, foetal anasarca, and polyhydramnios) who died within the first 5 min of life.</li> <li>• Positive in the brain of 4 full-term infants (2 as miscarriage and 2 with microcephaly) with suspected congenital ZIKV infection.</li> </ul>	<ul style="list-style-type: none"> <li>• May be useful in infants with suspected congenital ZIKV infection.</li> </ul>
Cerebrospinal fluid	<ul style="list-style-type: none"> <li>• May be useful in infants with suspected congenital ZIKV infection or patients with neurological complications.</li> </ul>	<ul style="list-style-type: none"> <li>• May be useful in infants with suspected congenital ZIKV infection or patients with neurological complications.</li> </ul>
Skin biopsy	<ul style="list-style-type: none"> <li>• May be useful to exclude concomitant infections in patients with persistent or atypical rash.</li> </ul>	<ul style="list-style-type: none"> <li>• May be useful to exclude concomitant infections in patients with persistent or atypical rash.</li> </ul>
Joint fluid	<ul style="list-style-type: none"> <li>• May be useful to exclude concomitant infections in patients with persistent or recurrent arthritis.</li> </ul>	<ul style="list-style-type: none"> <li>• May be useful to exclude concomitant infections in patients with persistent or recurrent arthritis.</li> </ul>
Bone marrow	<ul style="list-style-type: none"> <li>• May be useful to exclude concomitant infections in patients with unusually persistent or severe cytopenia.</li> </ul>	<ul style="list-style-type: none"> <li>• May be useful to exclude concomitant infections in patients with unusually persistent or severe cytopenia.</li> </ul>
Other tissues	<ul style="list-style-type: none"> <li>• Brain, liver, spleen, and pooled visceral (kidney, lung, and heart) tissues were positive in a fatal case (an adult male with co-morbidities and immunosuppressive treatment).</li> </ul>	<ul style="list-style-type: none"> <li>• May be useful to exclude concomitant infections in patients with unusually severe or fatal infection.</li> </ul>

Abbreviations: RT-PCR, reverse transcription-polymerase chain reaction; ZIKV, Zika virus.



(>10<sup>6</sup> copies/ml) than serum samples, and may be persistently positive for >30 days and ≥62 days after symptom onset, respectively.<sup>97,138</sup> In a few cases, ZIKV RNA has also been detected in saliva and nasopharyngeal swab samples of patients whose serum samples tested negative for ZIKV. These samples should therefore also be collected in suspected cases of ZIKV infection.<sup>40,78,79,96</sup> Collection of amniotic fluid should be considered in pregnant women with positive ZIKV test result or if the foetuses show ultrasonographic evidence suggestive of congenital ZIKV infection.<sup>14,102,128</sup> Cerebrospinal fluid, placental, and/or umbilical cord tissues from neonates with suspected congenital ZIKV infection should be sent for virological and/or histopathological examinations to establish the diagnosis.<sup>14,121,125</sup> ZIKV RNA may also be detected in organ tissues in the rare cases of suspected ZIKV-related deaths.<sup>121</sup> Future studies should aim to better stratify the clinical use of these tests and to develop point-of-care tests (eg: antigen tests) that can be widely used in less developed regions without the facilities and expertise for molecular or serological tests.

## Clinical management and perinatal care

Treatment is usually not required for patients with asymptomatic or uncomplicated Zika fever. The mainstay of treatment is supportive as there are no specific anti-ZIKV antiviral agents. Acetaminophen may be used to relieve fever and arthralgia. Anti-histamines may help to control pruritus. Adequate rehydration for fluid loss through sweating, vomiting, and insensible losses should be encouraged. Aspirin should be avoided due to the risks of bleeding in those with thrombocytopenia and developing Reye's syndrome in children less than 12 years of age. Nonsteroidal anti-inflammatory drugs are also contraindicated in cases where DENV and CHIKV infections cannot be confidently excluded in order to avoid haemorrhagic complications. Potential neurological complications, especially Guillain-Barré syndrome, should be diagnosed promptly to allow early use of intravenous immunoglobulins and/or plasmapheresis. The risk of immune enhancement should also be considered if convalescent-phase plasma therapy with neutralising antibodies against ZIKV is used for treatment of severe cases.

Virological testing and foetal ultrasound to exclude ZIKV infection and foetal microcephaly or intracranial calcifications should be offered to pregnant women who develop Zika fever-like symptoms during or within 2 weeks of travel to areas with ZIKV transmission.<sup>139</sup> Besides collecting the appropriate specimens for virological tests, serial foetal ultrasound examinations should be performed every 3–4 weeks to monitor foetal anatomy and growth in suspected cases of congenital ZIKV infection. Foetal ultrasound and/or amniocentesis should also be offered to asymptomatic and seropositive pregnant women with history of travel to affected areas. After delivery, serum should be collected either from the umbilical cord or directly from the neonate within 2 days of birth for RT-PCR, IgM and/or neutralising antibodies against ZIKV.<sup>140</sup> Comprehensive physical examination including measurement of the occipitofrontal circumference, length, and weight, evaluation for neurological abnormalities, dysmorphic features,

hepatosplenomegaly, rash, ophthalmological lesions, and auditory defects, and laboratory testing for TORCH screening should be performed.<sup>140</sup> The affected child and the family should be managed and counselled by a multidisciplinary team consisting of paediatric neurologist, clinical geneticist or dysmorphologist, infectious disease specialist, medical social worker, and other relevant specialists.<sup>140</sup> Long-term follow-up to monitor physical, intellectual, and functional progress of the child should be offered.<sup>140</sup>

## Epidemic and infection control

Both vector control and personal preventive measures are important for interrupting the transmission of ZIKV. Systematic mosquito surveillance and control programs should be established and coordinated by health authorities.<sup>51</sup> Mass sanitation campaigns to eliminate mosquito breeding sites in household and high-risk areas such as garbage collection points, construction sites, illegal dumping grounds, and invalid car fields should be organised. Mosquitoes should be removed with a radius of at least 400 m around areas with high population densities, such as schools, transport terminals, churches, and healthcare facilities. In areas where autochthonous or imported cases of ZIKV are detected, the use of adulticide through spraying to remove infected adult mosquitoes should be considered. Residents in or travellers to affected areas should stay indoor with air conditioning, window and door screens if possible, wear long sleeves and pants, use permethrin-treated clothing and gear, and use insect repellents when outdoor.<sup>140</sup> Most Environmental Protection Agency (EPA)-registered insect repellents, including N,N-diethyl-m-toluamide (DEET), should be safe for pregnant and lactating women (20% DEET), and children (10% DEET) aged >2 months.<sup>141</sup> Individuals returning from affected areas to non-affected regions should continue to use insect repellents for at least an additional 14 days to prevent local non-infected mosquitoes from the acquisition of virus from the asymptotically infected returned travellers. This will serve to interrupt the mosquito-human-mosquito transmission chain. Hospitalised laboratory-confirmed cases should be managed in designated wards to avoid mosquito bites. The effects of other novel mosquito-control measures, such as the *Wolbachia* biological control approach, should be evaluated.<sup>142</sup> Other animals such as rodents should also be investigated as potential animal reservoirs and controlled as findings indicate.

Non-vector-borne transmission of ZIKV may be prevented by specific measures (Table 3). Concerning blood transfusion, universal nucleic acid testing of blood donors is recommended. The use of universal primers that can simultaneously detect multiple arboviruses such as DENV and ZIKV should be considered. Temporary discontinuation of blood donation should be considered during an outbreak situation. In non-endemic areas, pre-donation questionnaire to identify donors with recent travel history to regions with reported cases of ZIKV infection and deferral of blood donation from these donors until at least 14 days after returning from affected regions should be implemented. Most transfusion-related transmissions of arboviruses are



associated with asymptomatic infections, and symptomatic donors who were RT-PCR-positive for ZIKV usually developed symptoms between 3 and 10 days after blood donation.<sup>143</sup> Newer pathogen reduction technologies for blood products should be considered.<sup>143</sup> Similarly, donated organs, especially kidneys, from individuals with travel history to affected areas should be tested for ZIKV as the virus may persist in the genitourinary tract for an undetermined period.<sup>40,41,49,50,97</sup> Barrier methods should be used to prevent sexual transmission through infected semen. Male returned travellers should continue the use of condom with pregnant sex partner throughout the whole duration of pregnancy. Future studies should evaluate the duration of virus shedding in semen and the infectiousness of RNA-positive semen samples, in order to determine how long barrier methods should be used by men returning to non-endemic regions. Some regional authorities have advised women to avoid pregnancy until the epidemic is over.<sup>144</sup> Pregnant women or those planning for pregnancy should defer travelling to regions with reported cases of ZIKV infection. If such travel was unavoidable, they should strictly comply with personal protective measures to avoid mosquito bites. Further studies are needed to determine the risk of ZIKV transmission by breast milk and saliva. Other less common transmission routes, including mucocutaneous exposure to infected bodily fluid during laboratory and patient-care procedures, and bites by infected primates should be avoided with strict compliance to infection control measures. In the laboratory setting, ZIKV can be killed by potassium permanganate, ether, and heat (>60 °C), but it is not effectively neutralised with low concentration (10%) of ethanol.<sup>54</sup>

No ZIKV vaccine is available currently. Because the moratorium for pregnancy may be impractical for some people, a safe and effective ZIKV vaccine is urgently needed. Some realistic approaches include live-attenuated or killed vaccine from human cell lines (as in the case of YFV and Japanese encephalitis vaccines), attenuated chimeric vaccine (DENV vaccine using the YFV vaccine backbone, currently in Phase III clinical trial), DNA and recombinant protein vaccine.<sup>145</sup> Suitable animal models for evaluation of these potential vaccine candidates should be developed for ZIKV infection. The role of passive immunisation before and after exposure to ZIKV should also be assessed in future studies.

## Conclusion

The ZIKV epidemic has emerged as an unexpected global health emergency as the rapidly expanding ZIKV epidemic may turn out to be a major cause of permanent and severe disability in a generation of newborns, which would constitute a huge socioeconomic burden to the affected countries. The future of the ZIKV epidemic is unpredictable, but the worldwide spread of DENV and CHIKV over the past two decades suggests that ZIKV has the potential to follow their paths. With more than half of the world's human population living in areas infested with *Aedes* mosquitoes, the ongoing adaptation of ZIKV to an urban cycle signify the virus' pandemic potential.<sup>36</sup> Research preparedness is urgently needed to improve mosquito-control

measures, as well as to develop point-of-care laboratory diagnostics, antivirals, and vaccines which are suitable for use in pregnant women and foetuses.

## Conflict of interest

The authors declare no conflict of interest.

## Acknowledgements

The study was partly supported by the Consultancy Service for Enhancing Laboratory Surveillance of Emerging Infectious Disease of the Department of Health, The Food and Health Bureau, Hong Kong Special Administrative Region, China; and by the donations of Hui Hoy and Chow Sin Lan Charity Fund Limited and Mr. Larry Chi-Kin Yung.

## References

1. Chan JF, To KK, Tse H, Jin DY, Yuen KY. Interspecies transmission and emergence of novel viruses: lessons from bats and birds. *Trends Microbiol* 2013;21(10):544–55.
2. Cheng VC, Lau SK, Woo PC, Yuen KY. Severe acute respiratory syndrome coronavirus as an agent of emerging and reemerging infection. *Clin Microbiol Rev* 2007;20(4):660–94.
3. Chan JF, Lau SK, To KK, Cheng VC, Woo PC, Yuen KY. Middle East respiratory syndrome coronavirus: another zoonotic betacoronavirus causing SARS-like disease. *Clin Microbiol Rev* 2015;28(2):465–522.
4. Chan JF, Lau SK, Woo PC. The emerging novel Middle East respiratory syndrome coronavirus: the “knowns” and “unknowns”. *J Formos Med Assoc* 2013;112(7):372–81.
5. Chan JF, Li KS, To KK, Cheng VC, Chen H, Yuen KY. Is the discovery of the novel human betacoronavirus 2c EMC/2012 (HCoV-EMC) the beginning of another SARS-like pandemic? *J Infect* 2012;65(6):477–89.
6. Cheng VC, To KK, Tse H, Hung IF, Yuen KY. Two years after pandemic influenza A/2009/H1N1: what have we learned? *Clin Microbiol Rev* 2012;25(2):223–63.
7. To KK, Ng KH, Que TL, Chan JM, Tsang KY, Tsang AK, et al. Avian influenza A H5N1 virus: a continuous threat to humans. *Emerg Microbes Infect* 2012;1(9):e25.
8. To KK, Hung IF, Chan JF, Yuen KY. From SARS coronavirus to novel animal and human coronaviruses. *J Thorac Dis* 2013;5(Suppl. 2):S103–8.
9. To KK, Chan JF, Chen H, Li L, Yuen KY. The emergence of influenza A H7N9 in human beings 16 years after influenza A H5N1: a tale of two cities. *Lancet Infect Dis* 2013;13(9):809–21.
10. To KK, Tsang AK, Chan JF, Cheng VC, Chen H, Yuen KY. Emergence in China of human disease due to avian influenza A(H10N8) – cause for concern? *J Infect* 2014;68(3):205–15.
11. To KK, Chan JF, Tsang AK, Cheng VC, Yuen KY. Ebola virus disease: a highly fatal infectious disease reemerging in West Africa. *Microbes Infect* 2015;17(2):84–97.
12. Fauci AS, Morens DM. Zika virus in the Americas – yet another arbovirus threat. *N Engl J Med* 2016;374(7):601–4.
13. Duffy MR, Chen TH, Hancock WT, Powers AM, Kool JL, Lanciotti RS, et al. Zika virus outbreak on Yap Island, Federated States of Micronesia. *N Engl J Med* 2009;360(24):2536–43.
14. Schuler-Faccini L, Ribeiro EM, Feitosa IM, Horovitz DD, Cavalcanti DP, Pessoa A, et al. Possible association between Zika virus infection and microcephaly – Brazil, 2015. *MMWR Morb Mortal Wkly Rep* 2016;65(3):59–62.

15. World Health Organization (WHO). *WHO statement on the first meeting of the International Health Regulations (2005) (IHR 2005) Emergency Committee on Zika virus and observed increase in neurological disorders and neonatal malformations*. 1 February 2016. Available from: <http://www.who.int/mediacentre/news/statements/2016/1st-emergency-committee-zika/en/>.
16. Dick GW, Kitchen SF, Haddow AJ. Zika virus. I. Isolations and serological specificity. *Trans R Soc Trop Med Hyg* 1952;**46**(5): 509–20.
17. Macnamara FN. Zika virus: a report on three cases of human infection during an epidemic of jaundice in Nigeria. *Trans R Soc Trop Med Hyg* 1954;**48**(2):139–45.
18. Robin Y, Mouchet J. Serological and entomological study on yellow fever in Sierra Leone. *Bull Soc Pathol Exot Fil* 1975;**68**(3):249–58.
19. Olson JG, Ksiazek TG, Suhandiman, Triwibowo. Zika virus, a cause of fever in Central Java, Indonesia. *Trans R Soc Trop Med Hyg* 1981;**75**(3):389–93.
20. Jan C, Languillat G, Renaudet J, Robin Y. A serological survey of arboviruses in Gabon. *Bull Soc Pathol Exot Fil* 1978;**71**(2): 140–6.
21. Saluzzo JF, Gonzalez JP, Herve JP, Georges AJ. Serological survey for the prevalence of certain arboviruses in the human population of the south-east area of Central African Republic. *Bull Soc Pathol Exot Fil* 1981;**74**(5):490–9.
22. Saluzzo JF, Ivanoff B, Languillat G, Georges AJ. Serological survey for arbovirus antibodies in the human and simian populations of the South-East of Gabon. *Bull Soc Pathol Exot Fil* 1982;**75**(3):262–6.
23. Monlun E, Zeller H, Le Guenno B, Traore-Lamizana M, Hery JP, Adam F, et al. Surveillance of the circulation of arbovirus of medical interest in the region of eastern Senegal. *Bull Soc Pathol Exot Fil* 1993;**86**(1):21–8.
24. Olson JG, Ksiazek TG, Gubler DJ, Lubis SI, Simanjuntak G, Lee VH, et al. A survey for arboviral antibodies in sera of humans and animals in Lombok, Republic of Indonesia. *Ann Trop Med Parasitol* 1983;**77**(2):131–7.
25. Diagne CT, Diallo D, Faye O, Ba Y, Faye O, Gaye A, et al. Potential of selected Senegalese *Aedes* spp. mosquitoes (Diptera: Culicidae) to transmit Zika virus. *BMC Infect Dis* 2015;**15**:492.
26. Dick GW. Epidemiological notes on some viruses isolated in Uganda; Yellow fever, Rift Valley fever, Bwamba fever, West Nile, Mengo, Semliki forest, Bunyamwera, Ntaya, Uganda S and Zika viruses. *Trans R Soc Trop Med Hyg* 1953;**47**(1):13–48.
27. Derraik JG, Slaney D. Notes on Zika virus – an emerging pathogen now present in the South Pacific. *Aust N Z J Public Health* 2015;**39**(1):5–7.
28. Roth A, Mercier A, Lepers C, Hoy D, Duituturaga S, Benyon E, et al. Concurrent outbreaks of dengue, chikungunya and Zika virus infections – an unprecedented epidemic wave of mosquito-borne viruses in the Pacific 2012–2014. *Euro Surveill* 2014;**19**(41).
29. Dupont-Rouzeyrol M, O'Connor O, Calvez E, Daures M, John M, Grangeon JP, et al. Co-infection with Zika and dengue viruses in 2 patients, New Caledonia, 2014. *Emerg Infect Dis* 2015;**21**(2):381–2.
30. Musso D. Zika virus transmission from French Polynesia to Brazil. *Emerg Infect Dis* 2015;**21**(10):1887.
31. Tognarelli J, Ulloa S, Villagra E, Lagos J, Aguayo C, Fasce R, et al. A report on the outbreak of Zika virus on Easter Island, South Pacific, 2014. *Arch Virol* 2016;**161**(3):665–8.
32. Pan American Health Organization/World Health Organization (PAHO/WHO). *Epidemiological update – neurological syndrome, congenital anomalies, and Zika virus infection*. 17 January 2016. Available from: [http://www.paho.org/hq/index.php?option=com\\_docman&task=doc\\_view&Itemid=270&gid=32879&lang=en](http://www.paho.org/hq/index.php?option=com_docman&task=doc_view&Itemid=270&gid=32879&lang=en).
33. Bogoch II, Brady OJ, Kraemer MU, German M, Creatore MI, Kulkarni MA, et al. Anticipating the international spread of Zika virus from Brazil. *Lancet* 2016;**387**(10016):335–6.
34. Enfissi A, Codrington J, Roosblad J, Kazanji M, Rousset D. Zika virus genome from the Americas. *Lancet* 2016;**387**(10015): 227–8.
35. Salvador FS, Fujita DM. Entry routes for Zika virus in Brazil after 2014 world cup: new possibilities. *Travel Med Infect Dis* 2016;**14**(1):49–51.
36. Marcondes CB, Ximenes MF. Zika virus in Brazil and the danger of infestation by *Aedes* (*Stegomyia*) mosquitoes. *Rev Soc Bras Med Trop* 2015. pii: S0037–86822015005003102. [Epub ahead of print].
37. Paz S, Semenza JC. El Niño and climate change-contributing factors in the dispersal of Zika virus in the Americas? *Lancet* 2016;**387**(10020):745.
38. World Health Organization (WHO). *Zika situation report – neurological syndrome and congenital anomalies*. 5 February 2016. Available from: [http://apps.who.int/iris/bitstream/10665/204348/1/zikasitrep\\_5Feb2016\\_eng.pdf?ua=1](http://apps.who.int/iris/bitstream/10665/204348/1/zikasitrep_5Feb2016_eng.pdf?ua=1).
39. Kwong JC, Druce JD, Leder K. Zika virus infection acquired during brief travel to Indonesia. *Am J Trop Med Hyg* 2013;**89**(3):516–7.
40. Fonseca K, Meatherall B, Zarra D, Drebot M, MacDonald J, Pabbaraju K, et al. First case of Zika virus infection in a returning Canadian traveler. *Am J Trop Med Hyg* 2014;**91**(5): 1035–8.
41. Kutsuna S, Kato Y, Takasaki T, Moi M, Kotaki A, Uemura H, et al. Two cases of Zika fever imported from French Polynesia to Japan, December 2013 to January 2014. *Euro Surveill* 2014;**19**(4).
42. Tappe D, Risland J, Gabriel M, Emmerich P, Gunther S, Held G, et al. First case of laboratory-confirmed Zika virus infection imported into Europe, November 2013. *Euro Surveill* 2014;**19**(4).
43. Waehre T, Maagard A, Tappe D, Cadar D, Schmidt-Chanasit J. Zika virus infection after travel to Tahiti, December 2013. *Emerg Infect Dis* 2014;**20**(8):1412–4.
44. Zammarchi L, Tappe D, Fortuna C, Remoli ME, Gunther S, Venturi G, et al. Zika virus infection in a traveller returning to Europe from Brazil, March 2015. *Euro Surveill* 2015;**20**(23).
45. Zammarchi L, Stella G, Mantella A, Bartolozzi D, Tappe D, Gunther S, et al. Zika virus infections imported to Italy: clinical, immunological and virological findings, and public health implications. *J Clin Virol* 2015;**63**:32–5.
46. Tappe D, Perez-Giron JV, Zammarchi L, Risland J, Ferreira DF, Jaenisch T, et al. Cytokine kinetics of Zika virus-infected patients from acute to convalescent phase. *Med Microbiol Immunol* 2015 [Epub ahead of print].
47. Summers DJ, Acosta RW, Acosta AM. Zika virus in an American recreational traveler. *J Travel Med* 2015;**22**(5):338–40.
48. Tappe D, Nachtigall S, Kapaun A, Schnitzler P, Gunther S, Schmidt-Chanasit J. Acute Zika virus infection after travel to Malaysian Borneo, September 2014. *Emerg Infect Dis* 2015;**21**(5):911–3.
49. Shinohara K, Kutsuna S, Takasaki T, Moi ML, Ikeda M, Kotaki A, et al. Zika fever imported from Thailand to Japan, and diagnosed by PCR in the urines. *J Travel Med* 2016;**23**(1).
50. Korhonen EM, Huhtamo E, Smura T, Kallio-Kokko H, Raassina M, Vapalahti O. Zika virus infection in a traveller returning from the Maldives, June 2015. *Euro Surveill* 2016;**21**(2).
51. Pan American Health Organization/World Health Organization (PAHO/WHO). *Epidemiological alert – neurological syndrome, congenital malformations, and Zika virus infection. Implications for public health in the Americas*. 1 December 2015. Available from: [http://www.paho.org/hq/index.php?option=com\\_docman&task=doc\\_view&Itemid=270&gid=32405&lang=en](http://www.paho.org/hq/index.php?option=com_docman&task=doc_view&Itemid=270&gid=32405&lang=en).

52. Diallo D, Sall AA, Diagne CT, Faye O, Faye O, Ba Y, et al. Zika virus emergence in mosquitoes in southeastern Senegal, 2011. *PLoS One* 2014;9(10):e109442.
53. Chan JF, To KK, Chen H, Yuen KY. Cross-species transmission and emergence of novel viruses from birds. *Curr Opin Virol* 2015;10:63–9.
54. Dick GW. Zika virus. II. Pathogenicity and physical properties. *Trans R Soc Trop Med Hyg* 1952;46(5):521–34.
55. Boorman JP, Porterfield JS. A simple technique for infection of mosquitoes with viruses; transmission of Zika virus. *Trans R Soc Trop Med Hyg* 1956;50(3):238–42.
56. Marchette NJ, Garcia R, Rudnick A. Isolation of Zika virus from *Aedes aegypti* mosquitoes in Malaysia. *Am J Trop Med Hyg* 1969;18(3):411–5.
57. Akoua-Koffi C, Diarrassouba S, Benie VB, Ngbichi JM, Bozoua T, Bosson A, et al. Investigation surrounding a fatal case of yellow fever in Cote d'Ivoire in 1999. *Bull Soc Pathol Exot* 2001;94(3):227–30.
58. Li MI, Wong PS, Ng LC, Tan CH. Oral susceptibility of Singapore *Aedes (Stegomyia) aegypti* (Linnaeus) to Zika virus. *PLoS Negl Trop Dis* 2012;6(8):e1792.
59. Haddow AJ, Williams MC, Woodall JP, Simpson DI, Goma LK. Twelve isolations of Zika virus from *Aedes (Stegomyia) africanus* (Theobald) taken in and above a Uganda Forest. *Bull World Health Organ* 1964;31:57–69.
60. Weinbren MP, Haddow AJ, Williams MC. The occurrence of Chikungunya virus in Uganda. I. Isolation from mosquitoes. *Trans R Soc Trop Med Hyg* 1958;52(3):253–7.
61. Gratz NG. Critical review of the vector status of *Aedes albopictus*. *Med Vet Entomol* 2004;18(3):215–27.
62. Paupy C, Delatte H, Bagny L, Corbel V, Fontenille D. *Aedes albopictus*, an arbovirus vector: from the darkness to the light. *Microbes Infect* 2009;11(14–15):1177–85.
63. Wong PS, Li MZ, Chong CS, Ng LC, Tan CH. *Aedes (Stegomyia) albopictus* (Skuse): a potential vector of Zika virus in Singapore. *PLoS Negl Trop Dis* 2013;7(8):e2348.
64. Grard G, Caron M, Mombo IM, Nkoghe D, Mboui Ondo S, Jiolle D, et al. Zika virus in Gabon (Central Africa) – 2007: a new threat from *Aedes albopictus*? *PLoS Negl Trop Dis* 2014;8(2):e2681.
65. McCrae AW, Kirya BG. Yellow fever and Zika virus epizootics and enzootics in Uganda. *Trans R Soc Trop Med Hyg* 1982;76(4):552–62.
66. Faye O, Freire CC, Iamarino A, Faye O, de Oliveira JV, Diallo M, et al. Molecular evolution of Zika virus during its emergence in the 20(th) century. *PLoS Negl Trop Dis* 2014;8(1):e2636.
67. Ledermann JP, Guillaumot L, Yug L, Saweyog SC, Tided M, Machieng P, et al. *Aedes hensilli* as a potential vector of Chikungunya and Zika viruses. *PLoS Negl Trop Dis* 2014;8(10):e3188.
68. Fagbami AH. Zika virus infections in Nigeria: virological and seroepidemiological investigations in Oyo State. *J Hyg (Lond)* 1979;83(2):213–9.
69. Berthet N, Nakoune E, Kamgang B, Selekon B, Descorps-Declere S, Gessain A, et al. Molecular characterization of three Zika flaviviruses obtained from sylvatic mosquitoes in the Central African Republic. *Vector Borne Zoonotic Dis* 2014;14(12):862–5.
70. Darwish MA, Hoogstraal H, Roberts TJ, Ahmed IP, Omar F. A sero-epidemiological survey for certain arboviruses (Togaviridae) in Pakistan. *Trans R Soc Trop Med Hyg* 1983;77(4):442–5.
71. Wolfe ND, Kilbourn AM, Karesh WB, Rahman HA, Bosi EJ, Cropp BC, et al. Sylvatic transmission of arboviruses among Bornean orangutans. *Am J Trop Med Hyg* 2001;64(5–6):310–6.
72. Kilbourn AM, Karesh WB, Wolfe ND, Bosi EJ, Cook RA, Andau M. Health evaluation of free-ranging and semi-captive orangutans (*Pongo pygmaeus pygmaeus*) in Sabah, Malaysia. *J Wild Dis* 2003;39(1):73–83.
73. Gasperi G, Bellini R, Malacrida AR, Crisanti A, Dottori M, Aksoy S. A new threat looming over the Mediterranean basin: emergence of viral diseases transmitted by *Aedes albopictus* mosquitoes. *PLoS Negl Trop Dis* 2012;6(9):e1836.
74. Schaffner F, Mathis A. Dengue and dengue vectors in the WHO European region: past, present, and scenarios for the future. *Lancet Infect Dis* 2014;14(12):1271–80.
75. Musso D, Nhan T, Robin E, Roche C, Bierlaire D, Zisou K, et al. Potential for Zika virus transmission through blood transfusion demonstrated during an outbreak in French Polynesia, November 2013 to February 2014. *Euro Surveill* 2014;19(14).
76. Foy BD, Kobylinski KC, Chilson Foy JL, Blitvich BJ, Traversos da Rosa A, Haddow AD, et al. Probable non-vector-borne transmission of Zika virus, Colorado, USA. *Emerg Infect Dis* 2011;17(5):880–2.
77. Musso D, Roche C, Robin E, Nhan T, Teissier A, Cao-Lormeau VM. Potential sexual transmission of Zika virus. *Emerg Infect Dis* 2015;21(2):359–61.
78. Besnard M, Lastere S, Teissier A, Cao-Lormeau V, Musso D. Evidence of perinatal transmission of Zika virus, French Polynesia, December 2013 and February 2014. *Euro Surveill* 2014;19(13).
79. Musso D, Roche C, Nhan TX, Robin E, Teissier A, Cao-Lormeau VM. Detection of Zika virus in saliva. *J Clin Virol* 2015;68:53–5.
80. Tan PC, Rajasingam G, Devi S, Omar SZ. Dengue infection in pregnancy: prevalence, vertical transmission, and pregnancy outcome. *Obstet Gynecol* 2008;111(5):1111–7.
81. Poulriot SH, Xiong X, Harville E, Paz-Soldan V, Tomashek KM, Breart G, et al. Maternal dengue and pregnancy outcomes: a systematic review. *Obstet Gynecol Surv* 2010;65(2):107–18.
82. Basurko C, Carles G, Youssef M, Guindi WE. Maternal and fetal consequences of dengue fever during pregnancy. *Eur J Obstet Gynecol Reprod Biol* 2009;147(1):29–32.
83. Adam I, Jumaa AM, Elbashir HM, Karsany MS. Maternal and perinatal outcomes of dengue in PortSudan, Eastern Sudan. *Virol J* 2010;7:153.
84. Barthel A, Gourinat AC, Cazorla C, Joubert C, Dupont-Rouzeyrol M, Descloux E. Breast milk as a possible route of vertical transmission of dengue virus? *Clin Infect Dis* 2013;57(3):415–7.
85. Fritel X, Rollot O, Gerardin P, Gauzere BA, Bideault J, Lagarde L, et al. Chikungunya virus infection during pregnancy, Reunion, France, 2006. *Emerg Infect Dis* 2010;16(3):418–25.
86. Gerardin P, Barau G, Michault A, Bintner M, Randrianaivo H, Choker G, et al. Multidisciplinary prospective study of mother-to-child chikungunya virus infections on the island of La Reunion. *PLoS Med* 2008;5(3):e60.
87. Stewart RD, Bryant SN, Sheffield JS. West Nile virus infection in pregnancy. *Case Rep Infect Dis* 2013;2013:351872.
88. Centers for Disease Control and Prevention (CDC). Possible West Nile virus transmission to an infant through breastfeeding – Michigan, 2002. *MMWR Morb Mortal Wkly Rep* 2002;51(39):877–8.
89. Bentlin MR, de Barros Almeida RA, Coelho KI, Ribeiro AF, Siciliano MM, Suzuki A, et al. Perinatal transmission of yellow fever, Brazil, 2009. *Emerg Infect Dis* 2011;17(9):1779–80.
90. Kuhn S, Twele-Montecinos L, MacDonald J, Webster P, Law B. Case report: probable transmission of vaccine strain of yellow fever virus to an infant via breast milk. *CMAJ* 2011;183(4):E243–5.
91. Chen LH, Wilson ME. Transmission of dengue virus without a mosquito vector: nosocomial mucocutaneous transmission and other routes of transmission. *Clin Infect Dis* 2004;39(6):e56–60.



92. Centers for Disease Control and Prevention (CDC). Laboratory-acquired West Nile virus infections – United States, 2002. *MMWR Morb Mortal Wkly Rep* 2002;**51**(50):1133–5.
93. Rigau-Perez JG, Vorndam AV, Clark GG. The dengue and dengue hemorrhagic fever epidemic in Puerto Rico, 1994–1995. *Am J Trop Med Hyg* 2001;**64**(1–2):67–74.
94. Iwamoto M, Jernigan DB, Guasch A, Trepka MJ, Blackmore CG, Hellinger WC, et al. Transmission of West Nile virus from an organ donor to four transplant recipients. *N Engl J Med* 2003;**348**(22):2196–203.
95. Centers for Disease Control and Prevention (CDC). Possible dialysis-related West Nile virus transmission – Georgia, 2003. *MMWR Morb Mortal Wkly Rep* 2004;**53**(32):738–9.
96. Leung GH, Baird RW, Druce J, Anstey NM. Zika virus infection in Australia following a monkey bite in Indonesia. *Southeast Asian J Trop Med Public Health* 2015;**46**(3):460–4.
97. Gourinat AC, O'Connor O, Calvez E, Goarant C, Dupont-Rouzeyrol M. Detection of Zika virus in urine. *Emerg Infect Dis* 2015;**21**(1):84–6.
98. Kuno G, Chang GJ, Tsuchiya KR, Karabatsos N, Cropp CB. Phylogeny of the genus flavivirus. *J Virol* 1998;**72**(1):73–83.
99. Cook S, Holmes EC. A multigene analysis of the phylogenetic relationships among the flaviviruses (Family: Flaviviridae) and the evolution of vector transmission. *Arch Virol* 2006;**151**(2):309–25.
100. Haddow AD, Schuh AJ, Yasuda CY, Kasper MR, Heang V, Huy R, et al. Genetic characterization of Zika virus strains: geographic expansion of the Asian lineage. *PLoS Negl Trop Dis* 2012;**6**(2):e1477.
101. Kuno G, Chang GJ. Full-length sequencing and genomic characterization of Bagaza, Kedougou, and Zika viruses. *Arch Virol* 2007;**152**(4):687–96.
102. Lanciotti RS, Kosoy OL, Laven JJ, Velez JO, Lambert AJ, Johnson AJ, et al. Genetic and serologic properties of Zika virus associated with an epidemic, Yap State, Micronesia, 2007. *Emerg Infect Dis* 2008;**14**(8):1232–9.
103. Faye O, Faye O, Diallo D, Diallo M, Weidmann M, Sall AA. Quantitative real-time PCR detection of Zika virus and evaluation with field-caught mosquitoes. *Virol J* 2013;**10**:311.
104. Lindenbach BD, Rice CM. Molecular biology of flaviviruses. *Adv Virus Res* 2003;**59**:23–61.
105. Chavez JH, Silva JR, Amarilla AA, Moraes Figueiredo LT. Domain III peptides from flavivirus envelope protein are useful antigens for serologic diagnosis and targets for immunization. *Biologicals* 2010;**38**(6):613–8.
106. Tsetsarkin KA, Vanlandingham DL, McGee CE, Higgs S. A single mutation in chikungunya virus affects vector specificity and epidemic potential. *PLoS Pathog* 2007;**3**(12):e201.
107. de Melo Freire CC, Iamarino A, de Lima Neto DF, Sall AA, de Andrade Zanotto PM. Spread of the pandemic Zika virus lineage is associated with NS1 codon usage adaptation in humans. *bioRxiv* 2015. <http://dx.doi.org/10.1101/032839> [Epub ahead of print].
108. Hamel R, Dejarnac O, Wichit S, Ekchariyawat P, Neyret A, Luplertlop N, et al. Biology of Zika virus infection in human skin cells. *J Virol* 2015;**89**(17):8880–96.
109. Carneiro LA, Travassos LH. Autophagy and viral diseases transmitted by *Aedes aegypti* and *Aedes albopictus*. *Microbes Infect* 2016. pii: S1286–4579(16)00004-6. [Epub ahead of print].
110. Bell TM, Field EJ, Narang HK. Zika virus infection of the central nervous system of mice. *Arch Gesamte Virusforsch* 1971;**35**(2):183–93.
111. Weinbren MP, Williams MC. Zika virus: further isolations in the Zika area, and some studies on the strains isolated. *Trans R Soc Trop Med Hyg* 1958;**52**(3):263–8.
112. Kuno G. Persistence of arboviruses and antiviral antibodies in vertebrate hosts: its occurrence and impacts. *Rev Med Virol* 2001;**11**(3):165–90.
113. Rudolph KE, Lessler J, Moloney RM, Kmush B, Cummings DA. Incubation periods of mosquito-borne viral infections: a systematic review. *Am J Trop Med Hyg* 2014;**90**(5):882–91.
114. European Centre for Disease Prevention and Control (ECDC). *Rapid risk assessment: Zika virus infection outbreak, French Polynesia*. 14 February 2014. Available from: <http://ecdc.europa.eu/en/publications/Publications/Zika-virus-French-Polynesia-rapid-risk-assessment.pdf>.
115. Iloos S, Mallet HP, Leparac Goffart I, Gauthier V, Cardoso T, Herida M. Current Zika virus epidemiology and recent epidemics. *Med Mal Infect* 2014;**44**(7):302–7.
116. Campos GS, Bandeira AC, Sardi SI. Zika virus outbreak, Bahia, Brazil. *Emerg Infect Dis* 2015;**21**(10):1885–6.
117. Simpson DI. Zika virus infection in man. *Trans R Soc Trop Med Hyg* 1964;**58**:335–8.
118. Heang V, Yasuda CY, Sovann L, Haddow AD, Travassos da Rosa AP, Tesh RB, et al. Zika virus infection, Cambodia, 2010. *Emerg Infect Dis* 2012;**18**(2):349–51.
119. Arzuza-Ortega L, Polo A, Pérez-Tatis G, López-García H, Parra E, Pardo-Herrera LC, et al. Fatal Zika virus infection in girl with sickle cell disease, Colombia. *Emerg Infect Dis* 2016. <http://dx.doi.org/10.3201/eid2205.151934> [Epub ahead of print].
120. Oehler E, Watrin L, Larre P, Leparac-Goffart I, Lastere S, Valour F, et al. Zika virus infection complicated by Guillain-Barre syndrome – case report, French Polynesia, December 2013. *Euro Surveill* 2014;**19**(9).
121. European Centre for Disease Prevention and Control (ECDC). *Rapid risk assessment – Zika virus epidemic in the Americas: potential association with microcephaly and Guillain-Barré syndrome*. 10 December 2015. Available from: <http://ecdc.europa.eu/en/publications/Publications/zika-virus-americas-association-with-microcephaly-rapid-risk-assessment.pdf>.
122. Ventura CV, Maia M, Bravo-Filho V, Gois AL, Belfort Jr R. Zika virus in Brazil and macular atrophy in a child with microcephaly. *Lancet* 2016;**387**(10015):228.
123. British Broadcasting Corporation (BBC) News. *Colombia links Zika to rare nerve disorder deaths*. 5 February 2016. Available from: <http://www.bbc.com/news/health-35506726>.
124. Calvet GA, Filippis AM, Mendonça MC, Sequeira PC, Siqueira AM, Veloso VG, et al. First detection of autochthonous Zika virus transmission in a HIV-infected patient in Rio de Janeiro, Brazil. *J Clin Virol* 2016;**74**:1–3.
125. Mlakar J, Korva M, Tul N, Popovic M, Poljsak-Prijatelj M, Mraz J, et al. Zika virus associated with microcephaly. *N Engl J Med* 2016 [Epub ahead of print].
126. Ventura CV, Maia M, Ventura BV, Linden VV, Araujo EB, Ramos RC, et al. Ophthalmological findings in infants with microcephaly and presumable intra-uterus Zika virus infection. *Arq Bras Oftalmol* 2016;**79**(1):1–3.
127. de Paula Freitas B, de Oliveira Dias JR, Prazeres J, Sacramento GA, Ko AI, Maia M, et al. Ocular findings in infants with microcephaly associated with presumed Zika virus congenital infection in Salvador, Brazil. *JAMA Ophthalmol* 2016. <http://dx.doi.org/10.1001/jamaophthalmol.2016.0267> [Epub ahead of print].
128. Oliveira Melo AS, Malingier G, Ximenes R, Szejnfeld PO, Alves Sampaio S, Bispo de Filippis AM. Zika virus intrauterine infection causes fetal brain abnormality and microcephaly: tip of the iceberg? *Ultrasound Obstet Gynecol* 2016;**47**(1):6–7.
129. Butler D. Zika virus: Brazil's surge in small-headed babies questioned by report. *Nature* 2016;**530**(7588):13–4.
130. Silasi M, Cardenas I, Kwon JY, Racicot K, Aldo P, Mor G. Viral infections during pregnancy. *Am J Reprod Immunol* 2015;**73**(3):199–213.
131. Nogueira RM, Miagostovich MP, Cavalcanti SM, Marzochi KB, Schatzmayr HG. Levels of IgM antibodies against dengue virus in Rio de Janeiro, Brazil. *Res Virol* 1992;**143**(6):423–7.

132. Roehrig JT, Nash D, Maldin B, Labowitz A, Martin DA, Lanciotti RS, et al. Persistence of virus-reactive serum immunoglobulin m antibody in confirmed West Nile virus encephalitis cases. *Emerg Infect Dis* 2003;9(3):376–9.
133. Prince HE, Tobler LH, Lape-Nixon M, Foster GA, Stramer SL, Busch MP. Development and persistence of West Nile virus-specific immunoglobulin M (IgM), IgA, and IgG in viremic blood donors. *J Clin Microbiol* 2005;43(9):4316–20.
134. Busch MP, Kleinman SH, Tobler LH, Kamel HT, Norris PJ, Walsh I, et al. Virus and antibody dynamics in acute west nile virus infection. *J Infect Dis* 2008;198(7):984–93.
135. Faye O, Faye O, Dupressoir A, Weidmann M, Ndiaye M, Alpha Sall A. One-step RT-PCR for detection of Zika virus. *J Clin Virol* 2008;43(1):96–101.
136. Balm MN, Lee CK, Lee HK, Chiu L, Koay ES, Tang JW. A diagnostic polymerase chain reaction assay for Zika virus. *J Med Virol* 2012;84(9):1501–5.
137. Maher-Sturgess SL, Forrester NL, Wayper PJ, Gould EA, Hall RA, Barnard RT, et al. Universal primers that amplify RNA from all three flavivirus subgroups. *Virology* 2008;381(1):16–21.
138. Atkinson B, Hearn P, Afrough B, Lumley S, Carter D, Aarons EJ, et al. Detection of Zika virus in semen. *Emerg Infect Dis* 2016. <http://dx.doi.org/10.3201/eid2205.160107> [Epub ahead of print].
139. Petersen EE, Staples JE, Meaney-Delman D, Fischer M, Ellington SR, Callaghan WM, et al. Interim Guidelines for pregnant women during a Zika virus outbreak – United States, 2016. *MMWR Morb Mortal Wkly Rep* 2016;65(2):30–3.
140. Staples JE, Dziuban EJ, Fischer M, Cragan JD, Rasmussen SA, Cannon MJ, et al. Interim Guidelines for the evaluation and testing of infants with possible congenital Zika virus infection – United States, 2016. *MMWR Morb Mortal Wkly Rep* 2016;65(3):63–7.
141. Hennessey M, Fischer M, Staples JE. Zika virus spreads to new areas – region of the Americas, May 2015–January 2016. *MMWR Morb Mortal Wkly Rep* 2016;65(3):55–8.
142. Iturbe-Ormaetxe I, Walker T, SL ON. Wolbachia and the biological control of mosquito-borne disease. *EMBO Rep* 2011;12(6):508–18.
143. Marano G, Pupella S, Vaglio S, Liumbruno GM, Grazzini G. Zika virus and the never-ending story of emerging pathogens and transfusion medicine. *Blood Transfus* 2015:1–6.
144. Dyer O. Jamaica advises women to avoid pregnancy as Zika virus approaches. *BMJ* 2016;352:i383.
145. Ishikawa T, Yamanaka A, Konishi E. A review of successful flavivirus vaccines and the problems with those flaviviruses for which vaccines are not yet available. *Vaccine* 2014;32(12):1326–37.
146. Moore DL, Causey OR, Carey DE, Reddy S, Cooke AR, Akinkugbe FM, et al. Arthropod-borne viral infections of man in Nigeria, 1964–1970. *Ann Trop Med Parasitol* 1975;69(1):49–64.
147. Duong V, Vong S, Buchy P. Dengue and other arboviral diseases in South-East Asia. *Med Trop (Mars)* 2009;69(4):339–44.
148. Cao-Lormeau VM, Roche C, Teissier A, Robin E, Berry AL, Mallet HP, et al. Zika virus, French polynesia, South pacific, 2013. *Emerg Infect Dis* 2014;20(6):1085–6.
149. Musso D, Nilles EJ, Cao-Lormeau VM. Rapid spread of emerging Zika virus in the Pacific area. *Clin Microbiol Infect* 2014;20(10):O595–6.
150. Zanolini C, de Melo VC, Mosimann AL, Dos Santos GI, Dos Santos CN, Luz K. First report of autochthonous transmission of Zika virus in Brazil. *Mem Inst Oswaldo Cruz* 2015;110(4):569–72.
151. Dyer O. Zika virus spreads across Americas as concerns mount over birth defects. *BMJ* 2015;351:h6983.
152. Fontes BM. Zika virus-related hypertensive iridocyclitis. *Arq Bras Oftalmol* 2016;79(1):63.
153. Filipe AR, Martins CM, Rocha H. Laboratory infection with Zika virus after vaccination against yellow fever. *Arch Gesamte Virusforsch* 1973;43(4):315–9.