



RoboticScope-Assisted Microanastomosis in a Chicken Leg Model

Adi Ahmetpahic^{1,2} Eldin Burazerovic¹ Dragan Jankovic^{3,4} Eleonora Kujaca² Hana Rizvanovic²
Ibrahim Omerhodzic^{1,5} Haso Sefo¹ Nermir Granov⁵

¹Department of Neurosurgery, Clinical Center of the University of Sarajevo, Bolnička 25, Sarajevo, Bosnia and Herzegovina

²Department of Medicine, Sarajevo School of Science of Technology, Hrasnicka cesta 3a, Sarajevo, Bosnia and Herzegovina

³Department of Neurosurgery, University Medical Center of the Johannes Gutenberg University of Mainz, Mainz, Germany

⁴Department of Medicine, Josip Juraj Strossmayer University, Trg Svetog Trojstva3, Osijek, Croatia

⁵Department of Medicine, University of Sarajevo, Cekalusa 90, Sarajevo, Bosnia and Herzegovina

Address for correspondence Adi Ahmetpahic, MD, Clinical Center of the University of Sarajevo, Bolnička 25, Sarajevo, 71000, Bosnia and Herzegovina (e-mail: adi.ahmetpahic@ssst.edu.ba).

Asian J Neurosurg 2023;18:782–789.

Abstract

Background Many recent studies show that exoscopes are safe and effective alternatives to operating microscopes (OM). Developments of robotics and automation are present in neurosurgery with the appearance of a newer device such as RoboticScope (RS) exoscope with a digital three-dimensional (3D) image and a head-mounted display. The body of the RS is connected to a six-axis robotic arm that contains two video cameras, and serves as stereovision. This robotic arm allows accurate 3D camera motions over the field of view, giving the user a great degree of freedom in viewpoint selection. The surgeons may specify the direction and speed of the robotic arm using simple head movements when the foot pedal is pressed. Since its development in 2020, the RS has occasionally been used in neurosurgery for a multitude of procedures.

Methods This study showcases vessel microanastomosis training on chicken legs using the RS. The aim of this study is to demonstrate the feasibility of the RS without a comparative analysis of the standard OM. The study was conducted in 2023 during a month-long trial period of the device at the Department of Neurosurgery of the Clinical Center of the University of Sarajevo. All procedures including RS-assisted anastomosis were performed by a neurosurgeon in anastomosis training (A.A.) supervised by a senior vascular neurosurgeon (E.B.). For the purpose of the study, we evaluated occlusion time in minutes, bypass patency with iodine, and overall satisfaction of the trainee in terms of light intensity, precision of automatic focus, mobility of the device, ergonomics, and convenience of the helmet.

Results Ten RS-assisted microanastomoses were performed by interrupted suturing technique with 10.0 nylon thread. Bypass training included seven “end-to-side,” two

Keywords

- ▶ anastomosis
- ▶ microanastomosis training
- ▶ microsurgery
- ▶ ergonomics
- ▶ exoscope

DOI <https://doi.org/10.1055/s-0043-1776794>.
ISSN 2248-9614.

© 2023. Asian Congress of Neurological Surgeons. All rights reserved.

This is an open access article published by Thieme under the terms of the Creative Commons Attribution-NonDerivative-NonCommercial-License, permitting copying and reproduction so long as the original work is given appropriate credit. Contents may not be used for commercial purposes, or adapted, remixed, transformed or built upon. (<https://creativecommons.org/licenses/by-nc-nd/4.0/>)

Thieme Medical and Scientific Publishers Pvt. Ltd., A-12, 2nd Floor, Sector 2, Noida-201301 UP, India

“end-to-end,” and one “side-to-side” microanastomoses. The smallest vessel diameter was 1 mm. Occlusion time improved by training from 50 to 24 minutes, with contrast patency of the anastomoses in all cases without notable leakage of the contrast, except one case. Complete satisfaction of the trainee was achieved in 7 out of 10 cases. During this period, we also performed different RS-assisted surgeries including a single indirect bypass, convexity brain tumor resection, and microdissectomies.

Conclusion RS provides a new concept for microanastomosis training as an alternative or adjunct to the standard microscope. We found a full-time hands-on microsuturing without the need for manual readjustment of the device as an advantage as well as instant depth at automatic zooming and precise transposition of the focus via head movements. However, it takes time to adapt and get used to the digital image. With the evolution of the device helmet’s shortcomings, the RS could represent a cutting-edge method in vessel microanastomosis in the future. Nevertheless, this article represents one of the first written reports on microanastomosis training on an animal model with the above-mentioned device.

Introduction

The operative microscope (OM) has been an irreplaceable tool in the field of intracranial pathologies since the middle of the last century until the present date. In recent decades, it was impossible to imagine a neurosurgical operating room without an OM. The use of OM contributed to reduced morbidity and mortality, while surgeons developed new operative techniques, making many inoperable cases operable. However, the daily progress of technology, the emergence of digitalization, and the development of advanced optics provided the basis for the development of new devices such as the exoscope.¹ The emphasis today has switched to obtaining the greatest possible view of the operating field at all times.² With any exoscope, the surgeon was given a wider field of view, while the introduction of the three-dimensional (3D) exoscope enabled a high-resolution 3D image. There were a variety of responses to the image quality, with more critical remarks being made about the image quality at high magnification. Seeing picture distortion and pixelation at the greatest magnification were reported.³ To overcome the disadvantages of exoscopes, a robotic-assisted exoscope known as RoboticScope (RS; BHS Technologies, Innsbruck, Austria) was recently created.⁴ The RS presents a view-changing full digital 3D micro/exoscope that transmits a high-resolution image via a 3D camera to the screen in front of the surgeon’s eyes. Recent research has reported on the technical feasibility and safety of the RS for neurosurgical use in cranial procedures. Previous studies have shown that exoscopes, as well as the RS, are effective alternatives or adjuncts to binocular OM for brain tumors, skull base surgery, treatment of intracranial aneurysms, and vascular microanastomoses.^{5–8} To efficiently perform high-quality revascularization, in addition to practicing microvascular anastomosis, stereopsis, and high optical resolutions are necessary for proper visualization.⁹ The RS, which works similarly to virtual reality goggles, projects visuals from

external screens right in front of the user’s eyes. The RS is made up of a head-mounted display (HMD) with two video cameras that are connected to a six-axis robotic arm. By using LED-based illumination, the danger of thermal injury to the brain tissue during microsurgical procedures is also minimized since they produce less heat.⁸ The robotic arm allows for accurate 3D camera motions over the surgical field, giving the user a great degree of freedom in viewpoint selection. The RS guarantees that any viewpoint shift, even when examining the smallest structures, may be chosen or modified with the utmost precision of ± 0.03 mm. The surgeons may specify the direction and speed of the movement using simple, intuitive head movements when the foot pedal is pressed. Consequently, operating with the robotic arm is a completely hands-free task and this represents a significant benefit of the RS. The system also enables the recording and storing of images or videos on external storage devices so that the obtained operating footage may be revisited.⁴

Materials and Methods

The aim of this study was to demonstrate the feasibility of the RS as a microsuturing training tool without a comparative analysis of standard microscopy and microsurgery procedures. The study was conducted at the Department of Neurosurgery of the Clinical Center of the University of Sarajevo during a 1-month device trial period in 2023. Given that we used a chicken leg model for the purpose of the study, the approval of the ethics committee of the institution was not required.

For this research, we conducted RS-assisted vessel microanastomoses and thoroughly examined the device’s technical constraints and capabilities. The standard microscopic suturing technique earlier adopted by author A.A. during the cerebrovascular fellowship at Fujita Health University, Bantanne Hotokukai Hospital, Nagoya, Japan, under the mentorship of Professor Yoko Kato, and University Wisconsin (UW) Hospital, Madison, United States under the mentorship of

Professor Mustafa Baskaya was implemented at RS-assisted microanastomosis in all cases. We evaluated occlusion time, vessel size, and bypass patency using iodine contrast. Overall satisfaction of the trainee with the practicality of the device was evaluated in terms of the comfort with the system. We analyzed five different aspects of the device in numerical values from 0 to 1, the latter being complete satisfaction with the product and the outcome of the training procedure. The comfort aspects included light intensity, quality of image, precision of automatic focus, speed of adjustment, and convenience with the helmet of the system. To explore the feasibility and potential of the device we also performed multiple brain surgeries including convexity and skull base tumors as well as a single indirect anastomosis.

Results

A total of ten microanastomoses have been performed by interrupted suturing technique with a 10.0 nylon thread. To explore different bypass possibilities, microanastomosis training included “end-to-side” in six, “side-to-side” in three as well as “end-to-end” in one case. The smallest diameter of the sutured vessels was 1 mm, whereas the largest was 4 mm. Occlusion time was improved by training from 50 minutes in the first case to 24 minutes in the last case (mean = 33 minute), with contrast patency of the anastomoses in all cases. Significant leakage of the contrast was noted in only one performed anastomosis, which required an additional stitch.

An average of six stitches were used per model on one side. The zoom used for stitching the vessel was approximately 2x greater than the zoom used for making the knot. The camera distance ranged from 300 to 600 mm depending on the action. Readjustment and opening of the headset glasses were required approximately two and three times, respectively. A light intensity increase was necessary in 7 out of 10 procedures. The average size of the recipient vessel opening was 3.6 mm, while the depth of work averaged 2.7 cm from the surface of the model.

Complete satisfaction was achieved in 7 out of 10 cases with a pronounced progressive increase in the comfort of the trainee. The ratings primarily refer to the need to occasionally lift the glasses and reposition the display when they were in an inadequate position, the need for repositioning of the helmet because of sliding down, too much pressure on the helmet strap, or interpupillary distance readjustment. We reported 4 out of 10 procedures where the helmet strap produced tension-like discomfort and had to be released. Eye fatigue was observed in eight instances following an approximate 20- to 30-minute duration of work. There were no reported issues regarding work-related musculoskeletal disorder (WMD), head or neck pain in any of the 10 cases. The laboratory setting, as well as examples of the procedures, is presented in ►Figs. 1 to 4. Examples of live RS-assisted surgeries are shown in ►Figs. 5 to 6.

The numerical results are introduced in ►Tables 1 and 2.

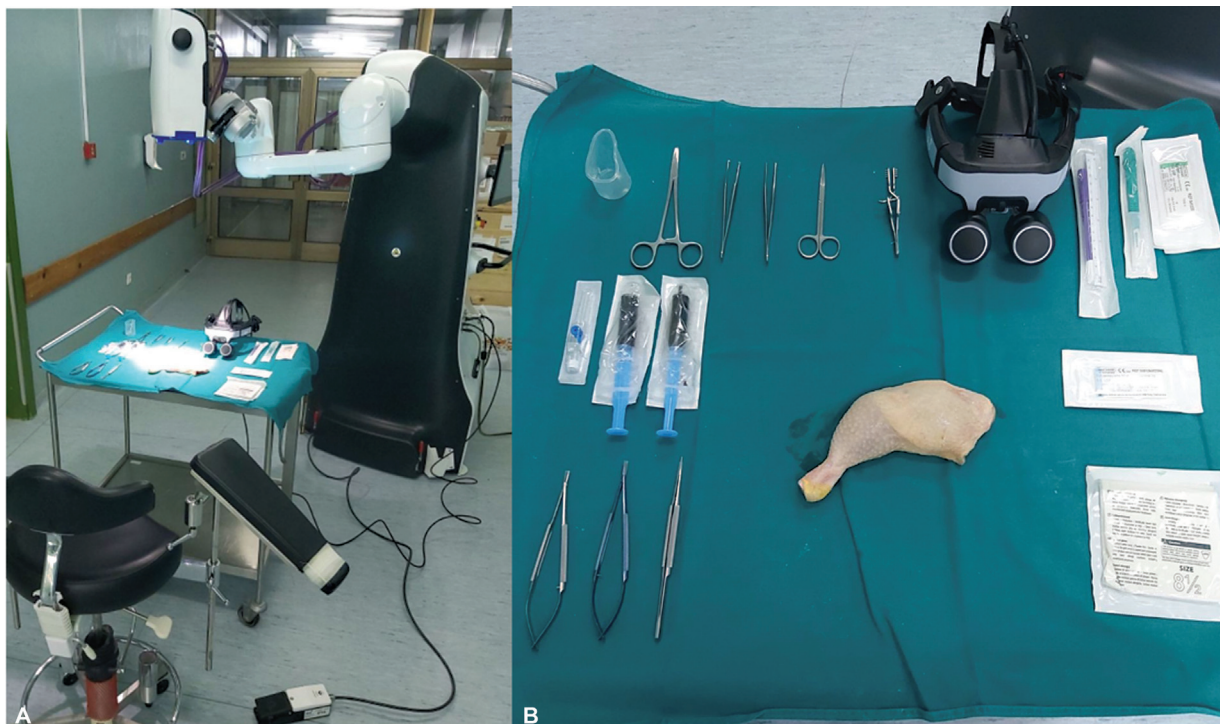


Fig. 1 (A) Laboratory setup for training at the Department of Neurosurgery of the Clinical Center of the University of Sarajevo. The RoboticScope (RS; BHS Technologies, Innsbruck, Austria) device is in the background; table and surgical chair are used. (B) Training tools are set. Upper left: Surgical instruments for the dissection and iodine contrast. Lower left: Microinstruments for the suturing. Upper right: RS helmet with integrated display for the visualization, scalpel, and thread. Lower right: surgical gloves.

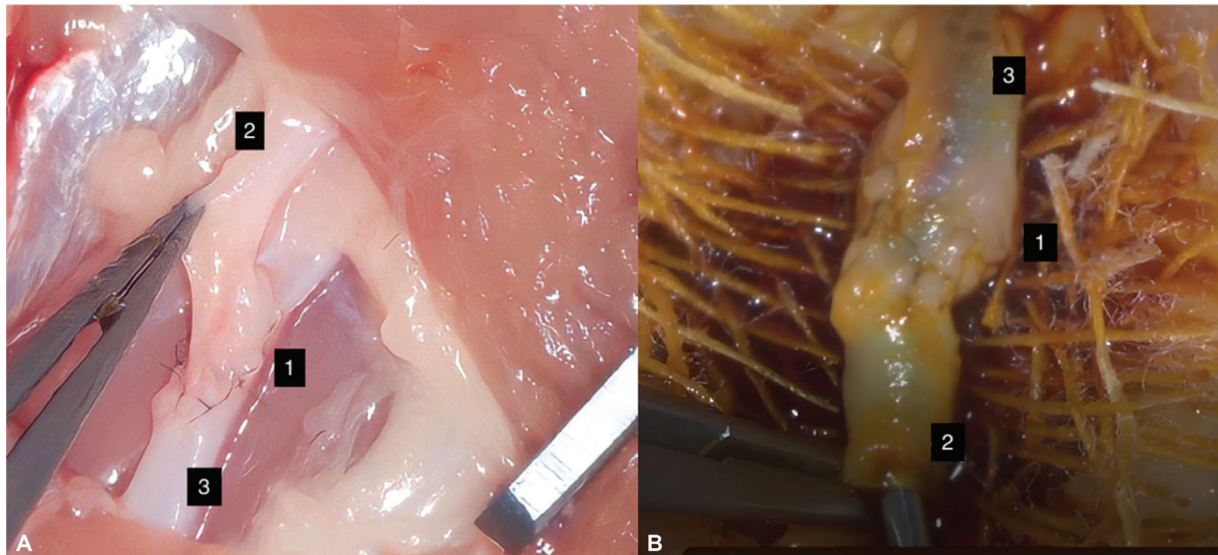


Fig. 2 (A) Case 1: End-to-side RoboticScope-assisted microanastomosis; imitation of the superficial temporal artery—middle cerebral artery bypass. The donor artery was lifted with forceps. No major defects are visible in the area of the microanastomosis after the placement of the sutures. (B) Case 1: Bypass patency is confirmed using iodine. The number 1 marks the gauze with some of the contrast leakage under but none at the site of the anastomosis. Number 2 marks the recipient artery under which a puncture is made. Number 3 marks the donor artery.

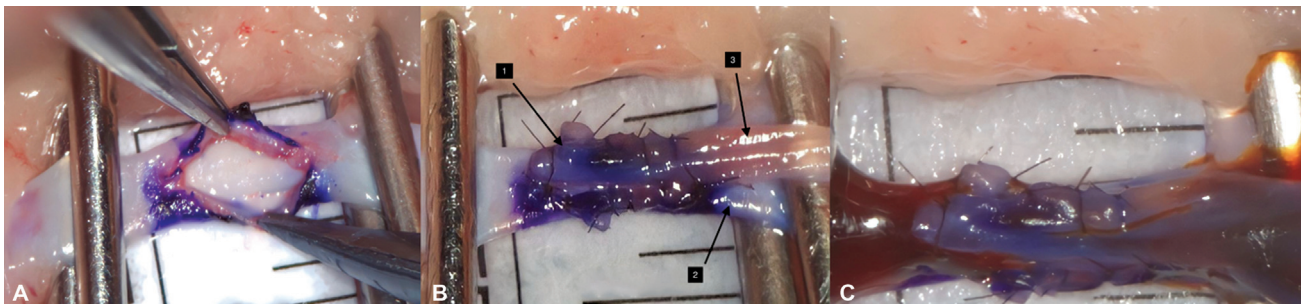


Fig. 3 (A) Case 2: Another example of end-to-side RoboticScope-assisted microanastomosis. The recipient's vessel has been prepared and opened. Purple color is used to mark the edges of the fenestration for easier suturing of the back wall of the anastomosis. Two clips were used to imitate a live situation with temporary occlusion. The caliber of the recipient vessel is 2 mm. (B) Case 2: The fish mouth technique was employed for the RS microanastomosis. A simple interrupted stitch was used for suturing with a 10.0 nylon thread. The caliber of the best dissected donor vessel is measured at 1 mm. (C) Case 2. Bypass patency after iodine administration. Small leakage of the contrast on the distal portion of the anastomosis is verified. Additional stitch has been applied to close the gap.

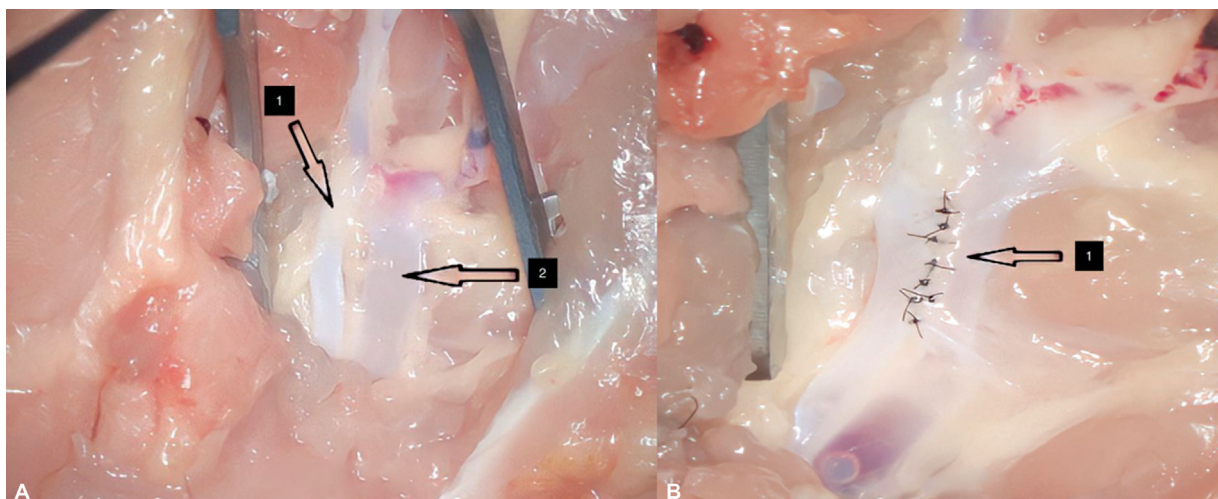


Fig. 4 (A) Case 3: Example of side-to-side RoboticScope-assisted microanastomosis. Two arteries have been dissected and prepared for the anastomosis. (B) Case 3: A simple interrupted stitch was used for suturing (arrow). There is no gap at the proximal and distal portions.

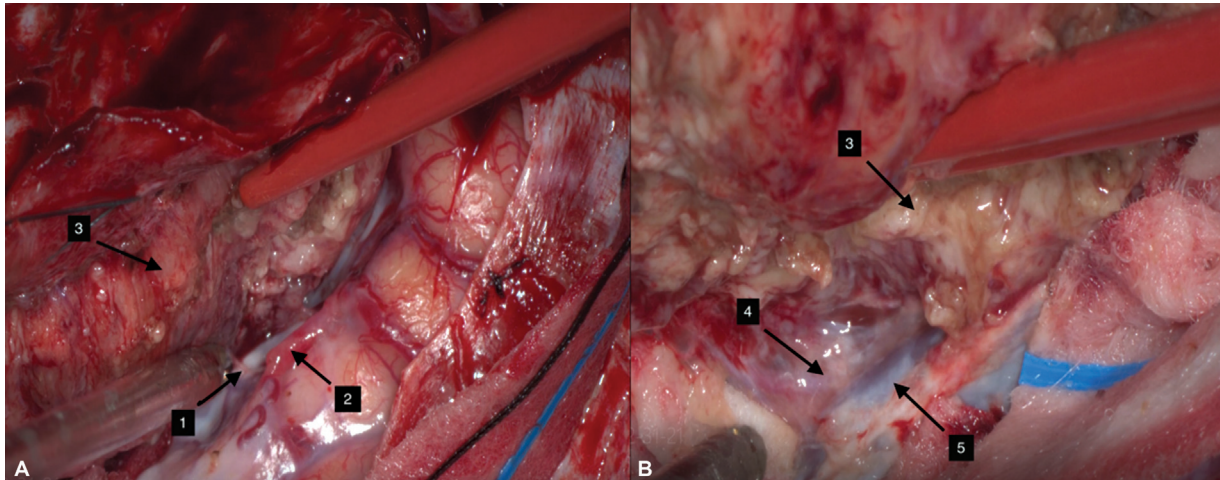


Fig. 5 (A) Example of the RoboticScope (RS)-assisted resection of the giant convexity meningioma in the left temporofrontal location in 450 X zoom. Surgery is performed by author A.A. during the same period of trial of the RS device. The phase of the surgery is the detachment of the tumor from the normal arterial vessels on the surface of the Sylvian fissure. Please note the high image resolution quality and focused light. Number 1 marks the small feeding branch of the tumor; 2 marks the M4/M5 branch of the left middle cerebral artery, 3 marks the tumor; (B) Same example in 600 X zoom. There is no significant change in the quality of the image and illumination. The tumor is now detached from Sylvian veins in depth following the arachnoid layer. At the final stage, the tumor was resected in one piece; Number 4 marks the arachnoid layer, 5 marks the Sylvian vein.

Discussion

Modern neurosurgery reached a turning point with the invention of the OM since it enabled the optical tools required to visualize the operative field during microsurgical procedures in an improved manner. Good visual magnification of the operating field is necessary to perform satisfactory microvascular procedures.⁴ Nonetheless, using conventional microscopes might limit intraoperative vision and cause ergonomic problems.⁸ The head-mounted microdisplays pro-

vide exceptional image quality and a fully immersive viewing experience. The 3D camera of this digital exoscope offers an improved stereoscopic vision, providing superior depth awareness, in contrast to most contemporary exoscopic instruments.¹⁰ A key benefit of digital instruments is the ability to adjust color hues and other optical characteristics in the most advantageous way to the surgeon. The neurosurgeon is able to learn more about the structural features seen throughout the surgical operation thanks to color separation and contrast modulation. One of the advantages of the RS

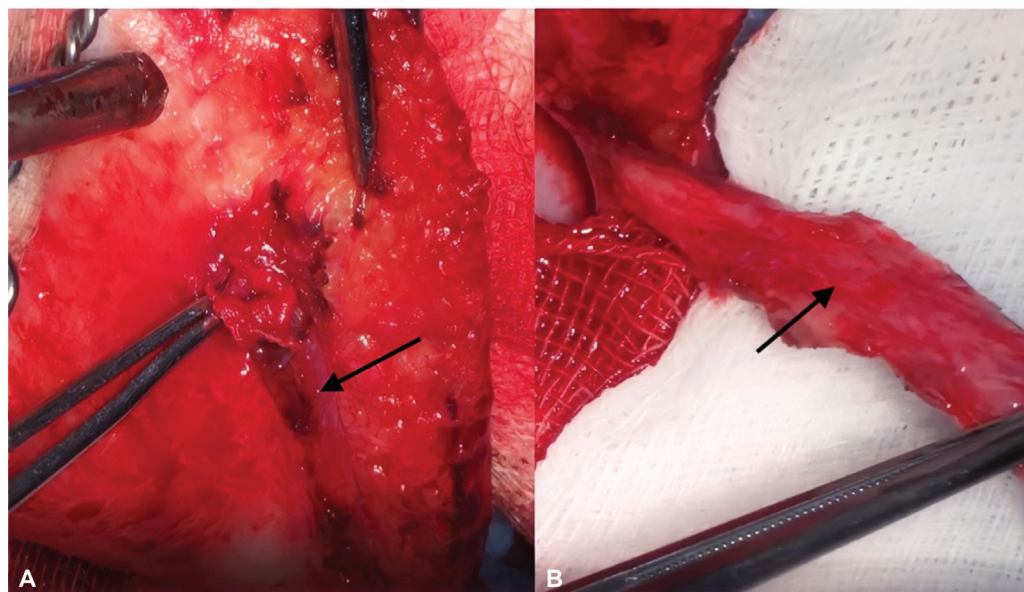


Fig. 6 (A) Example of the RoboticScope-assisted dissection of superficial temporal artery (STA) with perivascular connective tissue on the right side in 300 X zoom performed by A.A. in the study period. The graft was used for indirect anastomosis in the patient with a skull base tumor and steno-occlusive disease. (B) The arrow marks the STA graft which has been prepared for the dissection of the perivascular connective tissue.

Table 1 Assessment of RoboticScope-assisted microanastomoses

| | Size of the model vessel (mm) | Anastomosis type | Occlusion time (min) | Significant contrast leakage | Number of stitches by each side of the anastomosis | Additional stitch | Depth of the work from the surface of the wing (cm) | Size of anastomotic opening (cm) |
|----|-------------------------------|------------------|----------------------|------------------------------|--|-------------------|---|----------------------------------|
| 1 | 4 | End to side | 50 | Y | 5 | Y | 2 | 3 |
| 2 | 2 | Side to side | 35 | N | 6 | N | 2 | 4 |
| 3 | 1 | End to end | 35 | N | 5 | N | 4 | 2 |
| 4 | 3 | Side to side | 40 | N | 5 | N | 2 | 3 |
| 5 | 4 | End to side | 31 | N | 6 | N | 3 | 4 |
| 6 | 2 | End to side | 33 | N | 6 | N | 2 | 4 |
| 7 | 3 | End to side | 28 | N | 5 | N | 2 | 5 |
| 8 | 3 | End to side | 25 | N | 6 | N | 4 | 3 |
| 9 | 3 | End to side | 25 | N | 6 | N | 4 | 4 |
| 10 | 3 | Side to side | 24 | N | 5 | N | 3 | 4 |

Abbreviations: cm, centimeter; min, minute; mm, millimeter; N, no; Y, yes.

exoscope is that it is positioned high above the surgical field allowing for greater maneuverability of surgical instruments and typically no need for manual readjustment. The working distance of the OM is maximally 350 mm, whereas that of the RS reaches up to 600 mm.^{11,12} In our study, we used distances from 300 to 600 mm without notable influence on the visual perspective or position of the instruments. A distance of 300 mm showed a potential to collide with the surgeon when the device was moved in a posteroinferior position, that is, anterosuperior of the field point of interest. However, a distance of 450 mm was found as most convenient in terms of light intensity and focus

quality. The usage of the RS allows a delicate and exact portrayal of millimeter-sized anatomical features with a wide range of magnification up to a factor of 36. RS magnification of 34,4x is superior to that of the OM, averaging 12.5x.¹⁰ During our procedures, the camera zoom ranged from 2x to 5x, depending on the task at hand, whether it was to determine the end of the thread, place the knot, or position the suture on both sides of the vessel wall.

There are no significant modifications needed for the RS to be used in the operating room. The surgeon sits in a physiological position and directs their gaze straight ahead

Table 2 Technical details and surgeon's report on the RS exoscope

| | Zoom used for making the knot | Zoom used for stitching | Camera distance | Glasses opening | Glasses repositioning | Need for relaxation of glasses strip | Light increase | WMDs | Neck and head ergonomics | Eye fatigue | Overall satisfaction |
|----|-------------------------------|-------------------------|-----------------|-----------------|-----------------------|--------------------------------------|----------------|------|--------------------------|-------------|----------------------|
| 1 | 2x | 4x | 450 | 2x | 3x | Y | Y | N | Y | Y | 0 |
| 2 | 2x | 4x | 300 | 5x | 4x | Y | N | N | Y | Y | 0 |
| 3 | 2x | 5x | 450 | 5x | 2x | N | Y | N | Y | N | 1 |
| 4 | 3x | 4x | 450 | 2x | 4x | Y | N | N | Y | Y | 1 |
| 5 | 2x | 5x | 600 | 3x | 2x | Y | Y | N | Y | Y | 0 |
| 6 | 3x | 5x | 450 | 2x | 1x | N | Y | N | Y | Y | 1 |
| 7 | 3x | 4x | 450 | 3x | 1x | N | Y | N | Y | Y | 1 |
| 8 | 3x | 5x | 450 | 2x | 2x | N | Y | N | Y | Y | 1 |
| 9 | 3x | 5x | 300 | 1x | 1x | N | Y | N | Y | Y | 1 |
| 10 | 2x | 5x | 450 | 2x | 1x | N | Y | N | Y | N | 1 |

Abbreviations: 0, no satisfaction; 1, full satisfaction with the comfort and practicality of the device; N, no; RS, RoboticScope; WMD, work-related musculoskeletal disorders; x, times; Y, yes.

at the HMD's glasses microdisplays, while the detached camera is positioned immediately above the surgical field.⁸ Since the use of microscopes sometimes necessitates an unergonomic stance, surgeons may experience neck discomfort and according to research by Khansa et al, 79% of surgeons have neck discomfort and stiffness; in 27% of cases, the pain occurs while or after using a microscope. This can make it difficult for them to focus, and over time, the cervical spine may develop degenerative changes.^{10–13} In our study, the surgeon has reported positive experiences regarding head and neck ergonomics while using the RS, which is consistent with the literature. Hence, especially in surgeons with high operating caseloads, display-based exoscopes might play a significant role in avoiding WMDs. By searching the literature, we have not found any WMD report with the new RS device which we also do not report in our study. However, we noted visual fatigue as extreme discomfort, which has not been encountered in the reviewed literature. One of the potential causes of visual fatigue could be the 3D picture displayed right in front of the user's eyes, at a distance of approximately 2 to 3 cm. Future studies should investigate the effects of short-distance displays on surgeons' eyesight.

The transfer of microsurgical skills from an OM to the RS is an undemanding process that is made progressively easier with practice. This information is consistent with the results of our study, where the first anastomosis was performed in 50 and the last in 24 minutes, with only one anastomosis that required one additional stitch due to the contrast leakage (→ **Table 1**). After several repetitions, it is demonstrated that training considerably reduces occlusion time. The occlusion time observed in our study was deemed satisfactory, given the fact that the procedures were performed by a young neurosurgeon using a novel device.

Due to the novelty of working with the RS, we reported some discomfort also related to the helmet. This is a consequence of the immersive nature of the HMD, whose weight (<500 g) also contributes to discomfort, but it resolves over time after an adjustment period. However, we have not experienced any other discomfort symptoms like dizziness in relatively short procedures. The lack of a secondary HMD is an obstacle that prevents a second surgeon/assistant from receiving the same high-quality operating aid with a 3D view of the surgical field, which could impact the achievability of the procedure.¹⁴

Limitations of the Study

This study has several limitations. A short trial period of the device has led to fewer performed procedures. A longer training period is necessary to include a larger sample to correlate the given variables with statistical analysis.

Conclusion

Robotic-assisted microanastomosis is a new and evolutionary modality for the training of young vascular neurosurgeons. Promising advantages are microsuturing

without the need for manual or pedal point of interest adjustment, instant depth at automatic zooming as well as precise transposition of the focus and dynamics of the device by simple head movements. However, it requires some time to get used to the helmet and novel digital image patterns in 3D glasses. With the evolution of the device's helmet shortcomings, the RS could represent a cutting-edge method in vessel microanastomosis in the future. Nevertheless, this article represents one of the first written reports on microanastomosis on an animal model with the RS.

Ethical Approval Statement

Given that it is a chicken leg model, the approval of the ethics committee of the institution was not required.

Authors' Contributions

A.A. was involved in investigation, methodology, project administration, and writing—review and editing. E.B. contributed to conceptualization. D.J. helped in investigation, writing—review and editing, and project administration. E.K. contributed to writing—original draft and preparation, visualization, conceptualization, and investigation. H.R. was involved in writing—original draft and preparation, visualization, conceptualization, and investigation. I.O. reviewed the manuscript. H.S. helped in validation. N.G. was involved in data curation.

Conflict of Interest

None declared.

References

- Ricciardi L, Chaichana KL, Cardia A, et al. The exoscope in neurosurgery: an innovative "Point of View". A systematic review of the technical, surgical, and educational aspects. *World Neurosurg* 2019;124:136–144
- Herlan S, Marquardt JS, Hirt B, Tatagiba M, Ebner FH. 3D exoscope system in neurosurgery—comparison of a standard operating microscope with a new 3D exoscope in the Cadaver Lab. *Oper Neurosurg (Hagerstown)* 2019;17(05):518–524
- Yeung W, Vakharia N, Johnatty C, Achar P, Kasbekar AV. Feasibility study of the Vitom 3D exoscope in ENT surgery using an animal model: relevance to coronavirus disease 2019. *J Laryngol Otol* 2021;135(08):710–717
- Boehm F, Schuler PJ, Riepl R, Schild L, Hoffmann TK, Greve J. Performance of microvascular anastomosis with a new robotic visualization system: proof of concept. *J Robot Surg* 2022;16(03):705–713
- Baron RB, Lakomkin N, Schupper AJ, et al. Postoperative outcomes following glioblastoma resection using a robot-assisted digital surgical exoscope: a case series. *J Neurooncol* 2020;148(03):519–527
- Wali AR, Kang KM, Rennert R, Santiago-Dieppa D, Khalessi AA, Levy M. First-in-human clinical experience using high-definition exoscope with intraoperative indocyanine green for clip reconstruction of unruptured large pediatric aneurysm. *World Neurosurg* 2021;151:52
- Hafez A, Elsharkawy A, Schwartz C, et al. Comparison of conventional microscopic and exoscopic experimental bypass anastomosis: a technical analysis. *World Neurosurg* 2020;135:e293–e299

- 8 Piloni M, Bailo M, Gagliardi F, Mortini P. Resection of intracranial tumors with a robotic-assisted digital microscope: a preliminary experience with robotic scope. *World Neurosurg* 2021;152:e205–e211
- 9 Belykh E, George L, Zhao X, et al. Microvascular anastomosis under 3D exoscope or endoscope magnification: a proof-of-concept study. *Surg Neurol Int* 2018;9(01):115
- 10 Abramovic A, Demetz M, Krigers A, et al. Surgeon's comfort: the ergonomics of a robotic exoscope using a head-mounted display. *Brain Spine* 2021;2:100855
- 11 Khansa I, Khansa L, Westvik TS, Ahmad J, Lista F, Janis JE. Work-related musculoskeletal injuries in plastic surgeons in the United States, Canada, and Norway. *Plast Reconstr Surg* 2018;141(01):165e–175e
- 12 Ma L, Fei B. Comprehensive review of surgical microscopes: technology development and medical applications. *J Biomed Opt* 2021;26(01):010901
- 13 Yoo H, Kim BJ. History and recent advances in microsurgery. *Archives Hand Microsurgery* 2021;26(03):174–183
- 14 Cui GY, Han XG, Wei Y, et al. Robot-assisted minimally invasive transforaminal lumbar interbody fusion in the treatment of lumbar spondylolisthesis. *Orthop Surg* 2021;13(07):1960–1968