

Case Report

Retro-odontoid pseudotumor with uncommon presentation of cervical spine injury

Shota Kikuta,¹ Satoshi Ishihara, Yukihisa Yagata, Shigenari Matsuyama,¹ and Shinichi Nakayama

Department of Emergency and Critical Care Medicine, Hyogo Emergency Medical Center, Kobe City, Hyogo, Japan

Background: We report the first case of retro-odontoid pseudotumor with an isolated symptom of C2–C3 dysesthesia triggered by a traumatic event.

Case Presentation: An 86-year-old man, who was a wood craftsman for more than 50 years, presented to the emergency room with sudden-onset severe posterior head and neck dysesthesia after accidentally falling backward. No neurological impairment of the extremities was noted. Computed tomography revealed a C2–C7 osteophyte formation, mainly in front of the vertebral bodies. Moreover, magnetic resonance imaging showed cervical spinal cord compression by a soft tissue mass posterior to the odontoid process of the axis. Therefore, we diagnosed a cervical spine injury with an isolated symptom of C2–C3 dysesthesia due to a retro-odontoid pseudotumor. He did not undergo surgical intervention and was transferred to a rehabilitation hospital on day 11 for pain control.

Conclusion: Our report could be useful to emergency physicians dealing with similar cases of cervical symptoms following trauma.

Key words: Cervical spine injury, neuropathic pain, retro-odontoid pseudotumor, spinal cord compression

INTRODUCTION

RETRO-odontoid pseudotumor is a condition wherein abnormal tissue formation is seen around the odontoid process, which causes cervicomedullary compression.¹ This condition has been increasingly diagnosed due to the more frequent use of magnetic resonance imaging (MRI) for the assessment of craniovertebral junction lesions.² In most of the retro-odontoid pseudotumor cases, the onset of symptoms involves progressive myelopathy, such as paralysis or paresthesia of extremities.¹ As far as we have examined, this is the first case report showing only dysesthesia of the occipital region without motor dysfunction after accidental trauma.

CASE REPORT

AN 86-year-old man, who was a wood craftsman for more than 50 years, presented to the emergency room with a sudden onset of severe posterior head and neck dysesthesia immediately after accidentally falling backwards. He had no rheumatoid arthritis or other joint-related generalized disease. He had hypertension, diabetes mellitus, and hydrocephalus. On initial examination, his respiratory and hemodynamic status was stable. There was no neurological impairment of his extremities, although he had nuchal dysesthesia. It particularly worsened when we touched his ears. No contusions were observed on his neck or ears; therefore, we initially suspected an upper cervical spine injury. However, computed tomography revealed anterior and posterior C2–C7 osteophyte formation without cervical fracture. When the image brightness was adjusted using the window level, it revealed a retro-odontoid mass extending from the posterior part of the axis up to the cranial base (Fig. 1). The MRI showed cervical spinal cord compression by a soft tissue mass posterior to the odontoid process of the axis, with high-intensity of the cervical spine at the C1–C2 level on T2-weighted imaging (WI). The mass was seen as an area of iso-intensity on T1-WI and of low-intensity on T2-WI (Fig. 2).

*Corresponding: Shota Kikuta, MD, Department of Emergency and Critical Care Medicine, Hyogo Emergency Medical Center, 1-3-1 Wakinohamakaigandori, Chuo-ku, Kobe City, Hyogo 651-0073, Japan. E-mail: s-kikuta@hemc.jp.

Received 22 Mar, 2021; accepted 8 Jul, 2021

Funding information

No funding information provided.

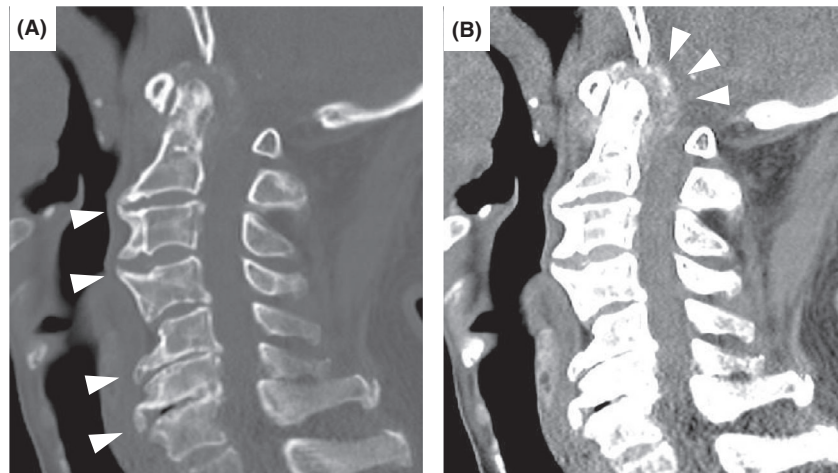


Fig. 1. Computed tomography (CT) scan on admission of an 86-year-old man with retro-odontoid pseudotumor. A, The slice showed C2–C7 osteophyte formation (white arrowheads). B, Sagittal slice revealed more obvious high-density area than on (A) (white arrowheads).

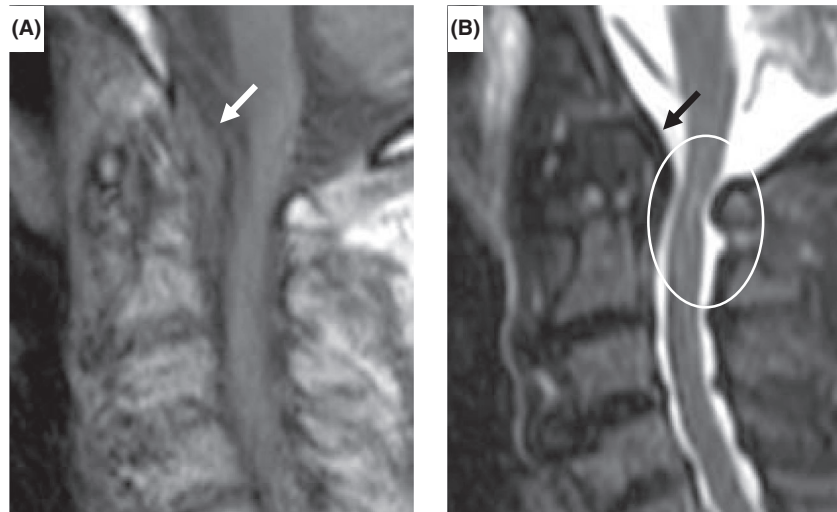


Fig. 2. Magnetic resonance imaging (MRI) on admission of an 86-year-old man with retro-odontoid pseudotumor. A, The mass was seen as an iso-intensity area on T1-weighted imaging (white arrow). B, T2-weighted imaging showed cord compression by the low-intensity area (black arrow) posterior to the odontoid process of the axis with high-intensity of the cervical spine at the C1–C2 level (white circle).

He was admitted to our hospital because of unbearable neuropathic pain, which continued from the time of injury. On day 3 of admission, a plain cervical spine radiograph was carried out by an orthopedic surgeon to check for surgical indication. The flexion extension X-rays of the cervical spine showed no atlantoaxial subluxation (Fig. 3). Due to the patient's age and the absence of motor impairment, surgical decompression of the cervical stenosis was not warranted. Because of cervical stability and severe nuchal

dysesthesia, his neck collar removed. The following are additional laboratory findings after admission: antinuclear antibody, negative; rheumatoid factor level, 1.7 IU/mL (normal range, <15 IU/mL); anti-cyclic citrullinated peptide antibody level, <0.5 U/mL (normal range, <4.5 U/mL); and serum amyloid A protein level, 5.4 μ g/mL (normal range, <8.0 μ g/mL). Carcinoembryonic antigen and carbohydrate antigen 19-9 levels were 6.5 ng/mL (normal range, <5.0 ng/mL) and 66.0 U/mL (normal range, <37 U/mL),

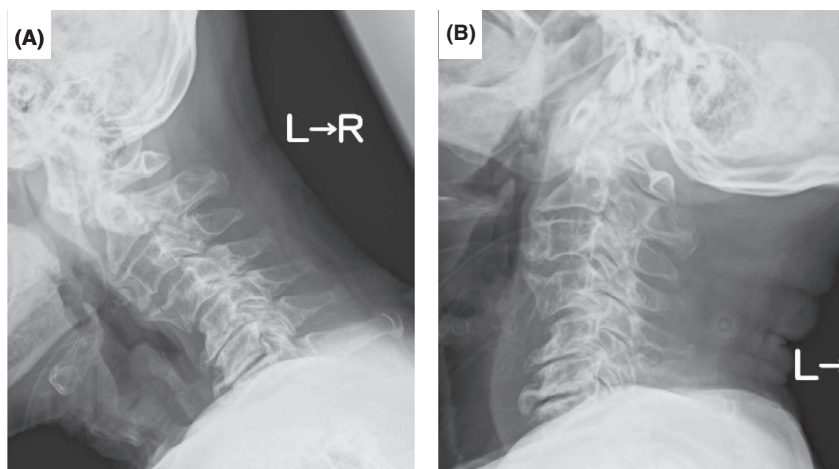


Fig. 3. Flexion extension X-rays of the cervical spine on day 3 of hospitalization of an 86-year-old man with retro-odontoid pseudotumor. A, Flexion test revealed no cervical instability. B, Extension test revealed no cervical instability.

respectively, which was slightly higher than the normal upper limit. The patient underwent upper and lower gastrointestinal endoscopy due to his history of gastric cancer, resected 24 years ago, and no evidence of malignancy was observed. Moreover, whole body contrast-enhanced computed tomography revealed no neoplastic tumors that could have metastasized to around C1–C2. Furthermore, we determined the anamnesis of long-term neck flexion due to his unique occupation. Therefore, we diagnosed a cervical spine injury with an isolated symptom of C2–C3 dysesthesia due to a retro-odontoid pseudotumor, and we believed that the retro-odontoid pseudotumor progressively developed over time with no related symptoms. We prescribed pregabalin at 150 mg/day on day 1 of admission and increased the dosage to 300 mg/day on day 8. On day 11, he was transferred to a rehabilitation hospital for pain control after slight recovery of the dysesthesia.

DISCUSSION

RETRO -odontoid pseudotumor can occur secondary to a variety of conditions, such as rheumatoid arthritis, crystal deposition diseases, amyloidosis, long-term hemodialysis, cervical degenerative changes, mechanical alterations, and trauma.^{1,3–5} Retro-odontoid pseudotumor has been generally attributed to atlantoaxial instability (AAI). It is believed that this instability can cause repeated tears and subsequent hypertrophy of ligaments, leading to retro-odontoid pseudotumor.^{1,6} Robles et al.¹ reported that the hypomobility of adjacent levels without AAI can alter the normal biomechanics of C1–C2, exposing it to excessive motion and stress. Atlantoaxial instability was not observed

in our present case, although the patient had an abnormal C2–C7 osteophyte formation. Moreover, his unique occupation could have led to chronic repetitive load to his neck; however, multiple diagnostic tests revealed no such findings suggesting other causes for the retro-odontoid pseudotumor. Despite not undergoing biopsy or surgery for the lesion, we presumed that the main cause of the formation of the retro-odontoid pseudotumor in our case was the adjacent spondylosis. In a case of acute cervical cord injury without fracture or dislocation of the spinal column, Koyanagi et al.⁷ reported that degenerative changes in the cervical spine and developmental narrowing of the spinal canal are important preexisting factors. In our case without any cervical fractures, we must consider the narrowing of the upper spinal canal so that we do not underdiagnose the retro-odontoid pseudotumor.

Robles et al.¹ reported that progressive myelopathy was observed in 95% of the cases with retro-odontoid pseudotumor without radiologic AAI. A previous study reported an elderly woman presenting with dysesthesia at the posterior neck and progressive gait disturbance for 3 weeks.⁸ Therefore, our case was rare, in that the patient had no symptoms preceding the accidental fall. On admission, he only had posterior head and neck dysesthesia; therefore, we suspected a variety of differential diagnoses, including a bruise, occipital neuralgia, or bilateral herpes zoster. There was no bruise or rash. There was abnormal pain at the C2–C3 level, which was consistent with sensory dermatome. Radiological abnormalities around the odontoid process were found. Furthermore, no bilateral radicular compression, cervical cord compression, or spinal high intensity at the C1–C2 level on T2-WI of MRI were observed. On the basis of the above

findings, the patient's symptoms most likely originated from the cervical spine. Finally, we made a general judgement that the pathology of this case might be due to injury to the central side of the lateral spinothalamic tract lesion localized to the C2–C3 level.

Robles et al.¹ suggested transoral or posterior pseudotumor resection in cases of retro-odontoid large masses causing severe cervicomedullary junction compression without radiological AAI. Our patient did not consent to such surgical interventions, and accordingly, he only underwent symptomatic treatment.

In summary, because retro-odontoid pseudotumor could occur in elderly patients with underlying chronic cervical disease, emergency physicians must keep in mind the etiology in cases of upper cervical injury, such as a traumatic injury from a fall.

CONCLUSION

WE REPORT THE first case of retro-odontoid pseudotumor with an isolated symptom of C2–C3 dysesthesia triggered by a traumatic event. In the emergency setting, early suspicions of this unique etiology are significant in cases of upper cervical injury, even with atypical symptoms.

DISCLOSURE

Approval of the research protocol: N/A.

Informed consent: Informed consent was obtained from the patient and his family.

Registry and the registration no. of the study/trial: N/A.

Animal studies: N/A.

Conflict of interest: None.

REFERENCES

- 1 Robles LA, Mundis GM. Retro-odontoid pseudotumor without radiologic atlantoaxial instability: a systematic review. *World Neurosurg.* 2019; 121: 100–10.
- 2 Kakutani K, Doita M, Yoshikawa M *et al.* C1 laminectomy for retro-odontoid pseudotumor without atlantoaxial subluxation: review of seven consecutive cases. *Eur. Spine* 2013; 22: 1119–26.
- 3 Rousselin B, Helenon O, Zingraff J *et al.* Pseudotumor of the craniocervical junction during long-term hemodialysis. *Arthritis Rheum.* 1990; 33: 1567–73.
- 4 Shi J, Ermann J, Weissman BN *et al.* Thinking beyond pannus: a review of retro-odontoid pseudotumor due to rheumatoid and non-rheumatoid etiologies. *Skeletal Radiol.* 2019; 48: 1511–23.
- 5 Hamard M, Martin SP, Boudabbous S. Retroodontoid pseudotumor related to development of myelopathy secondary to atlantoaxial instability on Os Odontoideum. *Case Rep. Radiol.* 2018; 2018: 1658129.
- 6 Crockard HA, Sett P, Geddes JF *et al.* Damaged ligaments at the craniocervical junction presenting as an extradural tumour: a differential diagnosis in the elderly. *J. Neurol. Neurosurg. Psychiatry* 1991; 54: 817–21.
- 7 Koyanagi I, Iwasaki Y, Hida K *et al.* Acute cervical cord injury without fracture or dislocation of the spinal column. *J. Neurosurg.* 2000; 93: 15–20.
- 8 Yu SH, Choi HJ, Cho WH *et al.* Retro-odontoid pseudotumor without atlantoaxial subluxation or rheumatic arthritis. *Korean J. Neurotrauma* 2016; 12: 180–4.