

## Original Article

## Open craniotomy for brain abscess: A forgotten experience?

Nisha Gadgil, Akash J. Patel, Shankar P. Gopinath

Department of Neurosurgery, Baylor College of Medicine, 1709 Dryden Suite 750, Houston, TX 77030, USA

E-mail: Nisha Gadgil - [gadgil@bcm.edu](mailto:gadgil@bcm.edu); Akash J. Patel - [ap144168@bcm.edu](mailto:ap144168@bcm.edu); \*Shankar P. Gopinath - [shankarg@bcm.edu](mailto:shankarg@bcm.edu)

\*Corresponding author

Received: 02 December 12 Accepted: 22 February 13 Published: 25 March 13

**This article may be cited as:**Gadgil N, Patel AJ, Gopinath SP. Open craniotomy for brain abscess: A forgotten experience?. *Surg Neurol Int* 2013;4:34.Available FREE in open access from: <http://www.surgicalneurologyint.com/text.asp?2013/4/1/34/109522>

Copyright: © 2013 Gadgil N. This is an open-access article distributed under the terms of the Creative Commons Attribution License, which permits unrestricted use, distribution, and reproduction in any medium, provided the original author and source are credited.

### Abstract

**Background:** Brain abscess carries a high morbidity and mortality despite medical advances. In this paper, we present a single institution's experience with the surgical treatment of brain abscess.

**Methods:** We retrospectively analyzed 33 cases of intracranial abscess who underwent surgical treatment between January 2001 and December 2009. Patients were treated with aspiration through a single burr hole, open aspiration with ultrasound guidance, or complete abscess resection. The medical records were analyzed for demographics, clinical presentation, predisposing factors, imaging, microbiological investigations, treatment, and outcomes.

**Results:** There were 26 male and 7 female patients, aged between 12 and 78 years. The most common predisposing factor was head trauma. Surgical excision of the abscess was performed in 22 patients, open aspiration in 9 patients, and burr-hole aspiration in 2 patients. Repeat surgical procedure was required in six patients. Mortality in this series was 21%. A favorable outcome (Glasgow outcome scale 4 and 5) was achieved in 54%. There was no significant correlation between outcome and age, predisposing factor, treatment modality, or culture results.

**Conclusions:** In this series, most patients were treated with an open technique, either by surgical excision or open aspiration of brain abscess. An open technique may reduce the need for additional imaging, surgical treatment, and length of antibiotic therapy. In resource-limited settings, excision of brain abscess may play a more important role in patient management while maintaining favorable outcomes.

**Key Words:** Brain abscess, craniotomy, intracranial infection

**Access this article online****Website:**[www.surgicalneurologyint.com](http://www.surgicalneurologyint.com)**DOI:**

10.4103/2152-7806.109522

**Quick Response Code:**

### INTRODUCTION

Brain abscesses are suppurative infections of the brain parenchyma surrounded by a vascularized capsule. These infections may result from contiguous spread of infection, hematogenous dissemination of bacteria, previous head trauma or neurosurgical procedure, or immunosuppression.<sup>[6]</sup> Although brain abscess continues

to have a high morbidity and mortality, modern microbiological diagnostic techniques, broad-spectrum antibiotics, and computed tomography (CT) and magnetic resonance imaging (MRI) have contributed to an improvement in the outcome of this entity.

Depending on the size, location, and characteristics of the abscess, several different treatment options may be considered. Surgical excision, once the mainstay of

therapy for brain abscess, has been overshadowed by the advent of stereotactic aspiration, which has become the treatment of choice in many institutions. As a result, few modern series of brain abscess have focused on the role that surgical excision still plays in the management of brain abscess, especially in resource-limited settings. In this paper, we present a series of 33 cases of brain abscess treated predominantly with an open surgical technique and review the literature on this topic.

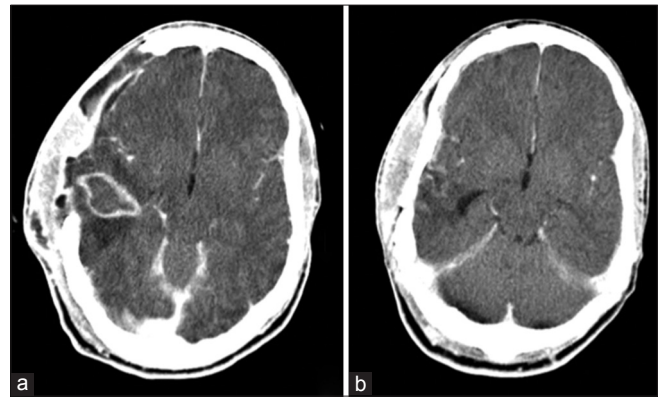
## MATERIALS AND METHODS

This report retrospectively reviews the medical records of 33 consecutive patients with brain abscess who underwent surgery at Ben Taub General Hospital (BTGH) from 2001 to 2009. This study was approved by Baylor College of Medicine's Institutional Review Board. The medical records were obtained of all patients who were discharged with the diagnosis, by clinical coding, of intracranial abscess between January 2001 and December 2009. Patients who demonstrated characteristic imaging findings of brain abscess (localized parenchymal ring-enhancing lesion with perilesional brain edema) and in whom surgical findings corroborated the diagnosis of brain abscess (identification of pus in brain parenchyma) were included in the study. Patients with other forms of intracranial empyemas such as epidural abscess or subdural empyema were excluded unless intracerebral abscess was also present. Patient demographics, clinical presentation, predisposing factors, imaging, microbiological investigations, treatment, and outcomes were recorded for all cases. Size of the abscess was recorded as the largest dimension of the abscess, and in the case of multiple abscesses, the largest dimension of each abscess added together. Neurological examination was graded according to Glasgow Coma scale (GCS) and Glasgow Outcome scale (GOS) was used to determine outcome. Surgical procedures were recorded and classified as burr-hole aspiration, open aspiration, and excision. In burr-hole aspiration, a single burr hole was made and abscess contents aspirated through this hole. Open aspiration was defined as craniotomy followed by aspiration of abscess after localization, but without excision of the abscess wall. Excision involved craniotomy and excision of the entire abscess including the abscess wall [Figure 1]. Patients were followed up until discharged from BTGH and from outpatient visits and subsequent inpatient hospitalizations.

Statistical data were evaluated by Graph Pad. Comparison of groups used one-way analysis of variance. Chi-squared test was used for qualitative comparisons. A *P* value less than 0.05 was considered significant.

## RESULTS

Clinical characteristics of the patients in this series are displayed in Table 1. Of the 33 patients, there were 26 males (79%) and 7 females (21%), aged between 12



**Figure 1:** Images obtained of an 18-year-old male with a gunshot wound to the head who subsequently developed an intracranial abscess and underwent complete surgical excision of the abscess, (a) Preoperative axial CT scan with contrast showing a brain abscess in the right temporal area, (b) Postoperative axial CT scan with contrast obtained 13 days later showing resolution of the abscess

and 78 years (mean 39 years) at the time of diagnosis. Presenting complaints at the time of presentation included headache in 14 patients (42%), nausea or vomiting in 6 (18%), altered mental status in 11 (33%), visual complaints in 5 (15%), and seizures in 3 (9%). Four patients presented with purulent scalp drainage from previous craniotomy site, one patient with purulent ear drainage, and two patients with purulent nose drainage. Focal neurological deficits were present in 16 patients (48%). Median duration of symptoms before seeking medical care was 7 days (range, 1 day to 4 months). On admission, consciousness was clear in 17 (GCS 15), minimally disturbed in 3 (GCS 14), moderately disturbed in 6 (GCS 9-13), and severely disturbed in 1 (GCS 3-8). Three patients were intubated, two with a GCS of 11T and one with a GCS of 6T. GCS on presentation was not recorded in three patients.

Twenty-seven patients (82%) presented with a known predisposing factor for brain abscess. A history of head trauma was the most common cause, accounting for abscess formation in nine patients (gunshot wound, *n* = 8, depressed skull fracture, *n* = 1). Otorhinogenic infection was the primary source in eight patients. An indwelling device such as a ventriculoperitoneal shunt or halo pin was implicated in three patients. Other factors included previous hemorrhagic infarction (*n* = 2), immunocompromized state (*n* = 1), endocarditis (*n* = 1), previous craniotomy for tumor (*n* = 1), nasopharyngeal carcinoma (*n* = 1), and odontogenic infection (*n* = 1).

All patients had CT or MRI scans. Twenty-four patients (73%) had solitary abscesses and nine (27%), multiple. Most abscesses were located in the frontal lobe (*n* = 10, 30%), then temporal (*n* = 6, 18%), parietal (*n* = 5, 15%), cerebellar (*n* = 4, 12%), temporoparietal (*n* = 3, 9%), occipital (*n* = 3, 9%), and

**Table 1: Clinical characteristics of 33 patients with brain abscess**

Characteristic	Number (%)
Sex	
Male	26 (79)
Female	7 (21)
Presenting symptoms	
Headache	14 (42)
Nausea/vomiting	6 (18)
AMS	11 (33)
Visual complaints	5 (15)
Seizures	3 (9)
GCS on admission	
15	17 (52)
14	2 (6)
9 to 13	13 (39)
3 to 8	1 (3)
Predisposing factor	
Trauma	9 (27)
Otorhinogenic infection	8 (24)
Indwelling device	3 (9)
Hemorrhagic infarction	2 (6)
Immunocompromised	1 (3)
Endocarditis	1 (3)
Previous craniotomy	1 (3)
Nasopharyngeal carcinoma	1 (3)
Odontogenic infection	1 (3)
None identified	6 (18)
Abscess number	
One	24 (73)
Multiple	9 (27)
Abscess location	
Frontal	10 (30)
Temporal	6 (18)
Parietal	5 (15)
Cerebellar	4 (12)
Temporoparietal	3 (9)
Occipital	3 (9)
Frontoparietal	2 (6)
Diagnosis	
CT alone	21 (63)
MRI	12 (36)
Culture	
No organism identified	12 (41)
Single organism	12 (41)
Multiple organisms	5 (17)

MRI: Magnetic resonance imaging, AMS: Altered mental status, GCS: Glasgow coma scale

frontoparietal ( $n = 2$ , 6%). Odontogenic and rhinogenic abscesses were all located in the frontal lobe, and otogenic abscesses were located in the temporal lobe ( $n = 2$ ) or cerebellum ( $n = 2$ ). Diameters of the abscesses ranged between 1.2 and 12 cm (median, 3.5 cm).

CT scan with contrast was used alone for preoperative diagnosis of brain abscess in 21 (63%) patients; MRI with contrast was used alone or in conjunction with CT to verify diagnosis in 12 (36%) patients. The classic CT findings of a hypodense ring-enhancing parenchymal lesion with perilesional edema were seen in all but three patients. Of these three, one had an otogenic temporal abscess that was isodense and ring-enhancing; one had a fungal abscess of the frontal lobe, which was hyperdense and had diffuse contrast enhancement; another had a temporal lobe abscess as a result of a previous open skull fracture that was hypodense and had diffuse contrast enhancement. In all cases where MRI was performed, imaging revealed a lesion that was T1 hypointense, T2 hyperintense, with rim enhancement and restricted diffusion. Ventriculitis was defined as abscesses close to the ventricle with a diffusely enhanced ventricular wall and clinical deterioration. There were two patients with ventriculitis.

Results of microbiological cultures from the brain abscess were available in 29 patients. In 12 of these patients, cultures remained sterile (41%). Of the positive cultures, a single organism was identified in 12 (71%) and multiple in 5 (29%). Most isolated micro-organisms were *Streptococcus* species, *Staphylococcus* species, and Gram-negative rods. Cultures grew fungal organisms in three cases and actinomyces in one case. The most common organism in patients with previous trauma was *Staphylococcus aureus*. Cultures in cases of otorhinogenic infection thought to be the source of brain abscess grew upper respiratory tract flora and anaerobes.

All patients in this series underwent surgical treatment. Treatment involved surgical excision of the abscess in 22 patients (67%), open aspiration in 9 patients (27%), and burr-hole aspiration in 2 patients (6%). No intraoperative complications occurred in any of the patients. Six patients (18%) underwent repeat surgical procedures for abscess recurrence or infectious sequelae such as subdural empyema. Of these, three had initially undergone excision, two had undergone open aspiration, and one had undergone burr-hole aspiration. Of the nine patients who originally underwent open aspiration, a drain was left in place in two patients, neither of which required repeat surgery.

Postoperative CT imaging was performed in all except two patients to document progression or resolution of the abscess. In all six patients requiring repeat surgery, postoperative CT revealed persistence of a ring-enhancing lesion that was evident on the first postoperative scan. In the remaining 27 patients not requiring repeat surgical therapy, postoperative CT scan revealed persistence of a ring-enhancing lesion in only three (11%) patients ( $P < 0.0001$ ). All other postoperative scans demonstrated resolution of the ring enhancing

lesion or an ill-defined area of contrast enhancement with no definite ring-enhancing lesion.

All patients were initially given intravenous (IV) antibiotic therapy. It was not always possible to determine the actual duration of the course of treatment in patients discharged home or to long-term care facilities. Duration of IV antibiotics ranged from 10 days to 12 weeks (median, 6 weeks), which was followed by varying periods of oral therapy. The most common initial choice of antibiotic was vancomycin plus metronidazole plus cefepime or ceftriaxone. IV antibiotic therapy was then tailored to the culture results. Patients who were surgically treated with abscess excision had an average duration of IV antibiotics of 5.1 weeks (range 1.5-12 weeks), as compared with 6.1 weeks for open drainage (range 5-8 weeks) ( $P = 0.34$ ).

Length of hospital stay ranged from 7 to 149 days (median, 24 days). Excluding those who died during hospitalization, patients treated with abscess excision had a median length of hospital stay of 33 days (range, 7-149 days) and patients treated with open aspiration had a median length of hospital stay of 23 days (range, 10-115 days) ( $P = 0.94$ ).

The overall mortality was 21% ( $n = 7$ ), with six (18%) attributed to abscess and one attributable to the

underlying medical problem. Clinical follow-up for the remaining 26 patients ranged from 0 to 112 months (median, 13 months). At last follow-up, 13 (39%) patients had good recovery (GOS = 5), 5 (15%) patients were moderately disabled (GOS = 4), 8 (24%) were severely disabled (GOS = 3), and none were in vegetative state (GOS = 2). Table 2 shows the relationship between clinical characteristics and outcome.

## DISCUSSION

### Epidemiology and risk factors

Brain abscess is a relatively uncommon entity in the US, with an occurrence of 1500-2500 cases per year.<sup>[6]</sup> Since the widespread availability of CT and improvements in antimicrobial therapy, the diagnosis and treatment of brain abscess has improved significantly;<sup>[15]</sup> mortality has declined from 40% to 60% in the pre-CT era to 0-10% currently.<sup>[13]</sup> However, brain abscess continues to carry a high morbidity and mortality.

While in earlier literature the most common predisposing factor was contiguous spread from otorhinogenic infection, more aggressive management of these primary infections has seen a reduction in resultant brain abscess

**Table 2: Outcomes based on clinical characteristics**

	Recovery (GOS 5)	Moderate (GOS 4)	Severe (GOS 3)	Death (GOS 1)	Total	Pvalue
Age						
Mean	34.3	33.6	42.8	46.3	38.8	0.69
GCS on presentation						
15	13	-	1	3	17 (63%)	
14	-	1	1	1	3 (11%)	
9-13	-	2	3	1	6 (22%)	
3-8	-	-	-	1	1 (4%)	
Duration of sx (days)						
Mean	21	5	6	10	13	0.46
Diameter of abscess (cm)						
Mean	3.3	3.8	5	4	3.9	0.50
#of Abscesses						
Solitary	8	4	7	5	24 (73%)	0.61
Multiple	5	1	1	2	9 (27%)	
Predisposing factor						
No	3	1	-	1	5 (18%)	0.55
Yes	10	4	8	5	27 (82%)	
Treatment						
Excision	8	3	7	4	22 (67)	0.68
Open aspiration	4	2	1	2	9 (27%)	
Burr hole drainage	1	-	-	1	2 (6%)	
Culture negative	8	1	1	2	12 (41%)	0.13
Culture positive	4	3	5	5	17 (59%)	
Need for repeat procedure						
Yes	2	1	2	1	6 (18%)	0.94
No	11	4	6	6	27 (81%)	

CT: Computed tomography, MRI: Magnetic resonance Imaging, GCS: Glasgow coma scale, GOS: Glasgow outcome scale, IV: Intravenous, BTGH: Ben taub general hospital

from these sources.<sup>[3]</sup> In our series, otorhinogenic sources accounted for 24% of brain abscesses. As expected, abscess secondary to otic infections were temporal or cerebellar, and abscesses related to direct spread from the paranasal sinuses were frontal. Causative organism reflected normal flora of the origin of infection, upper respiratory tract flora and anaerobes.

Trauma represents a significant source of brain abscess in our series: 37% of patients had head trauma, previous neurosurgery, or both. This is more than in other series of brain abscess,<sup>[10,15]</sup> likely a result of the high volume of trauma seen at our hospital. Gunshot wounds to the head alone accounted for 24% of brain abscesses in our series. While many of these patients had a poor outcome (63% with GOS <4), the outcome is confounded by their poor neurologic status due to trauma.

### Imaging

The widespread use of CT, and more recently MRI, has significantly improved the diagnosis, surgical planning, and follow-up of brain abscess.<sup>[3]</sup> In this series, CT with contrast was used most commonly as the imaging modality in diagnosing brain abscess, in part due to limitations in the availability of MRI in our hospital. The classic CT findings of a hypodense parenchymal lesion with a complete rim of contrast enhancement and perilesional edema were seen in all but three patients. In those three patients, abscess was nevertheless strongly suspected based on CT findings. We believe that brain abscess can be diagnosed based on clinical presentation and CT findings alone in most cases, and MRI is a helpful adjunct in equivocal cases. MRI may also be helpful in the detection of earlier stages of abscess formation such as cerebritis, in which the incompletely formed capsule may be difficult to visualize on CT.<sup>[6,8]</sup> The hallmark characteristic of a brain abscess on MRI is a lesion with low signal on T1-weighted and high signal on T2-weighted images, with a ring of enhancement surrounding the abscess and restricted diffusion on diffusion-weighted images. Restricted diffusion aids in differentiating brain abscess from necrotic neoplasms, which usually do not show restricted diffusion.<sup>[6]</sup>

Serial postoperative CT scanning was used to monitor for resolution or recurrence of abscess. Although some authors advocate follow-up imaging at regular postoperative intervals,<sup>[13,14]</sup> postoperative imaging in our series was performed based on the clinical status of the patients. As a result, in two cases, postoperative imaging was deemed unnecessary, neither of which had recurrent abscess. Presence of a persistent or enlarged ring-enhancing lesion on postoperative scan was usually an indication for reoperation. In all patients requiring reoperation, the persistent abscess was evident on the very first postoperative scan. In three patients, persistent

ring-enhancing lesion was seen on postoperative scanning but was reduced in size and did not require reoperation based on clinical status. Based on our experience, postoperative CT scanning without contrast was not helpful in abscess management unless some other underlying pathology was suspected.

### Treatment

Medical management alone is considered appropriate in certain cases of brain abscess, such as for small lesions (<2.5-3 cm in diameter) in which the causative organism is known and there is no compromise in neurologic status or signs of increased intracranial pressure.<sup>[3,4,15]</sup> In our series, no patients met these criteria, and therefore surgical therapy in addition to antibiotics was instituted in all cases. The initial choice of antibiotics in most cases was vancomycin plus metronidazole plus cefepime or ceftriaxone, which was then changed based on the results of cultures.

There is data supporting the use of steroids in meningitis, although controversial.<sup>[2,18,19]</sup> The use of steroids in brain abscess is more controversial. Some feel that steroid therapy can reduce antibiotic penetration into the abscess or increase the risk of ventricular rupture. However, in patients with severe cerebral edema, a short-course of steroids may be of benefit. In our practice, we do not routinely place patients with brain abscess on corticosteroid therapy. Many of our patients had severe traumatic brain injury, and in these cases we feel that the unclear benefit of corticosteroid therapy is contraindicated. Our utilization of corticosteroid therapy is done on a case-by-case basis. Thus, our study cannot adequately conclude whether this therapy would be of benefit.

The goals of surgical management of brain abscess are to decompress the space-occupying lesion, lessen intracranial pressure, and eradicate the infection as well as any primary infectious source, if present. Surgical treatment options include (1) aspiration, which may be performed freehand, stereotactically, or as an open procedure using ultrasound guidance and (2) complete excision of the abscess contents and capsule.

Aspiration results in rapid relief in intracranial pressure while confirming the diagnosis of abscess and obtaining a sample for identification of the causative organism.<sup>[1,9]</sup> It is relatively safe, and may therefore be performed even in patients who are poor surgical candidates. Aspiration of pus may be performed freehand or using ultrasound or stereotactic guidance. Stereotactic aspiration of brain abscess has become widespread since the introduction of CT-guided stereotaxy in the 1980s, and offers the advantage of precise localization of the abscess cavity. Barlas, *et al.* reported a reduction in mortality from 18 to 0% in patients with brain abscess from the pre-CT era to the post-CT era, which they attributed



to the advent of CT-guided stereotaxis.<sup>[1]</sup> Stereotactic aspiration has been shown particularly helpful in the aspiration of deep-seated abscesses and those in eloquent locations.<sup>[11]</sup> Stereotactic aspiration is now considered by many authors the treatment of choice for brain abscesses.<sup>[1,3,6,8,13,15,22]</sup>

Aspiration may incur complications such as subarachnoid or subdural leakage of pus, resulting in empyema or meningitis, or intraventricular rupture of the abscess.<sup>[9]</sup> The biggest drawback of stereotactic aspiration is that the abscess capsule is left intact and removal of purulent material is frequently incomplete. As a result, most patients require multiple aspiration procedures to achieve resolution of the abscess. In a series by Cavesoglu, *et al.*, 30 of 32 patients treated with aspiration required repeated aspiration, usually two to three times but occasionally more.<sup>[4]</sup> Mamelak, *et al.* reported that 62% of patients in their series required additional surgery for drainage after initial aspiration.<sup>[13]</sup> In our series, of the two patients initially treated with closed aspiration, one required two additional drainage procedures and one died of a massive cerebrovascular accident. However, others report a much lower incidence of abscess recurrence,<sup>[5,11]</sup> suggesting that patient selection and surgical technique may significantly affect the need for reaspiration.

Aspiration may incur complications such as subarachnoid or subdural leakage of pus, resulting in empyema or meningitis, or intraventricular rupture of the abscess.<sup>[9]</sup>

In the authors' anecdotal experience, in the years prior to the study period of this series, closed aspiration of abscess frequently incurred complications and required repeat procedures, resulting in high morbidity and poor outcomes. This led to a change in practice and preference for an open technique. In the present series, it was our intention to perform complete abscess excision in all but two patients who were poor surgical candidates and therefore were treated with Burr-hole aspiration.

In the remaining 31 patients, craniotomy was performed followed by either complete excision of the abscess or open aspiration under ultrasound guidance with thorough irrigation and verification of evacuation of abscess contents. The selection of surgical therapy was decided on the basis of appearance of the abscess on intraoperative ultrasound, which was used to localize the abscess and determine whether the lesion was amenable to complete excision. In cases where the wall of the abscess appeared too thin on ultrasound to perform excision, open aspiration was performed instead of complete excision, a technique which has been described previously.<sup>[16]</sup> Abscesses located in deep or eloquent regions also were treated with open aspiration.

In a few cases, attending surgeon preference resulted in the choice of open aspiration rather than excision of abscess. However, excision of abscess was performed in the majority of cases (22 of the 33 total).

In our series, we had a much lower rate of reoperation with excision as compared with open aspiration and burr-hole aspiration. From our experience, the more extensive the resection and drainage of the abscess, the lower the rate of recurrence. Of the patients in our series who underwent open excision and had recurrence, recurrence was delayed, as opposed to early evidence of incomplete drainage and failure of treatment. Delayed recurrence of abscess in our patient population, due to socioeconomic factors, can be due to patient noncompliance once leaving the hospital.

Many modern series advocate stereotactic aspiration above open craniotomy except in certain circumstances such as multiloculated abscesses, posterior fossa abscess, abscess associated with a foreign body or open head injury, those that have failed aspiration procedures, and fungal abscesses.<sup>[1,4,6,8,13,15,21,27]</sup> However, in suitable surgical candidates, we prefer an open procedure over stereotactic aspiration for the following reasons.

Open craniotomy for excision of brain abscess allows complete removal of purulent material and the surrounding abscess capsule, providing definitive treatment that may reduce the need for additional treatment and length of antibiotic therapy.<sup>[14,20,26,27]</sup> In cases where complete excision is not feasible, open aspiration via craniotomy allows for thorough irrigation of the abscess cavity and verification of complete evacuation of abscess contents using ultrasound. In those patients undergoing open aspiration, a drain was left in place in two of the nine patients, neither of which required reoperation; two of the seven patients in which a drain was not placed required reoperation. It is possible that the more liberal use of drains may lead to a lower rate of recurrence. In this series, patients undergoing an open procedure had a reoperation rate of only 16%, which is lower than the rates of reoperation after closed aspiration in most other modern series.<sup>[4,13]</sup> Craniotomy for either abscess excision or open aspiration and irrigation requires only a small craniotomy, approximately 3 × 3 cm in most cases. In our series, no surgery took longer than 90 minutes from start to finish, and many were much shorter. Based on our more recent experience using neuronavigation, closed aspiration is not a shorter procedure. Following open craniotomy, length of IV antibiotic therapy may also be reduced as compared with closed aspiration;<sup>[14,20]</sup> in our series, mean IV antimicrobial duration was also only 5.4 weeks. In addition, the need for serial follow-up imaging is reduced in abscess excision,<sup>[20]</sup> as closed aspiration usually leaves a persistent ring-enhancing lesion that must be followed closely until resolution.

It is disputed whether the advantages of complete surgical excision of abscess come at the expense of worsened outcome. Most series of brain abscess including both patients treated with closed aspiration and those treated with excision report no significant difference in effectiveness of the two procedures.<sup>[8,12,13,23-25]</sup> Some series have shown a lower mortality<sup>[25]</sup> and abscess recurrence<sup>[14]</sup> of complete excision. A recent meta-analysis comparing abscess excision with aspiration showed a lower rate of mortality using aspiration (6.6% versus 12.7%),<sup>[20]</sup> however, it is important to note that most published studies are retrospective case series that possess significant selection bias.

Our overall mortality in this series was 21%, which compares to large CT era studies reporting a mortality rate of 7.1-25%.<sup>[3,4,8,12,17,24]</sup> However, one patient in our series died from an unrelated cause. Eighteen percent of the patients died as a result of brain abscess. This is in the middle of the range in the published literature. There are several factors that may explain the higher rate of mortality as compared with some modern series. Our series includes a relatively higher percentage of patients with severe traumatic head injury, changing their prognosis due to their underlying neurosurgical condition. Very few patients had primary brain abscess without other serious complicating medical conditions. A number of our patients experienced a significant delay in seeking medical care once symptoms began, up to 4 months. This may be a reflection of the low socioeconomic status and poor access to healthcare resources in our patient population.

Before the CT-guided stereotactic aspiration, open craniotomy was widely used in the treatment of brain abscess. In recent decades, this technique has rarely been revisited in lieu of the advent of more modern techniques. Most recent series predominantly favor CT-guided aspiration, reserving surgical excision for refractory cases or those with unfavorable complicating factors. However, several authors have stressed the importance of the preference of the neurosurgeon and consideration of setting rather than choice of procedure in the treatment of brain abscess.<sup>[7]</sup> As rising healthcare costs have garnered significant attention, length of hospital stay, length of antibiotic therapy, and need for repeat procedures and imaging are of considerable importance in patient management, particularly in resource-limited settings. Reliability of follow up, as required for serial imaging and prolonged antibiotic administration, continues to be problematic in our patient population. As a result, in our patient population and other low-resource settings, complete excision of brain abscess may be an appropriate treatment for abscesses amenable to this modality. This stance is not novel, but rather a reiteration of an older treatment paradigm that we believe still holds an important role in the treatment of this pathology.

## CONCLUSIONS

In this series of 33 patients with intracranial brain abscess, the majority of patients were treated with an open technique, either by complete surgical excision or open aspiration of the abscess. An open technique may reduce the need for additional imaging, surgical treatment, and duration of antibiotic therapy. Therefore, in resource-limited environments, excision of brain abscess may play a more important role in patient management while maintaining favorable outcomes.

## Limitations

Analysis of results in this case series is hampered by selection biases inherent to a retrospective study. In addition, this small series is not sufficiently powered to show statistical significance between treatment groups; rather, it is designed to be a descriptive account of our experience with brain abscess. Further studies to delineate the role of various treatment modalities in brain abscess are necessary; however, a randomized trial is likely not feasible due to the rarity of brain abscess.

## REFERENCES

1. Barlas O, Sencer A, Erkan K, Eraksoy H, Sencer S, Bayindir C. Stereotactic surgery in the management of brain abscess. *Surg Neurol* 1999;52:404-11.
2. Benninger F, Steiner I. Steroids in bacterial meningitis: Yes. *J Neural Transm* 2013;120:339-42.
3. Carpenter J, Stapleton S, Holliman R. Retrospective analysis of 49 cases of brain abscess and review of the literature. *Eur J Clin Microbiol Infect Dis* 2007;26:1-11.
4. Cavusoglu H, Kaya RA, Turkmenoglu ON, Colak I, Aydin Y. Brain abscess: Analysis of results in a series of 51 patients with a combined surgical and medical approach during an 11-year period. *Neurosurg Focus* 2008;24:E9.
5. Dyste GN, Hitchon PW, Menezes AH, VanGilder JC, Greene GM. Stereotaxic surgery in the treatment of multiple brain abscesses. *J Neurosurg* 1988;69:188-94.
6. Erdogan E, Cansever T. Pyogenic brain abscess. *Neurosurg Focus* 2008;24:E2.
7. Hakan T. Management of bacterial brain abscesses. *Neurosurg Focus* 2008;24:E4.
8. Hakan T, Ceran N, Erdem I, Berkman MZ, Goktas P. Bacterial brain abscesses: An evaluation of 96 cases. *J Infect* 2006;52:359-66.
9. Hall WA, Truwit CL. The surgical management of infections involving the cerebrum. *Neurosurgery* 2008;62:519-31.
10. Kao PT, Tseng HK, Su SC, Lee CM. Haemophilus aphrophilus brain abscess: A case report. *J Microbiol Immunol Infect* 2002;35:184-6.
11. Kocherry XG, Hegde T, Sastry KV, Mohanty A. Efficacy of stereotactic aspiration in deep-seated and eloquent-region intracranial pyogenic abscesses. *Neurosurg Focus* 2008;24:E13.
12. Lu CH, Chang WN, Lin YC, Tsai NW, Liliang PC, Su TM, et al. Bacterial brain abscess: Microbiological features, epidemiological trends and therapeutic outcomes. *QJM* 2002;95:501-9.
13. Mamelak AN, Mampalam TJ, Obana WG, Rosenblum ML. Improved management of multiple brain abscesses: A combined surgical and medical approach. *Neurosurgery* 1995;36:76-86.
14. Mampalam TJ, Rosenblum ML. Trends in the management of bacterial brain abscesses: A review of 102 cases over 17 years. *Neurosurgery* 1988;23:451-8.
15. Mathisen GE, Johnson JP. Brain abscess. *Clin Infect Dis* 1997;25:763-81.
16. Maurice-Williams RS. Experience with 'open evacuation of pus' in the treatment of intracerebral abscess. *Br J Neurosurg* 1987;1:343-51.
17. Nathoo N, Nadvi SS, Narotam PK, van Dellen JR. Brain abscess: management and outcome analysis of a computed tomography era experience with 973 patients. *World Neurosurg* 2011;75:716-26.

18. Peterkovic V, Trkulja V, Kutlesa M, Krajcinovic V, Lepur D. Dexamethasone for adult community-acquired bacterial meningitis: 20 years of experience in daily practice. *J Neurol* 2012;259:225-36.
19. Pfausler B, Schmutzhard E. Controversies in neurology, Vienna, 2012: Steroids in bacterial meningitis: No. *J Neural Transm* 2013;120:343-6.
20. Ratnaik TE, Das S, Gregson BA, Mendelow AD. A review of brain abscess surgical treatment-78 years: Aspiration versus excision. *World Neurosurg* 2011;76:431-6.
21. Sharma BS, Gupta SK, Khosla VK. Current concepts in the management of pyogenic brain abscess. *Neurol India* 2000;48:105-11.
22. Stapleton SR, Bell BA, Uttley D. Stereotactic aspiration of brain abscesses: Is this the treatment of choice? *Acta Neurochir (Wien)* 1993;121:15-9.
23. Tekkok IH, Erbenli A. Management of brain abscess in children: Review of 130 cases over a period of 21 years. *Childs Nerv Syst* 1992;8:411-6.
24. Tseng JH, Tseng MY. Brain abscess in 142 patients: Factors influencing outcome and mortality. *Surg Neurol* 2006;65:557-62.
25. Xiao F, Tseng MY, Teng LJ, Tseng HM, Tsai JC. Brain abscess: Clinical experience and analysis of prognostic factors. *Surg Neurol* 2005;63:442-50.
26. Yang SY. Brain abscess: A review of 400 cases. *J Neurosurg* 1981;55:794-9.
27. Yang SY, Zhao CS. Review of 140 patients with brain abscess. *Surg Neurol* 1993;39:290-6.