

## Unicornuate uterus and ectopic (undescended) ovary

W. OMBELET<sup>1</sup>, G. VERSWIJVEL<sup>2</sup>, C. VANHOLSBEKE<sup>1</sup>, J.C. SCHOBSENS<sup>1</sup>

<sup>1</sup>Department of Obstetrics and Gynaecology and <sup>2</sup>Department of Radiology, Ziekenhuizen Oost-Limburg, Schiepse Bos 6, 3600 Genk, Belgium.

Correspondence at: willem.ombelet@telenet.be

According to the literature the prevalence of congenital uterine anomalies varies between 3.4 and 5.0% and Müllerian anomalies are found more often in subfertile patients compared to fertile controls (Raga *et al.*, 1997; Grimbizis *et al.*, 2001). Congenital malformations of the Müllerian system are probably caused by multifactorial polygenic and familial factors. The prevalence of a unicornuate uterus is rather low (0.3% of the whole population, 0.6% of the infertile population, 0.2% of the fertile population) (Raga *et al.*, 1997). However, of all Müllerian defects unicornuate uterus is found in 3 to 13% of women (Acién, 1997; Raga *et al.*, 1997; Grimbizis *et al.*, 2001). Unicornuate uterus is caused by a failure of one Müllerian duct to develop (unicornuate uterus without rudimentary horn) or to migrate to its proper location. During the third month of foetal life the developing ovaries descend from a position near the kidneys to their final position in the pelvis, this descent is guided by the gubernaculum (Van Voorhis *et al.*, 2000). The gubernaculum is attached to the uterus forming the utero-ovarian and round ligament.

Ectopic or undescended ovaries are characterized by the attachment of the upper pole to an area above the level of the common iliac vessels. Although the term ectopic ovary is commonly used, undescended ovary is probably a more accurate reflection of the underlying pathophysiology. Ovarian maldescent rarely occurs in patients with a normal uterus. On the other hand, the incidence is reported to be 20% when the uterus is absent (Rokitansky-Küstner-Hauser syndrome) and more than 40% in cases of unicornuate uterus. (Dabirashrafi *et al.*, 1994; Ombelet *et al.*, 2003b). Despite the well-known association of ectopic ovaries and unicornuate uterus, ectopic ovaries are reported only sporadically, suggesting the possibility that many cases go unrecognized (Verkauf and Bernhisel, 1996; Ombelet *et al.*, 2003b, 2003c).

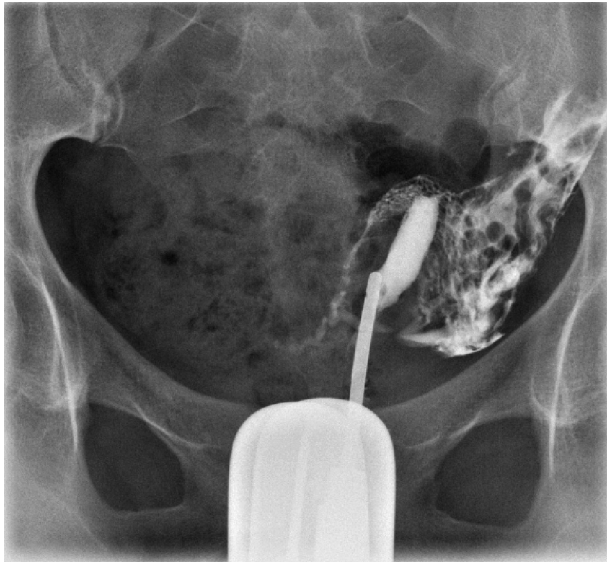We present a case of a unicornuate uterus associated with an ectopic ovary and absent kidney on the contralateral side.

### Case description

A 31-year-old woman was referred to our infertility clinic with a history of primary infertility for more than two years. During the routine infertility exploration a hysterosalpingography (HSG) showed a left sided unicornuate uterus with a patent tube (Fig. 1). On vaginal ultrasound only one ovary could be detected at the normal position, with a normal size and a normal number of antral follicles. On the right hand side no ovary could be visualized.

A 3D ultrasound was performed confirming the presence of a unicornuate uterus and a normal left-sided ovary with normal blood supply (Fig. 1).

Due to our previous experience with ectopic ovaries associated with a unicornuate uterus (Ombelet *et al.*, 2003b; Ombelet *et al.*, 2003c) an MRI after mild ovarian clomiphene citrate (CC)-stimulation was carried out. MRI was performed using an extended phased array body coil on a 1.5 Tesla (Siemens, Germany) scanner. Axial, coronal and sagittal T1 (TurboFlash) and T2 weighted (HASTE) images were acquired, without intravenous contrast. The images through the level of the pelvis demonstrated a left sided unicornuate uterus with a single vagina and a single cervix. The left ovary was located anteriorly in the fossa adjacent to the uterus and contained several tiny cysts. Furthermore, small cysts were found posterior from the hepatic flexure of the colon, interpreted as follicles in the right ovary (Fig. 2a). The right kidney was absent (Fig. 2b). Numerous subcentimetric tiny cysts vertically oriented posterior of the ascending part of the colon, like a string of beads could be demonstrated (Fig. 3a, Fig. 3b), interpreted as small isovolumetric



**Fig. 1.** — A hysterosalpingogram showing a left-sided unicornuate uterus with a patent tube.

follicles in a ‘stretched’ right-sided ovarian structure. According to the MRI images it was not sure whether the right-sided ectopic ovary was located intra- or extraperitoneally.

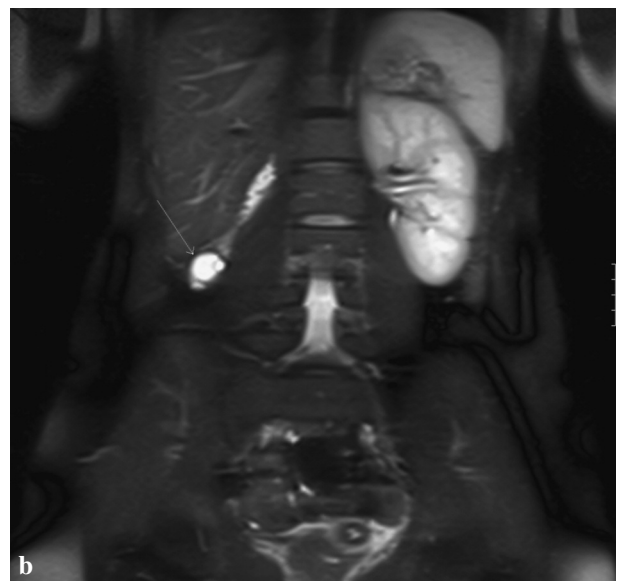
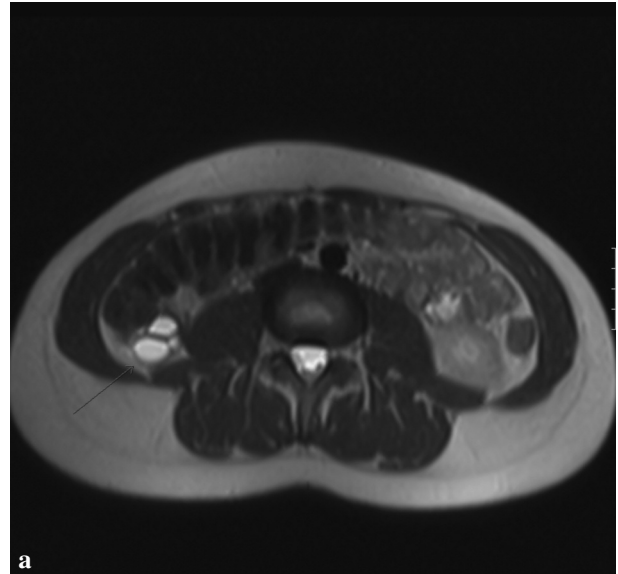
A laparoscopy confirmed the diagnosis of a unicornuate uterus with one normal patent tube and one normal ovary on the left side. On the right side no rudimentary horn could be seen. High up in the abdomen, just below the liver, an ectopic ovary could be visualized with a rudimentary tube. The distal, fimbriated end of the fallopian tube was developed adjacent to the ectopic ovary.

An infertility work-up of the male partner revealed an isolated teratozoospermia with 2% ideal forms using strict criteria of sperm morphology (Ombelet *et al.*, 1997; Cooper *et al.*, 2010). It was decided to start with a first-line treatment with intra-uterine inseminations.

## Discussion

A variety of terms have been used to describe an undescended or ectopic ovary. In 1991 Lachman and Berman proposed a new terminology for classification of ectopic ovaries. They suggested that ectopic or undescended ovaries can be divided in three categories: (1) postsurgical implant, (2) postinflammatory implant and (3) true embryologic.

The embryologic mechanism underlying undescended ovaries is uncertain but could be explained by a lack of caudal descent of the gonads into the true pelvis (Parmley, 1993, Van Voorhis *et al.*, 2000) or by a retarded differential growth of that portion of the urogenital ridge giving rise to both the gonad and the fallopian tube (Rock *et al.*, 1986). Unilateral and

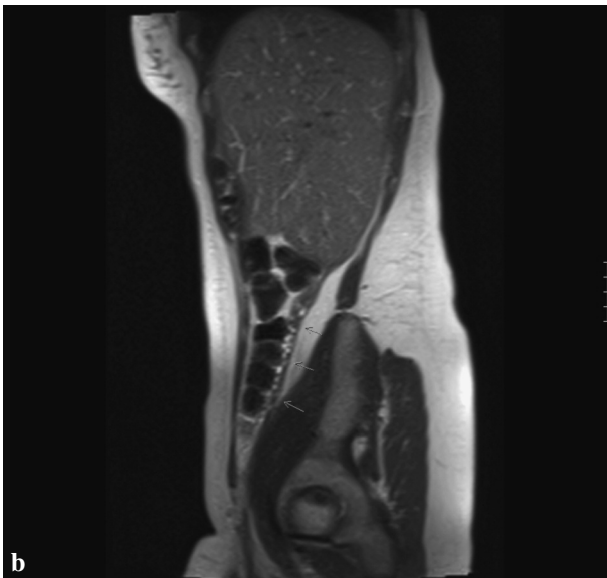
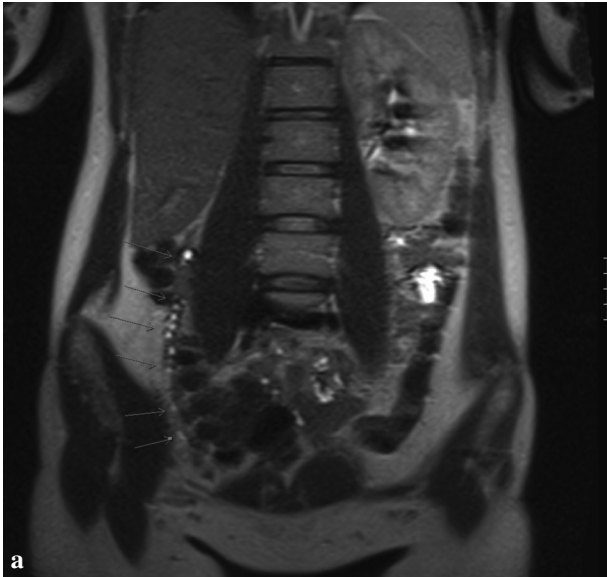


**Fig. 2a and b.** — MRI: Axial (a) and coronal (b) T2 weighted image demonstrating a cluster of cysts posterior (arrow) to the hepatic flexure of the colon and anterior to the quadratus lumborum muscle. An additional finding is the absence of the right kidney.

bilateral ectopic ovaries are described and are most frequently associated with abnormalities of the Müllerian ducts such as unicornuate uterus. The association of unicornuate uterus and urinary tract anomalies including ectopic kidney, renal agenesis, double renal pelvis and horseshoe kidneys is also well known (Fedele *et al.*, 1996; Acien and Acien, 2010).

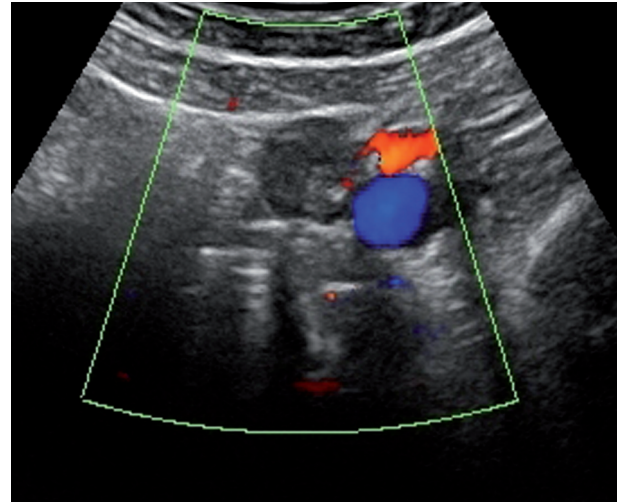
In previous studies we reported the value of MRI as a diagnostic tool when performed after mild ovarian stimulation with clomiphene citrate (Ombelet *et al.*, 2003b, 2003c). The multifollicular growth in the ectopic ovary greatly enhanced MRI diagnosis.

Although the incidence of a unicornuate uterus is low (0.3% of the whole population) (Raga *et al.*,

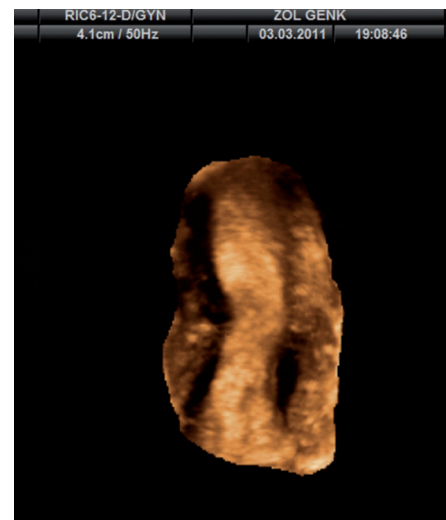


**Fig. 3a and b.** — MRI: Coronal (a) and sagittal (b) T2 weighted images demonstrating a string of numerous small cysts abutting the posterior part of the colon ascendens, from the pelvis to the inferior border of the liver (arrows).

1997), a correct diagnosis is mandatory not only to be aware of the existence of an ectopic ovary but also considering the reproductive performance when uterine malformations are involved. In 2003 we reported the first intrauterine pregnancy following timed coitus, resulting from transperitoneal sperm and/or oocyte migration as the oocyte originated from an ectopic ovary on the contralateral side of the fallopian tube which was attached to a unicornuate uterus (Ombelet *et al.*, 2003a). The presence of a unicornuate uterus is linked to an increase in obstetrical complications such as early miscarriages, ectopic pregnancy, abnormal foetal presentation, intrauterine growth retardation and premature labour (Raga *et al.*, 1997; Heinonen, 1997; Heinonen *et al.*, 1982; Andrews and Jones, 1982; Donderwinkel *et*



**Fig. 4.** — 2D Color Doppler image of the left-sided ovary



**Fig. 5.** — 3D-ultrasound: unicornuate uterus

*al.*, 1992; Moutos *et al.*, 1992). Considering assisted reproduction, significantly lower implantation rates are described after IVF-ET in unicornuate uterus cases (Heinonen *et al.*, 2000).

Continuous refinement of the MRI techniques with further improvement of the spatial resolution and increased availability of MRI will progressively increase its application in the detection of undescended ovaries and other Müllerian fusion defects. Since both intra- and extraperitoneal locations of undescended ovary may occur, the authors suggest that a combination of 3D-ultrasound and MRI can replace laparoscopic evaluation in this specific patient population (Doyle, 1992).

To conclude, MRI after CC ovarian stimulation should be performed when the diagnosis of unicornuate uterus is made in order to detect unexpected intraperitoneal or extraperitoneal ectopic ovaries more frequently.

## Acknowledgement

We gratefully acknowledge Ingrid Jossa for her technical support in preparing this manuscript. We also like to thank the couple for giving the permission to publish this case-report.

## References

- Acién P. Incidence of Müllerian defects in fertile and infertile women. *Hum Reprod.* 1997;12:1372-6.
- Acién P, Acién M. Unilateral renal agenesis and female genital tract pathologies. *Acta Obstet Gynecol Scand.* 2010;89:1424-31.
- Andrews MC and Jones HW Jr. Impaired reproductive performance of the unicornuate uterus: intrauterine growth retardation, infertility, and recurrent abortion in five cases. *Am J Obstet. Gynecol.* 1982;144:173-6.
- Dabirashrafi H, Mohammad, K, Moghadami-Tabrizi N. Ovarian malposition in women with uterine anomalies. *Obstet Gynecol.* 1994;83:293-4.
- Donderwinkel PF, Dorr JP, Willemsen WN. The unicornuate uterus: clinical implications. *Eur J Obstet Gynecol Reprod Biol.* 1992;47:135-9.
- Doyle MB. Magnetic resonance imaging in mullerian fusion defects. *J Reprod Med.* 1992;37:33-8.
- Fedele L, Bianchi S, Agnoli B *et al.* Urinary tract anomalies associated with unicornuate uterus. *J Urol.* 1996;155:847-8.
- Grimbizis GF, Camus M, Tarlatzis BC *et al.* Clinical implications of uterine malformations and hysteroscopic treatment results. *Hum Reprod Update.* 2001;7:161-74.
- Heinonen P. Unicornuate uterus and rudimentary horn. *Fertil Steril.* 1997;68:224-30.
- Heinonen PK, Kuismanen K, Ashorn R. Assisted reproduction in women with uterine anomalies. *Eur J Obstet Gynecol Reprod Biol.* (2000;89:181-4.
- Heinonen PK, Saarikoski S, Pystynen P. Reproductive performance of women with uterine anomalies. An evaluation of 182 cases. *Acta Obstet Gynecol Scand.* 1982;61:157-62.
- Lachman MF, Berman, MM. The ectopic ovary. A Case Report and Review of the Literature. *Arch Pathol Lab Med.* 1991;115:233-5.
- Moutos DM, Damewood MD, Schlaff WD *et al.* A comparison of the reproductive outcome between women with a unicornuate uterus and women with a didelphic uterus. *Fertil Steril.* 1992;58:88-93.
- Ombelet W, Deblaere K, Grieten M *et al.* Intrauterine pregnancy following transperitoneal oocyte and/or sperm migration in a woman with an ectopic (undescended) ovary. *Reprod Biomed Online.* 2003a;7:110-3.
- Ombelet W, Grieten M, DeNeubourg P *et al.* Undescended ovary and unicornuate uterus: simplified diagnosis by the use of clomiphene citrate ovarian stimulation and magnetic resonance imaging (MRI). *Hum Reprod.* 2003;18:858-62.
- Ombelet W, Verswijvel G, de Jonge E. Ectopic ovary and unicornuate uterus. *N Engl J Med.* 2003;348:667-8.
- Parmley T. The embryology of the female genital tract. In Verkauf, BS. (ed) *Congenital malformations of the female reproductive tract and their treatment.* Norwalk (CT): Appleton and Lang, 1993, Norwalk, USA.
- Raga F, Bauset C, Remohi J *et al.* Reproductive impact of congenital Müllerian anomalies. *Hum. Reprod.* 1997;12:2277-81.
- Rock JA, Parmley T, Murphy AA *et al.* Malposition of the ovary associated with uterine anomalies. *Ferti.I Steril.* 1986;45:561-3.
- Van Voorhis BJ, Dokras A, Syrop CH. Bilateral undescended ovaries: association with infertility and treatment with IVF. *Fertil Steril.* 2000;74:1041-3.
- Verkauf BS, Bernhisel MA. Ovarian maldescent. *Fertil Steril.* 1996;65:189-92.
- Wharton LR. Two cases of supernumerary ovary and one case of accessory ovary with an analysis of previously reported cases. *Am J Obstet Gynecol.* 1959;78:1101-1109.
- Cooper TG, Noonan E, von Eckardstein S *et al.* World Health Organization reference values for human semen characteristics. *Hum Reprod Update.* 2010;16:231-45.