

CASE REPORT

Open Access



# Time controlled adaptive ventilation<sup>TM</sup> as conservative treatment of destroyed lung: an alternative to lung transplantation

Malou Janssen<sup>1\*</sup> , J. Han. J. Meeder<sup>1</sup>, Leonard Seghers<sup>2</sup> and Corstiaan A. den Uil<sup>1,3,4</sup>

## Abstract

**Background:** Acute respiratory distress syndrome (ARDS) often requires controlled ventilation, yielding high mechanical power and possibly further injury. Veno-venous extracorporeal membrane oxygenation (VV-ECMO) can be used as a bridge to recovery, however, if this fails the end result is destroyed lung parenchyma. This condition is fatal and the only remaining alternative is lung transplantation. In the case study presented in this paper, lung transplantation was not an option given the critically ill state and the presence of HLA antibodies. Airway pressure release ventilation (APRV) may be valuable in ARDS, but APRV settings recommended in various patient and clinical studies are inconsistent. The Time Controlled Adaptive Ventilation (TCAV<sup>TM</sup>) method is the most studied technique to set and adjust the APRV mode and uses an extended continuous positive airway pressure (CPAP) Phase in combination with a very brief Release Phase. In addition, the TCAV<sup>TM</sup> method settings are personalized and adaptive based on changes in lung pathophysiology. We used the TCAV<sup>TM</sup> method in a case of severe ARDS, which enabled us to open, stabilize and slowly heal the severely damaged lung parenchyma.

**Case presentation:** A 43-year-old woman presented with *Staphylococcus Aureus* necrotizing pneumonia. Progressive respiratory failure necessitated invasive mechanical ventilation and VV-ECMO. Mechanical ventilation (MV) was ultimately discontinued because lung protective settings resulted in trivial tidal volumes. She was referred to our academic transplant center for bilateral lung transplantation after the remaining infection had been cleared. We initiated the TCAV<sup>TM</sup> method in order to stabilize the lung parenchyma and to promote tissue recovery. This strategy was challenged by the presence of a large bronchopleural fistula, however, APRV enabled weaning from VV-ECMO and mechanical ventilation. After two months, following nearly complete surgical closure of the remaining bronchopleural fistulas, the patient was readmitted to ICU where she had early postoperative complications. Since other ventilation modes resulted in significant atelectasis and hypercapnia, APRV was restarted. The patient was then again weaned from MV.

**Conclusions:** The TCAV<sup>TM</sup> method can be useful to wean challenging patients with severe ARDS and might contribute to lung recovery. In this particular case, a lung transplantation was circumvented.

**Keywords:** Acute respiratory distress syndrome, Bronchopleural fistula, Destroyed lung, Lung protective ventilation, Time-controlled adaptive ventilation, Veno-venous extracorporeal membrane oxygenation

## Background

Acute respiratory distress syndrome (ARDS) is most often caused by severe infection. The pathology is mediated via severe edema and alveolar collapse [1] and can be exacerbated by mechanical ventilation [2, 3]. Gas

\*Correspondence: m.janssen.1@erasmusmc.nl

<sup>1</sup> Department of Intensive Care Medicine, Erasmus MC, University Medical Center, Dr Molewaterplein 40, Room Rg 626, 3015 GD Rotterdam, The Netherlands

Full list of author information is available at the end of the article



© The Author(s) 2021. **Open Access** This article is licensed under a Creative Commons Attribution 4.0 International License, which permits use, sharing, adaptation, distribution and reproduction in any medium or format, as long as you give appropriate credit to the original author(s) and the source, provide a link to the Creative Commons licence, and indicate if changes were made. The images or other third party material in this article are included in the article's Creative Commons licence, unless indicated otherwise in a credit line to the material. If material is not included in the article's Creative Commons licence and your intended use is not permitted by statutory regulation or exceeds the permitted use, you will need to obtain permission directly from the copyright holder. To view a copy of this licence, visit <http://creativecommons.org/licenses/by/4.0/>. The Creative Commons Public Domain Dedication waiver (<http://creativecommons.org/publicdomain/zero/1.0/>) applies to the data made available in this article, unless otherwise stated in a credit line to the data.

exchange is often hampered due to damaged lung parenchyma. Besides pharmacological interventions such as surfactant therapy, inhalation of agents contributing to vasodilatation and anti-microbial therapy [4], ventilation strategies are an important factor in the treatment of ARDS. Lung protective ventilation [5] is defined by peak inspiratory pressures less than 30 cm H<sub>2</sub>O and tidal volumes 4–6 ml/kg/BW, and has been shown to be beneficial in patients with severe ARDS [6]. However, ARDS is still associated with a high mortality rate of about 30–45% [7–9], which allows for the trial of other ventilation strategies. It has been proposed that airway pressure release ventilation (APRV) [10] is applicable in patients with severe ARDS, but the APRV settings reported by various studies and clinical cases [11] are inconsistent. Time-controlled adaptive ventilation (TCAV<sup>TM</sup>) [12]—developed by Dr. Habashi (see attached protocol, ©2021, [www.aprvnetwork.org](http://www.aprvnetwork.org). All rights reserved)—is an APRV protocol that uses extended high plateau pressure times (continuous positive airway pressure, CPAP Phase) in combination with brisk periods of partial pressure release (Release Phase). The very brief Release Phase is set and adjusted based on changes in lung pathophysiology, which is measured by a shift in the slope of the expiratory flow curve (SlopeEF). The SlopeEF curve is a breath-by-breath measurement of respiratory system compliance (CRS). Termination of expiratory flow is calculated by multiplying the peak expiratory flow by 75%, which will determine the Release Phase time. The steeper the SlopeEF, indicating a fall in CRS, the shorter the Release Phase (to prevent derecruitment of alveoli with fast collapse time constants) and the smaller the tidal volume (V<sub>t</sub>) (to prevent overdistension of alveolar ducts). As the lung begins to heal and the CRS improves the Release Phase time will increase as will the size of V<sub>t</sub>. However, driving pressure will not increase because V<sub>t</sub> only increases with an increase in CRS. The TCAV<sup>TM</sup> method prevents the lung from depressurizing and thereby creates a time controlled positive end-expiratory pressure (TC-PEEP). Alveoli open and collapse as a viscoelastic system and thus the TCAV<sup>TM</sup> method makes use of the time lag between lung opening after start of inspiration and the time lag between start of expiration and alveolar collapse. The application of continuous positive pressure causes the alveoli to stabilize, and releasing this pressure for a short period of time will not result in alveolar collapse [13]. As a result, this method may prevent ventilator-associated lung injury by averting repetitive alveolar collapse and expansion [14, 15].

The pressure of the CPAP Phase should be set high enough to enable sufficient lung opening and to prevent regional lung strain [16]. Since these pressures are also a function of the time they are applied, longer periods of

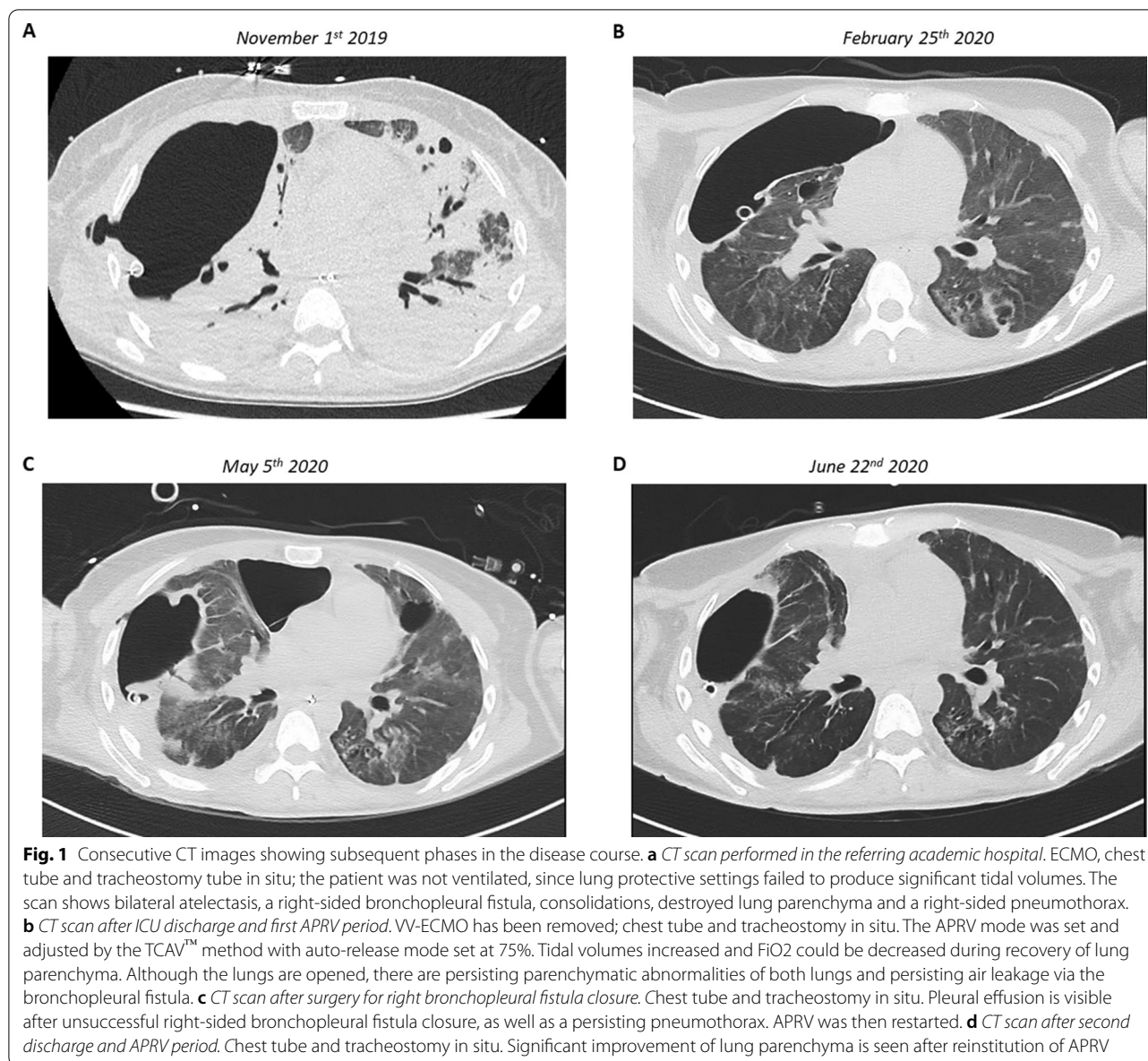
positive pressures in combination with short expiration periods will result in the maximal opening of alveoli [17]. Since the short expiratory time prevents total expiration, the low-pressure setting is always zero. If these settings are used correctly, APRV might be applied to treat severely damaged lung tissue [18]. The TCAV<sup>TM</sup> method is designed to rapidly stabilize viscoelastic lung tissue using a very brief Release Phase. Viscoelastic alveoli simply do not have sufficient time to collapse. The extended CPAP Phase will gradually open viscoelastic lung tissue over hours or days, depending on the severity of lung injury when the TCAV<sup>TM</sup> method is first applied. The end product is a stable and open lung that is highly resistant to VILI-induced injury.

In the case presented here, the lung parenchyma was severely damaged necessitating the use of veno-venous extracorporeal membrane oxygenation (VV-ECMO) to treat the refractory hypoxemia and hypercapnia. VV-ECMO is often used as a bridge until a donor can be found for a lung transplant [19, 20]. However, lung transplantation was not possible for this patient, but the TCAV<sup>TM</sup> method was highly effective at stabilizing and opening this severely injured lung, which eventually allowed for weaning from ECMO and then mechanical ventilation.

### Case presentation

A 43-year-old woman with no remarkable medical history underwent diagnostic arthrography of her right shoulder due to ongoing symptoms following a traumatic injury. Ten days later, the patient was admitted to the same general hospital with *Staphylococcus Aureus* sepsis. Ultrasound examination showed a fluid collection in her right shoulder. Repeated arthrocentesis was performed in order to drain the fluid and antibiotics were started. Three days after admission, she developed respiratory failure for which she was intubated and mechanical ventilation was started. The CT scan showed severe pneumonic infiltrates. Due to further deterioration, the patient was transferred to an academic hospital.

On transfer the patient was ventilated in the prone position [21]. During the first week, a spontaneous right-sided pneumothorax developed for which a chest tube was placed. Surgical debridement of the right shoulder was performed in order to eliminate the persistent infection. After 7 days she developed refractory respiratory failure and VV-ECMO was initiated. Consecutive CT scans showed a large bronchopleural fistula of the right lung, multiple abscesses and lung parenchyma which at that time was regarded as being destroyed (Fig. 1a). The patient continued to deteriorate and due to the ongoing septic profile, she was referred to our center where the proposal was made to perform a bilateral pneumectomy



and then clear the infection, whilst keeping the patient on ECMO until such time as bilateral lung transplantation was possible [22].

At the time of admission to our ICU, 35 days after intubation, the patient was in respiratory distress despite maximum VV-ECMO settings and tracheostomal high-flow oxygen therapy. She was not mechanically ventilated due to the impossibility of achieving adequate tidal volumes with lung protective settings. Successful donor matching for lung transplantation was considered highly unlikely due to the presence of multiple HLA antibodies (Panel-reactive antibody test = 100%). Furthermore, the patient was immobilized and had critical illness

polyneuropathy, providing a further contraindication to transplantation. In order to facilitate lung recovery, we applied the TCAV™ method to set and adjust the APRV mode [14, 16] (Dräger Evita® V800). The TCAV™ method applies an extended high pressure CPAP Phase with intermittent very brief Release Phases for CO<sub>2</sub> removal. We set the auto-release at 75%, resulting in termination of expiration at 75% of the peak expiratory flow rate, which initially yielded high frequencies and small tidal volumes (9). Our goal was to stabilize the lung with the very short Release Phase to minimize repetitive alveolar collapse-induced atelectrauma. The bronchopleural fistula and corresponding significant air leak persisted and

initially worsened, however, because the patient’s collapsed lung parenchyma recruited increasing lung volume, tidal volumes were able to be increased and FiO2 decreased. A tracheostomy was performed eleven days after admission. After a month of APRV and while still on VV-ECMO, her arterial blood gas (ABG) normalized (see Table 1). This strategy enabled the patient to be weaned off VV-ECMO and subsequently mechanical ventilation. After three months the patient was discharged from ICU (Fig. 1b), her tracheostoma had been closed but the chest tube was still in situ.

Two months after ICU discharge, surgery was performed to close several remaining bronchopleural fistulas and the patient was readmitted to ICU. Due to drain dysfunction, the fistulas unfortunately reopened. She was extubated the day after surgery, however, due to weakness, atelectasis and ongoing significant air leakage, the patient had to be reintubated after 3 days. One day later, a repeat tracheostomy was performed. Traditional pressure support and control ventilation modes were insufficient and resulted in significant atelectasis so the TCAV™ method was restarted. P<sub>High</sub> was reduced very slowly. Her clinical situation improved and attending physicians switched to pressure support ventilation, which was regarded as being more comfortable for the patient. However, hypercapnia occurred and after 2 days the

patient was exhausted and the TCAV™ method was again restarted. Due to clinical suspicion of infection, antibiotic therapy was broadened. After this infection had been cleared, weaning from ventilation was initiated which was successful after a further 20 days (Fig. 1d).

After less than 2 months, the patient was discharged home with a portable chest tube. The tube dislocated but this did not result in pneumothorax. In October 2020, the patient tested positive for COVID-19, but she only had minor symptoms and there was no need for admission to hospital.

**Discussion and conclusions**

In this patient, APRV set with use of the TCAV™ protocol contributed to lung recovery. It enabled us to wean her first from VV-ECMO and then from mechanical ventilation (twice), despite the presence of a large bronchopleural fistula. The TCAV™ method prevented alveolar collapse, which due to lack of surfactant in alveoli easily occurs in lungs affected by ARDS. If the implementation of APRV (both on and off VV-ECMO) earlier on in the course of the disease prevents deterioration and destroyed lung is still only a hypothesis. However, in exceptional cases such as ours, it may be a useful strategy in delaying the indication for lung transplantation.

**Table 1** Modes and settings of mechanical ventilation and corresponding arterial blood gases (ABG)

	Mode	FiO2/Vti	Pressures (cm H2O)	ABG; pressures in kPa
Admission to ICU at EMC (November 16th)	APRV + VV-ECMO	80% / 2.33 cc/kg 7L FiO2 1.0 sweep gas flow	P <sub>peak</sub> 41 P <sub>plat</sub> 40 P <sub>mean</sub> 28	pH 7.45 pO2 6.8 pCO2 5.7
November 17th	APRV + VV-ECMO	70% / 2.36 cc/kg 7L FiO2 1.0 sweep gas flow	P <sub>peak</sub> 44 P <sub>plat</sub> 42 P <sub>mean</sub> 28	pH 7.49 pO2 11.3 pCO2 5.0
December 20th	APRV + VV-ECMO	40% / 2.72 cc/kg 7.5L FiO2 1.0 sweep gas flow	P <sub>peak</sub> 36 P <sub>plat</sub> 32 P <sub>mean</sub> 23	pH 7.44 pO2 10.3 pCO2 6.6
January 12th	PS + VV-ECMO	30% / 4.34 cc/kg 4L FiO2 1.0 sweep gas flow	P <sub>peak</sub> 30 P <sub>mean</sub> 13 PEEP 10	pH 7.38 pO2 11.0 pCO2 8.1
February 25th	No mechanical ventilation, no ECMO	0.5 L O2 nasal cannula	n.a	No ABG
Following surgery and repeat tracheostomy (April 24th)	Start APRV, no ECMO	35% / 4.36 cc/kg	P <sub>peak</sub> 34 P <sub>mean</sub> 21 PEEP 11	pH 7.12 pO2 11.2 pCO2 10.5
April 29th	APRV, no ECMO	40%/4.08 cc/kg	P <sub>peak</sub> 31 P <sub>plat</sub> 28 P <sub>mean</sub> 23	pH 7.23 pO2 11.4 pCO2 9.9
May 5th	APRV, no ECMO	30%/3.44 cc/kg	P <sub>peak</sub> 21 P <sub>plat</sub> 20 P <sub>mean</sub> 17	pH 7.41 pO2 11.1 pCO2 6.6
May 31st	APRV, no ECCMO	25%/4.29 cc/kg	P <sub>peak</sub> 24 P <sub>plat</sub> 24 P <sub>mean</sub> 21	pH 7.41 pO2 13.8 pCO2 7.0
June 22nd	No mechanical ventilation, no ECMO	2 L O2 nasal canula	n.a	No ABG



The beneficial effects of the TCAV<sup>TM</sup>-method have been described in animal models. Using the TCAV<sup>TM</sup> protocol to set the APRV in Lewis rats, Silva et al. [23] showed that in pulmonary ARDS—but not in extra-pulmonary ARDS—this ventilation strategy was beneficial and resulted in less ventilation-induced injury. Using the same protocol, Roy et al. [24] reported that in pig models with intestinal ischemia and sepsis, that the animals that were ventilated using the TCAV<sup>TM</sup> method were less likely to develop ARDS than the animals receiving lung protective ventilation. In 2017, Zhou et al. [25] compared the beneficial effects of APRV with auto-release in humans with those of traditional lung protective ventilation. They showed that patients with APRV needed fewer days on mechanical ventilation and were more likely to be extubated. The methodology used in this study closely resembled the TCAV<sup>TM</sup> protocol, but showed some differences with our strategy because we initially used higher pressures and higher respiratory rates. Recently, the beneficial effects of APRV ventilation have been shown in patients with COVID-19, further emphasizing the relevance of this ventilation mode [26].

The correct settings of this ventilation mode are of great importance, as if Release Phase settings are inadequate they can cause repeated alveolar collapse and corresponding atelectrauma [27]. However, by using the auto-release setting that initiates the stop of expiration at the set percentage of the peak expiratory flow level, alveolar collapse can be prevented. Alternatively, the Release Phase time can be obtained by multiplying the Peak Expiratory Flow by 0.75 to obtain the Termination of Expiratory Flow point. Using the Release Phase time adjustment (TFlow) set the expiratory duration to stop at the calculated Termination of Expiratory Flow value, at which point the lung is rapidly reinflated. In fact, we generated a cast which protected the lungs from ventilation-induced injury. Low tidal volumes were sufficient and increased over time with ongoing tissue recovery.

### Conclusions and directions for further research

In our patient, lungs that were considered beyond repair necessitating a lung transplantation, in fact slowly recovered. In our opinion the TCAV<sup>TM</sup> method may therefore be a useful tool to aid the recovery of severely damaged lungs. It could even be argued that the severe lung pathology in this patient could have been prevented by initiating the TCAV<sup>TM</sup> method earlier on in the course of the disease, as suggested by Andrews et al. [28]. Both larger case series and randomized controlled trials are warranted to demonstrate the beneficial effect of the TCAV<sup>TM</sup> method in different patient groups with ARDS more comprehensively.

### Abbreviations

APRV: Airway pressure release ventilation; ARDS: Acute respiratory distress syndrome; COVID-19: Coronavirus induced disease 2019; CPAP: Continuous positive airway pressure; CRS: Compliance of the respiratory system; CT: Computed tomography; FiO<sub>2</sub>: Fraction of inspired oxygen; HLA: Human leukocyte antigen; ICU: Intensive care unit; MV: Mechanical ventilation; SlopeEF: Slope of the expiratory flow curve; TCAV<sup>TM</sup>: Time controlled adaptive ventilation; Vt(i): Tidal volume (inspiration); VV-ECMO: Veno-venous extracorporeal membrane oxygenation.

### Acknowledgements

Not applicable.

### Authors' contributions

MJ, JM and CU wrote the paper. MJ, JM, LS and CU provided patient care. LS provided reports on follow-up. All authors read and approved the final manuscript.

### Funding

No funding was obtained for this report.

### Availability of data and materials

Data is available from the corresponding author upon reasonable request.

### Declarations

#### Ethical approval

Not applicable (standard care, no interventions).

#### Consent for publication

Patient provided signed consent to participate and for publication of radiographic material.

#### Competing interests

The authors declare that they have no competing interests.

#### Author details

<sup>1</sup>Department of Intensive Care Medicine, Erasmus MC, University Medical Center, Dr Molewaterplein 40, Room Rg 626, 3015 GD Rotterdam, The Netherlands. <sup>2</sup>Department of Pulmonary Medicine, Transplant Center, Erasmus MC, University Medical Center, Rotterdam, The Netherlands. <sup>3</sup>Department of Cardiology, Erasmus MC, University Medical Center, Rotterdam, The Netherlands. <sup>4</sup>Department of Intensive Care Medicine, Maasstad Hospital, Rotterdam, The Netherlands.

Received: 1 February 2021 Accepted: 16 May 2021

Published online: 22 May 2021

### References

- Schiller HJ, McCann UG 2nd, Carney DE, Gatto LA, Steinberg JM, Nieman GF. Altered alveolar mechanics in the acutely injured lung. *Crit Care Med*. 2001;29:1049–55.
- Hasan D, Satalin J, van der Zee P, et al. Excessive Extracellular ATP Desensitizes P2Y<sub>2</sub> and P2X<sub>4</sub> ATP Receptors Provoking Surfactant Impairment Ending in Ventilation-Induced Lung Injury. *Int J Mol Sci*. 2018;19:1185.
- Albert RK. The role of ventilation-induced surfactant dysfunction and atelectasis in causing acute respiratory distress syndrome. *Am J Respir Crit Care Med*. 2012;185:702–8.
- Fan E, Brodie D, Slutsky AS. Acute respiratory distress syndrome: advances in diagnosis and treatment. *JAMA*. 2018;319:698–710.
- Camporota L, Hart N. Lung protective ventilation. *BMJ Br Med J*. 2012;344:e2491.
- Needham DM, Colantuoni E, Mendez-Tellez PA, et al. Lung protective mechanical ventilation and two year survival in patients with acute lung injury: prospective cohort study. *BMJ Br Med J*. 2012;344:e2124.
- Acute Respiratory Distress Syndrome N, Brower RG, Matthay MA, et al. Ventilation with lower tidal volumes as compared with traditional tidal

- volumes for acute lung injury and the acute respiratory distress syndrome. *N Engl J Med*. 2000;342:1301–8.
8. Writing Group for the Alveolar Recruitment for Acute Respiratory Distress Syndrome Trial I, Cavalcanti AB, Suzumura É A, et al. Effect of lung recruitment and titrated positive end-expiratory pressure (PEEP) vs low PEEP on mortality in patients with acute respiratory distress syndrome: a randomized clinical trial. *JAMA*. 2017 **318**: 1335–1345.
  9. Máca J, Jor O, Holub M, et al. Past and present ARDS mortality rates: a systematic review. *Respir Care*. 2017;62:113–22.
  10. Stock MC, Downs JB, Frolicher DA. Airway pressure release ventilation. *Crit Care Med*. 1987;15:462–6.
  11. Jain SV, Kollisch-Singule M, Sadowitz B, et al. The 30-year evolution of airway pressure release ventilation (APRV). *Intensive Care Med Exp*. 2016;4:11.
  12. Habashi NM. Other approaches to open-lung ventilation: airway pressure release ventilation. *Crit Care Med*. 2005;33:S228–240.
  13. Nieman GF, Al-Khalisy H, Kollisch-Singule M, et al. A physiologically informed strategy to effectively open, stabilize, and protect the acutely injured lung. *Front Physiol*. 2020;11:227.
  14. Nieman GF, Andrews P, Satalin J, et al. Acute lung injury: how to stabilize a broken lung. *Crit Care*. 2018;22:136.
  15. Kollisch-Singule M, Andrews P, Satalin J, Gatto LA, Nieman GF, Habashi NM. The time-controlled adaptive ventilation protocol: mechanistic approach to reducing ventilator-induced lung injury. *Eur Respir Rev*. 2019;28:180126.
  16. Nieman GF, Gatto LA, Andrews P, et al. Prevention and treatment of acute lung injury with time-controlled adaptive ventilation: physiologically informed modification of airway pressure release ventilation. *Ann Intensive Care*. 2020;10:3–3.
  17. Bates JHT, Smith BJ. Ventilator-induced lung injury and lung mechanics. *Ann Transl Med*. 2018;6:378.
  18. Nieman G, Satalin J, Andrews P, et al. Preemptive mechanical ventilation based on dynamic physiology in the alveolar microenvironment: novel considerations of time-dependent properties of the respiratory system. *J Trauma Acute Care Surg*. 2018;85:1081–91.
  19. Wu MY, Huang CC, Wu TI, Wang CL, Lin PJ. Venovenous extracorporeal membrane oxygenation for acute respiratory distress syndrome in adults: prognostic factors for outcomes. *Medicine (Baltimore)*. 2016;95:e2870.
  20. Noble DW, Peek GJ. Extracorporeal membrane oxygenation for respiratory failure: past, present and future. *Anaesthesia*. 2010;65:971–4.
  21. Guérin C, Reignier J, Richard J-C, et al. Prone positioning in severe acute respiratory distress syndrome. *New Engl J Med*. 2013;368:2159–68.
  22. Cypel M, Waddell T, Singer LG, et al. Bilateral pneumonectomy to treat uncontrolled sepsis in a patient awaiting lung transplantation. *J Thorac Cardiovasc Surg*. 2017;153:e67–9.
  23. Silva PL, Cruz FF, Samary CDS, et al. Biological response to time-controlled adaptive ventilation depends on acute respiratory distress syndrome etiology. *Crit Care Med*. 2018;46:e609–17.
  24. Roy S, Habashi N, Sadowitz B, et al. Early airway pressure release ventilation prevents ARDS—a novel preventive approach to lung injury. *Shock*. 2013;39:28–38.
  25. Zhou Y, Jin X, Lv Y, et al. Early application of airway pressure release ventilation may reduce the duration of mechanical ventilation in acute respiratory distress syndrome. *Intensive Care Med*. 2017;43:1648–59.
  26. Joseph DAK, Baltazar GA, Jacquez RA, et al. A Pilot Study of patients with COVID-19-related respiratory failure utilizing airway pressure release ventilation (APRV). *Innovations in Surgery and Interventional Medicine*; 2020.
  27. Mireles-Cabodevila E, Dugar S, Chatburn RL. APRV for ARDS: the complexities of a mode and how it affects even the best trials. *J Thorac Dis*. 2018;10:S1058–63.
  28. Andrews PL, Shiber JR, Jaruga-Killeen E, et al. Early application of airway pressure release ventilation may reduce mortality in high-risk trauma patients: a systematic review of observational trauma ARDS literature. *J Trauma Acute Care Surg*. 2013;75:635–41.

### Publisher's Note

Springer Nature remains neutral with regard to jurisdictional claims in published maps and institutional affiliations.

Ready to submit your research? Choose BMC and benefit from:

- fast, convenient online submission
- thorough peer review by experienced researchers in your field
- rapid publication on acceptance
- support for research data, including large and complex data types
- gold Open Access which fosters wider collaboration and increased citations
- maximum visibility for your research: over 100M website views per year

At BMC, research is always in progress.

Learn more [biomedcentral.com/submissions](https://biomedcentral.com/submissions)

