





## CASE REPORT

# RAS mutation leading to acquired resistance to dabrafenib and trametinib therapy in a multiple myeloma patient harboring BRAF mutation

Baptiste Le Calvez<sup>1</sup> | Yannick Le Bris<sup>2,6,7</sup>  | Guillaume Herbreteau<sup>3</sup> | Bastien Jamet<sup>4,7</sup>  | Céline Bossard<sup>5</sup> | Benoit Tessoulin<sup>1,6</sup>  | Thomas Gastinne<sup>1</sup> | Béatrice Mahé<sup>1</sup> | Viviane Dubruille<sup>1</sup> | Nicolas Blin<sup>1</sup> | Chloé Antier<sup>1</sup> | Olivier Theisen<sup>2</sup> | Françoise Kraeber-Bodéré<sup>4,6,7</sup> | Steven Le Gouill<sup>1,6,7</sup> | Marie C. Béné<sup>2,6</sup> | Philippe Moreau<sup>1,6,7</sup> | Cyrille Touzeau<sup>1,6,7</sup> 

<sup>1</sup>Department of Hematology, University Hospital, Nantes, France

<sup>2</sup>Hematology Biology, University Hospital, Nantes, France

<sup>3</sup>Biochemistry Laboratory, University Hospital, Nantes, France

<sup>4</sup>Department of Nuclear Medicine, University Hospital, Nantes, France

<sup>5</sup>Service d'Anatomie et Cytologie Pathologiques, INSERM, CRCINA, Université de Nantes, CHU Nantes, Nantes F44000, France

<sup>6</sup>CRCINA, INSERM, CNRS, Université d'Angers, Université de Nantes, Nantes, France

<sup>7</sup>Site de Recherche Intégrée sur le Cancer (SIRIC) « ILIAD », INCA-DGOS-Inserm\_12558, Nantes, France

## Correspondence

Cyrille Touzeau, Service d'hématologie Clinique, Centre Hospitalier Universitaire, Place Alexis Ricordeau, 44093 Nantes, France.  
Email: cyrille.touzeau@chu-nantes.fr

Baptiste Le Calvez and Yannick Le Bris contributed equally to this work.

## Abstract

Multiple myeloma (MM) is still considered incurable and new therapeutic approaches are therefore needed. Deep-sequencing analysis revealed the presence of *BRAF* mutations in up to 15% of patients. The clinical experience of *BRAF*-targeted therapy in myeloma patients harboring *BRAF* mutation is still limited. We here report the case of a patient with penta-refractory (bortezomib, lenalidomide, carfilzomib, pomalidomide, and daratumumab) MM with extramedullary *BRAF*-mutated disease that achieved clinical response to dual *BRAF* and *MEK* inhibition. At the time of disease progression, gene sequencing analysis of the tumor at the time of progression demonstrated a clonal evolution with emergence of a *NRAS* mutation and persistence of *BRAF* and *TP53* mutations. Backtracking of the *NRAS* mutation was performed by digital polymerase chain reaction on the baseline biopsy and identified the pre-existence of the *NRAS* at a subclonal level. This observation is the first report of acquired *NRAS* mutation leading to resistance to dual *BRAF/MEK* inhibitors in MM. These data suggest that a systematic search for RAS mutations using highly sensitive techniques should be performed before considering targeted therapy in relapsed myeloma with *BRAF* mutation.

## KEYWORDS

*BRAF*, dabrafenib, multiple myeloma, RAS, trametinib

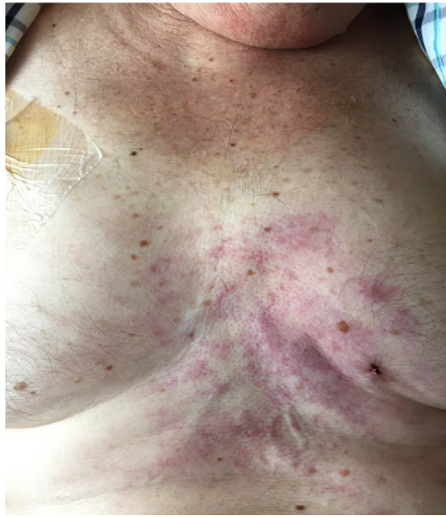Multiple myeloma (MM) is still considered incurable and the outcome of patients with triple-class refractory (proteasome inhibitors, immunomodulatory drugs, and anti CD38 monoclonal antibodies) disease remains very poor [1]. New therapeutic approaches with distinct mechanism of action are therefore needed. Deep-sequencing analysis

revealed the presence of *BRAF* mutations in 11-15% of patients [2-5]. The clinical experience of *BRAF*-targeted therapy in myeloma patients harboring *B-RAF* mutation is still limited [6-10]. Here, we report the case of a patient with triple-class refractory myeloma harboring *BRAF* mutation that achieved clinical response to dual *BRAF* and *MEK*

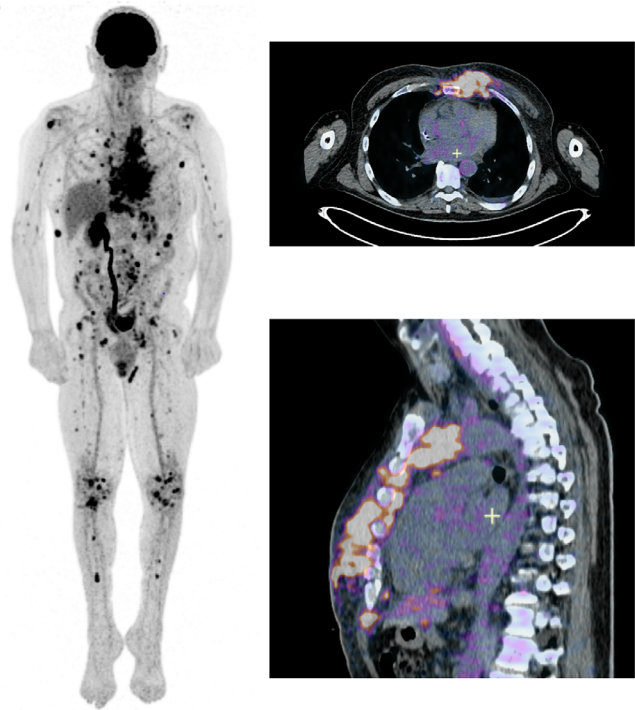
This is an open access article under the terms of the Creative Commons Attribution License, which permits use, distribution and reproduction in any medium, provided the original work is properly cited.

© 2020 The Authors. *eJHaem* published by British Society for Haematology and John Wiley & Sons Ltd.

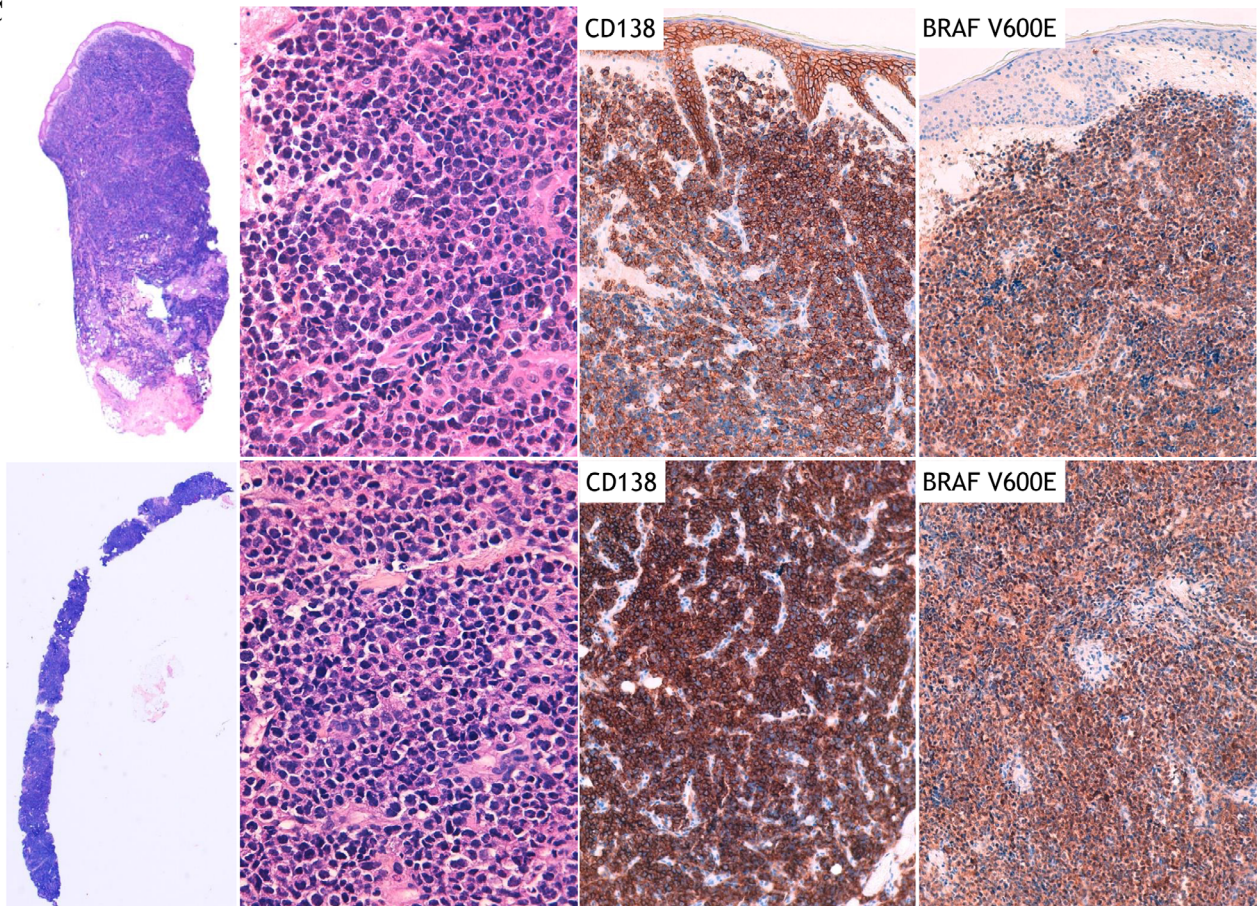
A



B



C



**FIGURE 1** Patient disease with extramedullary involvement. A, Patient with relapsed refractory multiple myeloma with extramedullary skin involvement. B,  $^{18}\text{F}$ FDG PET-CT imaging showing extramedullary involvement and multiple focal lesions on axial and appendicular skeleton. C, Morphology and immunochemistry of skin biopsies performed before and at the time of disease progression under BRAF+MEK inhibition. Upper part: pretreatment skin biopsy showing a diffuse cutaneous and subcutaneous infiltration by large tumor cells (a,  $\times 1.25$  magnification; b,  $\times 40$



inhibition but experienced early disease progression related to a clonal evolution involving RAS.

A 60-year-old male was diagnosed with symptomatic free-light chain kappa MM in November 2018. At the time of diagnosis, he presented with anemia, bone lesions, hypercalcemia, and circulating plasma cells (5%). Revised International Scoring System score was 3. The Fluorescence in situ Hybridization analysis identified a 1p32 deletion. Front-line therapy consisted on the triplet bortezomib-lenalidomide-dexamethasone (VRd). After three cycles, the patient presented disease progression with new bone lesions and appearance of extramedullary disease involving skin (Figures 1A and 1B). At that time, the triplet combination carfilzomib-pomalidomide-dexamethasone (KPd) was initiated. After two cycles, disease progression was confirmed and the patient started daratumumab-cyclophosphamide and dexamethasone. Again, therapy was ineffective with extramedullary disease progression. A skin biopsy confirmed the presence of clonal plasma cell involvement expressing BRAF V600E mutant (Figure 1C). Molecular analysis revealed the presence of a BRAF mutation (p.Val600Glu; c.1799T>A, 43%) together with a TP53 mutation (p.Cys176Gly; c.526T>G; 91%). In this context of penta-refractory (bortezomib, lenalidomide, carfilzomib, pomalidomide, and daratumumab) MM with extramedullary BRAF-mutated disease, the combination of dabrafenib (an oral BRAF inhibitor) associated with trametinib (an oral MEK inhibitor) was initiated. The patient presented a rapid clinical response with complete disappearance of skin lesions. No drug-related adverse event has been reported. Two months after treatment initiation, the patient experienced disease progression with recurrence of extramedullary disease. A new skin biopsy at the same site confirmed clonal plasma cells recurrence. Gene sequencing revealed the emergence of a mutation of NRAS p.Gly12Asp (c.35G>A, 47%) and the persistence of TP53 (90%) and BRAF (48%) mutations already present before treatment with the combination of dabrafenib plus trametinib. Backtracking of the NRAS mutation was performed by digital polymerase chain reaction on the material sampled before treatment initiation and identified the pre-existence of the NRAS p.G12D mutation at a subclonal level, with a variant allele frequency of 0.1% (Figure 2). At time of disease progression on dabrafenib plus trametinib, the patient was treated with panobinostat in addition with bortezomib and dexamethasone. No clinical response was obtained and the patient died a few weeks later due to disease progression.

To date, the clinical response to BRAF-targeted therapy in relapsed MM patients harboring BRAF mutation has been reported in only a few patients [8–11]. The efficacy of the BRAF inhibitor vemurafenib as single agent has been reported in four patients with relapsed extramedullary MM with BRAF p.V600E mutation that failed both proteasome inhibitor and immunomodulatory agents [6,9,10]. In this context, vemurafenib provided partial responses during from 2 to 8 months. In melanoma, dual rather than single inhibition of the MAPK

pathway (BRAF and MEK co-inhibition) has been shown to significantly prolong the duration of response to therapy [11]. In myeloma, the combination of BRAF and MEK co-inhibition (vemurafenib and cobimetinib, dabrafenib and trametinib) has been reported in four patients with advanced MM and BRAF p.V600E mutation and resulted in transient partial response [7,8]. Here, we obtained a transient clinical response to the combination of dabrafenib and trametinib in a penta-refractory patient with extramedullary disease harboring both a BRAF p.V600E mutation in addition with TP53 mutation.

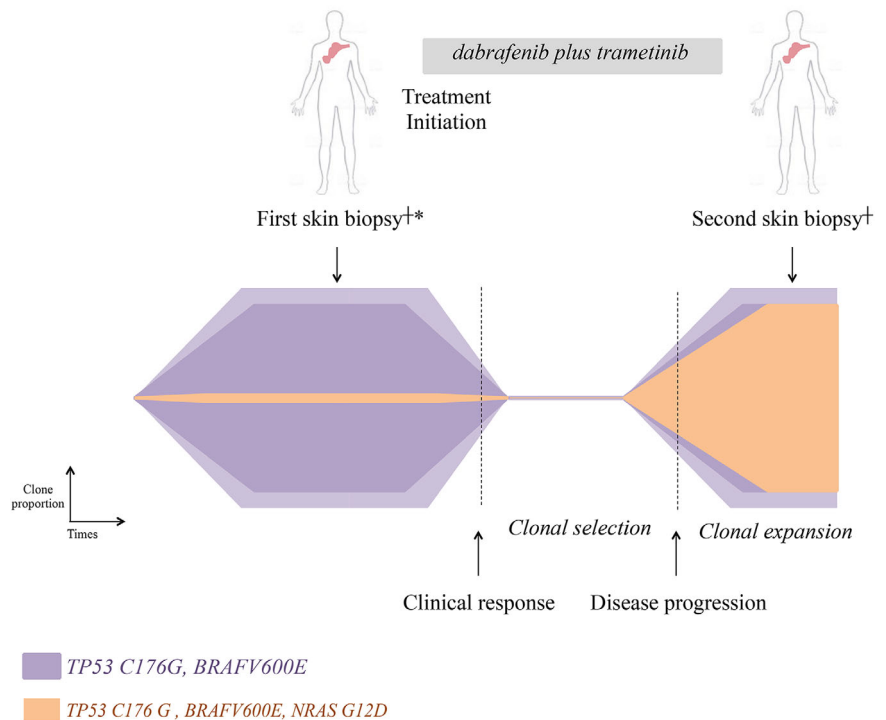
Molecular mechanisms leading to resistance to BRAF inhibition in myeloma still need to be elucidated. Recently, the case of a clonal evolution involving mutation within the capicua transcriptional repressor (CIC) gene leading to BRAF and MEK inhibitors resistance has been described in a MM patient [7]. In melanoma, mutations of genes of the RAS-family have been shown to be a major mechanism of resistance to BRAF inhibition [12]. A similar mechanism of resistance has been described in a MM patient harboring BRAF mutation treated with vemurafenib [9]. Interestingly, the authors documented the acquisition of distinct NRAS mutations in three different extramedullary lesions at time of treatment failure. In the present case, gene sequencing analysis of the tumor at the time of progression demonstrated a clonal evolution with emergence of a NRAS mutation and persistence of BRAF and TP53 mutations. In the present case, a hypothesis about the early progression is that the therapeutic pressure exerted by the combination of dabrafenib plus trametinib could have resulted in the selection of a pre-existing resistant subclone harboring both BRAF and NRAS mutations. Indeed, in RAS-mutated cells, BRAF inhibitors are known to induce paradoxical activation of the MAPK pathway via the formation of a BRAF/CRAF heterodimer [13]. This effect can be limited by the combination with a MEK inhibitor [14], nevertheless tumor escape after 2 months of treatment with this combination suggests that in MM cells carrying an activating mutation of a RAS gene, MEK inhibition is insufficient to block the excessive oncogenic activation of the MAPK pathway due to CRAF trans-activation. Although the first description in melanoma of a mutual exclusivity of NRAS and BRAF mutations, more recent studies have shown that their co-occurrence was possible in the same tumor before treatment [14]. However, if these mutations can coexist in the same melanoma lesion, data suggest that these mutations may be present in separate cell subclones, and do not coexist within the same cell. This characteristic does not seem to apply to MM, where the co-occurrence of MAPK pathway mutations has been previously described [15]. Here, it appears that they coexisted within the same cell clone before treatment.

This observation confirms the implication of NRAS mutation in the resistance to BRAF/MEK targeted therapy in MM. A Phase 1 clinical trial is currently evaluating the combination of dabrafenib and trametinib in relapsed MM patients with BRAF mutation (NCT03091257). The ongoing BIRMA trial (NCT02834364) is evaluating encorafenib

---

magnification). Immunohistochemistry demonstrated strong expression of CD138 and BRAF V600E by tumor cells (c,  $\times 200$  magnification; d,  $\times 200$  magnification). Lower part: second biopsy with the same morphological and immunophenotypic characteristics (e,  $\times 1.25$  magnification; f,  $\times 40$  magnification; g,  $\times 200$  magnification; h,  $\times 200$  magnification)

**FIGURE 2** Schematic representation of RAS/RAF clonal evolution. Methods: †DNA was extracted from fresh skin biopsies with a Maxwell RSC DNA FFPE Kit (Promega, Madison, WI, USA) and sequenced with QIAseq Targeted DNA Custom Panel (Qiagen, Hilden, DE, USA). \*Backtracking of the NRAS p.G12D mutation was performed using high-sensitivity digital polymerase chain reaction (QuantStudio 3D, Thermo Fisher Scientific, Waltham, MA, USA)



(BRAF inhibitor) in combination with binimetinib (MEK inhibitor) in BRAFV600E-mutated MM. The present case suggests performing a systematic search for RAS mutations using highly sensitive techniques in order to identify potential biomarker of resistance to those targeted therapies. The present case report highlights the need of innovative strategies to overcome resistance to BRAF/MEK co-inhibition in multiple myeloma.

#### CONFLICT OF INTEREST

The authors declare no conflict of interest.

#### AUTHOR CONTRIBUTIONS

BLC, YLB, PM, and CT wrote the manuscript. YLB, GH, CB, and OT performed experiments. CT, SLG, PM, BM, TG, NB, and JSB treated the patient. BJ provided imaging data. All the authors critically reviewed the manuscript.

#### ORCID

Yannick Le Bris  <https://orcid.org/0000-0002-0095-6999>

Bastien Jamet  <https://orcid.org/0000-0002-2145-9182>

Benoit Tessoulin  <https://orcid.org/0000-0001-7600-3329>

Cyrille Touzeau  <https://orcid.org/0000-0003-0275-2575>

#### REFERENCES

- Gandhi UH, Cornell RF, Lakshman A, Gahvari ZJ, McGehee E, Jagosky MH, et al. Outcomes of patients with multiple myeloma refractory to CD38-targeted monoclonal antibody therapy. *Leukemia*. 2019;33:2266–75.
- Bolli N, Avet-Loiseau H, Wedge DC, Van Loo P, Alexandrov LB, Martincorena I, et al. Heterogeneity of genomic evolution and mutational profiles in multiple myeloma. *Nat Commun*. 2014;5:2997.
- Boyle EM, Ashby C, Tytarenko R, Deshpande S, Wang Y, Sawyer J, et al. BRAF and DIS3 mutations associate with adverse outcome in a long-term follow-up of patients with multiple myeloma. *Clin Cancer Res*. 2020. <https://doi.org/10.1158/1078-0432.CCR-19-1507>
- Chapman MA, Lawrence MS, Keats JJ, Cibulskis K, Sougnez C, Schinzel AC, et al. Initial genome sequencing and analysis of multiple myeloma. *Nature*. 2011;471:467–72.
- Lionetti M, Barbieri M, Todoerti K, Agnelli L, Marzorati S, Fabris S, et al. Molecular spectrum of BRAF, NRAS and KRAS gene mutations in plasma cell dyscrasias: implication for MEK-ERK pathway activation. *Oncotarget*. 2015;6:24205–17.
- Andrulis M, Lehnert N, Capper D, Penzel R, Heining C, Huellein J, et al. Targeting the BRAF V600E mutation in multiple myeloma. *Cancer Discov*. 2013;3:862–9.
- Da Vià MC, Solimando AG, Garitano-Trojaola A, Barrio S, Munawar U, Striffler S, et al. CIC mutation as a molecular mechanism of acquired resistance to combined BRAF-MEK inhibition in extramedullary multiple myeloma with central nervous system involvement. *Oncologist*. 2019. <https://doi.org/10.1634/theoncologist.2019-0356>
- Mey UJM, Renner C, von Moos R, Vemurafenib in combination with cobimetinib in relapsed and refractory extramedullary multiple myeloma harboring the BRAF V600E mutation. *Hematol Oncol*. 2017;35:890–3.
- Raab MS, Lehnert N, Xu J, Ho AD, Schirmacher P, Goldschmidt H, et al. Spatially divergent clonal evolution in multiple myeloma: overcoming resistance to BRAF inhibition. *Blood*. 2016;127:2155–7.
- Sharman JP, Chmielecki J, Morosini D, Palmer GA, Ross JS, Stephens PJ, et al. Vemurafenib response in 2 patients with posttransplant refractory BRAF V600E-mutated multiple myeloma. *Clin Lymphoma Myeloma Leuk*. 2014;14:e161–3.
- Long GV, Stroyakovskiy D, Gogas H, Levchenko E, de Braud F, Larkin J, et al. Combined BRAF and MEK inhibition versus BRAF inhibition alone in melanoma. *N Engl J Med*. 2014;371:1877–88.



12. Nazarian R, Shi H, Wang Q, Kong X, Koya RC, Lee H, et al. Melanomas acquire resistance to B-RAF(V600E) inhibition by RTK or N-RAS upregulation. *Nature*. 2010;468:973–7.
13. Heidorn SJ, Milagre C, Whittaker S, Nourry A, Niculescu-Duvas I, Dhomen N, et al. Kinase-dead BRAF and oncogenic RAS cooperate to drive tumor progression through CRAF. *Cell*. 2010;140:209–21.
14. Del Regno L, Louveau B, Battistella M, Sadoux A, Baroudjian B, Delyon J, et al. Clinical significance of BRAF/NRAS concurrent mutations in a clinic-based metastatic melanoma cohort. *Br J Dermatol*. 2019. <https://doi.org/10.1111/bjd.18641>
15. Pasca S, Tomuleasa C, Teodorescu P, Ghiaur G, Dima D, Moisoiu V, et al. KRAS/NRAS/BRAF mutations as potential targets in multiple myeloma. *Front Oncol*. 2019;9:1137.

**How to cite this article:** Le Calvez B, Le Bris Y, Herbreteau G, et al. RAS mutation leading to acquired resistance to dabrafenib and trametinib therapy in a multiple myeloma patient harboring BRAF mutation. *eJHaem*. 2020;1:318–322. <https://doi.org/10.1002/jha2.8>