

CASE REPORT

Duplicated common bile duct: a recipe for biliary injury. Report of a new variant

Nabil M. Nuamah^{1,*}, Cem Ibis², Ali F.K. Gok³, Feza Ekiz³, and Bulent Acunas⁴

¹Department of Surgery, 37 Military Hospital, Accra, Ghana, ²Department of Surgery, Hepatopancreatobiliary and Liver Transplant Unit Istanbul University, Istanbul Medical Faculty, Istanbul, Turkey, ³Department of Surgery Istanbul University, Istanbul Medical Faculty, Istanbul, Turkey, and ⁴Department of Radiology Istanbul University, Istanbul Medical Faculty, Istanbul, Turkey

*Correspondence address. Department of Surgery, 37 Military Hospital, Accra, Ghana. Tel: +233-20-941-9355; E-mail: dnuamah72@yahoo.com

Abstract

Duplicated common bile duct, often associated with conditions like lithiasis, biliary cysts and pancreatobiliary maljunction, could result in highly morbid and potentially fatal biliary injuries. Precise preoperative diagnosis and classification still remain a challenge. A female patient undergoing emergency laparoscopic cholecystectomy for acute calculous cholecystitis sustained iatrogenic bile duct injury. A drainage tube was placed into the injured duct for post-operative conservative management. Post-operative tube cholangiogram revealed a double common bile duct with cystic duct opening distally. This was identified as a new variant not previously reported or classified. However rare, duplicated common bile duct could result in serious iatrogenic bile duct injury if unidentified during surgery. Knowledge of its existence is essential to avoid such injuries as preoperative diagnosis still remains a challenge. A thorough clinical and morphological study of previously reported variants is needed for a comprehensive classification to encompass newly discovered variants.

INTRODUCTION

Extrahepatic biliary duct duplication, also commonly called duplicated common bile duct (DCBD), is exceptionally rare and mostly turn to be unexpected finding during surgery exposing surgeons to unusual surprises leading to iatrogenic bile duct injuries (BDI). This anomaly has been reported to be associated with multiple disorders including cholelithiasis, choledocholithiasis, choledochal cyst, pancreatobiliary maljunction (PBM) and malignancy [1]. Recognition of the existence of this anomaly is important to prevent iatrogenic biliary injury and most importantly help in making the right surgical decision. After the first case of DCBD reported by Vesalius in 1543, numerous cases of different variants have been reported in the English literature across the globe [2–5]. Only seven out of nine variants currently described in the literature can be classified by

available classification systems [4]. Presented here-in, is a new variant of DCBD discovered after iatrogenic bile duct injury during laparoscopic cholecystectomy. The importance of recognition of its existence to avoidance BDI during surgery coupled with the need for a comprehensive classification system to encompass newly discovered variants are highlighted.

CASE PRESENTATION

A 64-year-old female presented to the surgical emergency unit with a day's history of right upper quadrant pain. Her physical examination revealed right upper quadrant tenderness with no rebound tenderness or muscular guarding. Other systemic findings were normal. Laboratory test showed leukocytosis of $17 \times 10^3/\mu\text{L}$ and elevated C-reactive protein of 51 mg/L (0–5 ml/L). Other

Received: December 15, 2016. Accepted: January 26, 2017

Published by Oxford University Press and JSCR Publishing Ltd. All rights reserved. © The Author 2017.

This is an Open Access article distributed under the terms of the Creative Commons Attribution Non-Commercial License (<http://creativecommons.org/licenses/by-nc/4.0/>), which permits non-commercial re-use, distribution, and reproduction in any medium, provided the original work is properly cited. For commercial re-use, please contact journals.permissions@oup.com

laboratory values including serum amylase, bilirubin and transaminases were normal. Abdominal ultrasound revealed thickened gallbladder (GB) wall (4.7 mm) with a 25 mm gallstone. A diagnosis of acute calculous cholecystitis was made and intravenous fluid and antibiotic treatment were initiated. Laparoscopic cholecystectomy was considered after 48 h of observation. During surgery a standard 4-port technique was used after pneumoperitoneum using the Veress needle. GB wall was found to be inflamed with omental adhesions. Using the critical view of safety approach, the cystic artery and cystic duct were separately identified, clipped and transected. After careful dissection of the GB from the liver bed small amount of bile was observed oozing from a spot proximal to the ligated cystic duct stump. Irrigation of the spot revealed a small tear at what was thought to be the common hepatic duct. A 5-Fr drainage catheter (50 cm long, 1.4 mm in diameter) was placed into the opened duct and exteriorized through the mid-clavicular 5 mm port site for post-operative drainage. A tube cholangiography done on post-operative Day 7 showed duplication of the common hepatic duct proximal to the cystic duct stump with the injury occurring on the right-sided duct (Fig. 1). A magnetic resonance cholangiopancreatography (MRCP) was taken which confirmed the presence of the duplicated common hepatic duct with the cystic duct stump distal to the duplication (Fig. 2). No PBM was observed. Her post-operative course was uneventful with an average biliary drainage output of about 300 ml. Drainage tube was clamped on post-operative Day 9 and finally removed 4 weeks after surgery. No complication was observed and patient is currently doing well.

DISCUSSION

The wide variation in morphology of reported cases of DCBD has posed a great challenge in its precise anatomical definition and classification. Goor and Ebert initial classification described seven configurations divided into four groups [2]. Choi *et al.* proposed modified classification system describes five groups, with subtypes, involving seven variants as depicted in Fig. 3 [4]. In the case presented here-in, the anomaly was discovered post-operatively by tube cholangiography following iatrogenic bile duct injury during laparoscopic cholecystectomy. The double ducts were noted to originate from the hepatic duct confluence

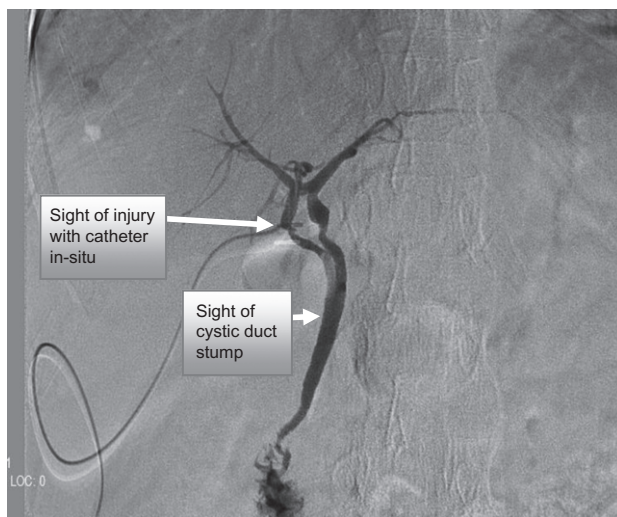


Figure 1: Cholangiogram showing the double duct originating from the hepatic hilus with injury on the right duct. The two ducts drain singly with cystic duct opening into the common duct.

separately and rejoined distally with the cystic duct noted to open into the unified duct (Figs 1 and 2). The injury occurred on the right-sided duct. This variant appears to be different from previously reported type V in which the cystic duct opens into the right duct before joining the left duct. Therefore this case appears to be a new variant not previously reported or classified. Literature review showed similar reported cases of inadvertent BDI associated with DBCD during surgery [6, 7] and other configurations that could not be classified with existing classification systems [3, 5, 8] [Fig. 4]. These reports reaffirm and underscore the importance of prior knowledge of the existence of this anomaly and careful dissection within the hepato-gastroduodenal ligament to avoid BDI, particularly during laparoscopic cholecystectomy. The clinical importance of this anomaly lies with its association with conditions such as cholecysto-choledocholithiasis and choledochal

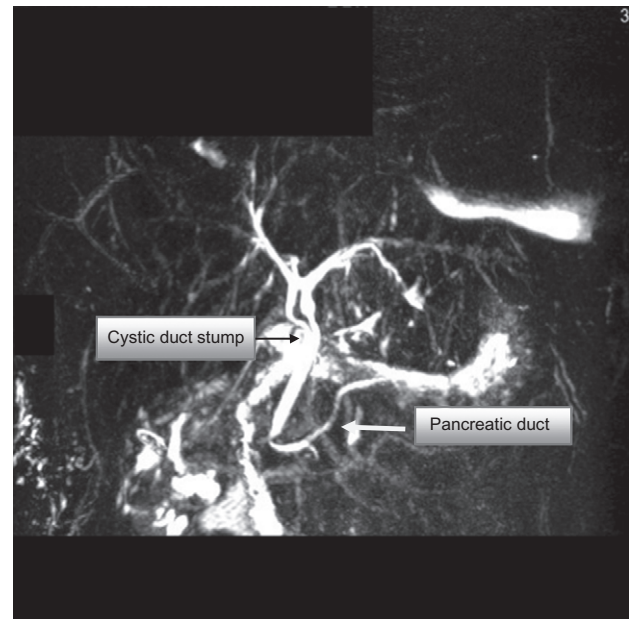


Figure 2: MRCP showing the double common bile duct, cystic duct stump and pancreatic duct. The cystic duct stump is noted to open distally into the common duct.

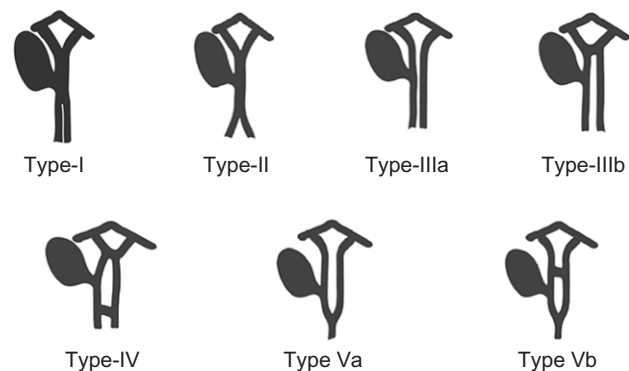


Figure 3: Modified double common bile duct classification proposed by Choi *et al.* Type I: CBD separated by septum; Type II: CBD that bifurcates to drain separately; Type III: double biliary drainage without extrahepatic communication channels (without IIIa) or with IIIb intrahepatic connecting channels; Type IV: double biliary drainage with one or more extrahepatic communication channels; Type V: single biliary drainage of double extrahepatic bile ducts without (Va) or with (Vb) communication channels.

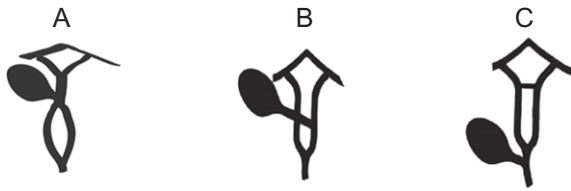


Figure 4: Unclassified reported variants. (A) Variant described by Paraskevas et al. and Sahu et al. (B) Variant described by Kosar et al. (C) Variant described in current report.

cyst, the risk of malignant transformation and the risk of exposing patients to biliary injury during surgery, if not detected preoperatively. The type of malignant transformation seems to be directly related to the drainage site of the ducts (gastric, duodenal or pancreatic) and the presence of PBM [1]. In a review of 47 cases in the Japanese literature, Yamashita et al. reported an incidence of cholelithiasis in 28%, choledochal cyst in 11%, PBM in 30% and malignancy in 26% of the cases [1]. An earlier review by Kanematsu et al. [9] reported an incidence of 48% calculous formation associated with DCBD anomaly. Review of 24 cases in the Chinese literature also revealed cholelithiasis in 37%, choledocholithiasis in 79%, choledochal cyst in 33% and PBM in 8% of the reported cases [10]. The high incidence of gallstone formation associated with this anomaly is thought to be due to bile stasis and repetitive cholangitis resulting from reflux of gastrointestinal content into the anomalous duct.

CONCLUSION

Extrahepatic bile duct duplication could be a recipe for disaster during surgery and a prior knowledge of its existence is important to avoid inadvertent BDI. A thorough review of all reported variants is needed for a comprehensive classification system of clinical significance.

ACKNOWLEDGEMENTS

We thank Dr Jared A. White (UAB liver transplant and hepatobiliary surgery, Birmingham, USA) and Dr G. Paraskevas of Greece for responding to our request seeking some clarification on their publication.

DISCLOSURE

Non-financial support disclosed.

COMPETING INTERESTS

None declared.

REFERENCES

1. Yamashita K, Oka Y, Urakami A, Iwamoto S, Tsunoda T, Eto T. Double common bile duct: a case report and a review of the Japanese literature. *Surgery* 2002;131:676–81.
2. Goor DA, Ebert PA. Anomalies of the biliary tree. Report of a repair of an accessory bile duct and review of the literature. *Arch Surg* 1972;104:302–9.
3. Paraskevas G, Papaziogas B, Ioannidis O, Kitsoulis P, Spanidou S. Double common bile duct: a case report. *Acta Chir Belg* 2009;109:507–9.
4. Choi E, Byun JH, Park BJ, Lee MG. Duplication of the extrahepatic bile duct with anomalous union of the pancreaticobiliary ductal system revealed by MR cholangiopancreatography. *Br J Radiol* 2007;80:150–4.
5. Kosar I, Ataseven H, Yonem O, Cakmak E, Ozer O, Ozer H, et al. A new variant of bile duct duplication with coexistence of distal cholangiocarcinoma. *Nat Rev Gastroenterol Hepatol* 2010;7:527–30.
6. Park JI, Oh SH. Double common bile duct with an ectopic drainage into the stomach. *Ann Surg Treat Res* 2015;88:229–31.
7. Hoepfner L, Sweeney KM, White JA. Duplicated extrahepatic bile duct identified following cholecystectomy injury. *J Surg Case Rep* 2016;4:1–3.
8. Sahu SK, Kumar S, Ray J. Double common bile duct. *Sri Lanka J Surg* 2014;32:27–9.
9. Kanematsu M, Imaeda T, Seki M, Goto H, Doi H, Shimokawa K. Accessory bile duct draining into the stomach: case report and review. *Gastrointest Radiol* 1992;17:27–30.
10. Chen G, Wang H, Zhang L, Li Z, Bie P. Double common bile duct with choledochal cyst and cholelithiasis: report of a case. *Surg Today* 2014;44:778–82.