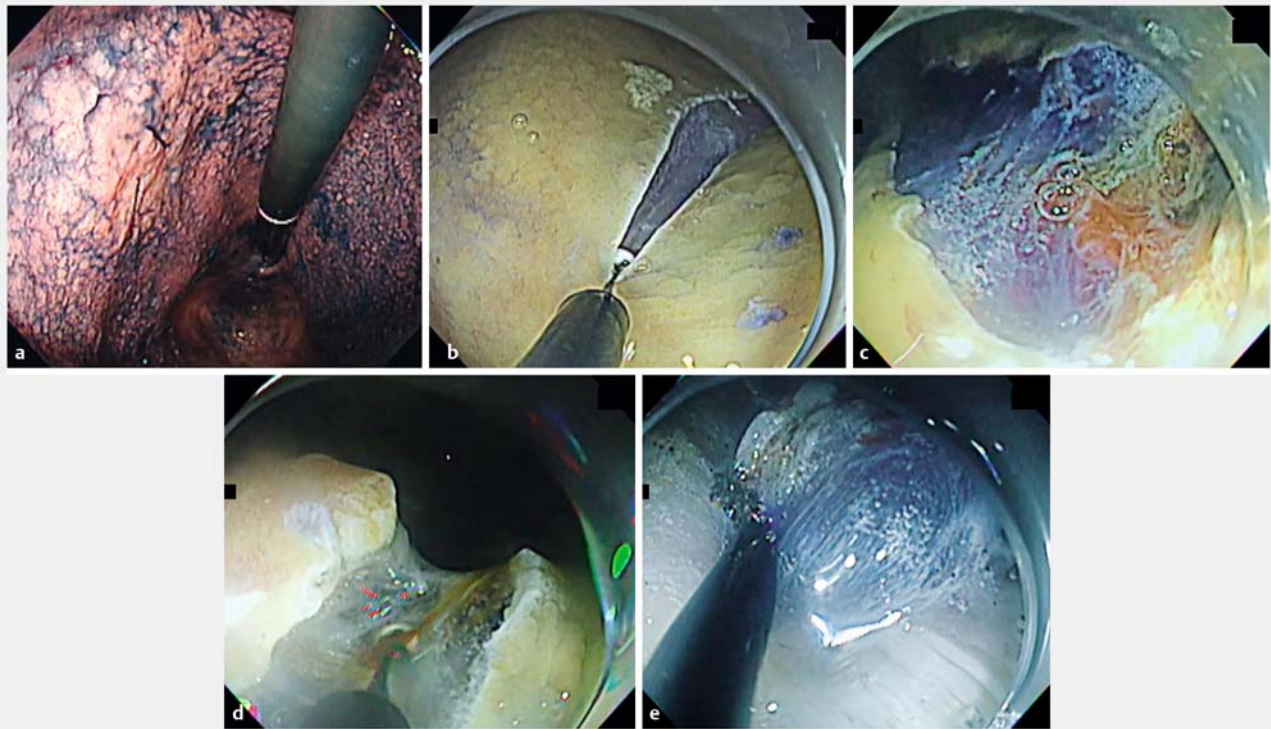


Endoscopic submucosal dissection of an early-stage gastric tumor with minimal bleeding using full-time red dichromatic imaging



► Fig. 1 Images illustrating the steps of endoscopic submucosal dissection using full-time red dichromatic imaging (RDI). **a** Flat elevated lesion (50 mm) located on the lesser curvature of the gastric body. **b** Circumferential incision is performed in RDI mode. **c** Vessels of the submucosa are clearly visible. **d** Bleeding points are easily identifiable with RDI. **e** The demarcation line between the submucosal and muscle layers is clearly visible.

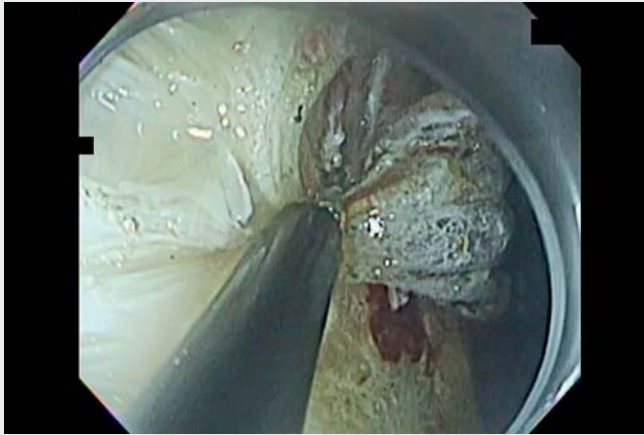Hemostasis during endoscopic submucosal dissection (ESD) can be challenging and time-consuming [1], as the thick vessels in the stomach can bleed profusely [2]. Red dichromatic imaging (RDI) was recently developed to address this difficulty [3]; it improves recognition of the bleeding points and enables safe hemostasis while reducing the psychological stress on the endoscopist. However, to date RDI has not significantly reduced hemostasis time [4]. We present the case of a patient with early gastric cancer in whom bleeding during ESD was promptly controlled using full-time RDI.

A 77-year-old man with gastric cancer (50 mm) was referred to our facility for ESD (► **Fig. 1 a**). We used a GIF-H290T

gastroscope (Olympus, Tokyo, Japan), the EVIS X1 video system (Olympus, Tokyo, Japan) as the light source, and an electrosurgical knife (IT2 knife; Olympus, Tokyo, Japan) for ESD. All procedures including submucosal injection, circumferential mucosal incision, submucosal dissection, and postresection hemostasis were performed in RDI mode. The submucosal injection and mucosal incision (► **Fig. 1 b**) were performed carefully avoiding deep vessels through the use of RDI. Because we could clearly identify submucosal vessels (► **Fig. 1 c**), the thick vessel was precoagulated. Any bleeding points were easily detected with RDI, allowing quick and effective hemostasis (► **Fig. 1 d**). The demarcation line be-

tween the submucosal and muscle layers was also clear, allowing safe submucosal dissection (► **Fig. 1 e**). Exposed ulcer vessels after resection were recognized clearly using RDI. The 65-mm specimen was resected en bloc in 40 minutes; only two bleeding events occurred with no complications (► **Video 1**).

This experience demonstrates that RDI is not only useful for quickly identifying bleeding points but is highly effective in avoiding hemorrhage by rendering the blood vessels more visible. Considering that RDI enables easier recognition of the submucosal layer [5], ESD using full-time RDI has the potential to become mainstream.



Video 1 Endoscopic submucosal dissection of a gastric tumor using full-time red dichromatic imaging.

- [4] Fujimoto A, Saito Y, Abe S et al. Clinical usefulness of red dichromatic imaging in hemostatic treatment during endoscopic submucosal dissection: first report from a multicenter, open-label, randomized controlled trial. *Dig Endosc* 2022; 34: 379–390
- [5] Miyamoto S, Ohya TR, Nishi K et al. Effectiveness of red dichromatic imaging for dissection of the submucosal layer when hematoma is encountered. *Endoscopy* 2021; 53: E413–E414

Bibliography

Endoscopy 2022; 54: E1001–E1002

DOI 10.1055/a-1887-6024

ISSN 0013-726X

published online 4.8.2022

© 2022. The Author(s).

This is an open access article published by Thieme under the terms of the Creative Commons Attribution-NonDerivative-NonCommercial License, permitting copying and reproduction so long as the original work is given appropriate credit. Contents may not be used for commercial purposes, or adapted, remixed, transformed or built upon. (<https://creativecommons.org/licenses/by-nc-nd/4.0/>)

Georg Thieme Verlag KG, Rüdigerstraße 14, 70469 Stuttgart, Germany



ENDOSCOPY E-VIDEOS

<https://eref.thieme.de/e-videos>



Endoscopy E-Videos is an open access online section, reporting on interesting cases and new

techniques in gastroenterological endoscopy. All papers include a high quality video and all contributions are freely accessible online. Processing charges apply (currently EUR 375), discounts and waivers acc. to HINARI are available.

This section has its own submission website at

<https://mc.manuscriptcentral.com/e-videos>

Endoscopy_UCTN_Code_CCL_1AB_2AD_3AZ

Competing interests

The authors declare that they have no conflict of interest.

The authors

Yohei Ikenoyama^{1,2}, Ayaka Iri³, Hajime Imai³, Hayato Nakagawa²

- 1 Department of Gastroenterology, Cancer Institute Hospital, Japanese Foundation for Cancer Research, Tokyo, Japan
- 2 Department of Gastroenterology and Hepatology, Mie University Hospital, Tsu, Japan
- 3 Department of Gastroenterology, Okanami General Hospital, Iga, Japan

Corresponding author

Yohei Ikenoyama, MD, PhD

Department of Gastroenterology Cancer Institute Hospital, 3-8-31, Ariake, Koto-ku, Tokyo 135-8550, Japan
307006yohei@gmail.com

References

- [1] Tanaka S, Toyonaga T, Morita Y et al. Efficacy of a new hemostatic forceps during gastric endoscopic submucosal dissection: a prospective randomized controlled trial. *J Gastroenterol Hepatol* 2017; 32: 846–851
- [2] Saito I, Tsuji Y, Sakaguchi Y et al. Complications related to gastric endoscopic submucosal dissection and their managements. *Clin Endosc* 2014; 47: 398–403
- [3] Yahagi N, Fujimoto A, Horii J et al. Dual red imaging: a novel endoscopic imaging technology visualizing thick blood vessels in the gastrointestinal wall. *Endosc Int Open* 2019; 7: E1632–E1635