

# Enhancement of Healing of Periodontal Intrabony Defects Using 810 nm Diode Laser and Different Advanced Treatment Modalities: A Blind Experimental Study

Shrief Hemaïd<sup>1\*</sup>, Ali Saafan<sup>1</sup>, Manal Hosny<sup>2</sup>, Gernot Wimmer<sup>3</sup>

<sup>1</sup>*Dental Laser Applications, Department of Medical Applications of Laser, National Institute for Laser Enhanced Sciences, Cairo University, Cairo, Egypt;* <sup>2</sup>*Department of Oral Medicine and Periodontology, Faculty of Dentistry, Cairo University, Cairo, Egypt;* <sup>3</sup>*Department of Oral Medicine and Periodontology, Meduni Graz, Graz, Austria*

## Abstract

**Citation:** Hemaïd S, Saafan A, Hosny M, Wimmer G. Enhancement of Healing of Periodontal Intrabony Defects Using 810 nm Diode Laser and Different Advanced Treatment Modalities: A Blind Experimental Study. *Open Access Maced J Med Sci*. 2019 Jun 15; 7(11):1847-1853. <https://doi.org/10.3889/oamjms.2019.484>

**Keywords:** NanoHydroxyApatite; Laser biostimulation; Periodontal intrabony defects; Rabbits; Platelet-rich fibrin

**\*Correspondence:** Shrief Hemaïd. Dental Laser Applications, Department of Medical Applications of Laser, National Institute for Laser Enhanced Sciences, Cairo University, Cairo, Egypt. E-mail: [shriefhemaïd@yahoo.com](mailto:shriefhemaïd@yahoo.com)

**Received:** 18-Apr-2019; **Revised:** 23-May-2019; **Accepted:** 24-May-2019; **Online first:** 14-Jun-2019

**Copyright:** © 2019 Shrief Hemaïd, Ali Saafan, Manal Hosny, Gernot Wimmer. This is an open-access article distributed under the terms of the Creative Commons Attribution-NonCommercial 4.0 International License (CC BY-NC 4.0)

**Funding:** This research did not receive any financial support

**Competing Interests:** The authors have declared that no competing interests exist

**BACKGROUND:** Low-level laser therapy (LLLT) in the early stage of bone healing was demonstrated as a positive local biostimulative effect. It was also shown that platelet-rich fibrin (PRF) and nanohydroxyapatite alloplast (NanoHA) are effective in treating periodontal intrabony defects.

**AIM:** The study aimed to evaluate the combined effects of LLLT (810 nm), PRF and NanoHA on induced intrabony periodontal defects healing.

**MATERIAL AND METHODS** The study was conducted on 16 defects in 8 adult male rabbits (n = 16) divided into 4 groups; Control non-treated group (C), laser irradiated control group (CL), PRF+NanoHA graft (NanoHA-Graft+PRF) treated group and laser irradiated and treated group (NanoHA-Graft+PRF+L). CT radiography was made at baseline, 15 and 30 days later. The defects were induced in the form of one osseous wall defects of 10 mm height, 4 mm depth between the 1<sup>st</sup> and the 2<sup>nd</sup> molars using a tapered fissure drill coupled to a high-speed motor. Statistical analysis was done using ANOVA.

**RESULTS:** (NanoHA-Graft+PRF+L) group significantly produced bone density higher than C, CL and NanoHA-G+PRF alone.

**CONCLUSION:** The combination of LLLT+PRF+NanoHA as a treatment modality induced the best results in bone formation in the bone defect more than LLLT alone or PRF+NanoHA alone.

## Introduction

Periodontitis is a chronically multifactorial inflammatory disease related to dysbiotic plaque biofilms and characterised by the gradual destruction of dental supportive apparatus [1]. It is caused by specific microorganisms resulting in progressive destruction of the periodontal ligament [PDL] and clinical attachment loss (CAL) or alveolar bone with pocket formation, recession or both [1], [2], [3], [4].

Periodontal therapy's general objectives include 1 — prevention of primary and secondary periodontal diseases through infection and inflammation control and 2. The maintenance or improvement of all supporting structures and tissues (gingivae, PDL], cement and alveolar bone), in health

and function, comfort and aesthetic [5].

Periodontal regeneration is a complex multifactorial process involving biologic events like cell adhesion, migration, proliferation, and differentiation in a composed sequence. Regenerative periodontal procedures [6], [7], [8] include soft tissue grafts, bone grafts, root biomodifications, guided tissue regeneration [GTR], laser biostimulation and combinations of these procedures.

After Maiman had introduced the first actual laser system in 1960, [9] the laser was introduced in dentistry than in periodontology and divided into high-level laser [HLL] and Low-Level laser [LLL].

Recently, LLLT has been used as a biostimulator for tissue repair, as it helps to improve local circulation, cell proliferation and collagen synthesis [10], [11], [12].

At the cellular level, LLL induces biochemical, bioelectric and bioenergetic improvements, leading to increased metabolism, mitotic activity of epithelial cells, fibroblasts cell proliferation and maturation, collagen construction, granulation tissue increase, decrease of inflammatory mediators, triggering the healing process through changes in capillary density and stimulation of local microcirculation [13], [14], [15].

In some studies, on new bone formation, it was stated that the laser's biostimulation effect is not only due to its specific characteristics but also to the development of a series of local conditions that accelerate the bone formation and oedema resolution [16].

This study aimed to evaluate the effect of LLLT in combination with Nano-HA bone graft and autologous PRF compared to the effect of the combined treatment of Nano-HA bone graft and autologous PRF on induced periodontal intrabony defects in rabbits as experimental animal models.

## Material and Methods

### Preparation of animals

After Experimental Animal Research Ethics committee approval (Cu/I/F/11/19), This study was done over 16 intrabony defects in 8 adult male rabbits, aged 7-8 months and with an average body weight more than 2.5 kg. Before the procedures, all rabbits were separated from each other, then acclimatised in the laboratory environment for 5 days. They were fed by a special, pelleted commercial diet. They were anaesthetised using general anaesthesia with Subcutaneous injections of Ketamine and Xylazine HCl.

### Experimental groups and induction of periodontal defects

The study included preparation of 16 periodontal defects at the region of interest [ROI] that were grouped (4 defects in each group) as follows;

I) control group [C group]: the induced defects were left without adding any materials nor irradiated by laser therapy.

II) control laser group [(CL) group]: the induced defects were irradiated by Laser only.

III) the treated group (G+PRF): the induced periodontal defects were induced then treated by adding the graft material and PRF without laser irradiation.

IV) the test group (L+G+PRF): the induced defects were irradiated by laser after adding graft and the PRF to the defects.

These 4 groups were distributed randomly in rabbits where each group contains 2 rabbits(4defects) as follows:

- Group 1 (Rabbits 1&2) the right-side defects were [C group] while the left side defects were [(CL)-group].
- Group 2 (Rabbits 3&4), the right-side defects were [C group] while the left side defects were [(G+PRF)-group].
- Group 3 (Rabbits 5&6) the right-side defects were [(G+PRF)-group] while the left-side defects were [(L+G+PRF)].
- Group 4 (Rabbits 7&8); the right-side defects were [(CL)-group], while the left-side defects were (L+G+PRF).

The surgical field was prepared for the surgical intervention by being shaved carefully, then sterilised using ethanol 70%. A 5 cm rostro-caudal full-thickness incision was made in the skin and the underlying muscles for exposure of the ROI, which is the interdental area between the mandibular 1<sup>st</sup> and 2<sup>nd</sup> molars of all rabbits without vertical incisions.

After retraction of the flap corono-apically, 1- osseous-wall defect [17], [18] was then induced by exposing the distal surface of distal root of the 1<sup>st</sup> molar and mesial surface of mesial root of the 2<sup>nd</sup> molar with the aid of a stopper-premeasured tapered FG drill coupled to a high-speed motor with copious physiological saline irrigation.

The defect presented the following measures: 10 mm corono-apical (measured from the cemento-enamel junction to the most apical edge of the defect) and 4 mm deep (buccolingual direction) measured from the surface of the alveolar bone to the lingual surface of the defect. The exposed roots were curetted using Gracey curette G5/6 to remove the Sharpey's fibres of the periodontal ligament and cementum.

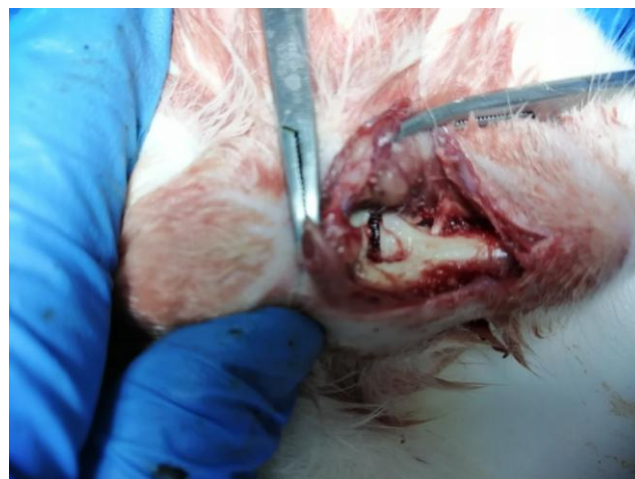

Figure 1: Defect induction

### PRF preparation

To prepare PRF, five-millilitre blood samples were collected from each rabbit before sedation using capillary tubes from the inner canthus of the eye into syringes without anti-coagulants then centrifuged at 30.000 RPM for 15 min. PRF was picked up and compressed between 2 sterile glass slides to form a thin membrane and divided into 2 pieces; one was used as a membrane, and the other was cut into pieces to be mixed with the Nano-HA reinforced Fisiograft.

### Defects treatment

Some periodontal defects were filled with the mix of FISIOGRAFT NanoHA-reinforced bone graft and PRF and then covered by PRF membrane according to the group.

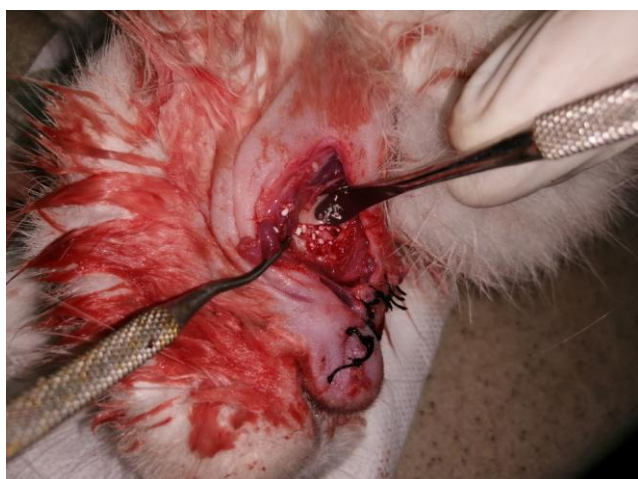


Figure 2: Filling the defect with the mix of NanoHA+PRF

The laser was applied before flap closure according to the blinding procedures using Diode laser –[GaAlAs] 810 nm- in a continuous mode of power 100 mW for 180 sec to get 18 J. with delivery tip 0.35 cm radius and 0.385 cm<sup>2</sup> area. Energy density applied was about 46.8 J/cm<sup>2</sup>. The flap was repositioned after suturing the muscles with simple interrupted pattern with 3-0 Vicryl while the skin was sutured with 3-0 Silk. The wound was left undressed to the open environment. The laser then was applied daily for 5 consecutive days postoperatively according to the blinding procedures.

### Postoperative management and assessment

Baseline CT radiography was operated and repeated on the living rabbits at the 15 and 30 days later. The rabbits were then housed in an individual cage. The room was maintained at 22° relative humidity and a 12-hour light-dark cycle. Food and water were provided ad libitum. Postoperative

analgesic (Diclofenac Sodium) was taken once daily for 3 days S.C 10 mg/kg. Postoperative antibiotic (Ceftriaxone) was taken once daily for 3 days S.C. 25 mg/kg.

Laser device was operated daily to each rabbit in 4 sessions (2 to the right side and 2 to the left side) of 90 seconds every session where;

- In group 1 and 3, the device was adjusted to the non-laser mode for the right side and adjusted to laser mode for the left side.
- In group 2, the device was adjusted to the non-laser mode for the right side and the left side.
- In group 4, the device was adjusted to laser mode for the right and the left sides.

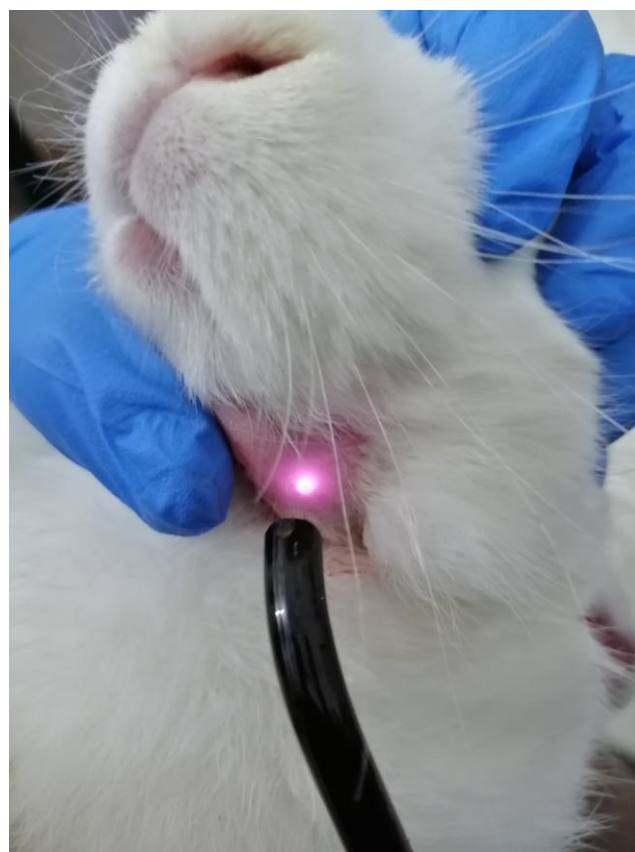

Figure 3: Laser biostimulation

CT radiographs were taken for the live animals at baseline, 15 and 30 days later.

The collected data were analysed statistically using SPSS (version 20), and Excel 2013 programs were used for data analysis. Mean, and standard deviation of quantitative data was estimated. Bone density at baseline, 15<sup>th</sup> and 30<sup>th</sup> days were analysed with ANOVA test to determine the differences within each group and between groups at different observation periods. The significance ( $\sigma$ ) level was set at  $P \leq 0.05$ .

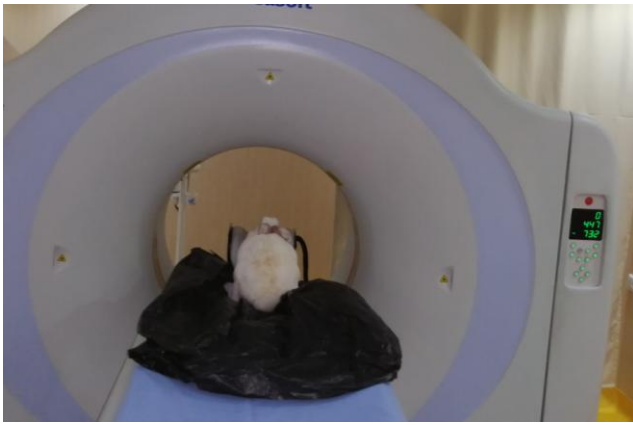


Figure 4: CT radiography for the rabbit

**Randomisation and blinding procedures**

For randomisation, the rabbits were numbered and randomly allocated in the groups (1, 2, 3, 4).

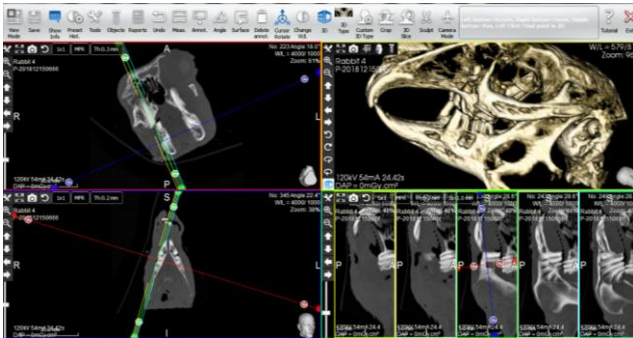


Figure 5: Baseline CT radiography of one of (G+PRF+L) group rabbits

For blinding procedures: Triple blinding was applied where all surgical procedures were performed by the periodontist researcher. Laser device was adjusted by the main operator and operated blindly by another clinician. The CT radiography was operated by a technician and analysed by a radiologist who didn't know the group allocation of the defect. The statistician also didn't know the treatment modality of each group.

**Results**

**Differences in bone densities within each group at different time intervals**

Changes in mean bone density of ROI in different groups are presented and compared at different observation periods (Table 1).

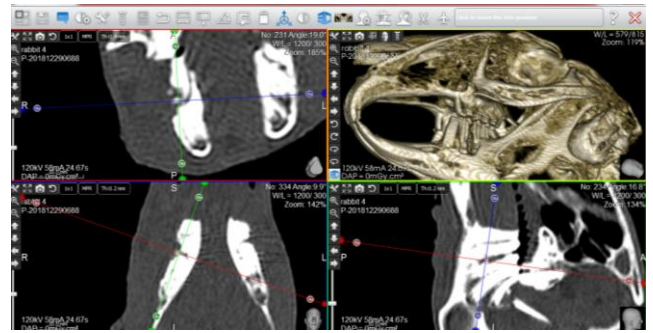


Figure 6: 15<sup>th</sup> day CT radiography of one of (G+PRF+L) group rabbits

All treatment groups showed increased bone density after 15 and 30 days. Only the (C) group showed a non-significant increase after 15 and 30 days compared to baseline. While the groups (CL), (G+PRF) and (G+PRF+L) showed significant increase after 15 days compared to the baseline (P= 0.00 , P= 0.00 and P= 0.00 respectively) and also showed significant increase after 30 days compared to the baseline (P= 0.00 , P= 0.00 and P= 0.00 respectively). Only (G+PRF+L) group showed a significant increase in bone density from the 15<sup>th</sup> day to the 30<sup>th</sup> day (p= 0.026).

Table 1: Comparison between groups and between time intervals within each group

	Mean values				P-value				
	C	G+ PRF	CL	G+PRF+L	CL: C	GPRF:C	G+PRF+L: G+PRF	G+PRF+L: CL	G+PRF+L: C
(0)	149.67± 159.13	165 ± 187.1	147.48± 177.77	243.12 ± 189.55	1.0	0.293	0.0049*	0.209	0.208
15th day	356 ± 534.81	644.1 ± 289.7	465.06± 180.55	749.74 ± 244.15	0.77	0.072	0.771	0.049*	0.0023*
15: 0	0.98	0.00	0.00	0.00					
30th day	391.25± 151.79	648.7± 273.2	564.67± 410.87	1061.94± 624.46	0.87	0.485	0.026*	0.083	0.0036*
30: 0	0.166	0.00	0.00	0.00					
30: 15	0.967	0.998	0.598	0.026					

**Differences between groups bone density at baseline**

At baseline, there was a significant difference in bone density of ROI between group (G+PRF+L) and (G+PRF) and between (G+PRF) and (CL) group (P = 0.049) and (P = 0.022).

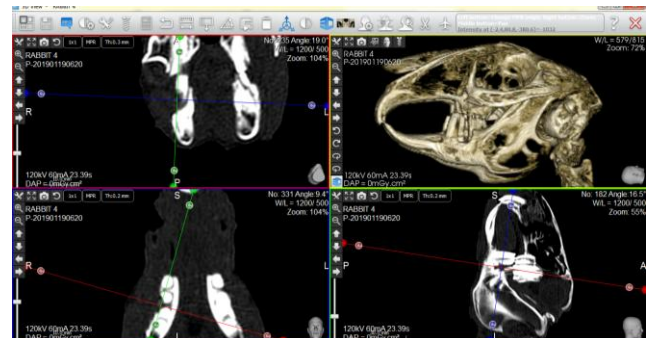


Figure 7: 30<sup>th</sup> day CT radiography of one of (G+PRF+L) group rabbits

**Changes between groups in bone density after 15 days**

After 15 days, there was a significant

difference between (G+PRF+L) and (C) and between (G+PRF+L) and (CL); P= 0.002 and 0.049 respectively.

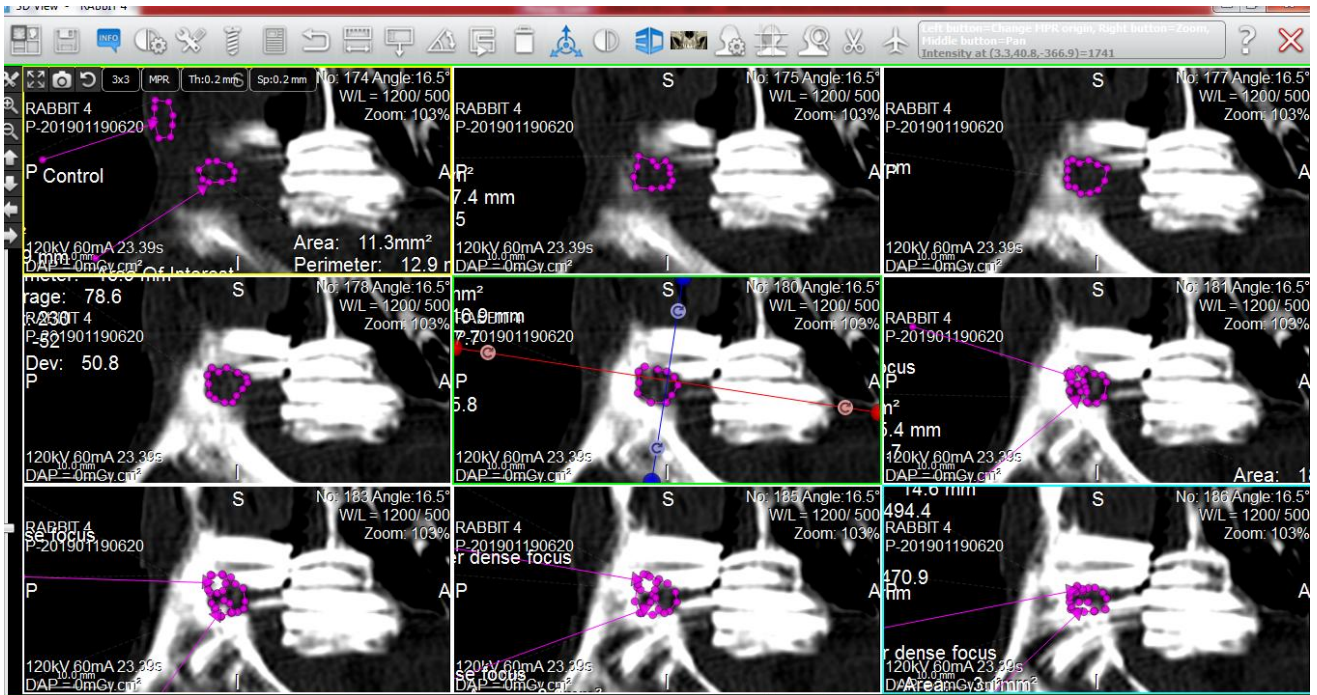


Figure 8: Baseline CT radiography assessment of one of (G+PRF+L) group rabbits

**Changes between groups in bone density after 30 days**

After 30 days, there was a significant difference between (G+PRF+L) and (C) and between (G+PRF+L) and (G+PRF); P-value = 0.004 and 0.027 respectively.

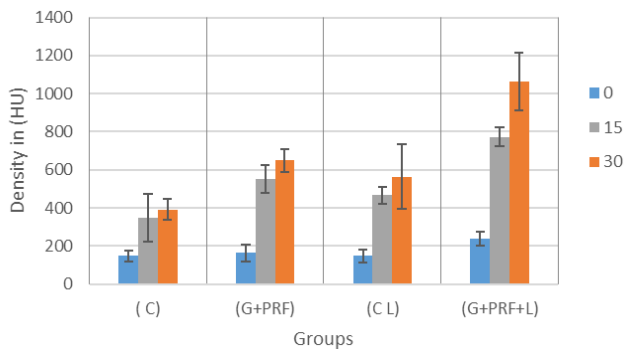


Figure 9: Bone Density in animal groups throughout time intervals; baseline, after 15 days & 30 days

**Discussion**

The effects of LLLT and a combination of PRF and Nano-HA graft on bone healing were evaluated in the current experimental study.

There is no experimental study to our

knowledge that has evaluated the combined effect of LLLT, PRF and Nano-HA graft on bone healing. A few potential limitations are needed to be considered before reaching conclusions based on the present results. Although the methodology of the current study can be applied in various settings, these results were applied exclusively to experimental animal studies and mayn't be considered generalizable. The present study was conducted on 16 defects. Our findings, however, were consistent and coherent, indicating the study's external validity strongly.

One of the challenges of clinical and experimental research is to develop the bioactive surgical additives used to regulate inflammation and increase the speed of the healing process. PRF consists of an autologous leukocyte-platelet-rich fibrin matrix composed of a tetramolecular structure with cytokines, platelets and stem cells within it, acting as a biodegradable scaffold that promotes the development of micro-vascularization and can guide epithelial cell migration to its surface [2], [19], [20], [21], [22]. It has also been demonstrated that PRF is an effective treatment for periodontal intrabony defects. In 2013 Qi Li et al. reported that PRF enhances osteogenic lineage differentiation of alveolar bone progenitors more than of periodontal progenitors by augmenting osteoblast differentiation and mineralised nodule formation via its principal component fibrin [23]. Pripatnanont et al. in 2013 [24]

reported that PRF had a positive effect on bone formation when used alone or combined with autogenous bone.

When twenty patients were treated with nanocrystalline hydroxyapatite (NcHA) alone or with PRF in split-mouth study design, the results showed that the clinical advantages of NcHA bone graft in combination with PRF were superior to those of the NcHA alone [25], [26], [27].

In the present investigation, using PRF + Nano-HA as one of the treatment modalities in induced intrabony defects didn't show significant bone formation compared to the control group whereas there were significant differences in bone density between after 15 and 30 days compared to baseline ( $p = 0.000$ ,  $p = 0.000$ ). This agrees with Elgendy [2015] et al. study [26].

LLLT alone showed increased mitochondrial activity, synthesis of DNA / RNA in osteoblasts, cell viability, and alkaline phosphatase [16]. A recent experimental study showed that in the early stages of bone healing, LLLT had a positive local biostimulative effect [28].

The results of the current study didn't show statistical-significant improvements in bone healing after LLLT alone compared to the control group, whereas there were significant differences in bone density between 15 and 30 days of healing compared to baseline. ( $p = 0.000$ ,  $p = 0.000$  respectively).

In large bone defects, LLLT has been used to accelerate healing [29]. Stimulating osteogenesis [30] is considered a non-invasive, safe technique.

In the present investigation, the combined use of PRF+Nano-HA+Laser as one of the treatment modalities for induced intrabony surgical defects showed a statistically significant increase in a bone density greater than in the control group after 15&30 days ( $p = 0.002$  and  $0.004$  respectively). And there were significant differences in bone density between 15<sup>th</sup> day compared to baseline, 30<sup>th</sup> day compared to baseline and 30<sup>th</sup> day compared to 15<sup>th</sup> day ( $p = 0.000$ ,  $p = 0.000$  and  $p = 0.026$  respectively).

Bone healing is a complex process comprising prolonged inflammation, bone formation, and bone remodelling processes. The mechanism of action of LLLT, bone substitute, and PRF are different in accelerating the process of bone healing. LLLT and PRF and NanoHA's synergic effect could be superior to their separate use.

No study has assessed this possible synergistic effect to date. The combined effect of LLLT with PRF and NanoHA graft as a method of treatment in intrabony surgical defects in this experiment showed the highest amount of bone formation with the best quality of the newly formed bone. Radiographical examination and statistical analysis confirmed the superiority of the bioactive combination of surgical

additive PRF+NanoHA+LLLT in periodontal intrabony defect repair.

Within the limitation of this experimental study, the following could be concluded; the use of PRF+NanoHA mix results in an increase in bone fill and density regarding the radiographical outcomes in induced periodontal intrabony defects in rabbits, and LLLT may improve the effects of this mix significantly.

## References

- Papapanou PN, Sanz M, Buduneli N, et al. Periodontitis: Consensus report of workgroup 2 of the 2017 World Workshop on the Classification of Periodontal and Peri-Implant Diseases and Conditions. *J Clin Periodontol.* 2018; 45(December 2017):S162-S170. <https://doi.org/10.1111/jcpe.12946> PMID:29926490
- Chandran P, Sivadas A. Platelet-rich fibrin : Its role in periodontal regeneration. *Saudi J Dent Res.* 2014; 5(2):117-122. <https://doi.org/10.1016/j.ksuids.2013.09.001>
- G. Caton J, Armitage G, Berglundh T, et al. A new classification scheme for periodontal and peri-implant diseases and conditions - Introduction and key changes from the 1999 classification. *J Clin Periodontol.* 2018; 45(March):S1-S8. <https://doi.org/10.1111/jcpe.12935> PMID:29926489
- Needleman I, Garcia R, Gkraniias N, et al. Mean annual attachment, bone level, and tooth loss: A systematic review. *J Clin Periodontol.* 2018; 45(May 2017):S112-S129. <https://doi.org/10.1111/jcpe.12943> PMID:29926483
- Siali M, Chatzopoulou D, Gillam DG. An overview of periodontal regenerative procedures for the general dental practitioner. *Saudi Dent J.* 2018; 30(1):26-37. <https://doi.org/10.1016/j.sdentj.2017.11.001> PMID:30166868 PMCid:PMC6112342
- Trombelli L. Which reconstructive procedures are effective for treating the periodontal intraosseous defect? *Periodontol.* 2005; 37(1):88-105. <https://doi.org/10.1111/j.1600-0757.2004.03798.x> PMID:15655027
- Regeneration P. *Academy Report.* 2005;(September):1601-1622.
- Needleman I, Tucker R, Giedrys - Leeper E, Worthington H. Guided tissue regeneration for periodontal intrabony defects - a Cochrane Systematic Review. *Periodontol.* 2005; 37(1):106-123. <https://doi.org/10.1111/j.1600-0757.2004.37101.x> PMID:15655028
- Klement W, Willens R, Duwez P. © 1960 Nature Publishing Group. *Nat No* 4740. 1960; 187:896-870. <https://doi.org/10.1038/187869b0>
- Elavarasu S, Naveen D, Thangavelu A. Lasers in periodontics. *J Pharm Bioallied Sci.* 2012. <https://doi.org/10.4103/0975-7406.100245> PMID:23066266 PMCid:PMC3467892
- Smith KC. Laser (and LED) Therapy Is Phototherapy. *Photomed Laser Surg.* 2005; 23(1):78-80. <https://doi.org/10.1089/pho.2005.23.78> PMID:15782040
- Vladimirov YA, Osipov AN, Klebanov GI. Photobiological Principles of Therapeutic Applications of Laser Radiation. *Biochem.* 2004; 69(1):81-90. <https://doi.org/10.1023/B:BIRY.0000016356.93968.7e>
- Walsh LJ. The current status of low level laser therapy in dentistry. Part 1 . Soft tissue applications. 1997;(4). <https://doi.org/10.1111/j.1834-7819.1997.tb00129.x> PMID:9316312
- Walsh LJ. The current status of low level laser therapy in dentistry . Part 2 . Hard tissue applications. 1997;(5).

- <https://doi.org/10.1111/j.1834-7819.1997.tb00134.x> PMID:9409045
15. Anna Mathew P, More V, B.S JP. Lasers - It's Role in Periodontal Regeneration. *Heal Informatics - An Int J*. 2018; 7(2/3/4):01-07. <https://doi.org/10.5121/hij.2018.7401>
  16. Huang Y-Y, Sharma SK, Carroll J, Hamblin MR. Biphasic Dose Response in Low Level Light Therapy - an Update. *Dose-Response*. 2011; 9(4):dose-response. <https://doi.org/10.2203/dose-response.11-009.Hamblin> PMID:22461763 PMCid:PMC3315174
  17. Struillou X, Boutigny H, Soueidan A, Layrolle P. Experimental Animal Models in Periodontology: A Review. *Open Dent J*. 2010; 4(1):37-47. <https://doi.org/10.2174/1874210601004010037> PMID:20556202 PMCid:PMC2885595
  18. Kim C-S, Kim C-K, Wikesjö UME, et al. Periodontal Repair in Surgically Created Intrabony Defects in Dogs: Influence of the Number of Bone Walls on Healing Response. *J Periodontol*. 2005; 75(2):229-235. <https://doi.org/10.1902/jop.2004.75.2.229> PMID:15068110
  19. Sculean A, Nikolidakis D, Schwarz F. Regeneration of periodontal tissues: Combinations of barrier membranes and grafting materials - Biological foundation and preclinical evidence: A systematic review. *J Clin Periodontol*. 2008; 35(SUPPL. 8):106-116. <https://doi.org/10.1111/j.1600-051X.2008.01263.x> PMID:18724845
  20. Sculean A, Nikolidakis D, Nikou G, Ivanovic A, Chapple ILC, Stavropoulos A. Biomaterials for promoting periodontal regeneration in human intrabony defects: A systematic review. *Periodontol 2000*. 2015. <https://doi.org/10.1111/prd.12086> PMID:25867987
  21. Preeja C, Arun S. Platelet-rich fibrin: Its role in periodontal regeneration. *Saudi J Dent Res*. 2014. <https://doi.org/10.1016/j.ksujds.2013.09.001>
  22. Tsai CH, Shen SY, Zhao JH, Chang YC. Platelet-rich fibrin modulates cell proliferation of human periodontally related cells in vitro. *J Dent Sci*. 2009; 4(3):130-135. [https://doi.org/10.1016/S1991-7902\(09\)60018-0](https://doi.org/10.1016/S1991-7902(09)60018-0)
  23. Li Q, Pan S, Dangaria SJ, et al. Platelet-Rich Fibrin Promotes Periodontal Regeneration and Enhances Alveolar Bone Augmentation. *Biomed Res Int*. 2013; 2013:1-13. <https://doi.org/10.1155/2013/729413> PMID:24319687
  24. Pripatnanont P, Nuntanarant T, Vongvatcharanon S, Phurisat K. The primacy of platelet-rich fibrin on bone regeneration of various grafts in rabbit's calvarial defects. *J Cranio-Maxillofacial Surg*. 2013; 41(8):e191-e200. <https://doi.org/10.1016/j.jcms.2013.01.018> PMID:23395296
  25. Singh V, Nayak D, Uppoor A, Shah D. Nano-crystalline hydroxyapatite bone graft combined with bioresorbable collagen membrane in the treatment of periodontal intrabony defects: A randomized controlled clinical trial. *J Indian Soc Periodontol*. 2013; 16(4):562. <https://doi.org/10.4103/0972-124X.106912> PMID:23493628 PMCid:PMC3590728
  26. Elgendy E, Abo Shady T. Clinical and radiographic evaluation of nanocrystalline hydroxyapatite with or without platelet-rich fibrin membrane in the treatment of periodontal intrabony defects. *J Indian Soc Periodontol*. 2015; 19(1):61. <https://doi.org/10.4103/0972-124X.148639> PMID:25810595 PMCid:PMC4365160
  27. Trombelli L, Farina R. Clinical outcomes with bioactive agents alone or in combination with grafting or guided tissue regeneration. *J Clin Periodontol*. 2008; 35(SUPPL. 8):117-135. <https://doi.org/10.1111/j.1600-051X.2008.01265.x> PMID:18724846
  28. Aboelsaad NS, Soory M, Gadalla LMA, et al. Effect of soft laser and bioactive glass on bone regeneration in the treatment of bone defects (an experimental study). *Lasers Med Sci*. 2009; 24(4):527-533. <https://doi.org/10.1007/s10103-008-0590-y> PMID:18626570
  29. Zhang JC, Lu HY, Lv GY, Yan ACMG, The CH. The repair of critical-size defects with porous hydroxyapatite / polyamide nanocomposite : an experimental study in rabbit mandibles. *Int J Oral Maxillofac Surg*. 2010; 39(5):469-477. <https://doi.org/10.1016/j.ijom.2010.01.013> PMID:20194003
  30. Garcia VG, Fernandes LA, De Almeida JM, et al. Comparison between laser therapy and non-surgical therapy for periodontitis in rats treated with dexamethasone. *Lasers Med Sci*. 2010; 25(2):197-206. <https://doi.org/10.1007/s10103-009-0678-z> PMID:19440786