



# Treatment of Distal Radio Vicious Consolidation: Corrective Osteotomy Through 3D Printing Prototyping\*

## *Tratamento da consolidação viciosa do rádio distal: Osteotomia corretiva mediante planejamento com prototipagem em impressão 3D*

João Carlos Belloti<sup>1</sup> Bernardo Vaz Peres Alves<sup>1</sup> Nicola Archetti<sup>1</sup> Luis Renato Nakachima<sup>1</sup>   
Flavio Faloppa<sup>1</sup> Marcel Jun Sugawara Tamaoki<sup>1</sup>

<sup>1</sup> Hand Surgery Discipline, Orthopedics and Traumatology Department, Escola Paulista de Medicina, Universidade Federal de São Paulo, São Paulo, SP, Brazil  
Rev Bras Ortop 2021;56(3):384–389.

Address for correspondence João Carlos Belloti, Hand Surgery Discipline, Orthopedics and Traumatology Department, Rua Borges Lagoa, 786, Vila Clementino, São Paulo, SP, 04038-002, Brazil (e-mail: jcbelloti@gmail.com).

### Abstract

#### Keywords

- ▶ radial deformity
- ▶ radial fractures complications
- ▶ x-ray tomography
- ▶ three-dimensional printing

### Resumo

#### Palavras-chave

- ▶ deformidade do rádio
- ▶ complicações fraturas do rádio
- ▶ tomografia por raios x
- ▶ impressão tridimensional

Distal radial fractures are very common. Vicious consolidation can occur in up to one third of these fractures, resulting in wrist pain, restricted movement, and, eventually, physical limitation or disability. The treatment of this condition consists in corrective osteotomy, which requires careful preoperative planning due to its three-dimensional complexity, especially in injuries with joint involvement. Recently, prototyping based on three-dimensional (3D) reconstruction of computed tomography (CT) scans has been used for osteotomy planning in a 3D anatomical model. It allows a better understanding of the deformity in a realistic surgical approach, leading to safer, faster, and more predictable procedures. The aim of the present study is to present this technique and show its use in two clinical cases.

As fraturas da porção distal do rádio estão entre as mais comuns do esqueleto. A consolidação viciosa pode ocorrer em até um terço dessas fraturas e acarretar restrição de movimento e dor no punho, com conseqüente limitação ou incapacidade laboral. O tratamento desta condição implica em osteotomia corretiva das deformidades, o que necessita de um planejamento pré-operatório criterioso em virtude de sua complexidade tridimensional, notadamente naquelas em que há acometimento articular. Assim, recentemente, tem sido utilizada a prototipagem a partir da reconstrução 3D da tomografia computadorizada (TC), o que permite o planejamento com realização da osteotomia em modelo anatômico tridimensional, com o melhor

\* The present study was performed by the Hand and Upper Limb Surgery group, Departamento de Ortopedia e Traumatologia, Escola Paulista de Medicina, Universidade Federal de São Paulo, São Paulo, Brazil.

received  
April 26, 2020  
accepted  
July 6, 2020  
published online  
December 18, 2020

DOI <https://doi.org/10.1055/s-0040-1718510>  
ISSN 0102-3616.

© 2020. Sociedade Brasileira de Ortopedia e Traumatologia. All rights reserved.

This is an open access article published by Thieme under the terms of the Creative Commons Attribution-NonDerivative-NonCommercial-License, permitting copying and reproduction so long as the original work is given appropriate credit. Contents may not be used for commercial purposes, or adapted, remixed, transformed or built upon. (<https://creativecommons.org/licenses/by-nc-nd/4.0/>)

Thieme Revinter Publicações Ltda., Rua do Matoso 170, Rio de Janeiro, RJ, CEP 20270-135, Brazil

entendimento da deformidade, aproximando-se da situação realística da cirurgia, o que torna o procedimento mais seguro, ágil e previsível. O objetivo do presente estudo é apresentar esta técnica e seu emprego em dois casos clínicos.

## Introduction

Distal radial fractures are very common, accounting for up to 75% of forearm fractures.<sup>1</sup> Their distribution is bimodal, affecting mostly young men subjected to high-energy trauma, or patients > 65 years old, predominantly females, with bone fragility-osteopenia who suffered low-energy trauma.<sup>1,2</sup> An epidemiological study carried out from 1999 to 2010 in Sweden, with a population of 11.2 million inhabitants, revealed an incidence of 278 distal radial fractures for every 100,000 people, with a gender ratio of three women per man.<sup>2</sup> Correspondingly, the city of São Paulo, Brazil, with a population of 12.2 million inhabitants, would have > 41,000 fractures in the same period; considering that up to 33% of these fractures evolve with vicious consolidation,<sup>3,4</sup> approximately 13,000 patients would be affected. These figures demonstrate the importance of studies promoting the prevention and treatment of this clinical condition.

There is still no consensus on the best way to treat distal radial fractures<sup>3</sup> Despite constant developments in surgical techniques and implants, complications still occur; the most common include posttraumatic arthrosis, tendon rupture, median nerve compression, and vicious consolidation.<sup>3,4</sup> Vicious consolidation can occur in up to 33% of cases,<sup>4</sup> mostly after nonsurgical treatment.

Vicious distal radial consolidation can lead to a range of functional and painful limitations depending on the deformity type. Angular deformities result in an abnormal compensatory movement in the midcarpal joint that causes wrist instability followed by pain, limited movement, and degenerative arthrosis. Radial shortening deformities can lead to ulnocarpal impingement and instability of the distal radioulnar joint. Joint step deformities are highly probable of evolving with degenerative wrist changes. Knirk et al.<sup>5</sup> assessed functional outcomes from distal radial treatment in young adults and found out that joint congruence was a critical factor for success. Post-traumatic arthrosis occurred in 11% of patients with no joint step deformities, compared to 91% subjects with non-congruent joints.<sup>5</sup> These changes resulted in functional limitations that can lead to permanent work disability.

Corrective osteotomies for vicious distal radial consolidation aim to recover the normal bone anatomy for functional improvement and pain relief; in addition, these procedures prevent the progression of degenerative changes at the wrist joint. Since vicious consolidation presentations are widely variable, there are many corrective osteotomy techniques, but the common point for their indication is the presence of pain and functional limitation in patients with no advanced radiocarpal arthrosis. Surgical correction has a significant clinical benefit.<sup>6</sup>

Clinical and radiological analysis are critical for the good outcome of deformity correction. In addition to posteroanterior and true lateral radiographic views of both the affected and contralateral wrist, the use of computed tomography (CT) is essential to assess joint impairment and improve surgical planning, especially in vicious consolidations with joint involvement.<sup>7</sup>

Recently, CT with three-dimensional (3D) reconstruction has been used for prototyping in a 3D model using polylactic acid (PLA). It allows for a better understanding of the deformity, and it has great value for surgical planning.<sup>6,7</sup> Careful planning prior to the surgical procedure, in a 3D model with the actual dimensions from the patient, allows the surgeon to validate the type of implant to be used and to predict procedural steps and strategies. This approach reduces surgical time, improves implant selection and placement, and validates the exact location and direction of the osteotomy required for deformity correction.<sup>7,8</sup> About 2 years ago, a prototyping laboratory with 3D printing resources was implemented with the support from the São Paulo Research Foundation (*Fundação de Amparo à Pesquisa do Estado de São Paulo* [FAPESP, in the Portuguese acronym]), allowing us to start the development of studies using the technique described below.

## Indications and Contraindications

Preoperative planning using 3D printing in a prototyped model (PLA) of distal radial vicious consolidation is recommended for all corrective surgeries due to the complex anatomical distortion related to this clinical condition. This strategy allows for a better 3D understanding and real correction in patients who present anatomical deformity and significant functional limitation.

Corrective osteotomies for distal radial vicious consolidation are contraindicated in patients with low demand for daily activities, mild anatomical deformity, little functional restriction, long-standing injury, or radiocarpal degenerative osteoarthritis. Thus, in deformities with sustained articular or extra-articular incongruence, we recommend a more specific assessment of the degree of joint cartilage degeneration using nuclear magnetic resonance or wrist arthroscopy; correction with osteotomy is contraindicated if severe joint degeneration is present.

## Preoperative Technique

Bilateral CT scans of the wrists must be performed in 1 mm-thickness sections. The file is generated in Digital Imaging and Communications in Medicine (DICOM) format and standardization and then imported into a 3D medical image processing and reconstruction software (InVesalius version

3.1.1, Centro de Tecnologia da Informação Renato Archer, Campinas, SP, Brazil). This 3D model of the distal radio is exported as a Standart Tessellation Language/Stereo-Lithography (STL) file and the Simplify3D software (Simplify3D: Cincinnati, Ohio, USA) translates the information from the .stl file into instructions for the 3D printer. The material for 3D printing is PLA.

The corrective osteotomy was planned after preparing prototypes from the deformed distal radius and the normal contralateral bone. Plate positioning, screw length, and osteotomy location must be evaluated using C-arm fluoroscopy for proper selection of surgical materials.

Surgical programming with 3D reconstruction and PLA model prototyping allows the surgeon to better understand the deformity, plan the exact osteotomy location under real perspective and determine the best type of implants and their specifications. As such, it anticipates and optimizes surgical stages, resulting in a safer, faster, more predictable deformity correction. This research project was analyzed and approved by the ethics committee under the number 9253251119.

### Selected Cases

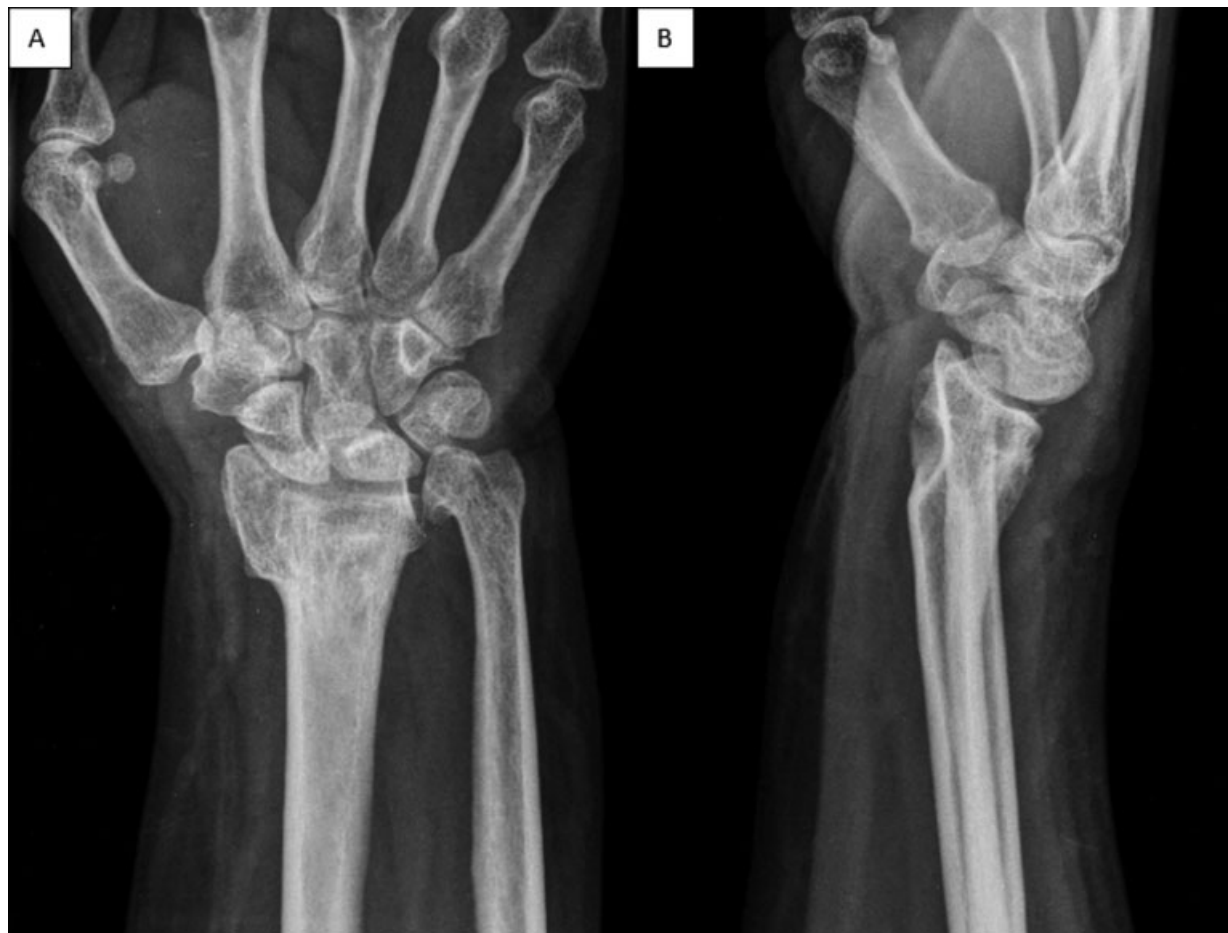Case 1—Female patient, 46 years old, with sequelae from a left distal radial fracture. This injury occurred 4 years ago,

when it was treated with plastered immobilization. She presents pain and limited flexion at the left wrist. Posteroanterior and true lateral radiographies of the left wrist show vicious consolidation (►Figure 1). Bilateral distal radius prototyping based on CT scans with 3D reconstruction improved deformity understanding and surgical planning (►Figure 2).

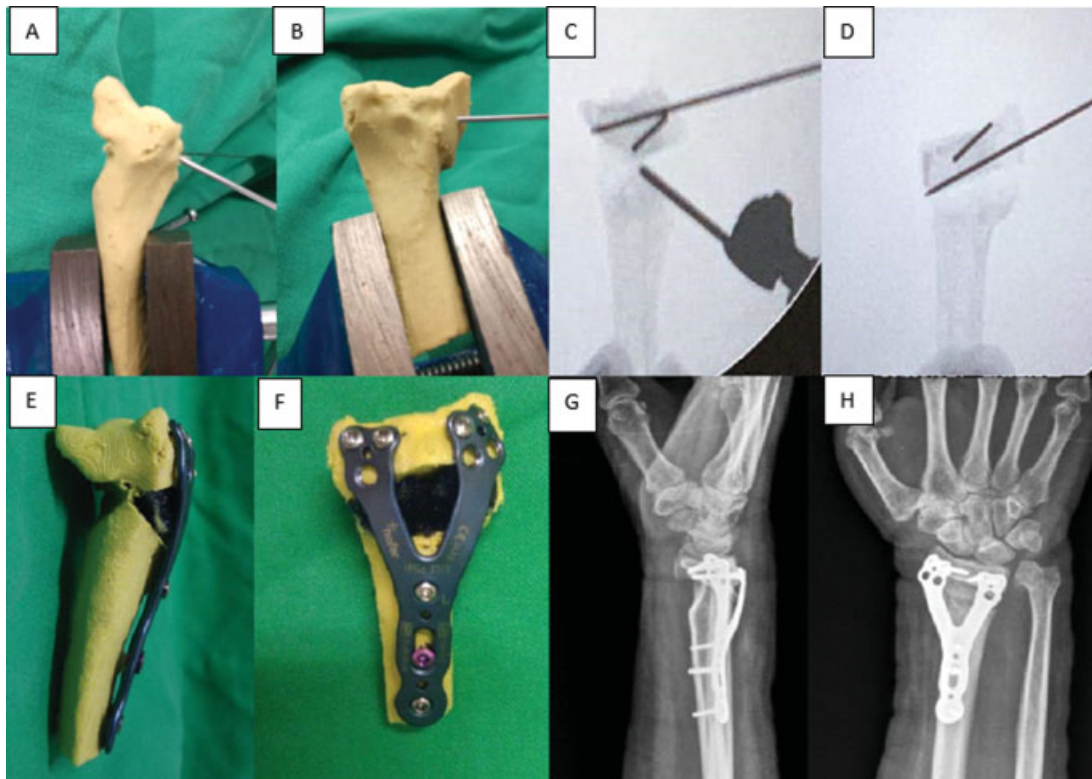
Case 2—Male patient, 47 years old. The subject presented a distal fracture at the right radius 4 months ago, which was submitted to nonsurgical treatment. Wrist radiographs show vicious consolidation with loss of volar inclination and widening of the joint surface of the distal radius with radiocarpal joint step (►Figure 3). As in the previous case, a PLA model from both distal radial bones of the patient was printed and used to outline the osteotomy point and deformity correction. (►Figures 4 and 5).

### Discussion

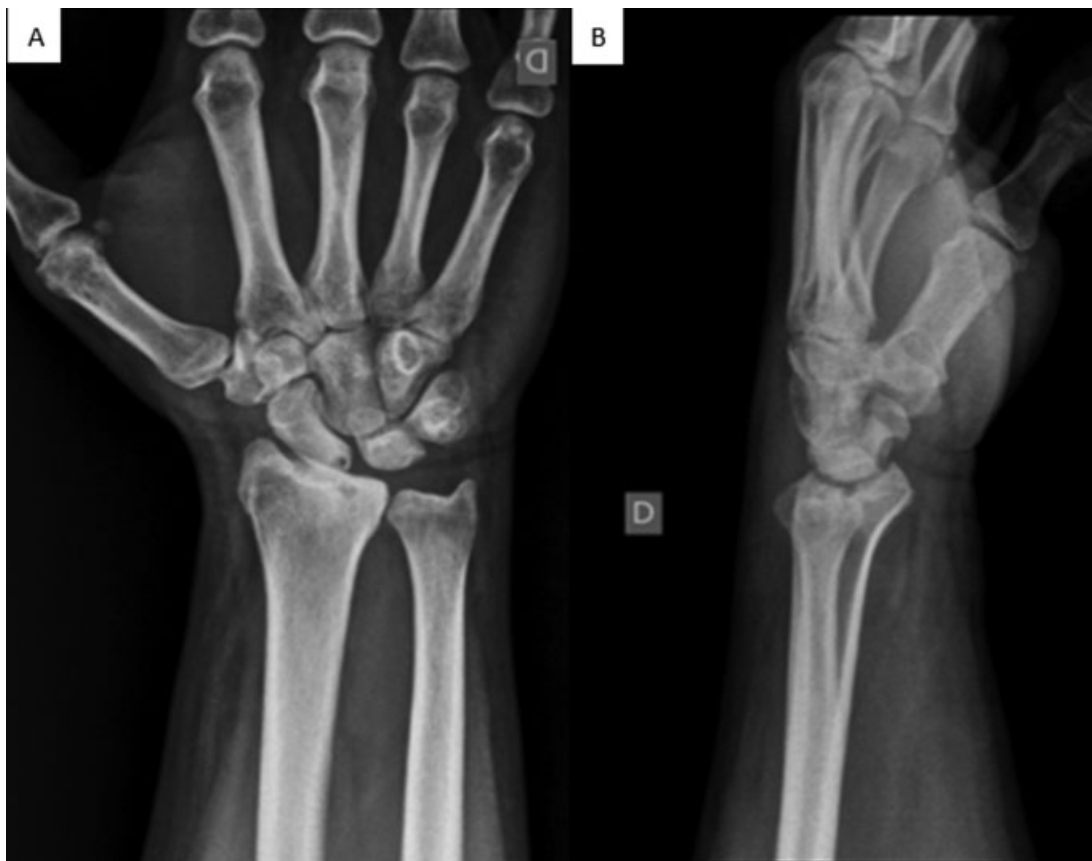In the early 1980s, Charles Hull developed and conceptualized 3D printing, allowing the creation of objects based on material deposition layer by layer. Since then, 3D printing advanced and models present better resolution, faster production, and lower cost; in addition, there is a greater variety of materials for printing.<sup>7</sup>



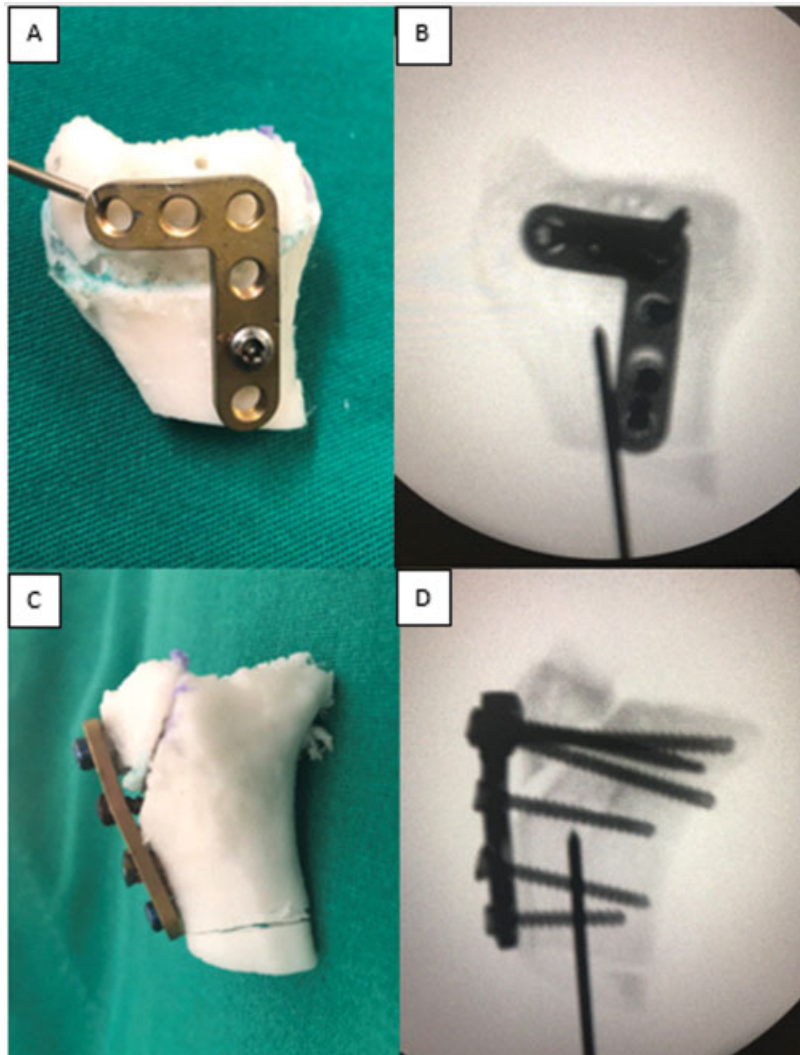
**Fig. 1** Posteroanterior (A) and true lateral (B) radiographies of the left wrist showing vicious consolidation with dorsal deviation, radial shortening, ulnar head deformity, and adaptive carpal instability.



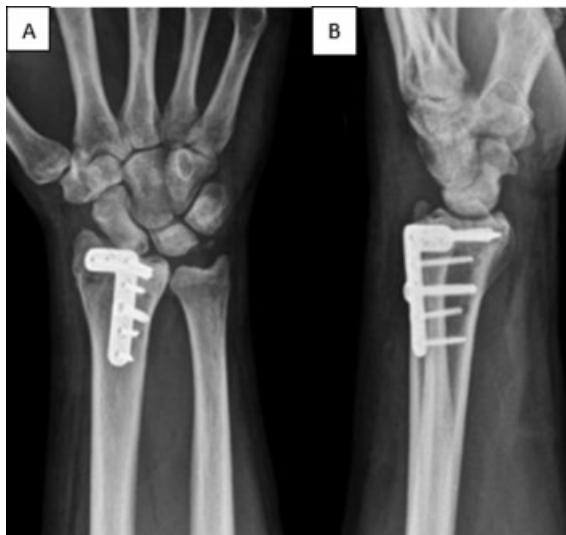**Fig. 2** Planning and surgery with prototyping in a PLA model: guidewires placement for osteotomy in model (A, B) and fluoroscopic control of model osteotomy (C, D), prototyping after corrective osteotomy and dorsal plate fixation (E, F). Postoperative follow-up radiographies (G, H).



**Fig. 3** Posteroanterior (A) and lateral (B) radiographies of the distal portion of the right radius showing vicious consolidation with radiocarpal joint step and loss of normal radial volar tilt.



**Fig. 4** Dorsal view: planning of the corrective articular osteotomy of the distal portion of the right radius in a printed model (A), and fluoroscopic image after locked dorsal plate fixation at the distal radius (B). Lateral view: articular osteotomy of the distal radius and locked dorsal plate fixation in a printed model (C), and fluoroscopic image with corrected radiographic parameters (D).



**Fig. 5** Posteroanterior (A) and lateral (B) radiographies 4 weeks after surgery. Joint step reduction and enlargement of the radial articular surface as performed during the preoperative planning in a PLA model.

The use of 3D prototyping in orthopedic surgery allows for a better 3D understanding of the fracture or its vicious consolidation. Visualization and manipulation of models, which are true to the patient's anatomy, help surgical programming and intraoperative decision making.

### Final Considerations

In cases of vicious consolidation of the distal portion of the radius, printing a model based on the 3D reconstruction of CT scans helps the surgeon to select proper implants and determine the direction and location for corrective osteotomy. This preoperative planning saves surgical time, resulting in a lower rate of complications and in a more favorable functional outcome.

### Funding

This study was developed at the Prototyping with 3D Printing laboratory with resources funded by FAPESP as a regular project under the number 17/26283-0.

**Conflict of Interests**

The authors have no conflict of interests to declare.

**References**

- 1 Chung KC, Spilson SV. The frequency and epidemiology of hand and forearm fractures in the United States. *J Hand Surg Am* 2001; 26(05):908–915
- 2 Jerrhag D, Englund M, Karlsson MK, Rosengren BE. Epidemiology and time trends of distal forearm fractures in adults - a study of 11.2 million person-years in Sweden. *BMC Musculoskelet Disord* 2017;18(01):240
- 3 Belloti JC, Santos JBG, Atallah AN, Albertoni WM, Faloppa F. Fractures of the distal radius (Colles' fracture). *Sao Paulo Med J* 2007;125(03):132–138
- 4 Cole JM, Obletz BE. Comminuted fractures of the distal end of the radius treated by skeletal transfixation in plaster cast: an end-result study of thirty-three cases. *J Bone Joint Surg Am* 1966;48(05):931–945
- 5 Knirk JL, Jupiter JB. Intra-articular fractures of the distal end of the radius in young adults. *J Bone Joint Surg Am* 1986;68(05):647–659
- 6 Van Cauwelaert de Wyels J, De Smet L. Corrective osteotomy for malunion of the distal radius in young and middle-aged patients: an outcome study. *Chir Main* 2003;22(02):84–89
- 7 Stockmans F, Dezillie M, Vanhaecke J. Accuracy of 3D virtual planning of correlative osteotomies of the distal radius. *J Wrist Surg* 2013;2(04):306–314
- 8 Walenkamp MM, de Muinck Keizer RJ, Dobbe JG, et al. Computer-assisted 3D planned corrective osteotomies in eight malunited radius fractures. *Strateg Trauma Limb Reconstr* 2015;10(02):109–116