



Acute Exacerbation of Fever Following Administration of Tropicamide and Phenylephrine Ophthalmic Solution: A Case Report

Yuichiro Haba¹ · Takayoshi Shiga¹ · Toshio Naito¹

Published online: 12 February 2019
© The Author(s) 2019

Abstract

A 24-year-old woman with atopic dermatitis and persistent fever (axillary temperature of 37–38 °C for 6 months) received combination ophthalmic drops containing tropicamide and phenylephrine (Mydrin[®]-P), which exacerbated her fever within 15 min after instillation. Her axillary fever reached 40.1 °C but resolved the following day. No new dermatological symptoms developed. Although the patient's fever may have been caused by either tropicamide or phenylephrine, neither of which have been reported to induce fever in topical formulations, atopic dermatitis and tropicamide's inhibitory effect on perspiration under hot and humid conditions may have been the more probable cause. While drug-induced fever has been reported for other ophthalmic anticholinergic agents, this is the first reported case of possible fever exacerbation by an ophthalmic formulation of tropicamide, if the causative agent is assumed to be tropicamide.

Key Points

Tropicamide can cause acute fever via the same mechanism as that of atropine by inhibiting perspiration rather than inducing a hypersensitivity reaction.

Ophthalmic anticholinergic-induced fever tends to occur during the summer months because of health and environmental factors.

Introduction

Mydrin[®]-P (Santen Pharmaceutical Co., Ltd, Osaka, Japan) is a drug containing equal amounts of tropicamide 0.5%, which blocks the parasympathetic nervous system, and phenylephrine hydrochloride 0.5%, a sympathomimetic agent that selectively stimulates α_1 receptors. Mydrin[®]-P relaxes the sphincter pupillae muscles to achieve pupillary dilatation, and relaxes the ciliary muscles to achieve accommodation paresis. Because both tropicamide and phenylephrine have shorter durations of effect (5–6 h) than atropine (7–12 days), and the combination of tropicamide and

phenylephrine at a ratio of 1:1 can promptly induce maximal mydriasis with few systemic adverse effects, Mydrin[®]-P has been widely used in ophthalmic examinations for over half a century [1]. The most common adverse reactions associated with tropicamide are local complications such as conjunctivitis, blepharitis, and itching; however, a few systemic complications such as nausea, headache, shock, and anaphylaxis have also been reported [1–3]. Although the sympathetic nerve-stimulating effects of phenylephrine can raise blood pressure and alter heart rate [4], there have been no reports of fever induced by the administration of tropicamide alone, phenylephrine alone (containing systemic use), or a combination of tropicamide and phenylephrine. We herein report a case in which a patient's fever was exacerbated after instillation of Mydrin[®]-P. In this report, all body temperatures reported for our patient are axillary temperatures.

Case Presentation

A 24-year-old Japanese woman, with no use of medication and with no medical history except for that of untreated atopic dermatitis, was referred to our facility for chronic fever (approximately 37–38 °C) that had persisted for 6 months. She also had systemic superficial lymphadenitis, which was previously proven as dermatopathic lymphadenopathy based on biopsy results.

✉ Yuichiro Haba
yhaba@juntendo.ac.jp

¹ Juntendo University School of Medicine, Tokyo, Japan

The patient was hospitalized for further tests to determine the origin of her fever. Upon hospitalization, she was in a generally good state, with a body temperature, blood pressure, and heart rate of 36.7 °C, 108/54 mmHg, and 80 bpm, respectively. No liver or kidney dysfunction was observed. The course of her fever during hospitalization is shown in Fig. 1.

At 2.00 p.m. on day 3 after hospitalization, one drop of ophthalmic solution containing tropicamide and phenylephrine (Mydrin®-P) was administered in each eye to dilate the patient’s pupils for funduscopy. The patient did not have a previous history of using this medication. After 15 min, the patient complained of feeling hot, and 90 min after instillation her body temperature abruptly rose from 37.0 to 40.1 °C; however, her heart rate (approximately 90 bpm) indicated relative bradycardia, and her blood pressure had not markedly changed (Fig. 2). The patient was administered a single dose of acetaminophen (400 mg) followed by a single dose of loxoprofen (60 mg). Cold applications, such as the use of an ice pillow, were not utilized as the patient refused. The patient’s fever gradually broke; after approximately 24 h, the patient’s body temperature returned to approximately 37.0 °C (Fig. 2). No noteworthy changes were observed in subsequent laboratory findings, and her blood culture test results were negative. Because the patient had severe general atopic dermatitis, marked eosinophilia

(2205/μL; 24% white blood cells), and elevated immunoglobulin E levels (28,542 IU/μL), an allergic reaction was suspected at the time. However, a drug lymphocyte stimulation test performed 3 days after the onset of fever was negative for tropicamide and phenylephrine.

Over the patient’s 12-day hospital stay, blood and urine tests, bone marrow aspiration, gallium scintigraphy, whole-body contrast-enhanced computed tomography, positron emission tomography, three blood culture examinations, echocardiography, and funduscopy were performed; however, the cause of persistent low-grade fever could not be identified.

Discussion

In general, up to 80% of ophthalmic drop components can enter the systemic circulation to cause systemic reactions [5]. Mydriatic and cycloplegic agents such as atropine and scopolamine, with anticholinergic effects similar to those of tropicamide, are known to cause systemic adverse reactions that include lethargy, confusion, hallucinations, headache, facial flushing, and fever [3, 6, 7]. When atropine is administered as anesthetic premedication, it suppresses the activity of sweat glands, which are innervated by sympathetic nerves that utilize the neurotransmitter acetylcholine, resulting

Fig. 1 Course of fever during hospitalization

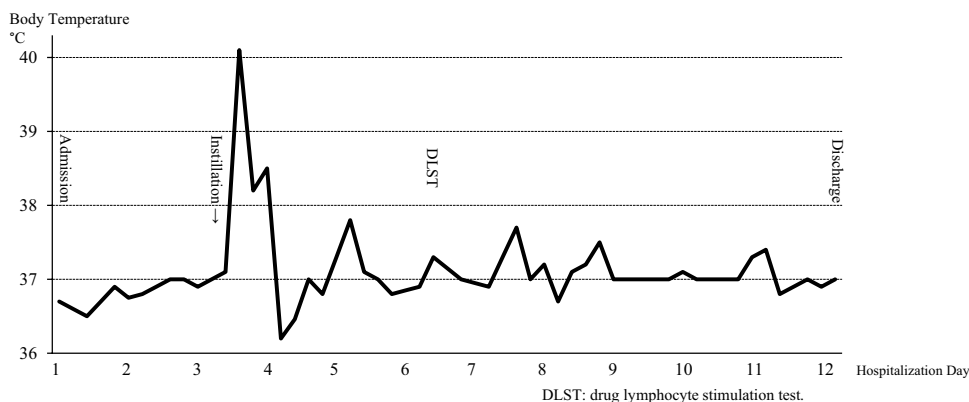
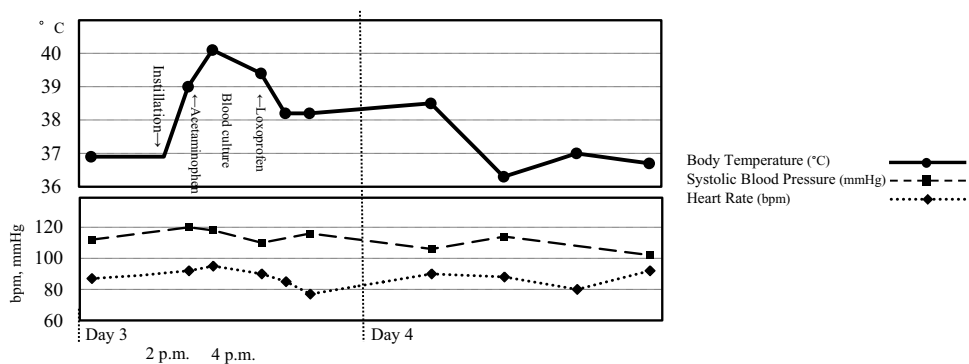


Fig. 2 Fever, heart rate, and systolic blood pressure from days 3–4



in heat retention. This phenomenon often develops into a high fever known as ‘atropine fever’ [8, 9]. The frequency of ophthalmic atropine drop-induced fever in children has been reported at 1.3% (2/160) [7], 3.9% (32/811) [10], 4.0% (13/326) [11], and 72.7% (48/66) [12].

Rewari and Trikha [8] reported that on the Indian subcontinent, fever in children induced by ophthalmic formulations of atropine occur more frequently during the hot summer months, while Toyama et al. [11] noted that in Japan, ophthalmic atropine drop-induced fever in infants commonly occurs between April and September, with the highest frequency in July. Furthermore, Garg and Sinha [12] reported that in several children (6/66) in New Delhi, India, fever reached > 40 °C (no method of measurement was reported). Whereas the above reports [7, 8, 10–12] lacked detailed environmental descriptions, Magbagbeola [13] reported that in Ibadan, Nigeria, 58.5% (117/200) of children administered intramuscular injections of atropine as premedication for surgery had increased body temperature; the hospital ward had no air conditioning, an ambient temperature of 28.74 ± 0.13 °C, and a mean relative humidity of $71.59 \pm 0.54\%$. That is to say, hot weather may be one of the risk factors for this type of hyperthermia.

Patients with atopic dermatitis often experience hypohidrosis and delayed perspiration [14, 15]. It is also known that some patients with atopic dermatitis suffer from heat retention because of the lack of adequate perspiration. Our patient was hospitalized during early summer (late June). Although the hospital was air-conditioned at 3.00 p.m. on the day of ophthalmic drug instillation, our patient’s ward was hot and humid (27.2 °C and 68% humidity) because of the relatively sultry outdoor weather. We hypothesize that the hot and humid environment and inadequate perspiration due to atopic dermatitis may have contributed to the medication’s anticholinergic effect on perspiratory glands, leading to acute exacerbation of the patient’s fever.

Fever devoid of other signs, occurring immediately after administration of a drug, usually suggests drug-induced fever [16]. Generally, drug-induced fever classified as a hypersensitivity reaction (the most prominent category) develops 3–14 days after the start of administration, with most occurring after 7–10 days [17]. In the present case, the onset of fever was rapid (within 15 min after administration) and coincided with the time at which both tropicamide and phenylephrine normally induce maximum pupillary dilatation (15–45 min) [18]. As there were no other symptoms (i.e. no dermal effects, changes in laboratory data, cardiopalmus, or paroxysmal hypertension), hypersensitivity to these agents was considered unlikely. Although possible, phenylephrine was not strongly suspected because systemic phenylephrine tends to induce bradycardia and hypertension, which the patient did not have, suggesting that the muscarinic blocking activity of tropicamide, rather than α_1

receptor stimulation by phenylephrine, was the more valid cause of our patient’s drug-induced fever.

Drug-induced fever has not been reported for either tropicamide or phenylephrine, but the reason for this is unclear. We hypothesize the following: (1) drug-induced fever is simply underreported; (2) the duration of action of tropicamide and phenylephrine is extremely short compared with that of other mydriatic drops, reducing the risk of systemic reactions; and (3) topical tropicamide, when not combined with other drugs, is used for testing purposes only (it is never used routinely, and therefore its adverse effects are not often encountered).

Conclusion

Drug-induced fever may have been more frequent, contrary to our thoughts. When unexpected fever erupts during the administration of anticholinergic agents, environmental factors and individual predispositions should be considered. Although phenylephrine is a potential source of acute fever, ocularly applied tropicamide was the more probable cause of the patient’s condition. Clinicians should be careful in using tropicamide, as well as atropine, especially during the summer months.

Compliance with Ethical Standards

Conflict of Interest Yuichiro Haba, Takayoshi Shiga, and Toshio Naito have no conflicts of interest that are directly relevant to the contents of this case report.

Patient Consent Written informed consent was obtained from the patient prior to publication of this case report. A copy of the written consent may be requested for review from the corresponding author upon reasonable request.

Funding No sources of funding were used to assist in the preparation of this case report.

Open Access This article is distributed under the terms of the Creative Commons Attribution-NonCommercial 4.0 International License (<http://creativecommons.org/licenses/by-nc/4.0/>), which permits any noncommercial use, distribution, and reproduction in any medium, provided you give appropriate credit to the original author(s) and the source, provide a link to the Creative Commons license, and indicate if changes were made.

References

1. Pharmaceutical interview form Mydrin®-P ophthalmic solution (11th edition, July 2017). Santen Co., Ltd, Osaka, Japan [in Japanese]. <http://image.packageinsert.jp/pdf.php?mode=1&yjcode=1319810Q1053>. Accessed 24 Nov 2018.

2. Hamasaki I, Hasebe S, Kimura S, et al. Cycloplegic effect of 0.5% tropicamide and 0.5% phenylephrine mixed eye drops: objective assessment in Japanese schoolchildren with myopia. *Jpn J Ophthalmol.* 2007;51(2):111–5.
3. Rengstorff RH, Doughty CB. Mydriatic and cycloplegic drugs: a review of ocular and systemic complications. *Am J Optom Physiol Opt.* 1982;59(2):162–77.
4. Sbaraglia F, Mores N, Garra R, et al. Phenylephrine eye drops in pediatric patients undergoing ophthalmic surgery: incidence, presentation, and management of complications during general anesthesia. *Paediatr Anaesth.* 2014;24(4):400–5.
5. Labetoulle M, Frau E, Jeunne CL. Systemic adverse effects of topical ocular treatments. *Presse Med.* 2005;34(8):589–95.
6. The Pediatric Eye Disease Investigating Group. A randomized trial of atropine vs patching for treatment of moderate amblyopia in children. *Arch Ophthalmol.* 2002;120(3):268–78.
7. Repka MX, Cotter SA, Beck RW, et al. A randomized trial of atropine regimens for treatment of moderate amblyopia in children. *Ophthalmology.* 2004;111(11):2076–85.
8. Rewari V, Trikha A. Atropine fever—an anesthetic dilemma. *Paediatr Anaesth.* 2007;17(9):901.
9. Osaki M, Negishi C, Atarashi K, et al. Atropine increases the sweating threshold in human volunteers [text in Japanese, abstract in English]. *Anesth Resus.* 1996;32(Suppl 34):13–5.
10. Wakayama A, Nishina S, Miki A, et al. Incidence of side effects of topical atropine sulfate and cyclopentolate hydrochloride for cycloplegia in Japanese children: a multicenter study. *Jpn J Ophthalmol.* 2018;62(5):531–6.
11. Toyama E, Seki Y, Takahashi R, et al. Incidence and symptoms of atropine side effect in children [text in Japanese, abstract in English]. *J Jpn Asso Certified Orthoptists.* 2014;43:213–8.
12. Garg R, Sinha R. Preoperative atropine treatment and fever in children. *Anaesth Intensive Care.* 2008;36(4):619.
13. Magbagbeola JA. The effect of atropine premedication on body temperature of children in the tropics. *Br J Anaesth.* 1973;45(11):1139–42.
14. Shimoda-Komatsu Y, Sato Y, Yamazaki Y, et al. A novel method to assess the potential role of sweating abnormalities in the pathogenesis of atopic dermatitis. *Exp Dermatol.* 2018;27(4):386–92.
15. Matsui S, Murota H, Takahashi A, et al. Dynamic analysis of histamine-mediated attenuation of acetylcholine-induced sweating via GSK3 β activation. *J Invest Dermatol.* 2014;134(2):326–34.
16. Mackowiak PA, LeMaistre CF. Drug fever: a critical appraisal of conventional concepts. An analysis of 51 episodes in two Dallas hospitals and 97 episodes reported in the English literature. *Ann Intern Med.* 1987;106(5):728–33.
17. Patel RA, Gallagher JC. Drug fever. *Pharmacotherapy.* 2010;30(1):57–69.
18. Moisseiev E, Loberman D, Zunz E, et al. Pupil dilation using drops vs gel: a comparative study. *Eye (Lond).* 2015;29(6):815–9.