



Correlation between clinical severity and type and degree of pectus excavatum in twelve brachycephalic dogs

Elham A. HASSAN^{1)*}, Marwa H. HASSAN¹⁾ and Faisal A. TORAD¹⁾

¹⁾Department of Surgery, Anesthesiology and Radiology, Faculty of Veterinary Medicine, Cairo University, Giza Square P.O. 12211, Giza, Egypt

ABSTRACT. The aim of the study was to correlate the clinical severity of pectus excavatum with its type and degree based on objective radiographic evaluation. Twelve brachycephalic dogs were included. Grading of the clinical severity was done based on a 6-point grading score. Thoracic radiographs were used to calculate the frontosagittal and vertebral indices at the tenth thoracic vertebra and the vertebra overlying the excavatum. Correlation between the clinical severity score and frontosagittal and vertebral indices was evaluated using Pearson's correlation coefficient. Typical pectus excavatum was recorded in the caudal sternum in seven dogs, with a mean clinical severity score of 1.7 ± 1.4 , whereas in five dogs, atypical mid-sternal deviation was recorded with a mean clinical severity score of 3.8 ± 0.7 . A strong correlation ($r=0.7$) was recorded between the clinical severity score and vertebral index in the atypical form, whereas a weak correlation ($r=0.02$) was recorded in the typical form ($P<0.05$). The clinical severity and degree of pectus excavatum was poorly correlated ($r=0.3$) in the typical form of pectus excavatum, whereas it was strongly correlated ($r=0.9$) in the atypical form. Pectus excavatum in dogs is associated with compressive cardiopulmonary dysfunction, which depends mainly on the site/type of deviation rather than the degree of deviation.

KEY WORDS: deviation, frontosagittal index, radiograph, sternum, vertebral index

J. Vet. Med. Sci.

80(5): 766–771, 2018

doi: 10.1292/jvms.17-0518

Received: 16 September 2017

Accepted: 7 March 2018

Published online in J-STAGE:

29 March 2018

Pectus excavatum (funnel chest; sunken chest) is the most commonly reported congenital skeletal deformity of the thoracic wall characterized by ventro-dorsal deviation of the sternum and associated costal cartilages [10, 12]. The condition is usually uncommon; however, several reports have been published describing the deformity in humans, dogs, and cats, as well as in non-domesticated animals [1, 3, 5, 8, 9, 11, 14, 17]. It typically occurs in the caudal part of the sternum [1, 3, 8, 9, 11, 14, 17]. A previous study reported two littermate Welsh terrier puppies with atypical deformities in the cranial portion of the sternum [5].

The incidence and gender predisposition are unclear. However, brachycephalic dogs are overrepresented. In a study that included eight dogs with pectus excavatum, 75% were brachycephalic [13]. Involvement of multiple dogs within the same litter suggests possible heritability [5, 8, 9, 14].

The exact cause of pectus excavatum is unclear; different theories have been proposed, including congenital diaphragmatic musculature defect, shortening of the central diaphragmatic tendon, failure of osteo-/chondrogenesis, and increased intrauterine pressure [8–10]. Acquired pectus excavatum has been reported secondary to upper airway disease, inspiratory dyspnea, and laryngeal paralysis [6, 11].

Diagnosis of pectus excavatum is mainly based on clinical and radiographic examinations [10, 12]. Compressive cardiopulmonary dysfunction including respiratory distress, dyspnea, cough, decreased appetite, weight loss, exercise intolerance, muffled heart sound, and cardiac murmur are the most common clinical signs [10].

Radiographic evaluation is used to objectively grade the degree of pectus excavatum by calculating the frontosagittal and vertebral indices [4, 10]. The frontosagittal index (FSI) is the ratio of the thoracic width at the 10th thoracic vertebra (T10) on ventro-dorsal radiograph and the distance from the ventral surface of T10 and the nearest point on the sternum, whereas the vertebral index (VI) is the ratio between the depth of the thorax measured at the center of the dorsal surface of T10 and the dorso-ventral diameter of T10 at the same level [8–10]. An increase in the FSI (reference range for brachycephalic dogs, 1 to 1.5) and a decrease in the VI (reference range for brachycephalic dogs, 12.5 to 16.5) are usually reported in pectus excavatum [10].

The correlation between the severity of clinical signs and degree of pectus excavatum in dogs is poorly understood. Many reports denied the correlation between the clinical severity and degree of pectus excavatum [10]. A recent study in kittens

*Correspondence to: Hassan, E. A.: elhamhassan@cu.edu.eg

©2018 The Japanese Society of Veterinary Science



This is an open-access article distributed under the terms of the Creative Commons Attribution Non-Commercial No Derivatives (by-nc-nd) License. (CC-BY-NC-ND 4.0: <https://creativecommons.org/licenses/by-nc-nd/4.0/>)

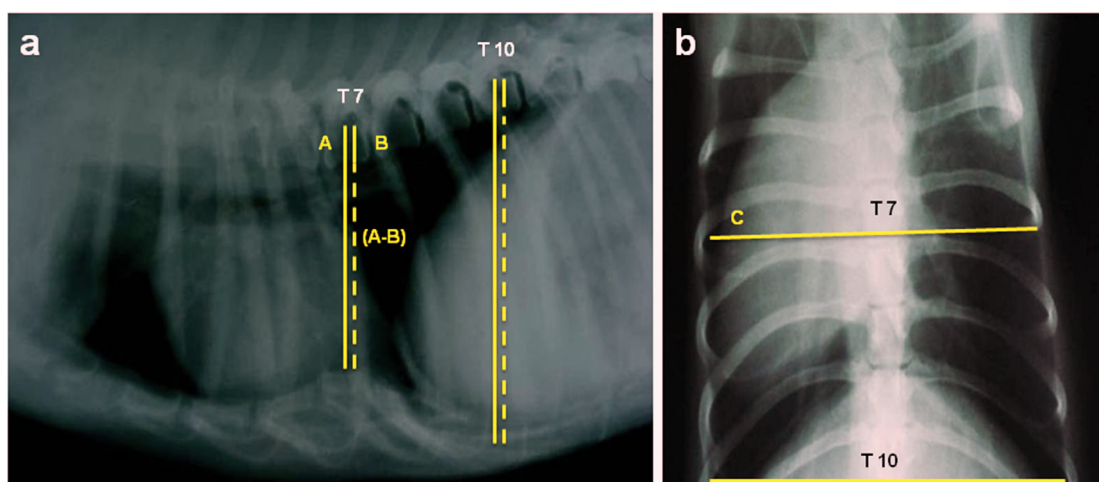


Fig. 1. Right lateral thoracic radiograph (a) and ventro-dorsal radiograph (b) demonstrating measurement of the thoracic depth and width for calculation of thoracic indices at the 10th thoracic vertebra (T10) as well as the 7th thoracic vertebra (T7) representing the vertebra overlying the excavatum. The VI is the ratio between the distance between the dorsum of the vertebral segment to the dorsal aspect of the sternum (A) and the dorso-ventral diameter of the corresponding vertebral segment (B). The FSI is the ratio between the center of the ventral aspect of each vertebral segment to the corresponding point on the dorsal aspect of the sternum (A–B) and the corresponding thoracic width measured at the same vertebral segment using ventro-dorsal radiograph (C).

correlated the clinical signs with the computed tomographic imaging of pectus excavatum using a 6-point clinical severity score [3]. No available records have been published correlating the severity of clinical signs with the type of pectus excavatum based on the degree and anatomic location of the sternal deviation.

The aim of present study was to correlate the clinical severity of pectus excavatum with its type and degree based on objective radiographic evaluation in 12 brachycephalic dogs.

MATERIALS AND METHODS

The present study was carried out on 12 brachycephalic dogs (five Pug, four Pekingese, and three Yorkshire dogs) of different ages (6 months to 5 years) and sexes (seven male and five female). These dogs were presented to the clinic of the Department of Surgery, Anesthesiology and Radiology, Faculty of Veterinary Medicine, Cairo University. Owners were aware that their dogs will be included in research purposes and signed a consent indicating their approval. No additional investigations were done for any dog other than those required for diagnosis. All legal and ethical requirements have been met with regard to the humane management of the presented dogs.

Complete historical data were collected including the initial complaint; 9 dogs were admitted with respiratory distress, dyspnea, cough, and exercise intolerance, while the other 3 dogs were presented without any clinical manifestation. Complete clinical examination was done to exclude the evidence of brachycephalic airway obstructive syndrome manifested by absence of stenotic nares, elongated soft palate, everted tonsils, or laryngeal collapse. No concurrent systemic manifestation was reported in any of the presented dogs.

All dogs underwent complete physical examination; the clinical signs were assessed using a 6-point clinical severity score (0, clinically sound; 1, elevated respiratory rate >30 breaths/min; 2, elevated respiratory rate and exercise intolerance; 3, elevated respiratory rate and intermittent dyspnea <50% of the time; 4, prolonged dyspnea >50% of the time; 5, prolonged dyspnea with significant extrathoracic disease) [3].

Lateral and ventro-dorsal thoracic radiographs were taken to determine the type of pectus excavatum (based on the anatomical location of the deviation) and to evaluate the thoracic width and depth by means of the FSI and VI [10]. The FSI and VI were calculated at the site of the defect and compared to those at T10 (Fig. 1).

Detailed evaluation of thoracic radiographs including the trachea, bronchi, and lung parenchyma as well as the size and position of the heart was done [16]. Echocardiographic examination was done for all dogs to evaluate cardiac size and function based on the established reference values specific for each breed [2].

Data were expressed as mean \pm SD. A paired *t*-test was used to compare the mean FSI and VI at T10 as well as at the vertebra overlying the deviation. Data were considered statistically significant when the *P*-value was <0.05. The correlation between the severity of clinical signs and type and degree of pectus excavatum was evaluated using Pearson's correlation coefficient. An *r*-value \geq 0.5 was considered strongly correlated, and an *r*-value <0.5 was poorly correlated. Data were analyzed using SPSS software version 21 (SPSS Inc., Chicago, IL, U.S.A.).

Table 1. Clinical severity score in relation to the site of deviation in 12 brachycephalic dogs which presented with pectus excavatum

Score	Clinical signs	No. of dogs	Site of sternal deviation
0	Clinically sound	3	Caudal
1	Elevated respiratory rate >30 breaths/min	0	
2	Elevated respiratory rate and exercise intolerance	1	Caudal
3	Elevated respiratory rate and intermittent dyspnea <50% of the time	5	2 Mid-sternum and 3 Caudal
4	Prolonged dyspnea >50% of the time	3	Mid-sternum
5	Prolonged dyspnea with significant extrathoracic disease	0	

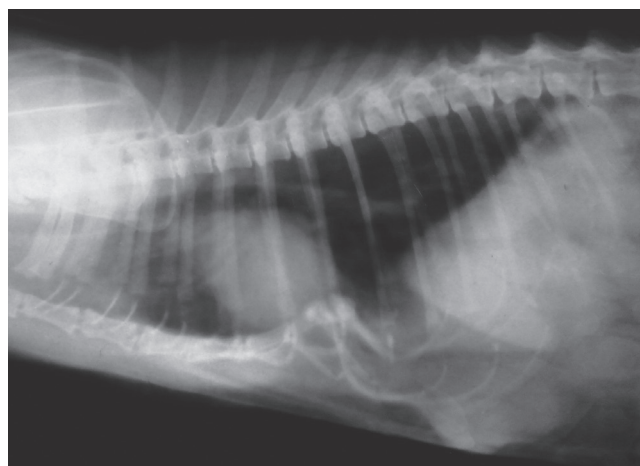


Fig. 2. Right lateral thoracic radiograph of a 3-year-old Yorkshire dog with typical pectus excavatum. Note the ventro-dorsal sternal deviation at the level of the 6th–8th sternebrae. Dorsal displacement of the heart results in dorsal displacement of the trachea where it becomes parallel to the thoracic spines. Marked thickening was seen along the bronchi (tram line) appearance indicating bronchial pattern.

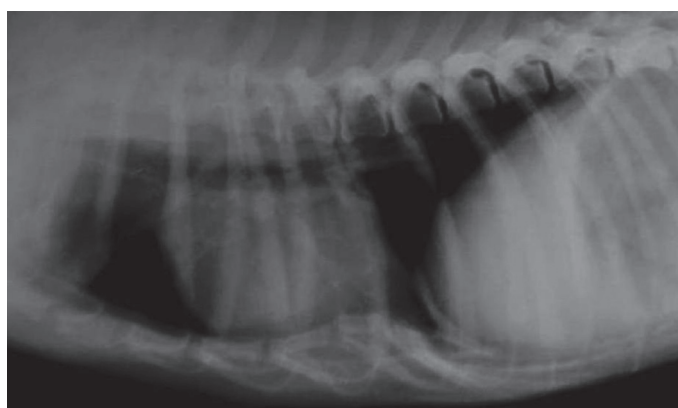


Fig. 3. Right lateral thoracic radiograph of a 3-year-old Pekingese dog with typical pectus excavatum. A ventro-dorsal deviation of the sternum is located at the level of the 5th–8th sternebrae. A small round radiolucent bulla (emphysematous bulla) was seen within the lung parenchyma.

RESULTS

All of the presented dogs were brachycephalic breeds of different ages (growing and adult). Upon admission, the main clinical manifestation was mild to severe respiratory distress manifested by dyspnea ($n=9$) and recurrent paroxysmal cough ($n=4$), whereas three dogs presented without any respiratory or cardiovascular manifestation. Palpable concave depression within the ventral thoracic wall was noticed by the owners of eight dogs.

On inspection, marked depression was seen at the caudal part of the sternum ($n=7$) and mid-sternum in the remaining dogs ($n=5$). The depression was shallow (less than 2 cm) occupying about 2–3 cm of the caudal sternum ($n=4$), while it was deep (more than 2 cm) extending about 3–5 cm in the caudal ($n=3$) and mid-sternal ($n=5$) region. Shallow rapid respiration with audible wheezes was noticed in six dogs, and open-mouth respiration was recorded in one dog.

The mean clinical severity score were 1.7 ± 1.4 and 3.8 ± 0.7 in the dogs with caudal and mid-sternal deviations, respectively. The detailed clinical severity score in relation to the site of deviation is presented in Table 1.

Thoracic auscultation revealed loud wheezes all over the chest ($n=6$). The cardiac sound was audible at the right hemithorax (6th to 9th intercostal spaces) in seven dogs. Abnormal systolic murmurs were recorded in five dogs.

Lateral thoracic radiographs demonstrated ventro-dorsal sternal deviation that was typically recorded at the caudal sternum (in three dogs at the level of 7th–8th sternebrae, in three dogs at the 6th–8th sternebrae, and in one dog at the 5th–8th sternebrae) (Figs. 2 and 3). Atypical deviation was recorded at the 4th–6th sternebrae of the mid-sternal region ($n=5$) (Fig. 4).

In all radiographs, the heart was dorsally displaced with subsequent dorsal displacement of the trachea where it appeared parallel to the thoracic spine. Cardiomegaly was diagnosed in four dogs. Bronchial pattern was seen along the lung parenchyma in the form of thickened linear opacity of the main bronchi extending toward the periphery of the lung ($n=5$). A rounded radiolucent area was seen within the lung parenchyma in two dogs, suggesting emphysematous bullae.

Ventro-dorsal radiographs of dogs with typical deviation revealed right-sided heart displacement where the heart was in contact

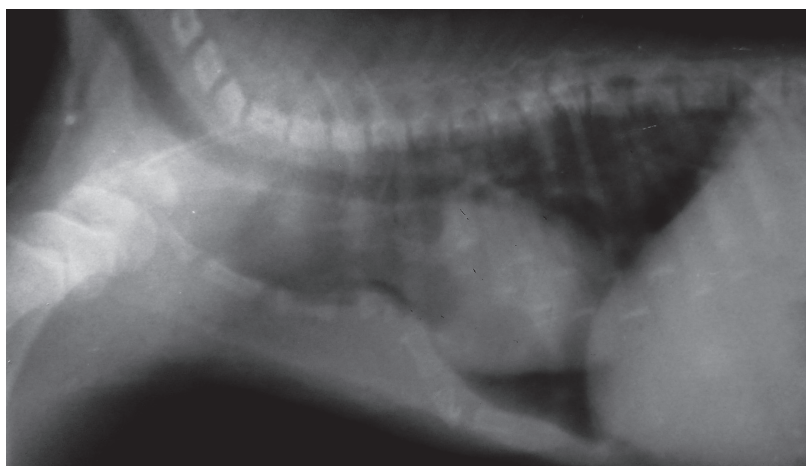

Fig. 4. Right lateral thoracic radiograph of a 6-month-old Pug puppy with atypical pectus excavatum. Note the mid-sternal deviation extending from the level of the 3rd–6th sternbrae. The heart is displaced dorsally with apparent rotation; the heart apex is shifted from the sternum and comes in contact with the diaphragm.

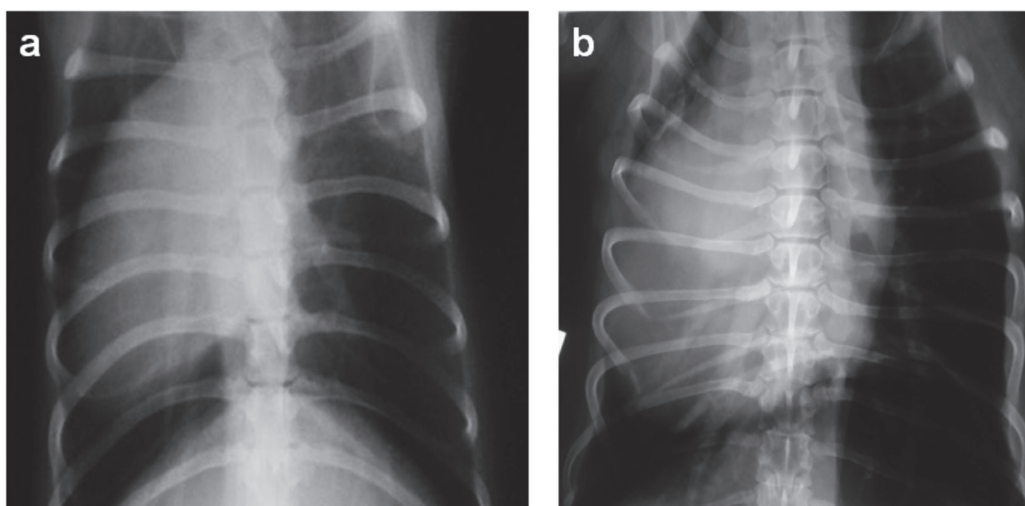


Fig. 5. Ventro-dorsal thoracic radiograph of a 3-year-old Pekingese dog (a) and a 5-year-old Pug dog (b) with typical pectus excavatum demonstrating displacement of the heart to the right hemithorax where the heart is in close contact to the thoracic wall (a) and in contact to the thoracic wall (b).

with the right thoracic wall ($n=4$) or close to the thoracic wall ($n=3$) (Fig. 5). In dogs with atypical deviation ($n=5$), the heart was mildly displaced to the right side.

Echocardiographic examinations revealed normal cardiac dimensions and indices in four dogs. Four dogs demonstrated increased left ventricular internal diameter in diastole (LVIDd) and left ventricular internal diameter in systole (LVIDs). Eight dogs demonstrated left ventricular dyskinetic wall motion, which was clearly visualized in dogs with atypical pectus excavatum compared with those with the typical form. Echocardiographic data of dogs with typical and atypical pectus excavatum are presented in Table 2.

The mean FSI was 1.4 ± 0.3 at T10 and 2.2 ± 0.5 at the vertebra overlying the excavatum in the typical form, while it was 1.2 ± 0.1 at T10 and 1.6 ± 0.1 at the site of excavatum in the atypical form. The mean VI in the typical form was 12.5 ± 1.4 at T10 and 7.4 ± 1.2 at the vertebra overlying the excavatum. In the atypical form, the mean VI was 13.2 ± 0.3 at T10 and 5.6 ± 0.2 at the site of excavatum. The VI was more indicative of the degree of deviation and reduction of the thoracic depth compared to the FSI. The mean FSI and VI in the typical and atypical forms of pectus excavatum is presented in Table 3.

A strong positive correlation ($r=0.7$) was recorded between the clinical severity score and VI in the atypical form of pectus excavatum, while a weak correlation ($r=0.02$) was recorded in the typical form ($P<0.05$).

Table 2. Echocardiographic data of the 12 brachycephalic dogs with typical and atypical forms of pectus excavatum

Dog	Type of pectus excavatum	Breed	LVIDd (cm)	LVIDs (cm)	FS (%)	EF (%)	Remarks
1	Typical	Pug	2.8	1.7	39.3	61.1	Normal echocardiographic dimensions and indices for the specific breed
2	Typical	Pug	3.6	2.8	22.2	36.2	Cardiomegaly associated with dyskinetic wall motion
3	Typical	Yorkshire	3.1	1.7	45.2	75.3	Normal echocardiographic dimensions and indices for the specific breed
4	Typical	Yorkshire	3.3	1.9	42.4	59.3	Normal cardiac dimensions associated with dyskinetic wall motion
5	Typical	Pekingese	3.0	1.4	53.3	56.2	Normal echocardiographic dimensions and indices for the specific breed
6	Typical	Pekingese	3.2	1.6	50.0	62.3	Normal echocardiographic dimensions and indices for the specific breed
7	Typical	Pekingese	3.4	1.8	47.1	66.6	Normal cardiac dimensions associated with dyskinetic wall motion
8	Atypical	Pug	3.8	2.8	26.3	38.1	Cardiomegaly associated with dyskinetic wall motion
9	Atypical	Pug	3.7	2.7	27.0	34.2	Cardiomegaly associated with dyskinetic wall motion
10	Atypical	Pug	3.5	2.1	40.0	58.3	Normal cardiac dimensions associated with dyskinetic wall motion
11	Atypical	Yorkshire	3.0	1.8	40.0	56.5	Normal cardiac dimensions associated with dyskinetic wall motion
12	Atypical	Pekingese	4.1	2.9	29.1	40.3	Cardiomegaly associated with dyskinetic wall motion

LVIDd, left ventricular internal diameter in diastole; LVIDs, left ventricular internal diameter in systole; FS, fractional shortening; EF, ejection fraction.

Table 3. The mean frontosagittal index and vertebral index in the typical and atypical forms of pectus excavatum in 12 brachycephalic dogs

Index	Site	Type of pectus excavatum	
		Typical	Atypical
Frontosagittal index	T10	1.4 ± 0.3	1.2 ± 0.1
	Vertebra overlying deviation	2.2 ^a ± 0.5	1.6 ^a ± 0.1
Vertebral index	T10	12.5 ± 1.4	13.2 ± 0.3
	Vertebra overlying deviation	7.4 ^a ± 1.2	5.6 ^a ± 0.2

a) Statistically significant when compared to the 10th thoracic vertebrae (T10), *P*-value <0.05.

DISCUSSION

Twelve brachycephalic dogs were included in the present study investigating a ventro-dorsal sternal deviation categorized as typical and atypical pectus excavatum. Based on objective radiographic evaluation, a strong positive correlation was reported between the clinical severity and type of pectus excavatum in the atypical form.

The exact cause of the sternal deviation is unclear. Multiple causes have been suggested, including abnormal intrauterine pressure, shortening in the central diaphragmatic tendon, failure of osteo-/chondrogenesis, or abnormal pressure respiratory gradient [8–10]. In the present study, all dogs were brachycephalic breeds; thus, genetic predisposition cannot be excluded. Such brachycephalic breeds are predisposed to obstructive respiratory distress manifested by elevated upper airway resistance, with subsequent elevated pleural pressure, leading to a pressure respiratory gradient and inward traction of the sternum [11, 15].

The diagnosis of pectus excavatum is usually straightforward through clinical and radiographic examination. Although the condition is congenital, dogs included in the study were presented at varying ages based on the owner's observation of the deviation or progression of the clinical signs. The condition was diagnosed mostly in the caudal part of the sternum, caudal to the 5th sternbrae (typical pectus excavatum) [1, 3, 8, 9, 11, 14, 17], while it was reported at the cranial sternum, from the 1st to 5th sternbrae, in two Welsh terrier dogs [5]. In the present study, five of the presented dogs had a mid-sternal deviation from the 4th to the 6th sternbrae which could be classified as atypical form of pectus excavatum.

The clinical signs associated with pectus excavatum could be attributed to the compressive cardiopulmonary dysfunction resulting from organ displacement or restriction of ventilation [4, 7].

In the present study, audible wheezes all over the lung parenchyma suggest bronchial narrowing, which was confirmed radiographically by the presence of bronchial pattern. The radiolucent emphysema seen in two dogs may have resulted from the recurrent paroxysmal cough leading to rupture of some alveoli. Auscultation of heart sound in the right hemithorax indicated right displacement of the heart, which was confirmed by the ventro-dorsal radiographs. The degree of displacement was correlated with the severity of the concurrent clinical signs. Cardiac displacement and possibly cardiac rotation may have resulted in kinking of the major blood vessels, which manifested clinically as cardiac murmurs.

Echocardiographic examination revealed dyskinetic wall motion in eight dogs, which may be a result of dorsal displacement of the heart by the deviated sternum. This displacement results in pressure overload on the heart and major blood vessels, resulting in cardiomegaly, as evidenced in four dogs.

The radiographic reference point for evaluating the thoracic depth and width was taken at T10. This point is the deepest and widest thoracic dimensions in lateral and ventro-dorsal radiographs, respectively. Objective radiographic evaluation of the

thoracic depth by means of the FSI and VI relies on evaluating the thoracic depth and width at the level of T10. Based on thoracic conformation, the thoracic depth and width at any other level is logically lower than those at T10.

In the present study, the FSI was significantly increased and the VI was significantly decreased at the site of deviation compared to those at T10. The VI was more indicative of the degree of deviation and reduction of the thoracic depth when compared to the FSI. The FSI depends on two linear measurements obtained from two orthogonal views wherein multiple factors may affect the accuracy of these measurements (possible magnification, phase of respiration, and variable thoracic width). The VI relies on linear measurements obtained from the same point at the same radiograph and depends on a constant reference point (width of the T10).

The weak correlation between the clinical severity score and degree of deviation reported in dogs with typical pectus excavatum coincided with the findings of previous reports [10], which could be explained by the absence of cardiopulmonary dysfunction in caudal sternal deviation. The strong positive correlation of the clinical severity score in dogs with atypical pectus excavatum could be attributed to the high clinical severity score as a result of compressive cardiopulmonary dysfunction manifested by compression, displacement, and possible rotation of the heart with its associated blood vessels as well as restricted ventilation.

Limitation of the present study may include absence of the history of progression of sternal deviation, which may help in better understanding the etiopathogenesis of deviation. Another limitation may include the low number of dogs included in the study, reflecting the low incidence of sternal deviations. Thus, further multicenter studies should be directed toward collaborative research.

In conclusion, all dogs that presented with pectus excavatum show variable clinical signs, which depend mainly on the site/type of deviation rather than the degree of deviation.

REFERENCES

1. Benirschke, K., Kumamoto, A. T. and Bogart, M. H. 1981. Congenital anomalies in Lemur variegatus. *J. Med. Primatol.* **10**: 38–45. [[Medline](#)] [[CrossRef](#)]
2. Boon, J. A. 2011. *Veterinary Echocardiography*. 2nd ed. Wiley-Blackwell, Oxford.
3. Charlesworth, T. M., Schwarz, T. and Sturgess, C. P. 2016. Pectus excavatum: computed tomography and medium-term surgical outcome in a prospective cohort of 10 kittens. *J. Feline Med. Surg.* **18**: 613–619. [[Medline](#)] [[CrossRef](#)]
4. Cho, S., Hong, S., Chung, Y. and Kim, O. 2012. Radiological assessment of pectus excavatum in a Pekingese dog. *Korean J. Vet. Serv.* **35**: 251–254. [[CrossRef](#)]
5. Ellison, G. and Halling, K. B. 2004. Atypical pectus excavatum in two Welsh terrier littermates. *J. Small Anim. Pract.* **45**: 311–314. [[Medline](#)] [[CrossRef](#)]
6. Fan, L. and Murphy, S. 1981. Pectus excavatum from chronic upper airway obstruction. *Am. J. Dis. Child.* **135**: 550–552. [[Medline](#)]
7. Fonkalsrud, E. W. 2003. Current management of pectus excavatum. *World J. Surg.* **27**: 502–508. [[Medline](#)] [[CrossRef](#)]
8. Fossum, T. W., Boudrieau, R. J., Hobson, H. P. and Rudy, R. L. 1989. Surgical correction of pectus excavatum, using external splintage in two dogs and a cat. *J. Am. Vet. Med. Assoc.* **195**: 91–97. [[Medline](#)]
9. Fossum, T. W., Boudrieau, R. J. and Hobson, H. P. 1989. Pectus excavatum in eight dogs and six cats. *J. Am. Anim. Hosp. Assoc.* **25**: 595–605.
10. Fossum, T. W. 2012. Surgery of the lower respiratory system. pp. 958–90. *In: Small Animal Surgery*, 4th ed. (Fossum, T. W. ed.), Mosby, St. Louis.
11. Kurosawa, T. A., Ruth, J. D., Steurer, J., Austin, B. and Heng, H. G. 2012. Imaging diagnosis—acquired pectus excavatum secondary to laryngeal paralysis in a dog. *Vet. Radiol. Ultrasound* **53**: 329–332. [[Medline](#)]
12. Orton, E. C. 2003. Thoracic wall. pp. 373–87. *In: Textbook of Small Animal Surgery*, 3rd ed. (Slatter, D. ed.), Saunders, Philadelphia.
13. Pearson, J. L. 1973. Pectus excavatum in the dog (a case report). *Vet. Med. Small Anim. Clin.* **68**: 125–128. [[Medline](#)]
14. Rahal, S. C., Morishin Filho, M. M., Hatschbach, E., Machado, V. M., Aptekmann, K. P. and Corrêa, T. P. 2008. Pectus excavatum in two littermate dogs. *Can. Vet. J.* **49**: 880–884. [[Medline](#)]
15. Singh, M., Parrah, J. D., Moulvi, B. A., Athar, H., Kalim, M. O. and Dedmari, F. H. 2013. A review on pectus excavatum in canines: A congenital anomaly. *Iranian J. Vet. Surg.* **8**: 59–64.
16. Torad, F. A. and Hassan, E. A. 2014. Two-dimensional cardiothoracic ratio for evaluation of cardiac size in German shepherd dogs. *J. Vet. Cardiol.* **16**: 237–244. [[Medline](#)] [[CrossRef](#)]
17. Yaygingul, R., Kibar, B., Suner, I. and Belge, A. 2016. Pectus excavatum in a cat: a case report. *Vet. Med. (Praha)* **61**: 409–411. [[CrossRef](#)]