



OPEN Hydrocephalus in primary brainstem hemorrhage risk predictors and management

Yuehui Ma¹✉, Linghao Bu¹, Dengchang Wu², Kang Wang² & Hengjun Zhou¹

This study explored the risk factors associated with hydrocephalus incidence and evaluated the effectiveness of surgical treatments in managing this condition. Patients with PBSH were retrospectively evaluated, identifying clinical and radiological characteristics. A multivariate logistic regression model was used for analyses. Of the 169 patients studied, 77 developed hydrocephalus. Midbrain hemorrhage, tegmental pons hemorrhage, disappearance of annular cisterna, combined cerebellar and intraventricular hematoma increased the risk of hydrocephalus ($p < 0.05$). A linear relationship was found between hematoma volume and hydrocephalus, with a volume > 6.1 mL associated with a higher risk. Patients with ≥ 2 the following factors: multiple hematoma sites, intraventricular hematoma, or hematoma volume > 6.1 mL, had a significantly increased risk of hydrocephalus. Forty-seven patients received surgical treatments including stereotactic puncture drainage of hematoma (SPDH) or external ventricular drainage (EVD). Both SPDH and EVD were effective in treating hydrocephalus ($p < 0.001$). The combination of SPDH and EVD showed the greatest benefit ($p < 0.001$); 30-day mortality and de-ventilator rates in the surgical group were significantly different from the non-surgical group. This finding provides valuable insights for early surgical intervention in patients with PBSH.

Keywords Brainstem, Hemorrhage, Stroke, Hydrocephalus, Risk factors, Surgery

Primary brainstem hemorrhage (PBSH) is a rare but fatal subtype of intracerebral hemorrhage (ICH), representing approximately 3.4–5.8% of spontaneous ICH cases^{1,2}. PBSH is characterized by acute onset, rapid progression, and early coma, often necessitating mechanical ventilation. It is associated with poor outcomes, including high mortality and disability rates^{2,3}. The severity of PBSH leads to prolonged hospital stays and increased medical resource use, imposing a substantial burden on healthcare systems.

While conservative management may be appropriate for small brainstem hematomas with clear consciousness and a favorable prognosis, larger brainstem hematomas can have mortality rates as high as 30 to 90%^{4–6} and typically require surgical intervention. Active treatment approaches have been shown to improve outcomes in cases with larger hematomas^{7–9}. Although such instances are currently isolated, their frequency may increase with advancements in minimally invasive surgical techniques.

Hydrocephalus is a common and treatable complication following spontaneous ICH^{10–12}. PBSH can easily extend into the ventricle system and obstruct cerebrospinal fluid circulation, resulting in hydrocephalus. Many patients with larger hematomas often present with hydrocephalus-related complications. According to a systematic review, hydrocephalus develops in up to 30.3% of patients with PBSH¹³ and has been identified as an independent prognostic factor for PBSH^{14,15}.

PBSH treatment is inactive and passive. External ventricular drainage (EVD) is a formal indication in cases presenting with hydrocephalus. However, current treatment is still conservative intensive care for the little dataset supporting neurosurgical interventions^{16–18}. Moreover, EVD alone cannot solve the mass effect and secondary injury of hematoma. Early aggressive surgical treatment, including hematoma removal surgery, may stabilize and shorten the pathological process of brain stem hematoma as soon as possible, providing a solid foundation for patients to withdraw from life system support and enter rehabilitation treatment as early as possible. This study aimed to identify clinical and radiological features associated with the development of hydrocephalus and to evaluate the effectiveness of hydrocephalus treatment in patients with PBSH.

¹Department of Neurosurgery, The First Affiliated Hospital, School of Medicine, Zhejiang University, No.79 Qingchun Road, Hangzhou 310003, Zhejiang Province, China. ²Department of Neurology, The First Affiliated Hospital, School of Medicine, Zhejiang University, No.79 Qingchun Road, Hangzhou 310003, Zhejiang Province, China. ✉email: yhma@zju.edu.cn

Methods

Clinical data collection and study design

This retrospective study was conducted at a single center between January 2021 and December 2023. This study was approved by the Clinical Research Ethics Committee of the First Affiliated Hospital, Zhejiang University School of Medicine (2024/ETH1161). Due to the retrospective nature of the study, the need for informed consent was waived by First Affiliated Hospital, Zhejiang University School of Medicine. The study was performed in accordance with the relevant guidelines and regulations. Medical information was collected in tabular form, and serial numbers were used instead of patient's private information. Diagnosis of PBSH was confirmed through computed tomography (CT) or CT angiography (CTA). Patients with non-spontaneous causes, such as trauma, tumors, cavernous hemangiomas, arteriovenous malformations, aneurysms, hemorrhagic cerebral infarction, or coagulopathy, were excluded from this study. Medical records and brain CT imaging from a computerized database were independently reviewed by two clinical research coordinators using structured forms.

Study group and interventions

Patients were divided into hydrocephalus group and non-hydrocephalus group. Hydrocephalus presence was determined from brain CT scans by observing dilation in the temporal horn of the ventricle, enlargement of the third or lateral ventricles, and either shallow or disappeared sulci. Intraventricular hematomas were also referenced for confirmation. Information on risk factors associated with the incidence of hydrocephalus was collected from imaging characteristics: hematoma sites, hematoma volume, ambiens cistern disappearance, and combined hematoma elsewhere, such as basal ganglia, cerebellum and ventriculohematoma. The volume of the hematoma was calculated using Tada's formula ($ABC/2$)¹⁹.

Individualized surgical interventions were selected based on the following factors: (1) hematoma volume, (2) resolution of cisterna surrounding the brainstem, (3) extension of the hematoma into the ventricle, (4) presence of hydrocephalus, (5) severity of the patient's condition, and (6) family preference. Stereotactic puncture drainage of hematoma (SPDH) and/or EVD were employed as surgical methods. The Medtronic S8 opt-magnetic integrated navigation system guided puncturing brainstem hematoma and the lateral ventricle. For EVD, a ventricular catheter (Phoenix external drainage set) was placed on the frontal horn of the right lateral ventricle. Microbiological and biochemical analysis of cerebrospinal fluid (CSF) samples is carried out daily. The velocity of CSF is regulated by adjusting the height of the drainage device. For SPDH, the navigation system was used to place the ventricular catheter into the hematoma stereotactically. The design principle of the puncture path is that the entry point is selected on the convex surface of the cerebellum, and the target is located in the center of the long axis of the hematoma; the puncture path should be as short as possible and close to the longitudinal axis of the hematoma. After postoperative CT scanning, the hematoma was aspirated with a syringe and then dissolved by injecting urokinase into the hematoma cavity once a day. The drainage catheter was removed according to CT scanning results. Patients with PBSH were categorized into different groups based on their respective surgical approach, with non-operative patients serving as the control group: (1) control group, (2) SPDH group, (3) EVD group, and (4) SPDH + EVD group. The effectiveness of the operative was evaluated by hydrocephalus remission and prognosis assessment.

Outcome assessment

Indicators of disease severity included the disturbance of consciousness at admission, cardiac arrest and cardiopulmonary resuscitation (CPR), endotracheal intubation, and ventilator-assisted breathing. Consciousness was assessed using the Glasgow Coma Scale (GCS), with unconsciousness defined as the absence of voluntary movements, unresponsiveness to verbal and external stimuli, and a GCS score below nine. For patients who underwent SPDH or EVD, the duration of drainage was used to evaluate the operation's effectiveness. Patient prognosis was assessed based on 30-day mortality (mortality within 30 days of symptom onset), successful ventilator withdrawal (de-ventilator), and length of hospital stay (in-hospital days). Upon discharge, patients were either monitored at home or referred to a rehabilitation hospital for further treatment.

Statistical analysis

Statistical analysis was performed using R language (version 4.2.2). Univariate analyses were performed using Chi-square tests or non-parametric rank sum tests to determine: (1) the relationship between hydrocephalus and indicators of disease severity, (2) the relationship between hydrocephalus and prognosis indicators of PBSH, (3) risk factors of hydrocephalus, and (4) the impact of different surgical treatments on hydrocephalus remission and prognosis. Multivariate logistic regression analysis identified disease severity indicators and prognostic factors related to hydrocephalus, as well as the best surgical treatment for hydrocephalus in patients with PBSH. Fisher's exact test was used to examine differences in prognosis between surgical treatment groups, considering factors such as age and sex. Statistical significance was set at $p < 0.05$.

Results

Prognosis analysis of patients with PBSH

Of the 169 patients with PBSH enrolled in this study, 140 were men and 29 were women, with an average age of 52.7 years (range 33–91 years) (Table 1). Severe PBSH often presents with a high incidence of coma. At admission, 62 patients were conscious, while 107 (63.3%) were unconscious. Eight patients experienced cardiac arrest and were successfully resuscitated with CPR. Ninety-three patients required endotracheal intubation and ventilator-assisted breathing upon admission. Other common symptoms included sudden headaches, dizziness, nausea, vomiting, convulsions, and limb weakness or numbness.

Factors	With Hydrocephalus (n = 77)	Without hydrocephalus (n = 92)	Total (n = 169)
Age (years) ^a	50.2 (36–80)	54.8 (33–89)	52.7
Sex			
Male	69	71	140
Female	8	21	29
Level of consciousness			
Conscious	2 (3.2%)	60 (96.8%)	62
Unconscious	75 (70.1%)	32 (29.9%)	107
Cardiac arrest/CPR	5 (62.5%)	3 (37.5%)	8
Endotracheal intubation	67 (72.0%)	26 (28.0%)	93
Ventilator support	74 (69.2%)	33 (30.8%)	107
Hematoma location			
Midbrain	0 (0%)	2 (100%)	2
Pons			
Basal pons	2 (9.1%)	20 (90.9%)	22
Tegmental pons	12 (31.6%)	26 (68.4%)	38
Central pons	4 (10.8%)	33 (89.2%)	37
Medulla	1 (25.0%)	3 (75.0%)	4
Midbrain-pons	58 (87.9%)	8 (12.1%)	66
Midbrain-pons-medulla	1 (100%)	0 (0%)	1
Combined hematoma elsewhere			
Basal ganglia	11 (100%)	0 (0%)	11
Cerebellum	8 (88.9%)	1 (11.1%)	9
Intraventricular hematoma	56 (91.8%)	5 (8.2%)	61
Third ventricle	4 (100%)	0 (0%)	4
Fourth ventricle	17 (81.0%)	4 (19.0%)	21
Third-fourth ventricle	11 (100%)	0 (0)	11
Third-lateral ventricle	9 (90.0%)	1 (10.0%)	10
Total ventricular system	15 (100%)	0 (0)	15
Ambiens cistern disappearance	69 (98.6%)	1 (1.4%)	70
Hematoma volume (mL) ^a	15.8 (3.4–36.7)	2.9 (0.3–9.2)	8.7
Status on Discharge			
30-day mortality	18 (90.0%)	2 (10.0%)	20
30-day de-ventilator	22 (53.7%)	19 (46.3%)	41
Time of de-ventilator (d) ^a	10 (8–10.75)	10 (8–10.75)	9.2
In-hospital days (d) ^a	14.2 (4–20)	11.1 (6–14)	12.5

Table 1. Clinical characteristics of patients without hydrocephalus versus patients with hydrocephalus. Values are reported as frequency (percentage) or ^a mean (range). CPR, cardio-pulmonary resuscitation; De-ventilator, detaching ventilator; d, day.

Twenty patients (11.8%) died within 30 days of symptom onset. The remaining patients were discharged home or transferred to local or rehabilitation hospitals. The average length of hospital stay was 12.5 ± 7.2 days. By the 30th day of admission, 66 of the 107 patients (61.7%) who received endotracheal intubation and ventilator support still required ventilator assistance, while 41 (38.3%) patients were successfully weaned from ventilator support, with a mean de-ventilator time of 9.2 ± 4.8 days.

Neuroradiological findings among patients with PBSH

Radiological characteristics are detailed in Table 1. Pons hemorrhage was the most common, occurring in 97 (57.4%) cases, including basal hemorrhage (22 cases), tegmental hemorrhage (38 cases), and central hemorrhage (37 cases). Isolated midbrain and medulla hemorrhages were less frequent, with two and four cases, respectively. Additionally, 39.1% of cases involved multiple parts of the brainstem: midbrain-pons (66 cases) and midbrain-pons-medulla (one case). Massive bleeding extended to the basal ganglia in 11 cases and the cerebellum in nine cases.

The occupying effect of PBSH often led to the disappearance of the cisterna surrounding the brainstem, with the disappearance of the annular cisterna being the most common, occurring in 70 cases. Among the 169 patients, 61 had hematomas that penetrated the ventricular system, including the third ventricle (four cases), fourth ventricle (21 cases), both third and fourth ventricles (11 cases), third and lateral ventricles (10 cases), and

the entire ventricular system (15 cases). The average hematoma was 9.1 mL (range 0.3–36.7 mL). Of these, 83 cases had a volume ≤ 6.1 mL, and 86 cases had a volume > 6.1 mL.

Hydrocephalus prevalence in patients with PBSH and its risk factors

In this cohort of 169 patients with PBSH, 77 (45.6%) patients developed hydrocephalus. Hydrocephalus aggravated the condition, with 44% of patients being unconscious, 39.6% requiring endotracheal intubation, and 43.8% needing ventilator support. Univariate analysis showed that patients with hydrocephalus had significantly more severe disease compared with those without hydrocephalus, as indicated by higher rates of unconsciousness, endotracheal intubation, and ventilator support ($p < 0.001$). There was no significant difference in the incidence of cardiac arrest between patients with and without hydrocephalus ($p = 0.33$).

Hydrocephalus also affects the prognosis. The 30-day mortality rate for patients with hydrocephalus was significantly higher compared with those without hydrocephalus (23.4% vs. 2.2%, $p < 0.001$). Conversely, the de-ventilator rate was significantly lower than in those without hydrocephalus (29.7% vs. 57.6%, $p < 0.01$). Multivariate logistic regression analysis revealed that hydrocephalus was associated with a low de-ventilator rate (odds ratio (OR) = 0.27, 95%CI: 0.084–0.78, $p < 0.05$), indicating that patients with hydrocephalus were less likely to be weaned off ventilator support.

As a direct complication of PBSH, risk factors for hydrocephalus were examined mainly through imaging findings of PBSH. Univariate logistic regression, adjusted for age and sex, identified midbrain hemorrhage, tegmental pons hemorrhage, annular cisterna disappearance, and hematoma extension into the cerebellum as increasing the risk of hydrocephalus. Additionally, hematoma penetration into the ventricles also heightened the risk. The RCS curve demonstrated a linear relationship between hematoma volume and hydrocephalus (Fig. 1). Compared with the reference group with hematoma volume ≤ 6.1 mL, a volume > 6.1 mL was associated with a significantly increased risk of hydrocephalus (Table 2).

Variables with $p < 0.01$ in univariate logistic regression were included in the multivariate logistic model for further analysis. The results are shown in Table 3. Midbrain hemorrhage, tegmental pons hemorrhage, annular cisterna disappearance, hematoma involving the cerebellum, hematoma penetrating the ventricle, and hematoma

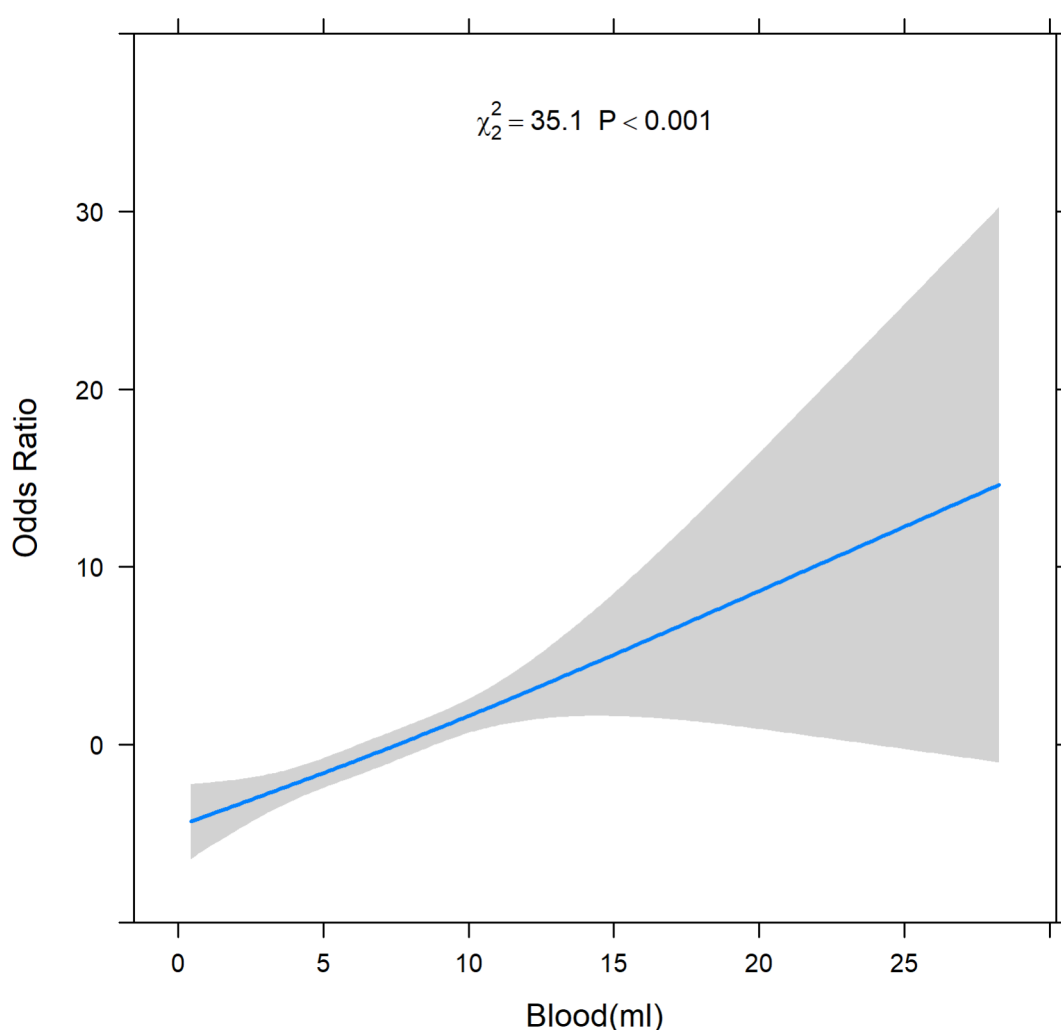


Fig. 1. RCS curve of hematoma volume and hydrocephalus in patients with PBSH.

Factors	Case	With Hydrocephalus (n = 77)	Without hydrocephalus (n = 92)	OR (95%CI)	p
Hematoma location					
Midbrain ^a	69	59	10	33.9 (14.1–92.4)	<0.001
Pons					
Basal pons ^a	32	11	21	0.4 (0.2–1.0)	0.055
Tegmental pons ^a	74	46	28	4.7 (2.4–9.9)	<0.001
Central pons ^a	66	29	37	0.8 (0.4–1.6)	0.59
Medulla ^a	5	2	3	1.1 (0.1–7.4)	0.92
Combined hematoma elsewhere					
Basal ganglia ^a	11	11	0	-	0.99
Cerebellum ^a	9	8	1	10.8 (1.9–206.7)	0.028
Intraventricular hematoma^a	61	56	5	97.0 (29.7–433.9)	<0.001
Third ventricle ^a	40	39	1	-	0.98
Fourth ventricle ^a	47	43	4	48.0 (15.1–212.1)	<0.001
Lateral ventricle ^a	25	24	1	47.9 (9.2–888.1)	<0.001
Ambiens cistern disappearance^a	70	69	1	1082.0 (175.5–22040.0)	<0.001
Hematoma volume (> 6.1 mL)^b	83	72	11	109.2 (3.8–397.3)	<0.001

Table 2. Comparison of hydrocephalus risk factors in patients with PBSH on admission. Values are presented as number (n) or mean (range). ^a Chi-square test; ^bNonparametric rank sum test.

Factors	β (S.D)	OR (95%CI)	p
Midbrain hematoma	3.9 (1.0)	50.5 (9.3–491.8)	<0.001
Tegmental hematoma	2.1 (0.9)	8.4 (1.7–6.3)	0.019
Combined cerebellum hematoma	4.1 (1.7)	57.5 (3.5–3411.7)	0.015
Combined intraventricular hematoma	4.1 (1.1)	59.7 (9.8–7.5)	<0.001
Hematoma volume	1.23 (0.4)	3.41 (1.95–9.85)	0.0018

Table 3. Multivariate logistic regression analysis of risk factors of hydrocephalus in patients with PBSH. S.D, Standard Deviation.

volume were highly reliable predictors of hydrocephalus development. The receiver operating characteristic (ROC) curve, based on this model (area under the curve (AUC)=0.988, 95%CI: 0.978–0.998), indicated an optimal cutoff value of 0.350, with specificity=0.924, sensitivity=0.961, and Youden index=0.885 (Fig. 2).

Radiological features of hematoma described above were classified into three categories: (1) multiple hematoma sites, (2) presence of intraventricular hematoma, and (3) hematoma volume>6.1 mL. These risk factors were included in a multifactorial risk study for hydrocephalus. Logistic regression analysis showed that patients with PBSH having ≥2 risk factors had a significantly increased risk of developing hydrocephalus compared with ≤1 risk factor (OR = 1618.5, 95%CI: 288.1–17515.7, $p < 0.001$).

Hydrocephalus surgery effectiveness and outcomes in patients with PBSH

The surgical methods used in this study included SPDH and EVD. Of 77 patients with PBSH complicated by hydrocephalus, 47 (61.0%) received surgical treatment. This included six patients in the SPDH group, 20 in the EVD group, and 21 in the SPDH + EVD group. Thirty (39.0%) patients did not undergo surgery (Control group). The average duration of hematoma puncture drainage was 5.0 days (range 4–14 days), while the average duration of external ventricular drainage was 10.3 days (range 4–17 days). Among the 21 patients who underwent combined SPDH and EVD (SPDH + EVD group), two patients ultimately required ventriculoperitoneal (VP) shunt surgery because of the unrelieved hydrocephalus.

Among the 47 patients with PBSH and hydrocephalus who underwent surgical intervention, 30 experienced relief from hydrocephalus, yielding a remission rate of 63.8%. In contrast, only one out of the 30 (3.3%) patients who did not undergo surgery experienced relief from hydrocephalus. There were notable differences in the remission rates of hydrocephalus based on the surgical method employed (Table 4). Specifically, the remission rates were 85.1% in patients who underwent SPDH surgery and 58.5% in those who underwent EVD surgery. Correlation analysis revealed that both SPDH and EVD surgeries were effective in treating hydrocephalus in patients with PBSH (Chi-square test, both $p < 0.001$). Logistic regression analysis further demonstrated that EVD (OR = 15.6, 95%CI: 2.39–310), and particularly the combination of SPDH and EVD (OR = 106.5, 95%CI: 15.5–2240.4), were the most effective surgical treatments for alleviating hydrocephalus in these patients ($p = 0.015$ and $p < 0.001$, respectively).

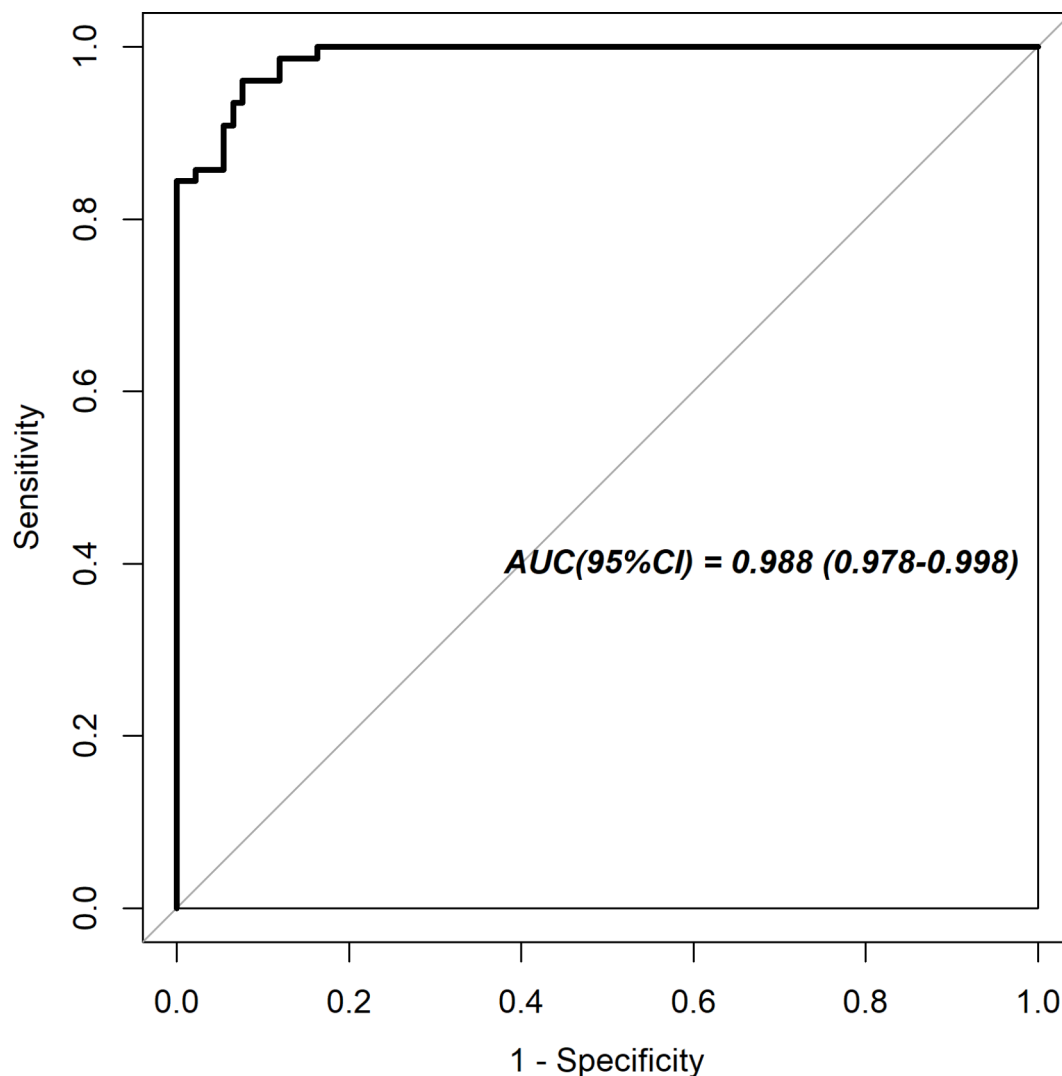


Fig. 2. ROC curve of risk factor regression model of hydrocephalus in patients with PBSH.

Groups	Case	Hydrocephalus remission rate	30-day mortality rate	30-day de-ventilator rate
Control group	30	1 (3.3%)	14 (46.7%)	1 (3.3%)
SPDH group	6	6 (100%)	0 (0)	4 (66.7%)
EVD group	20	7 (35.0%)	2 (10%)	10 (50.0%)
SPDH + EVD group	21	17 (81.0%)	2 (9.5%)	7 (33.3%)
<i>P</i> ^a		< 0.001	< 0.002	< 0.001

Table 4. Hydrocephalus remission rate and prognosis in different treatment groups. Values are reported as frequency (percentage). ^a Fisher's exact test, differences between groups.

Surgical intervention significantly improved the prognosis of patients with hydrocephalus. The 30-day mortality rate in the non-surgical (control) group was 46.7%, significantly higher than the 23.3% observed in the surgical group ($p < 0.001$). Additionally, the de-ventilator rate was only 3.3% in the control group, significantly lower than in the surgical group ($p < 0.001$). Further analysis revealed significant differences in 30-day mortality and de-ventilator rate among patients treated with different surgical methods (Table 4). The SPDH group had the lowest 30-day mortality (0%) and the highest de-ventilator (66.7%) rates, suggesting that patients with hydrocephalus due to PBSH greatly benefited from hematoma removal surgery.

Discussion

Many studies have sought to identify independent predictors of mortality or functional outcomes in patients with ICH or PBSH^{20–25}. The development of hydrocephalus has been recognized as a strong predictor of short- and long-term mortality, as well as poor 90-day outcomes in these patients^{16,20,26}. Hydrocephalus following PBSH is a common and treatable complication, making its management an important aspect of PBSH treatment. However, factors predicting hydrocephalus have been understudied. This study focused on identifying these factors and confirmed that PBSH had a high incidence of hydrocephalus, consistent with previous studies¹³. In this study, 45.6% of patients with PBSH developed hydrocephalus, which was associated with a more serious condition and poorer outcomes. Unconsciousness, endotracheal intubation, and ventilator support were statistically significant in patients with hydrocephalus. These patients also had a worse prognosis, evidenced by a higher 30-day mortality rate and a lower probability of being weaned off the ventilator. Although not statistically significant, patients with hydrocephalus also tended to have longer de-ventilator times and hospital stays than patients without hydrocephalus. Therefore, it is reasonable to recommend the inclusion of hydrocephalus in PBSH prognostication scoring systems¹⁵.

To the best of our knowledge, this is the first study to evaluate risk factors influencing the incidence of hydrocephalus in PBSH. Our study identified unconsciousness, midbrain hemorrhage, pons tegmental hemorrhage, combined cerebellum, combined intraventricular hematoma, and greater hematoma volume as the most significant predictors for the development of hydrocephalus following PBSH. Previous studies identified similar risk factors for hydrocephalus in patients with ICH, including infratentorial hemorrhage, hematoma extension to the ventricles, greater ICH volume, and hematoma expansion^{27–30}. Our results align with these, indicating that factors such as hematoma size, location, and expansion into the ventricle are critical in both PBSH and ICH for predicting the risk of hydrocephalus.

Understandably, hematoma expansion into the ventricle is a significant risk factor for hydrocephalus in PBSH. The midbrain and tegmental pons are anatomically close to the ventricles and cerebrospinal fluid circulation pathways, making bleeding in these areas more likely to either extend into the ventricular system or press on the pathways, thus increasing the risk of hydrocephalus. The amount of hematoma is another critical factor, differing in PBSH compared with other conditions like ICH. In this study, a hematoma volume threshold of 6.1 mL was identified, indicating that patients with hematoma volumes exceeding this volume have a very high probability of developing hydrocephalus.

Bleeding in the brainstem often extends longitudinally, affecting multiple sites. In our cohort, 36.1% of patients with PBSH exhibited hematoma involving multiple parts of the brainstem, such as pons-midbrain, pons-medulla, midbrain-pons-medulla, and even extending beyond the brainstem to areas like the basal ganglia and cerebellum. This study found significant differences in the location of multiple hematomas between patients with and without hydrocephalus. A prediction model was established based on three risk indicators: hematoma involvement of more than one site, hematoma volume greater than 6.1 mL, and hematoma extension into the ventricles. The study found that hydrocephalus could be predicted in patients with PBSH who had more than one of these risk factors.

In the past, the treatment approach for PBSH was often negative and pessimistic, largely owing to the severe nature of brainstem dysfunction and the high risk of persistent coma^{16,17}. Conservative treatment was associated with poor outcomes, particularly in cases of primary pons hemorrhage, where it was a poor predictor of 30-day mortality^{4,21}. With advancements in minimally invasive neurosurgery, the outlook for PBSH treatment has improved. Techniques like SPDH surgery have gained popularity because of their advantages, including simple and rapid operation, precise positioning, and minimal surgical trauma^{9,21,22}. The adoption of technologies, such as optomagnetic integrated navigation and neurosurgical robots, has further enhanced the precision and efficacy of these procedures, leading to better patient outcomes. This shift towards more proactive surgical interventions has contributed to improved prognosis and reduced reliance on long-term life support systems. Several studies have shown that early, aggressive surgical intervention can significantly reduce the 30-day mortality rate and improve prognosis^{8,14,31}. Our findings corroborate these results, showing that surgical treatment lowers the 30-day mortality rate and enhances the likelihood of ventilator weaning. Patients with hydrocephalus resulting from PBSH benefited from hematoma removal surgery.

Surgical treatment for hydrocephalus in patients with PBSH must address both the hydrocephalus and the hematoma. While EVD is the most common and effective surgical method for managing hydrocephalus^{7,32}, our study found that SPDH can also be effective. EVD may initially relieve hydrocephalus, but without hematoma removal, secondary damage can persist, and cerebrospinal fluid circulation may not be restored promptly. Combining SPDH with EVD addresses these issues. This combination clears the hematoma, reduces its occupying effect, and mitigates the cytotoxic impact of the hematoma decomposition products while helping to manage hydrocephalus in patients^{15,33}. This is especially important for the brainstem, which is especially sensitive to these cytotoxic effects^{33,34}. This study showed that SPDH combined with EVD was the best surgical method for PBSH complicated with hydrocephalus, which is very beneficial to the relief of hydrocephalus in patients with PBSH complicated with hydrocephalus.

Currently, the management of PBSH primarily involves passive and conservative intensive care. Despite the benefit of surgery for those presenting with PBSH has not been proven yet due to the limited dataset, exploratory surgical interventions are under consideration^{7,14,35,36}. This retrospective study specifically examines hydrocephalus during the early phase of PBSH, and surgical intervention may at least benefit patients in the early stage of treatment. However, this is evidently insufficient in addressing the entire treatment process and ultimate treatment objectives for PBSH. While various factors such as the financial capacity of patients' families, their willingness to continue treatment, and the rehabilitation and nursing capabilities of rehabilitation facilities may greatly influence later-stage treatments, it is imperative to conduct prospective studies that encompass

later prognostic indicators for hydrocephalus in patients with PBSH to determine specific surgical intervention methods associated with favorable or unfavorable outcomes.

Conclusions

PBSH complicated by hydrocephalus is a severe condition and was associated with a poorer outcome. Our research identified the most important factors contributing to the development of hydrocephalus in patients with PBSH: midbrain hemorrhage, tegmental pons hemorrhage, combined cerebellar or intraventricular hematoma, and hematoma volume > 6.1 mL. Furthermore, the risk of developing hydrocephalus significantly increased when patients exhibited multiple risk factors, that is, multiple hematoma sites, combined intraventricular hematoma, or hematoma volume > 6.1 mL. Advances in minimally invasive neurosurgical techniques have enhanced early prognosis in patients with PBSH. Both EVD and SPDH are effective in alleviating hydrocephalus, with the combination of SPDH and EVD being the most effective surgical method for relieving hydrocephalus, increasing the probability of successful ventilator weaning and reducing the 30-day mortality rate, thereby laying a solid foundation for neurological rehabilitation.

Data availability

The datasets generated during and/or analysed during the current study are available from the corresponding author on reasonable request.

Received: 18 November 2024; Accepted: 8 January 2025

Published online: 13 January 2025

References

- Nakajima, K. Clinicopathological study of pontine hemorrhage. *Stroke* **14**, 485–493 (1983).
- Sacco, S., Marini, C., Toni, D., Olivieri, L. & Carolei, A. Incidence and 10-year survival of intracerebral hemorrhage in a population-based registry. *Stroke* **40**, 394–399 (2009).
- AlMohammadi, R. M. et al. Brainstem hemorrhage is uncommon and is associated with high morbidity, mortality, and prolonged hospitalization. *Neurosciences (Riyadh)* **25**, 91–96 (2020).
- Chung, C. S. & Park, C. H. Primary pontine hemorrhage: A new CT classification. *Neurology* **42**, 830–834 (1992).
- Yoon, J. H., Kang, S. J., Choi, S. J. & Na, D. L. K. G. *Hypertensive Pontine Microhemorrhage Stroke* **33**, 925–929 (2002).
- Murata, Y. et al. Relationship between the clinical manifestations, computed tomographic findings and the outcome in 80 patients with primary pontine hemorrhage. *J. Neurol. Sci.* **167**, 107–111 (1999).
- Sripontan, S. Good outcome in a patient with massive pontine hemorrhage. *Asian J. Neurosurg.* **14**, 992–995 (2019).
- Meng, X. B., Wang, Q., Pei, X. G. & Xie, F. M. Prognosis and influencing factors of early microsurgery for severe hypertensive brainstem hemorrhage. *Dis. Markers* 5062591 (2022).
- Tang, Z. et al. Curative effect analysis of robot-assisted drainage surgery in treatment of spontaneous hypertensive brainstem hemorrhage. *Front. Neurol.* **15**, 1352949 (2024).
- Delcourt, C. et al. Intracerebral hemorrhage location and outcome among INTERACT2 participants. *Neurology* **88**, 1408–1414 (2017).
- Fischbein, N. J. & Wijman, C. A. C. *Nontraumatic Intracranial Hemorrhage Neuroimag Clin. N Am.* **20**, 469–492 (2010).
- Sheth, K. N. Spontaneous intracerebral hemorrhage. *N Engl. J. Med.* **387**, 1589–1596 (2022).
- Behrouz, R. Prognostic factors in pontine haemorrhage: a systematic review. *Eur. Stroke J.* **3**, 101–109 (2018).
- Jang, J. H., Song, Y. G. & Kim, Y. Z. Predictors of 30-day mortality and 90-day functional recovery after primary pontine hemorrhage. *J. Korean Med. Sci.* **26**, 100–107 (2011).
- Wahjoepramono, P. O. P. et al. Hydrocephalus is an independent factor affecting morbidity and mortality of ICH patients: systematic review and meta-analysis. *World Neurosurg.* **X**, **19**, 100194 (2023).
- Hemphill, J. C. et al. Guidelines for the management of spontaneous intracerebral hemorrhage: A guideline for healthcare professionals from the American Heart Association/American Stroke Association. *Stroke* **46**, 2032–2060 (2015).
- Steiner, T. et al. European Stroke Organisation. European Stroke Organisation (ESO) guidelines for the management of spontaneous intracerebral hemorrhage. *Int. J. Stroke.* **9**, 840–855 (2014).
- Hao, L., Wenke, L., Sen, L. & Chao, Y. Treatment of hypertensive brainstem hemorrhage. *Chin. J. Neurosurg.* **29**, 339–341 (2013).
- Kothari, R. U. et al. The ABCs of measuring intracerebral hemorrhage volumes. *Stroke* **27**, 1304–1305 (1996).
- Chen, D. et al. Primary brainstem hemorrhage: A review of prognostic factors and surgical management. *Front. Neurol.* **12**, 727962 (2021).
- Ding, Y., Qi, M., Zhang, X., Dong, J. & Wu, D. Stereotactic hematoma puncture and drainage for primary pontine hemorrhage: Clinical outcomes and predictive model. *Heliyon* **10**, e27487 (2024).
- Gong, X., Dong, H. Q., Li, X. & Liu, Z. J. Comparative analysis of clinical efficacy of stereotactic robot-guided puncture hematoma drainage and conventional puncture hematoma drainage in the treatment of intracerebral hemorrhage. *Pak J. Med. Sci.* **40**, 1675–1681 (2024).
- Ho, Y. N. et al. Predictive factors of neurologic deterioration in patients with spontaneous cerebellar hemorrhage: A retrospective analysis. *BMC Neurol.* **19**, 81 (2019).
- Posadas, G., Vaquero, J., Herrero, J. & Bravo, G. Brainstem haematomas: Early and late prognosis. *Acta Neurochir. (Wien)* **131**, 189–195 (1994).
- Zhang, J. et al. Retrospective analysis of prognostic factors in HICH patients after neuroendoscopic hematoma evacuation. *Sci. Rep.* **14**, 29505 (2024).
- Yang, W. S. et al. Hydrocephalus growth: Definition, prevalence, association with poor outcome in acute intracerebral hemorrhage. *Neurocrit Care.* **35**, 62–71 (2021).
- Chen, C. et al. Age-related differences in risk factors, clinical characteristics, and outcomes for intracerebral hemorrhage. *Front. Aging Neurosci.* **15**, 1264124 (2023).
- Flores, G., Amaral-Nieves, N., De Jesús, O. & Vigo, J. Risk factors for developing hydrocephalus in neonatal intraventricular hemorrhage. *PR Health Sci. J.* **39**, 55–57 (2020).
- Gluski, J. et al. Factors impacting hydrocephalus incidence in intracerebral hemorrhage: A retrospective analysis. *World Neurosurg.* **148**, e381–e389 (2021).
- Hu, R. et al. Long-term outcomes and risk factors related to hydrocephalus after intracerebral hemorrhage. *Transl Stroke Res.* **12**, 31–38 (2021).
- Hara, T. et al. Functional outcome of primary pontine hemorrhage: Conservative treatment or stereotaxic surgery. *No Shinkei Geka.* **29**, 823–829 (2001).

32. Sumer, M. M., Açıköz, B. & Akpınar, G. External ventricular drainage for acute obstructive hydrocephalus developing following spontaneous intracerebral haemorrhages. *Neurol. Sci.* **23**, 29–33 (2002).
33. Broderick, J. P. The STICH trial: What does it tell us and where do we go from here? *Stroke* **36**, 1619–1620 (2005).
34. Wu, Y., Huang, X., Yang, L. & Liu, Y. Purinergic neurotransmission receptor P2X4 silencing alleviates intracerebral hemorrhage-induced neuroinflammation by blocking the NLRP1/caspase-1 pathway. *Sci. Rep.* **13**, 14288 (2023).
35. Wang, S. S., Yang, Y. & Velz, J. Management of brainstem haemorrhages. *Swiss Med. Wkly.* **149**, w20062 (2019).
36. Wang, X. J. et al. Case Report: endoscopic trans-cerebellar medullary fissure approach for the management of brainstem hemorrhage. *Front. Neurol.* **14**, 1173905 (2023).

Acknowledgements

We would like to thank Prof. Yi-Min Zhu, Department of Epidemiology and Biostatistics, School of Medicine, Zhejiang University, for his data processing and statistical advice. We would also like to thank Wiley Editing Services for English language Editing.

Author contributions

All authors contributed to the study conception and design. Material preparation, data collection and analysis were performed by Y.M., L.B., D.W., K.W., H.Z. The first draft of the manuscript was written by Y.M. and all authors commented on previous versions of the manuscript. All authors read and approved the final manuscript.

Funding

This work was supported by the Project of Zhejiang Medical Science and Technology Plan [2020PY044] and the Ministry of Science and Technology of the People's Republic of China Plan (2022ZD0208605).

Declarations

Competing interests

The authors declare no competing interests.

Ethical approval

This study was approved by Clinical Research Ethics Committee of the First Affiliated Hospital, Zhejiang University School of Medicine, and no informed consent was required. This work was conducted in accordance with the Declaration of Helsinki.

Additional information

Correspondence and requests for materials should be addressed to Y.M.

Reprints and permissions information is available at www.nature.com/reprints.

Publisher's note Springer Nature remains neutral with regard to jurisdictional claims in published maps and institutional affiliations.

Open Access This article is licensed under a Creative Commons Attribution-NonCommercial-NoDerivatives 4.0 International License, which permits any non-commercial use, sharing, distribution and reproduction in any medium or format, as long as you give appropriate credit to the original author(s) and the source, provide a link to the Creative Commons licence, and indicate if you modified the licensed material. You do not have permission under this licence to share adapted material derived from this article or parts of it. The images or other third party material in this article are included in the article's Creative Commons licence, unless indicated otherwise in a credit line to the material. If material is not included in the article's Creative Commons licence and your intended use is not permitted by statutory regulation or exceeds the permitted use, you will need to obtain permission directly from the copyright holder. To view a copy of this licence, visit <http://creativecommons.org/licenses/by-nc-nd/4.0/>.

© The Author(s) 2025