

## CASE REPORT

# Osteopenia in a young man associated with the use of tenofovir disoproxil fumarate

Chunmei Li  | Hui Li | Ming Gong | Jia Wei

Department of Infectious disease and hepatology, Hospital of Yunnan University, Yunnan, China

**Correspondence**

Hui Li, Department of Infectious disease and hepatology, Hospital of Yunnan University, No.176 Qingnian Road, Kunming 650000, China.  
Email: lihuidoc@126.com

**Funding information**

There is no funding to report for this submission

**Abstract**

Tenofovir disoproxil fumarate is a recommended first-line therapy for patients with chronic hepatitis B, although the frequent Tenofovir disoproxil fumarate related adverse drug reactions are nephrotoxicity and bone toxicity. We described the case of a 21-year-old Han Chinese male patient with chronic hepatitis B with tenofovir disoproxil fumarate-associated osteopenia. The patient presented osteopenia at the site of his femoral neck with bone mineral density  $0.865\text{g}/\text{cm}^2$  ( $Z = -1.9$ ) in January 2020. Nine months after switching to TAF, bone mineral density at left femoral neck improved to  $0.978\text{g}/\text{cm}^2$  ( $Z = -1.0$ ) in September 2020. Bone mineral density of this patients was normal in January 2021. This is the first report in very young man presenting tenofovir disoproxil fumarate-associated osteopenia.

**KEYWORDS**

bone mineral density, chronic hepatitis B, osteopenia, tenofovir alafenamide fumarate, tenofovir disoproxil fumarate

## 1 | INTRODUCTION

An estimated 257 million people globally are living with chronic hepatitis B (CHB) infection, according to the World Health Organization in 2018.<sup>1</sup> Chronic hepatitis B virus infection is a principal cause of chronic liver disease, cirrhosis, and hepatocellular carcinoma.<sup>2</sup> Treatment's main goals in CHB are to halt disease progression and prevent disease-related complications, achieved by suppression of hepatitis B virus (HBV) DNA replication.<sup>3</sup> Treatment is often lifelong because existing therapies rarely provide a functional cure.<sup>4</sup> To the present date, CHB treatment is either based on nucleos(t)ide analog (NA) or on IFNa, currently pegylated (Peg IFNa).<sup>5</sup> NAs that have been approved for HBV treatment in humans include lamivudine (LAM), adefovir dipivoxil (ADV),

entecavir (ETV), telbivudine (LdT), tenofovir disoproxil fumarate (TDF), and tenofovir alafenamide (TAF), and can be classified into those associated with low barrier against HBV resistance (LAM, ADV, Ltd.) and those with high barrier to HBV resistance (ETV, TDF, TAF).<sup>6,7</sup> The main advantage of treatment with a potent NA with high barrier to resistance (ETV, TDF, and TAF), considered to be the first-line treatment for CHB, is its predictable high long-term antiviral efficacy leading to undetectable HBV-DNA levels in the vast majority of compliant patients as well as its good safety profile.<sup>5-7</sup> Tenofovir disoproxil fumarate (TDF) is a prodrug of tenofovir that was approved as a NA by the United States FDA for use in CHB infection in 2008. TDF is converted to tenofovir by hydrolysis and then phosphorylated by cellular enzymes to tenofovir diphosphate.<sup>8</sup> The common tenofovir-associated adverse

This is an open access article under the terms of the Creative Commons Attribution-NonCommercial-NoDerivs License, which permits use and distribution in any medium, provided the original work is properly cited, the use is non-commercial and no modifications or adaptations are made.

© 2022 The Authors. *Clinical Case Reports* published by John Wiley & Sons Ltd.

drug reactions (ADRs) include asthenia (11%), diarrhea (16%), nausea (11%), headache (1%–10%), pain (12%), and depression (1%–10%). The black box warnings of tenofovir include lactic acidosis, severe hepatomegaly with steatosis, and severe acute exacerbation of hepatitis B after tenofovir discontinuation.<sup>9</sup> Recent population based studies demonstrate that patients with chronic HBV infection are at increased risk for bone loss and osteoporosis compared with age- and gender-matched control subjects without HBV.<sup>10,11</sup> As the chronic hepatitis B population ages, more patients are likely to develop bone loss. A significant and independent association has been reported between the use of TDF and altered excretion of retinol-binding protein (RBP)/creatinine, and subclinical tubular damage in chronic HBV patients.<sup>12</sup> No significant differences were found between TAF and TDF across the bone parameters assessed, fractures, and relevant discontinuations. Only 1 discontinuation due to bone related, study drug associated adverse events was reported through all 14 trials, DEXA scans were performed during most of the studies included in this analysis, and therefore, the study discontinuations due to bone toxicity, although rare, reflect concerning new incidences of fast reduction in BMD or osteoporosis.<sup>13</sup>

## 2 | CASE SUMMARY

### 2.1 | Case presentation

The patient was a 21-year-old Han Chinese (China's largest ethnic group) man who was diagnosed with HBV infection of maternal-neonatal transmission in 2010. His mother

had hepatitis B infection. He had no history of hepatitis A or HIV infection or autoimmune hepatitis. Furthermore, he had no history of smoking or alcohol abuse. He has no concomitant comorbidities such as diabetes mellitus, arterial hypertension, and osteopenia. The patient was not receiving any other medication or supplement, except anti-viral drugs. The patient underwent an operation of bullectomy of lung and correction of pectus excavatum in January 2020. The patient visited the Outpatient Clinic of Hepatitis, Department of Infectious Disease, Hospital of Yunnan University in November, 2016, because of the regular follow-up. Between 2011 and November 2020, several attempts were made to control viral replication with different therapeutic strategies (Figure 1). In 2011, he received treatment with Pegylated interferon-a (Peg IFNa) for 48 weeks at his 11-year-old. Treatment was discontinued because of the ineffectiveness, and then, he had been treated with telbivudine (Ltd.) for several years until November, 2016. We switched the treatment from telbivudine to Lamivudine (LAM) combining adefovir (ADV) therapy because of myalgia and elevated creatine. At the point of switching, he presented HBV-DNA 8980 IU/ml. He suffered erythra and increasing number of stools. In follow-up half a year, the level of HBV-DNA was up to 29500 IU/ml in May, 2017, we considered that he presented a resistance for Lamivudine; so, he received the regimen of Entecavir (ETV), which could be considered as a rescue therapy for patients experienced LAM and developed resistance. He visited our outpatient regularly, viral load of HBV was, respectively, 166 IU/ml in August 2017, 127 IU/ml in February 2018, and 472 IU/ml in July 2018. Viral replication was not suppressed effectively while

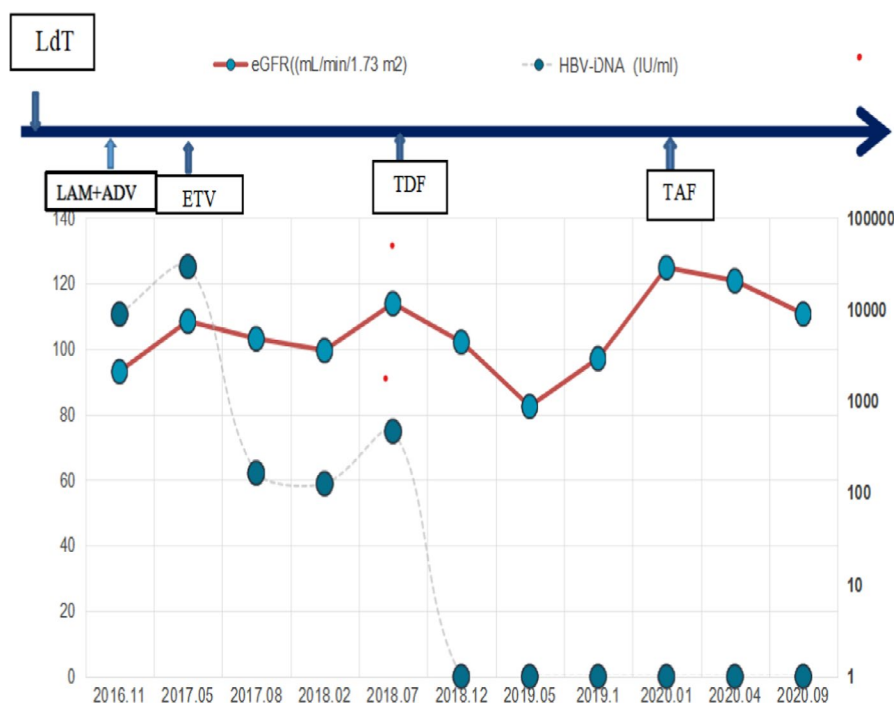


FIGURE 1 Chronological sequence of therapeutic strategies

the treatment of ETV, the patient started ETV combining TDF therapy in July 2018. During 20 weeks of combination therapy, HBV-DNA declined from 472 IU/ml in July 2018 to less than 100 IU/ml in December 2018 for the first time. HBsAg levels and HBeAg status remained unchanged, as did liver function tests, which were within the normal range all the time. Several laboratory indicators were monitored every 5 months up to January 2020. No significant changes were observed for Cr, Na, K, blood phosphate, and blood calcium. HBV-DNA was undetectable level (<20 IU/ml) in January 2020. Biochemical, virologic, and renal parameters of patient during the treatment (Table 1).

## 2.2 | Differential diagnosis

This patient had a history of pectus excavatum, and hepatitis B virus infection is risk factor of bone loss. We started to focus on the bone safety of this patient, BMD test was performed for this patient. Dual-energy X-ray absorptiometry (DXA) scan of neck of femur and lumbar spine was done. BMD at sit left hip joint and femoral neck was, respectively, 0.891 g/cm<sup>2</sup>, 0.865 g/cm<sup>2</sup> in January 2020. According to the international diagnostic criteria of osteoporosis, the patient's bone mass was close to abnormal. The patient had a thyroid function test on December 31, 2019. T3, T4, TSH, FT3, FT4 were, respectively, 0.9 ng/ml, 81.44 ng/ml, 1.19 uIU/ml, 5.44 pmol/L, 12.96 pmol/L. Thyroid function of this patient was within the normal range. This patient was generally nourished, without diabetes, no connective tissue disease and gastrointestinal malabsorption, and no hematologic diseases. The patient had no tooth loss and gingivitis. Folic acid and vitamin B12 tests also showed that the patient did not lack folic acid and vitamin B12. The patient is a student. The school has basic outdoor activities. He did not take any drugs orally except TDF. So, this patient switched TDF to TAF from this point because of the osteopenia. Therefore, we considered the patient's bone mass reduction due to oral tenofovir and adefovir dipivoxil.

## 2.3 | Outcome and follow-up

He suffered no immediate adverse drug effects and tolerated this regimen well. At the 8-month follow-up after TAF, the bone mass of his left hip joint and femoral neck was 0.932 g/cm<sup>2</sup>, 0.978 g/cm<sup>2</sup> in September 2020. One year after switching to TAF, the bone mass of his left hip joint and femoral neck was 0.967 g/cm<sup>2</sup>, 0.931 g/cm<sup>2</sup> in January 2021 (Table 2). HBV-DNA was undetectable (<10 IU/ml).

There were no abnormalities in liver function, renal function, blood calcium, and blood phosphorus.

## 3 | DISCUSSION

The aim of CHB treatment was to control viral replication, thereby reducing the risk of complications such as liver failure, cirrhosis, and hepatocellular carcinoma. CHB treatment is often based on the long-term NAs use, with the following drugs being approved: LAM, ETV, Ltd., ADV, TDF, and TAF, of which ETV, TDF, and TAF are considered to be the first-line drugs, due to its potency and high genetic barrier to resistance. Identification of potential associated AEs, even if with low incidence, might be a key factor in improving adherence and outcomes. Both entecavir and tenofovir (TDF and TAF) have minimal risk of drug resistance in NA-naive patients; tenofovir also has a very low rate of drug resistance in NA-experienced patients.<sup>14</sup> TDF is a highly potent inhibitor of HBV-DNA replication and recommended as a first-line treatment choice in CHB by the current clinical guidelines due to the absence of drug resistance.<sup>15</sup> While the long-term use of TDF has been associated with bone and renal toxicity in some patients, adverse event concern within TDF use is the bone mass reduction. In randomized clinical trials, a great loss of bone mineral density (BMD) had been well-described in patients with HIV infection treated with TDF.<sup>16,17</sup> In a 96 weeks analysis that includes both HBeAg-positive and HBeAg-negative patients, TAF treatment was associated with significantly smaller mean percentage changes in BMD at the hip (−0.33 vs. −2.51%,  $p < 0.001$ ) and spine (−0.75 vs. −2.57%,  $p < 0.001$ ) than using TDF. A higher proportion of subjects treated with TDF also experienced >3% declines in hip and spine BMD compared with TAF treated patients (spine: 45% vs. 25%,  $p < 0.001$  and hip: 39% vs. 14%,  $p < 0.001$ ).<sup>18</sup> By multivariate analysis, independent predictors for >3% BMD decline in hip or spine at week 96 included study drug treatment (TAF vs TDF, age (<50 vs. ≥50 years), gender (female vs male), and baseline renal function. To the best of our knowledge, a case of tooth loss associated with the use of tenofovir disoproxil fumarate has been reported, a 41-year-old Han Chinese man with CHB presented with halitosis, gingival swelling, and tooth loss after TDF use. After excluding the possibility of other drug related ADRs, TDF was considered a possible cause and switched with tenofovir alafenamide fumarate (TAF). After 6 months, the oral symptoms disappeared, with no additional tooth loss.<sup>19</sup> Tenofovir-associated loss of bone mineral density has also been observed with children and adolescents.<sup>20</sup>

For our case, combining adefovir dipivoxil and lamivudine for several years, HBV-DNA continued

TABLE 1 Time course of efficacy and safety variables during treatment

Variables	December 2018	May 2019	October 2019	January 2020	April 2020	September 2020	Reference range
WBCs ( $\times 10^9/L$ )	/	/	/	7.14	/	7.66	4.0–10
Neutrophils (%)	/	/	/	62	/	67.8	40.0–75.0
Albumin (g/L)	46	46	47	46	49	49.1	34–54
Globulin (g/L)	46.2	46.5	47	46.7	49.9	27.6	15–35
Albumin to globulin ratio	1.94	1.88	1.64	2.16	1.57	1.78	1.20–2.50
Alkaline phosphatase (U/L)	108	100	118	111	131	121	40–150
ALT (U/L)	56	16	28	38	16	12	5–40
AST (U/L)	32	20	27	37	25	22	8–40
r-GT (U/L)	18	11	16	17	21	20	11–50
Prealbumin (mg/L)	306	229	356	369	353	373	200–400
TBA ( $\mu\text{mol/L}$ )	1.7	2.7	4.6	1.7	2.9	1.8	$\leq 10$
TBIL ( $\mu\text{mol/L}$ )	6.1	5.3	12.2	8.1	5.2	7.5	3.0–21
TP (g/L)	70	71.3	75.6	68.3	81.6	76.7	60–83
Blood urea (mmol/L)	4.66	5.17	5.27	4.48	6.39	5.84	2.9–8.2
Serum uric acid (mmol/L)	419	433	453	399	508	492	0.1–0.42
Serum creatinine ( $\mu\text{mol/L}$ )	93	111	97	76	80	86	50–130
eGFR ( $\text{mL/min/1.73 m}^2$ )	102.16	82.49	97.09	124.85	120.85	110.73	$\geq 90$
Serum phosphorus (mmol/L)	1.25	1.01	1.07	1.04	0.88	0.98	0.74–1.52
Serum potassium (mmol/L)	4.71	4.6	4.66	4.22	4.43	4.35	3.5–5.2
Serum magnesium (mmol/L)	0.86	0.97	0.98	0.79	0.88	0.87	0.8–1.1
Serum calcium (mmol/L)	2.48	2.47	2.51	2.09	2.46	2.43	2.08–2.6
Serum sodium (mmol/L)	139.5	137.9	139.4	134.1	139.2	139.1	136–145
Blood chloride (mmol/L)	107.7	104	1.4.9	100.3	106.6	105.1	96–108
Urine $\beta$ -2-microglobulin ( $\mu\text{g/mL}$ )	/	/	0.211	0.102	0.115	0.127	$< 0.195$
LDH (U/L)	/	200	160	202	219	219	109–245
CK (U/L)	/	133	135	136	128	140	38–174
AFP ( $\mu\text{g/L}$ )	1.80	3.03	2.22	1.8	1.8		$< 10.00$
HBeAg (s/co)	14.24	6.93	7.5	6.66	6.9	8.32	0–1
Anti-HBe (s/co)	Negative	Negative	Negative	Negative	Negative	Negative	$< 1.0$ (Positive)
HBsAg (IU/mL)	26697	20654	22439	18880	20362	21278	/
HBV-DNA (IU/mL)	$< 100$	$< 100$	$< 100$	$< 20$	$< 100$	$< 10$	/

Abbreviations: AFP, alpha-fetoprotein; ALT, alanine aminotransferase; anti-HBe, hepatitis B virus e antibody; AST, aspartate aminotransferase; CK, creatine kinase; eGFR, estimated glomerular filtration rate; HBeAg, hepatitis B virus e antigen; HBsAg, hepatitis B surface antigen; HBV-DNA, hepatitis B virus DNA quantification; LDH, lactate dehydrogenase; r-GT, r-glutamyl transferase; TBA, total bile acid; TBIL, total bilirubin; TP, total protein; WBC, white blood cell.

to be positive, we considered that there was a resistance to lamivudine; so, entecavir was prescribed for this patient. During the treatment of entecavir, the virus rebounded; so, we switched to tenofovir fumarate dipivoxil tablets from entecavir. In January 2020, bone mineral density examination showed bone mass

decreased. Unfortunately, we did not test his BMD before switching to TAF. In case of bone loss caused by other diseases was excluded. We switched to tenofovir alafenamide fumarate (TAF). TAF was designed to have a greater plasma stability that allows a more efficient delivery of tenofovir to the liver cells. This also allows

TABLE 2 Changes in bone mineral density

Position	BMD(g/cm <sup>2</sup> )	Z value	BMD(g/cm <sup>2</sup> )	Z value	BM(g/cm <sup>2</sup> )	Z value
	January 2020		September 2020		January 2021	
Left femoral neck	0.865	-1.9	0.978	-1.0	0.931	-1.3
Left hip joint	0.891	-1.5	0.932	-1.2	0.967	-1

a lower orally administered dose of TAF than TDF and reduces the systemic exposure of tenofovir in the body. Thus, TAF preserves the antiviral efficacy of TDF with improved renal and bone safety.<sup>21</sup>

## 4 | CONCLUSION

Long-term use of TDF can lead to bone loss and even osteoporosis in young patient; therefore, healthcare staff must pay attention to the bone safety of the young patient, not only in old patient, and avoid using TDF for patients with previous calcium deficiency related diseases. Bone mineral density should be examined to confirm whether the patient have calcium loss and determine the possible relationship between TDF and calcium loss.

## ACKNOWLEDGMENT

None.

## CONFLICT OF INTEREST

All the authors declare that they have no competing interest.

## AUTHOR CONTRIBUTION

Li Hui was involved in patient's care. Gong Ming collected clinical data. Li Chunmei drafted the manuscript. Wei Jia was involved in manuscript editing. All authors read and approved the final manuscript.

## ETHICAL APPROVAL

None.

## CONSENT

Written informed consent was obtained from the patient to publish this report in accordance with the journal's patient consent policy.

## DATA AVAILABILITY STATEMENT

Data sharing is not applicable as no new data were generated.

## ORCID

Chunmei Li  <https://orcid.org/0000-0001-7984-0165>

## REFERENCE

1. WHO. *Hepatitis B*. Electronic address eeeWorld Health Organization; 2000. <https://www.who.int/news-room/fact-sheets/detail/hepatitis-b>
2. Pan CQ, Zhang JX. Natural history and clinical consequences of hepatitis B virus infection. *Int J Med Sci*. 2005;2(1):36-40.
3. Lo AO, Wong GL. Current developments in nucleoside/nucleotide analogues for hepatitis B. *Expert Rev Gastroenterol Hepatol*. 2014;8(6):607-622.
4. Locarnini S, Hatzakis A, Chen DS, Lok A. Strategies to control hepatitis B: public policy, epidemiology, vaccine and drugs. *J Hepatol*. 2015;62(1 Suppl):S76-86.
5. Lok AS, McMahon BJ, Brown RS, et al. Antiviral therapy for chronic hepatitis B viral infection in adults: a systematic review and meta-analysis. *Hepatology*. 2016;63(1):284-306.
6. European Association for the Study of the Liver. Electronic address eee, European association for the study of the L. EASL 2017 clinical practice guidelines on the management of hepatitis B virus infection. *J Hepatol*. 2017;67(2):370-398.
7. Terrault NA, Bzowej NH, Chang KM, et al. AASLD guidelines for treatment of chronic hepatitis B. *Hepatology*. 2016;63(1):261-283.
8. Fontana RJ. Side effects of long-term oral antiviral therapy for hepatitis B. *Hepatology*. 2009;49(5 Suppl):S185-S195.
9. Grigsby IF, Pham L, Mansky LM, Gopalakrishnan R, Carlson AE, Mansky KC. Tenofovir treatment of primary osteoblasts alters gene expression profiles: implications for bone mineral density loss. *Biochem Biophys Res Comm*. 2010;394(1):48-53.
10. Baeg MK, Yoon SK, Ko SH, et al. Males seropositive for hepatitis B surface antigen are at risk of lower bone mineral density: the 2008-2010 Korea national health and nutrition examination surveys. *Hepatol Int*. 2016;10(3):470-477.
11. Chen CH, Lin CL, Kao CH. Association between chronic hepatitis B virus infection and risk of osteoporosis: a nationwide population-based study. *Medicine*. 2015;94(50):e2276.
12. Min IS, Lee CH, Shin IS, et al. Treatment outcome and renal safety of 3-year tenofovir disoproxil fumarate therapy in chronic hepatitis B patients with preserved glomerular filtration rate. *Gut Liv*. 2019;13(1):93-103.
13. Pilkington V, Hughes SL, Pepperrell T, et al. Tenofovir alafenamide vs. tenofovir disoproxil fumarate: an updated meta-analysis of 14 894 patients across 14 trials. *AIDS (London, England)*. 2020;34(15):2259-2268.
14. Terrault NA, Lok ASF, McMahon BJ, et al. Update on prevention, diagnosis, and treatment of chronic hepatitis B: AASLD 2018 hepatitis B guidance. *Hepatology*. 2018;67(4):1560-1599.
15. Sarin SK, Kumar M, Lau GK, et al. Asian-Pacific clinical practice guidelines on the management of hepatitis B: a 2015 update. *Hepatol Int*. 2016;10(1):1-98.

16. Gill US, Zissimopoulos A, Al-Shamma S, et al. Assessment of bone mineral density in tenofovir-treated patients with chronic hepatitis B: can the fracture risk assessment tool identify those at greatest risk? *J Infect Dis*. 2015;211(3):374-382.
17. Bedimo R, Maalouf NM, Zhang S, Drechsler H, Tebas P. Osteoporotic fracture risk associated with cumulative exposure to tenofovir and other antiretroviral agents. *AIDS (London, England)*. 2012;26(7):825-831.
18. Seto WK, Asahina Y, Brown TT, et al. Improved bone safety of tenofovir alafenamide compared to tenofovir disoproxil fumarate over 2 years in patients with chronic HBV infection. *Clin Gastroenterol Hepatol*, 2018;S1542-S3565(18):30633-30635.
19. Jianfei L, Ling L, Yu Z, Jiming Z, Bin W. Tooth loss associated with the use of tenofovir disoproxil fumarate. *J Clin Pharm Ther*. 2020;45(6):1478-1482.
20. Purdy JB, Gafni RI, Reynolds JC, Zeichner S, Hazra R. Decreased bone mineral density with off-label use of tenofovir in children and adolescents infected with human immunodeficiency virus. *J Pediatr*. 2008;152(4):582-584.
21. Agarwal K, Brunetto M, Seto WK, et al. 96 weeks treatment of tenofovir alafenamide vs. tenofovir disoproxil fumarate for hepatitis B virus infection. *J Hepatol*. 2018;68(4):672-681.

**How to cite this article:** Li C, Li H, Gong M, Wei J. Osteopenia in a young man associated with the use of tenofovir disoproxil fumarate. *Clin Case Rep*. 2022;10:e05641. doi:[10.1002/ccr3.5641](https://doi.org/10.1002/ccr3.5641)