

Evaluation of macular and peri-papillary blood vessel density following uncomplicated phacoemulsification in diabetics using optical coherence tomography angiography

Noha Tarek, Noha M Khalil, Hesham F ElSheikh, Shireen M Shousha

Purpose: The aim of this study was to evaluate the macular and peri-papillary blood vessel density following uncomplicated phacoemulsification in diabetics using optical coherence tomography angiography (OCT-A). **Methods:** An observational case-control study was conducted on 60 patients eligible for phacoemulsification, divided equally into diabetic and control groups. Both study groups were matching in sex, age, and axial length. We excluded diabetic patients of any form of macular edema or treatment history for macular edema. All study participants were subjected to preoperative OCT and OCT-A, which was repeated for all study population 1 month postoperatively. **Results:** We had a mean age of 54.5 ± 6.34 years in the non-diabetic group and 57.2 ± 4.09 years in the diabetic group ($P = 0.06$). There was a significant increase in the mean value of the macular blood vessels density in the nasal area in both study groups ($P = 0.047$ in non-diabetic group, $P = 0.002$ in the diabetic group). The percentage of the radial peripapillary capillary plexus vessel density (RPCP VD) change was non-significant on comparing the results for the diabetic group (mean preoperative value = 52.8 ± 4.47 , postoperative = 52.0 ± 4.59 , $P = 0.204$, Δ is the preoperative-postoperative value = 0.8), and also was non-significant for the non-diabetic group (mean preoperative value = 50.9 ± 4.89 , postoperative = 52.1 ± 4.89 , $P = 0.090$, $\Delta = -1.3$). On comparing the results of the diabetic and nondiabetic groups, the RPCP VD Δ was significantly different ($P = 0.034$). **Conclusion:** Uncomplicated phacoemulsification results in increase of the nasal macular blood vessel density in the normal population and in diabetic patients without retinopathy.

Key words: Diabetes, macular vessel density, optical coherence tomography- angiography, phacoemulsification, radial peripapillary capillary plexus

A point of major concern in diabetic patients following cataract extraction is the detection and monitoring of postoperative vascular changes as accelerated retinopathy following cataract extraction might be considered a major risk factor for the post-operative development and progression of macular edema. Optical coherence tomography (OCT) does not provide direct information regarding retinal vascular changes, so fluorescein angiography (FA) and indocyanine green angiography (ICGA) still remain the standard imaging modalities to visualize and quantify retinal vascular changes.^[1] However, FA and ICGA have limitations as they involve intravenous dye administration, and are time-consuming (up to 20 minutes). Moreover, although the examined fields are wide, yet the provided scans are of low resolution, and 2 dimensional (2-D) making the quantification of vascular changes difficult. The introduction of OCT angiography (OCTA) has addressed most of these limitations and has provided rapid, non-invasive, high-resolution 3-D scans of the retinal and choroidal vasculature.^[1] This study aims at investigating the effect of phacoemulsification on the retinal vasculature in the macular and peripapillary areas in diabetic using OCT-A.

Methods

This is an observational case-control study. The study protocol was approved by the Cairo University Research Ethical Committee. The study and data collection conformed to all local laws and were compliant with the principles of the declaration of Helsinki 1964 and its later amendments. All data confidentiality was respected. 60 patients (60 eyes) eligible for elective cataract surgery (phacoemulsification) were recruited from the ophthalmology clinics in Cairo university hospitals in the interval between July 2018 and March 2019. The patients were divided into two groups:

Group A: 30 diabetic patients.

Group B: 30 non-diabetic patients.

Patients were included in the study when media opacity due to cataract allowed scanning by OCT and OCT-A. For both groups, we excluded patients with other retinal pathologies:

This is an open access journal, and articles are distributed under the terms of the Creative Commons Attribution-NonCommercial-ShareAlike 4.0 License, which allows others to remix, tweak, and build upon the work non-commercially, as long as appropriate credit is given and the new creations are licensed under the identical terms.

For reprints contact: WKHLRPMedknow_reprints@wolterskluwer.com

Cite this article as: Tarek N, Khalil NM, ElSheikh HF, Shousha SM. Evaluation of macular and peri-papillary blood vessel density following uncomplicated phacoemulsification in diabetics using optical coherence tomography angiography. Indian J Ophthalmol 2021;69:1173-7.

Access this article online

Website:

www.ijo.in

DOI:

10.4103/ijo.IJO_2187_20

Quick Response Code:



Faculty of Medicine, Cairo University, Cairo, Egypt

Correspondence to: Dr. Shireen M Shousha, MD, 60 Sudan Street, ElDokki, Giza, Egypt. E-mail: Shireen.Shousha@kasralainy.edu.eg

Received: 04-Jul-2020

Revision: 23-Sep-2020

Accepted: 10-Dec-2020

Published: 30-Apr-2021

glaucoma, uveitis, amblyopia, or other systemic diseases, including diabetes mellitus for group B. In the diabetic group, we excluded cases with any form of macular edema as well as patients showing any form of diabetic retinopathy including hard exudates or hemorrhages to avoid unreliable scans which could result from their shadowing effect, we excluded scan quality less than 7/10. Also, cases who received previous treatment for diabetic retinopathy were excluded from our study as well. Both study groups were matching as regards age, sex, and axial length. Written and informed consent were obtained for all study participants after explaining the nature and the possible complications of cataract surgery and imaging modalities. All the study participants were subjected pre-operatively to history taking, fasting blood sugar (FBS) measurement, HbA1c, full ophthalmological assessment, and biometry (Sonomed, Escalon, PacScan Plus, India) as a part of pre-operative preparation for cataract surgery.

Fluorescein angiography (Topcon TRC-50DX, Topcon medical system inc., 2015) was done to the diabetic patients to exclude patients showing any form of macular edema or diabetic retinopathy. OCT and OCTA were performed pre-operatively and 1-month postoperatively for all study groups. All patients were instructed to focus on a fixation target. OCTA images were obtained using the RTVue XR Avanti (AngioVue; Optovue Inc, Fremont, California, USA) machine and the incorporated AngioVue OCTA system. The scans included in the study were of high signal strength more than 7/10 and they were carefully inspected for motion artifacts to ensure that the OCTA findings were not segmentation artifacts. Automatic segmentation of intraretinal layers was done using the automated software of the machine. The angiogram size of 6*6 mm for the angio retina scan and 4.5*4.5 mm for the angio disc scan were chosen. Vessel density measurements were performed on the selected images; early treatment diabetic retinopathy study (ETDRS) grid overlay is centered on the foveal avascular zone (FAZ) of the Superficial capillary plexus (SCP) and then the software automatically measured the vessel density of the SCP in percentage and displayed it; quantitatively in tables and qualitatively in color-coded vessel density maps, where the areas of severe ischemia are color coded as dark blue. The macular vessel density was further evaluated on the co-registered OCT en face intensity images and was correlated with the central macular thickness measured by OCT B-scan images. We took 3 measurements for each eye in the same setting and the resultant macular vessel density percentage is the average value of the three to substitute for inter-scan variability. In the peri-papillary area, the average radial peri-papillary capillary plexus vessel density percentage (RPCP VD) and the average retinal nerve fiber layer (RNFL) thickness on the co-registered OCT B-scan images were taken. OCT and OCT-A were done by a single operator (masked) and phacoemulsification surgery was done for all patients by a single surgeon (author #4). Patients underwent standard phacoemulsification : 2 side port incisions , superior 2.8 mm wound , with the use of visco-cohesive viscoelastic (1% sodium hyaluronate, Healon ®; Pharmacia), stop and chop techniques^[2] using infinity phacomachine, Alcon, USA), with in-the-bag intraocular lens implantation of a single piece foldable hydrophobic acrylic intraocular lens (Acrysof, Alcon, USA). All study cases had the same postoperative treatment in form of combined

tobramycin and dexamethasone (TobraDex eye drops and eye ointment, Novartis, USA) tapered gradually over one month. Complicated cases were excluded from the study.

Statistical analysis

Statistical analysis was performed using SPSS 16 for Windows (SPSS Inc, Chicago, Illinois, USA). Quantitative variables were represented in the form of mean and standard deviation, while categorical variables were represented in the form of number and percentage. Chi square and student t tests were used for analysis. "P" of <0.05 was considered statistically significant. Δ for a variable was calculated by subtracting the preoperative value from the postoperative value. Intra-observer variability was judged by calculation of the mean of differences between repeated measurements in twenty randomly selected patients then intraclass correlation coefficient (ICC) was obtained and is accepted, ICC = 0.96 (95% CI, 0.91–0.98).

Results

Study patients' demographics are shown in Table 1. The diabetic group had a mean duration of diabetes of 4.5 (\pm 3.16) years. Ten patients of them (33%) were Insulin dependent. The excluded patients from our study either due to presence of another retinal pathology like age related macular degeneration or presence of macular edema/ischemia or history of treatment to diabetic retinopathy were all from the elderly population.

We analyzed the pre and post-operative results for both study groups, for the non-diabetic group, we had the following results: Central macular thickness (CMT) (preoperative = 243.5 \pm 29.92 μ m, postoperative = 240.1 \pm 35.41 μ m, P = 0.616, Δ CMT = 3.4 μ m), RNFL thickness (preoperative = 104.1 \pm 16.95 μ m, postoperative = 109.1 \pm 23.97 μ m, P = 0.060, Δ RNFL = -5.0 μ m), and RPCP VD (preoperative = 50.9 \pm 4.89%, postoperative = 52.1 \pm 4.89%, P = 0.090, Δ RPCP VD = -1.3%). The diabetic group had the following preoperative and postoperative results: CMT (preoperative = 235.8 \pm 22.77 μ m, postoperative = 241.3 \pm 25.19 μ m, P = 0.350, Δ CMT = -5.5 μ m), RNFL thickness (preoperative = 113.1 \pm 25.89 μ m, postoperative = 112.6 \pm 23.36 μ m, P = 0.790, Δ RNFL = 0.5 μ m), and RPCP VD (preoperative = 52.8 \pm 4.47%, postoperative = 52.0 \pm 4.59%, P = 0.204, Δ RPCP VD = 0.80%). On comparing the results of the diabetic and non-diabetic groups, only the RPCP VD Δ was significantly different [Table 2].

For the sake of statistical analysis of the macular area vessel density we divided it into: Sub foveal (central) area, parafoveal area (will be further subdivided into: Nasal, temporal, inferior and superior areas), and perifoveal area (will be further subdivided into: Nasal, temporal, inferior and superior areas). On analysis an increase of vessel density was noted in most of areas [Fig. 1] but only the nasal areas showed a statistically significant change as regards the macular blood vessels density in both study groups [Tables 3 and 4].

Discussion

The relationship between cataract extraction and the post-operative progression of diabetic retinopathy has been commonly investigated in literature, yet with no conclusive results.^[3,4] In 2018, Zhennan Zhao, *et al.*,^[5] conducted a prospective study on 32 non-diabetic patients to evaluate the changes in macular vasculature after uncomplicated

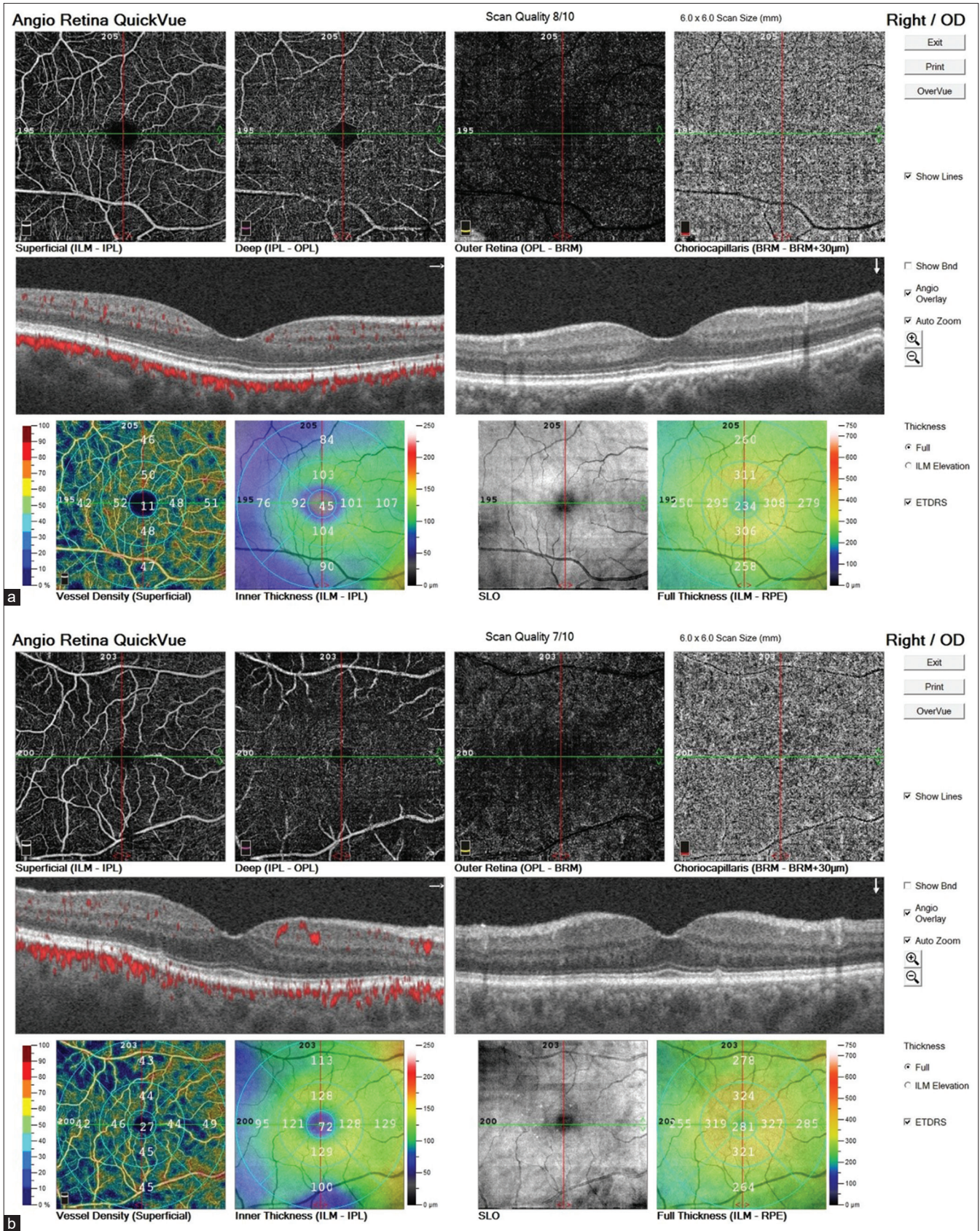


Figure 1: OCT-A of study patient no. 36 diabetic group. (a) is the preoperative and (b) is the postoperative macular vessel density. Note an increase in the vessel density in all areas postoperatively

Table 1: Demographics of our study population

Variable	Non diabetic group n=30	Diabetic group n=30	P
Mean age, year	54.50±6.34	57.20±4.09	0.060
Proportion of Female gender	73.30%	76.60%	0.766
Laterality (OD)	17 (56.70%)	20 (66.70%)	0.426
Mean FBS, mg/dL	91.8±8.97	199.9±40.69	<0.001
Mean AXL, mm	23.3±1.19	22.9±1.02	0.061
Mean HbA1C, mmol/mol	5.1±0.20	7.7±0.35	<0.001

FBS=Fasting blood sugar, AXL=Axial length, OD=Right eye

Table 2: Preoperative and postoperative results (Central macular thickness and RNFL thickness measured by OCT and RPCP VD measured by OCT A) in Both study groups

Variable	Non diabetic group n=30	Diabetic group n=30	P
Mean Central macular thickness Pre, μ	243.5±29.92	235.8±22.77	0.265
Mean RNFL thickness Pre, μ	104.1±16.95	113.1±25.89	0.114
Mean RPCP VD Pre, Percentage	50.9±4.89	52.8±4.47	0.108
Central macular thickness Δ (pre-post), μ	3.4	-5.5	0.320
RNFL thickness Δ (pre-post), μ	-5.0	0.5	0.097
RPCP VD Δ (pre-post), percentage	-1.3	0.80	0.034

Data are presented as mean±standard deviation. RNFL thickness=Retinal nerve fiber layer thickness, RPCP VD=Radial peripapillary capillary plexus vessel density, Pre=Preoperative, Post=Postoperative

Table 3: Macular area vessel density in the diabetic group

Zone	Preoperative	Postoperative	P
Central	13.37±6.45	13.70±11.47	0.082
Superior parafovea	44.63±10.32	44.23±7.40	0.338
Inferior parafovea	42.57±10.96	42.87±6.74	0.555
Nasal parafovea	41.23±8.55	41.83±7.09	0.647
Temporal parafovea	43.47±8.84	40.73±9.27	0.257
Superior perifovea	42.33±8.55	43.37±7.72	0.170
Inferior perifovea	42.47±8.33	44.07±8.00	0.789
Nasal perifovea	45.70±6.80	46.5±7.54	0.002
Temporal perifovea	38.07±8.02	37.47±7.98	0.259

Data are presented as mean±standard deviation. Macular blood vessel density in each zone is represented by percentage of the vascularized area

Table 4: Macular area vessel density in the non-diabetic patients' group

Zone	Preoperative	Postoperative	P
Central	9.27±7.37	11.2±6.40	0.740
Superior parafovea	44.53±12.65	46.10±11.27	0.260
Inferior parafovea	42.83±12.35	44.00±10.81	0.436
Nasal parafovea	37.07±7.29	41.90±10.36	0.047
Temporal parafovea	39.97±7.95	43.77±8.16	0.234
Superior perifovea	47.13±8.69	46.50±8.78	0.595
Inferior perifovea	47.37±9.64	49.33±10.80	0.810
Nasal perifovea	49.97±7.42	50.63±8.52	0.197
Temporal perifovea	39.63±8.36	40.11±7.11	0.136

Data are presented as mean±standard deviation. Macular blood vessel density in each zone is represented by percentage of the vascularized area

phacoemulsification surgery using OCT-A. They showed an agreement to our results as regard the post-operative increased VD, however, unlike their study, our study specified the region of increased VD which was the nasal area. In their study, they attributed the post-operative change in the VD to the decline in the IOP. Another theory was postulated by Hilton *et al.*,^[6] who reported an increased pulsatile ocular blood flow after cataract surgery due to postoperative inflammation with the markedly upregulated expression of pro-inflammatory genes and proteins, such as chemokine ligand 2 and interleukin-1b detected in the neurosensory retina. These cytokines were reported to cause vessel dilation and a breakdown of the blood-retinal barrier. However, Hilton *et al.* study focused on pulsatile ocular blood flow, which comes mainly from the choroid.^[6] Another possible explanation for the change in macular blood flow could be attributed to the increase in light exposure after cataract surgery. Whether the increased light exposure could lead to increased activity and more metabolic demands in the retina or not, this was not clear.^[7] J. M. Katsimpris, *et al.*,^[8] evaluated the central macular thickness by OCT in diabetic and non-diabetic patient following cataract surgery, they showed agreement with our study as regard the increase of post-operative central macular thickness in diabetic patients, however, their study disagreed with ours as regard the post-operative central macular thickness in the control group, which showed no difference on long run follow up. This disagreement could be explained by their longer follow up period (up to 12 months). The main reason OCT A was done in our study after the first post-operative month, was to attribute the possibly occurring vascular and thickness changes to the effect of phacoemulsification rather than the natural course of the disease.

In 2017, Bhaskar Jha, *et al.*^[9] did a prospective study on 100 non-diabetic healthy patients to assess the effect of phacoemulsification on measurement of retinal nerve fiber layer

and optic nerve head parameters using spectral-domain-OCT. They showed an increase in RNFL thickness following cataract surgery in non-diabetic patients. Their results were comparable to the results of Cheng *et al.*^[10] and El-Ashry *et al.*^[11] who also reported a significant increase in RNFL thickness, this increase could be attributed to the release of inflammatory mediators which may lead to edema of the RNFL.^[11] Bhaskar Jha, *et al.*^[9] attributed the increase in post-operative RNFL thickness to improvement in transmittance and reflectivity of the RNFL boundary after removal of opacified media and the intra-ocular lens power magnification rather than actual RNFL thickening after cataract surgery. Van Dijk *et al.*^[12] showed RNFL thinning in diabetic patients. The RNFL loss in diabetic retina has been attributed to the decreased perfusion of the retina and the optic nerve head (ONH) which may cause greater ischemia leading to structural damage to the ganglion cells.^[12] The exact mechanisms for inner retinal loss were not clear but have been implicated to lower perfusion and higher metabolic demands of the inner retina which make it more vulnerable to the metabolic stress induced by diabetes.^[12] Yunkao Zeng, *et al.*^[13] conducted a study to evaluate early retinal neurovascular impairment in patients with diabetes without clinically detectable retinopathy, they showed a decrease of the peri-papillary VD in the diabetic patients when compared to the control. The change in VD might be due to the disruption of retinal neurovascular autoregulation, regulating the VD in response to metabolic demands.^[14] Besides, in diabetics, chronic hyperglycemia leads to capillary endothelial cell injury which may lead to reduced VD in the retina.^[13] There were some limitations in our study as regard the relatively small sample size and the relatively short follow up period. In addition, the presence of normative data for the OCTA will help to standardize the results and allow for accurate assessment. An idea for further research is repetition of the OCT-A after a period of time to assure that any changes are surgery induced.

To the best of our knowledge, no previous studies specified the affected zones in the macula and addressed together with the peripapillary changes. We could attribute the increased nasal zone mean vascular density to the possibility of presence of the cilioretinal artery arising from the temporal aspect of the optic disc, it is known to be present in 6-32% of the population and supplying the temporal retina in most of the cases,^[15] with the main part of the artery being present in the nasal part of the macula. Unfortunately, we did not note the presence of the cilioretinal artery before the start of our research, however the increased mean macular blood vessel density was noted postoperatively in almost all zones although only the nasal zone showed a low significant difference [Tables 3 and 4].

Conclusion

We could conclude that phacoemulsification increases the macular blood vessel density in diabetics without retinopathy as well as in matched controls.

Financial support and sponsorship

Nil.

Conflicts of interest

There are no conflicts of interest.

References

- de Carlo TE, Romano A, Waheed NK, Duker JS. A review of optical coherence tomography angiography (OCTA). *Int J Retina Vitreous* 2015 Apr 15;1:5.
- Koch ES, Katzen LE. Stop and chop phacoemulsification. *J Cataract Refract Surg* 1994;20:566-70.
- Henricsson M, Heijl A, Janzon L. Diabetic retinopathy before and after cataract surgery. *Br J Ophthalmol* 1996;80:789-93.
- Romero-Aroca P, Fernández-Ballart J, Almena-García M, Méndez-Marín I, Salvat-Serra M, Buil-Calvo JA. Nonproliferative diabetic retinopathy and macular edema progression after phacoemulsification: Prospective study. *J Cataract Refract Surg* 2006;32:1438-44.
- Zhao Z, Wen W, Jiang C, Lu Y. Changes in macular vasculature after uncomplicated phacoemulsification surgery: Optical coherence tomography angiography study. *J Cataract Refractive Surgery* 2018;44:453-58.
- Hilton EJR, Hosking SL, Gherghel D, Embleton S, Cunliffe IA. Beneficial effects of small-incision cataract surgery in patients demonstrating reduced ocular blood flow characteristics. *Eye* 2005;19:670-5.
- Artigas JM, Felipe A, Navea A, Fandino A, Artigas C. Spectral transmission of the human crystalline lens in adult and elderly persons: Color and total transmission of visible light. *Invest Ophthalmol Vis Sci* 2012;53:4076-84.
- Katsimpris JM, Petropoulos IK, Zoukas G, Patokos T, Brinkmann CK, Theoulakis PE. Central foveal thickness before and after cataract surgery in normal and in diabetic patients without retinopathy. *Klin Monbl Augenheilkd* 2012;229:331-7.
- Jha B, Sharma R, Vanathi M, Agarwal T, Sidhu T, Tomar A, *et al.* Effect of phacoemulsification on measurement of retinal nerve fiber layer and optic nerve head parameters using spectral-domain-optical coherence tomography. *Oman J Ophthalmol* 2017;10:91-5.
- Cheng CS, Natividad MG, Earnest A, Yong V, Lim BA, Wong HT, *et al.* Comparison of the influence of cataract and pupil size on retinal nerve fiber layer thickness measurements with time-domain and spectral-domain optical coherence tomography. *Clin Exp Ophthalmol* 2011;39:215-21.
- El-Ashry M, Appaswamy S, Deokule S, Pagliarini S. The effect of phacoemulsification cataract surgery on the measurement of retinal nerve fiber layer thickness using optical coherence tomography. *Curr Eye Res* 2006;31:409-13.
- Van Dijk HW, Kok PH, Garvin M, Sonka M, Devries JH, Michels RP, *et al.* Selective loss of inner retinal layer thickness in type 1 diabetic patients with minimal diabetic retinopathy. *Invest Ophthalmol Vis Sci* 2009;50:3404-9.
- Zeng Y, Cao D, Yu H, Yang D, Zhuang X, Hu Y, *et al.* Early retinal neurovascular impairment in patients with diabetes without clinically detectable retinopathy. *Br J Ophthalmol* 2019;103:1747-52.
- Abcouwer SF, Gardner TW. Diabetic retinopathy: Loss of neuroretinal adaptation to the diabetic metabolic environment. *Ann N Y Acad Sci* 2014;1311:174-90.
- Michalinos A, Zogana S, Kotsiomitris E, Mazarakis A, Troupis T. Anatomy of the ophthalmic artery: A review concerning its modern surgical and clinical applications. *Anatomy Res Int* 2015;2015. Article ID 591961. doi: 10.1155/2015/591961.