

SCIENTIFIC REPORTS

OPEN

Publisher Correction:

Hyperpolarized [1-¹³C]-acetate Renal Metabolic Clearance Rate Mapping

Emmeli F. R. Mikkelsen^{1,2}, Christian Østergaard Mariager¹, Thomas Nørting^{1,2}, Haiyun Qi¹, Rolf F. Schulte³, Steen Jakobsen⁴, Jørgen Frøkiær⁴, Michael Pedersen², Hans Stødtkilde-Jørgensen¹ & Christoffer Laustsen¹ 

Correction to: *Scientific Reports* <https://doi.org/10.1038/s41598-017-15929-x>, published online 22 November 2017

This Article contains an error in the order of the Figures. Figures 2, 3, 4 and 5 were published as Figures 4, 2, 5 and 3 respectively. The correct Figures 2, 3, 4 and 5 appear below. The Figure legends are correct.

¹MR Research Centre, Aarhus University Hospital, Palle Juul-Jensens Boulevard 99, 8200, Aarhus N, Denmark. ²Comparative Medicine Lab, Aarhus University Hospital, Palle Juul-Jensens Boulevard 99, 8200, Aarhus N, Denmark. ³GE healthcare, Freisinger Landstraße 50, 85748, Munich, Germany. ⁴Department of Nuclear Medicine and PET Center, Aarhus University Hospital, Nørrebrogade, 8000, Aarhus C, Denmark. Emmeli F. R. Mikkelsen and Christian Østergaard Mariager contributed equally to this work. Correspondence and requests for materials should be addressed to C.L. (email: cl@clin.au.dk)

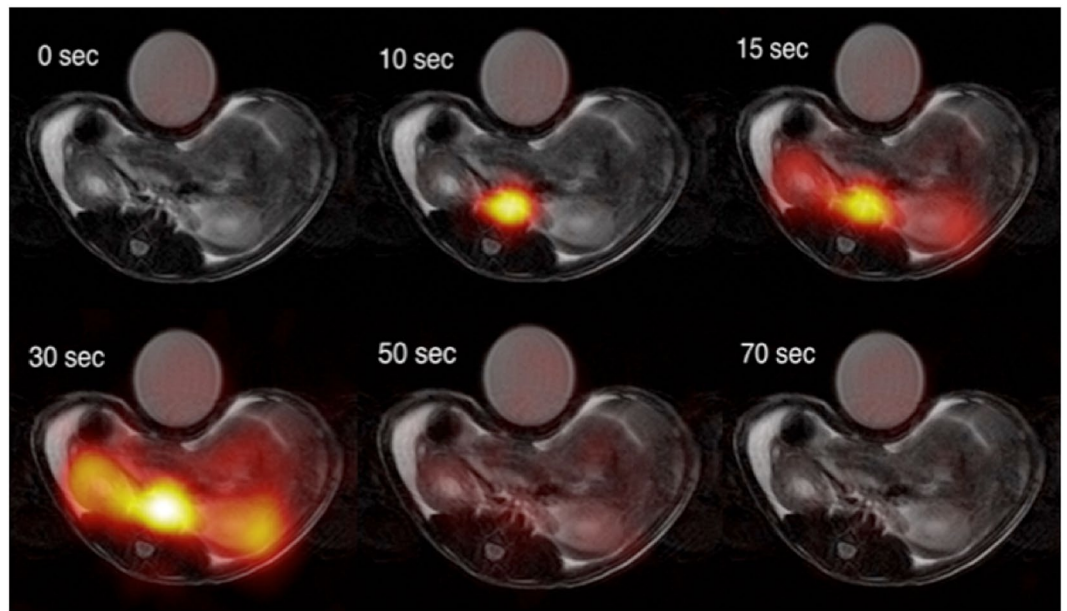


Figure 2. Examples of $[1-^{13}\text{C}]$ -acetate uptake in the aorta and kidneys over time. Hyperpolarized $[1-^{13}\text{C}]$ -acetate signal overlaid ^1H -anatomical MR images of an axial slice, showing two kidneys and the presence of a signal in the aorta and following the kidneys. MR; magnetic resonance.

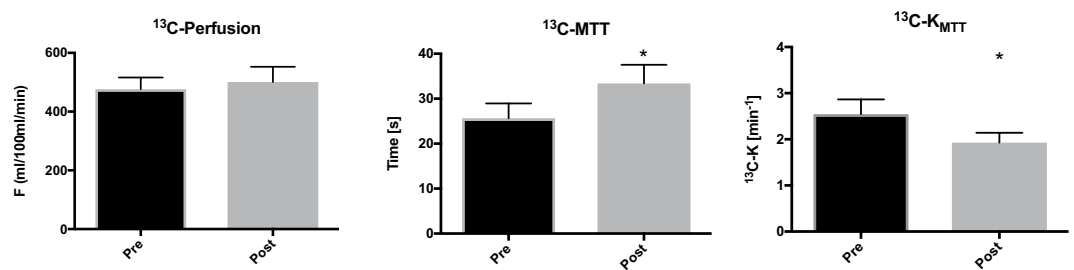


Figure 3. ^{13}C -acetate *in vivo* hemodynamic parameters. Acetate perfusion (ml/100 ml/min), mean transit time (MTT) (sec), and acetate mean transit time metabolic clearance rate K_{MTT} (min^{-1}) before and after administration of furosemide. The mean is plotted with standard errors.

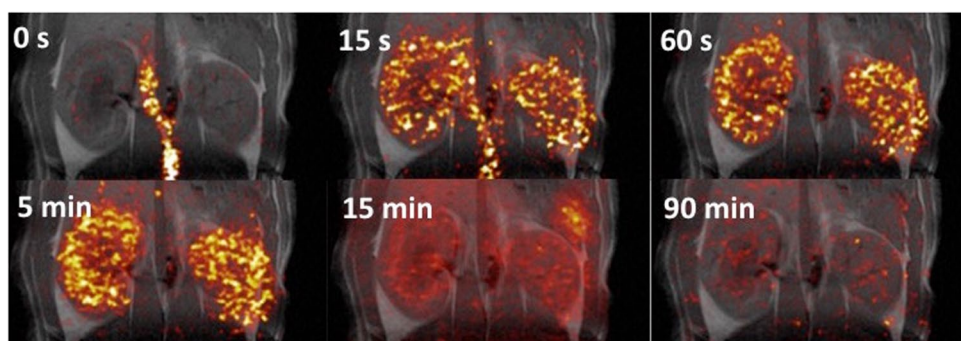


Figure 4. Examples of ^{11}C -acetate uptake in the aorta and kidneys over time. Positron emission tomography ^{11}C -acetate signal overlaid ^1H -anatomical MR images of a coronal slice, showing two kidneys and the presence of a signal in the aorta and following the kidneys. MR; magnetic resonance.

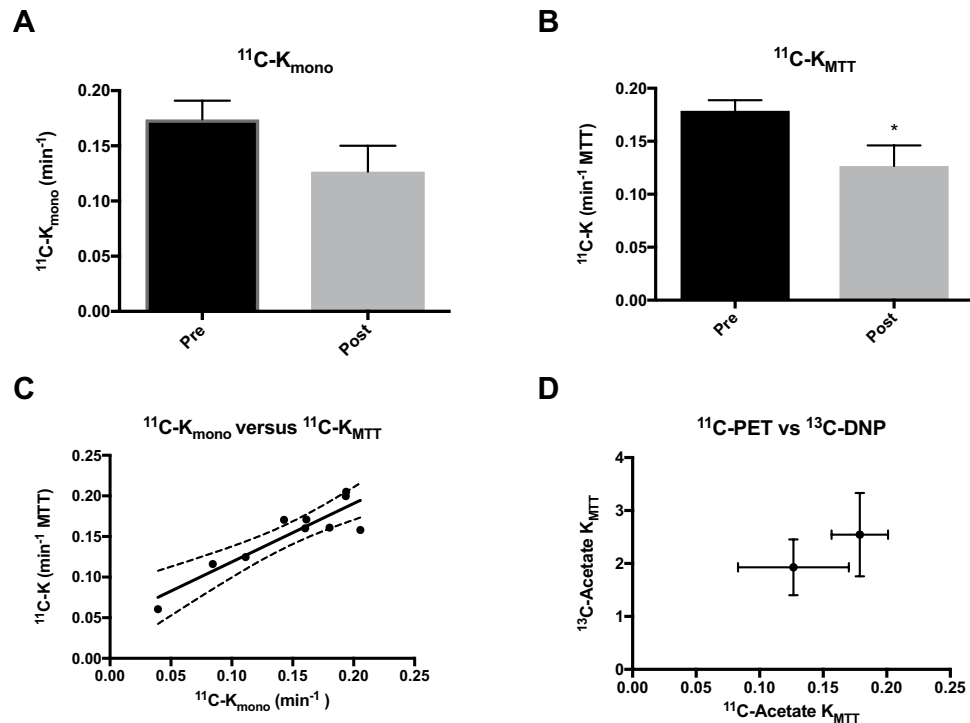


Figure 5. ^{11}C -acetate *in vivo* kinetic parameters. (A) ^{11}C -acetate single exponential metabolic clearance rate, K_{mono} . (B) ^{11}C -acetate mean transit time metabolic clearance rate, K_{MTT} . (C) Correlations between the decay derived or the first moment derived rates and the hyperpolarized ^{13}C , showing a positive correlation ($R^2 = 0.82$, $P = 0.0003$). (D) A tendency towards a similar response to furosemide treatment is seen between the ^{11}C -PET and the ^{13}C -hyperpolarization estimations. The mean is plotted with standard errors. PET, positron emission tomography.



Open Access This article is licensed under a Creative Commons Attribution 4.0 International License, which permits use, sharing, adaptation, distribution and reproduction in any medium or format, as long as you give appropriate credit to the original author(s) and the source, provide a link to the Creative Commons license, and indicate if changes were made. The images or other third party material in this article are included in the article's Creative Commons license, unless indicated otherwise in a credit line to the material. If material is not included in the article's Creative Commons license and your intended use is not permitted by statutory regulation or exceeds the permitted use, you will need to obtain permission directly from the copyright holder. To view a copy of this license, visit <http://creativecommons.org/licenses/by/4.0/>.

© The Author(s) 2018