

Ultrasound-Guided Glenohumeral Joint Injection Using the Posterior Approach

Carl P.C. Chen, MD, PhD, Henry L. Lew, MD, PhD, and Chih-Chin Hsu, MD, PhD

From the Department of Physical Medicine & Rehabilitation, Chang Gung Memorial Hospital at Linkou and College of Medicine, Chang Gung University, Kwei-Shan, Tao-Yuan County, Taiwan (CPCC); John A. Burns School of Medicine, University of Hawaii at Manoa, Honolulu, Hawaii (HLL); Department of Physical Medicine and Rehabilitation, Virginia Commonwealth University (VCU) School of Medicine, Richmond, Virginia (HLL); and Department of Physical Medicine & Rehabilitation, Chang Gung Memorial Hospital at Keelung and College of Medicine, Chang Gung University, Kwei-Shan, Tao-Yuan County, Taiwan (C-CH).

Financial disclosure statements have been obtained, and no conflicts of interest have been reported by the authors or by any individuals in control of the content of this article.

0894-9115/15/9412-e117

American Journal of Physical Medicine & Rehabilitation

Copyright © 2015 Wolters Kluwer Health, Inc. All rights reserved. This is an open-access article distributed under the terms of the Creative Commons Attribution-Non Commercial-No Derivatives License 4.0 (CCBY-NC-ND), where it is permissible to download and share the work provided it is properly cited. The work cannot be changed in any way or used commercially.

DOI: 10.1097/PHM.0000000000000366

This feature is a unique combination of text (voice) and video that more clearly presents and explains procedures in musculoskeletal medicine. These videos will be available on the journal's Website. We hope that this new feature will change and enhance the learning experience.



Video Gallery: To view the online video of these procedures, use your smartphone camera QR Reader App to scan and capture this QR Code or visit www.AJPMR.com to locate this digital video content.

URL: <http://journals.lww.com/ajpmr/Pages/videogallery.aspx?videoId=22&autoplay=true>

Injection treatment to the glenohumeral joint is often needed to treat shoulder problems such as adhesive capsulitis.^{1,2} This can be done through blind palpation technique and fluoroscopic or musculoskeletal ultrasound guidance.³ In recent years, ultrasound has been proven to increase the accuracy of needle placement into the glenohumeral joint.⁴ Ultrasound is radiation free and offers real-time images in performing needle-guided injection procedures.⁵

All correspondence and requests for reprints should be addressed to: Chih-Chin Hsu, MD, PhD, Department of Physical Medicine & Rehabilitation, Chang Gung Memorial Hospital at Keelung 222, Majjin Road, Keelung, Taiwan.

Glenohumeral joint injection can be done using the anterior rotator interval approach or the posterior approach technique.⁴ Both techniques are generally well tolerated by the patients. However, it was shown that the posterior injection technique offers an easier and a more effective approach to the glenohumeral joint with less extravasation rate as compared with the anterior approach.⁴ The posterior approach also avoids the potential risk of accidental puncture or injection into the axillary neurovascular structures. A linear transducer of 5–12 MHz is usually used.⁶ This technique is often applied to inject corticosteroid for the treatment of frozen shoulder or contrast medium for computed tomography or magnetic resonance shoulder arthrography.⁶

ULTRASOUND-GUIDED GLENOHUMERAL JOINT INJECTION USING THE POSTERIOR APPROACH—HOW IT IS PERFORMED

Patients can be placed in the prone, upright, or semi-prone body positions to receive the glenohumeral joint injection treatment using the posterior approach.^{6,7} In the upright body position, the patient sits in an upright position, and the physiatrist performing the injection stands behind the patient. The hand of the injection side (ipsilateral hand) can be positioned on the patient's contralateral shoulder (preferred) or rests on the thigh with the elbow placed in a natural 90-degree angle. The semiprone body position is preferred by many authors. The affected shoulder is at the uppermost position, and the ipsilateral arm is placed over a pillow to maximize comfort and stability.⁶

In this video gallery article, the real-time injection images were obtained from a patient placed under the semiprone position. Corticosteroid suspension was injected into the glenohumeral joint for the treatment of frozen shoulder. The ultrasound transducer is positioned over the long axis of the myotendinous junction of the infraspinatus tendon to view the contours of the posterior glenoid rim, posterior glenoid labrum, and posterior portion of the humeral head (Fig. 1). These structures must be viewed simultaneously on the ultrasound image as this is the correct injection spot.⁶ The teres minor muscle is located inferior to the infraspinatus muscle and must not be mistakenly identified as the injection spot (see video). Therefore, it is crucial to move the transducer around to locate the correct injection spot.

As stated by the American Institute of Ultrasound in Medicine, it is recommended that ultrasound-guided musculoskeletal injection should be done using sterile ultrasound gel, and the injector must wear gloves to reduce the risk of contamination and infection (<http://www.aium.org/resources/guidelines/musculoskeletal.pdf>). Under the axial oblique sonographic real-time images, the injection needle is introduced at the skin surface just lateral to the transducer, and in an oblique lateral to medial direction, the needle is inserted into the glenohumeral joint space.⁶ There must be a

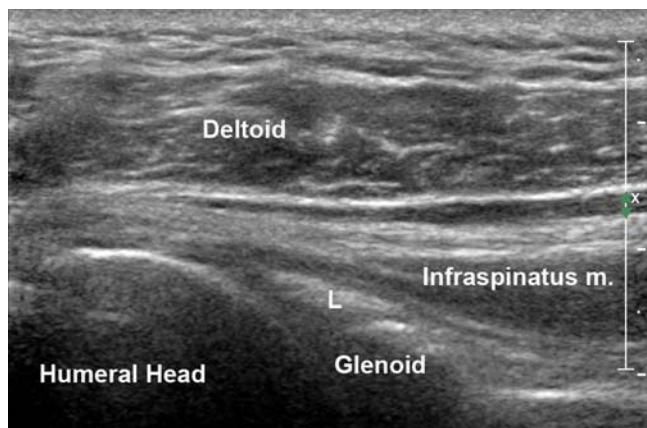


FIGURE 1 *Ultrasound image of the right shoulder glenohumeral joint as viewed from the posterior aspect. L, labrum.*

safe distance between the transducer gel and the needle to avoid possible introduction of ultrasound gel into the shoulder joint and its nearby soft tissue structures. In this oblique needle path in which the needle travels through the infraspinatus muscle, the accidental puncture of the suprascapular or the circumflex scapular neurovascular structures can be avoided.⁶ The needle appears as a hyperechoic line under ultrasound imaging, and the ideal position of the needle is between the free margin of the posterior glenoid labrum and the hypoechoic articular cartilage of the humeral head. In the work by Zwar et al., it was stated that during needle advancement through the infraspinatus muscle and into the glenohumeral joint, the injection needle may be deflected off course. Therefore, Zwar et al. recommended that keeping the bevel of the needle tip facing upward during needle advancement can prevent this from happening. After reaching the glenohumeral joint, the needle tip needs to be rotated to have the bevel facing downward. The injection of the sonolucent medication fluid can then

be started.⁶ A 20- to 22-gauge spinal needle is recommended in this injection technique.

CONCLUSIONS

The ultrasound-guided injection technique has been shown to have 100% accuracy in needle placement in performing procedures such as caudal epidural injection. This video thoroughly demonstrates how the glenohumeral joint is injected using the posterior approach under real-time ultrasound image guidance. The ultrasound images of the glenoid labrum, infraspinatus tendon, and humeral head are clearly shown. The posterior approach is preferred in glenohumeral joint injection as less extravasation will occur as compared with the anterior rotator interval approach.

REFERENCES

1. Chen MJ, Lew HL, Hsu TC, et al: Ultrasound-guided shoulder injections in the treatment of subacromial bursitis. *Am J Phys Med Rehabil* 2006;85:31–5
2. Park SW, Lee HS, Kim JH: The effectiveness of intensive mobilization techniques combined with capsular distension for adhesive capsulitis of the shoulder. *J Phys Ther Sci* 2014; 26:1767–70
3. Amber KT, Landy DC, Amber I, et al: Comparing the accuracy of ultrasound versus fluoroscopy in glenohumeral injections: A systematic review and meta-analysis. *J Clin Ultrasound* 2014; 42:411–6
4. Ogul H, Bayraktutan U, Ozgokce M, et al: Ultrasound-guided shoulder MR arthrography: Comparison of rotator interval and posterior approach. *Clin Imaging* 2014;38:11–7
5. Chen CP, Tang SF, Hsu TC, et al: Ultrasound guidance in caudal epidural needle placement. *Anesthesiology* 2004;101:181–4
6. Zwar RB, Read JW, Noakes JB: Sonographically guided glenohumeral joint injection. *AJR Am J Roentgenol* 2004;183:48–50
7. Masala S, Fiori R, Bartolucci DA, et al: Diagnostic and therapeutic joint injections. *Semin Intervent Radiol* 2010;27:160–71