

Is there an association between the Hand Diagram and Electrodiagnostic Testing for Carpal Tunnel Syndrome?

Existe associação entre o diagrama da parestesia da mão e a eletroneuromiografia no diagnóstico da Síndrome do Túnel do Carpo?

Henver Ribeiro Paiva Filho¹ Antonio Carlos Costa² Valdênia Graças Nascimento Paiva¹
Diego Abad Santos² Ivan Chakkour²

¹ Orthopedics Department, Hand Surgery Service, Hospital de Clínicas, Universidade Federal do Triângulo Mineiro, Uberaba, MG, Brazil

² Orthopedics Department, Hand Surgery Service, Santa Casa de São Paulo, São Paulo, SP, Brazil

Rev Bras Ortop 2021;56(1):74–77.

Address for correspondence Valdênia das Graças Nascimento Paiva, PhD, Departamento de Ortopedia e Traumatologia, Hospital de Clínicas, Universidade Federal do Triângulo Mineiro, Avenida Getúlio Guaritá, 130, Nossa Sra. da Abadia, Uberaba, MG, Brazil (e-mail: vallfntm@yahoo.com.br).

Abstract

Objective Verify if there is an association between the hand diagram of paresthesia (HDP) and the results of electroneuromyography (ENMG) in the diagnosis of carpal tunnel syndrome.

Methods A total of 92 people filled in a schematic drawing of the hand with the exact location of the paresthesia (167 hands). The main author classified the diagrams according to the criteria of Katz et al.⁵ The results of the HDP were crossed with the positive results of ENMG for the diagnosis of carpal tunnel syndrome.

Results The possible pattern of the HDP was prevalent both in isolation and after crossing with the degrees of ENMG.

Conclusion There was no association between the HDP and ENMG in the diagnosis of carpal tunnel syndrome.

Keywords

- ▶ electromyography
- ▶ median neuropathy
- ▶ carpal tunnel syndrome

Resumo

Objetivo Verificar se existe associação entre o diagrama da parestesia da mão (DPM) e os resultados da eletroneuromiografia (ENMG) no diagnóstico da síndrome do túnel do carpo.

Métodos Um total de 92 pessoas preencheram um desenho esquemático da mão com o local exato da parestesia (167 mãos). O autor principal classificou os diagramas de acordo com os critérios de Katz et al. Os resultados do DPM foram cruzados com os resultados positivos da ENMG para o diagnóstico da síndrome do túnel do carpo.

Resultados O padrão possível do DPM foi prevalente tanto isoladamente quanto após o cruzamento com os graus da ENMG.

Conclusão Não houve associação entre o DPM e a ENMG no diagnóstico da síndrome do túnel do carpo.

Palavras-chave

- ▶ eletromiografia
- ▶ neuropatia mediana
- ▶ síndrome do túnel do carpo

Work developed at the Hand Surgery Service of the Santa Casa de São Paulo, São Paulo, SP, and at the Universidade Federal do Triângulo Mineiro, Uberaba, MG, Brazil.

received
October 25, 2019
accepted
April 15, 2020
published online
September 25, 2020

DOI <https://doi.org/10.1055/s-0040-1713763>.
ISSN 0102-3616.

© 2020. Sociedade Brasileira de Ortopedia e Traumatologia. All rights reserved.

This is an open access article published by Thieme under the terms of the Creative Commons Attribution-NonDerivative-NonCommercial-License, permitting copying and reproduction so long as the original work is given appropriate credit. Contents may not be used for commercial purposes, or adapted, remixed, transformed or built upon. (<https://creativecommons.org/licenses/by-nc-nd/4.0/>)

Thieme Revinter Publicações Ltda., Rua do Matoso 170, Rio de Janeiro, RJ, CEP 20270-135, Brazil

Introduction

Carpal tunnel syndrome (CTS) is the most common peripheral neuropathy of the upper limbs due to compression of the median nerve at the level of the carpal tunnel.¹ The diagnosis is usually made through clinical history and physical examination,² while electroneuromyography (ENMG) assists in the diagnostic confirmation of doubtful cases and in establishing the severity.^{3,4} In 1990, Katz et al.⁵ popularized hand diagrams, which are schematic drawings in which the patient marks the exact location of the numbness symptoms in the hands. These hand diagrams of paresthesia (HDPs) were considered, at the time, as a screening method in people with suspected CTS.^{5,6}

In our clinical practice and in the field of occupational medicine, we have observed an increase in the number of work leaves caused by CTS due to some doctors prioritizing positive ENMG for this condition to the detriment of a well-performed clinical examination, generating consequences for the employer, from negative company image to production delay, and to the employee, with unnecessary surgery and prolonged leave. We justify the performance of the present work, too, due to the scarcity of publications in the literature that directly compare the classification of HDP with ENMG.

The aim of our study was to verify whether there is an association between HDP and ENMG in the diagnosis of CTS.

Casistry and Methods

A cross-sectional, qualitative, and quantitative study was carried out, with the evaluation of 107 consecutively scheduled patients over a 4-month period. All procedures were performed in accordance with the ethical standards determined by the Research Ethics Committee for research on human beings, and with the Helsinki Declaration of 1964. The Free and Informed Consent Form was obtained from all study participants, by signing a specific term.

The inclusion criteria were people of both genders, > 18 years old, who presented, in the initial consultation, upper limb ENMG positive for CTS. The exclusion criteria were people who had neuropathy of the cervical spine, of the median nerve in the proximal region or associated with the ulnar nerve, anatomical variations identified by ENMG, history of polyneuropathies, trauma or previous surgery on the wrist, uncontrolled comorbidities (diabetes, hypothyroidism, rheumatoid arthritis, systemic lupus erythematosus, gout, amyloidosis, chronic renal failure), tenosynovitis or tumors in the wrist, pregnant women, and people with reports of labor activities with repetitive movements of flexion-extension of the wrists, vibration of hands and arms or exposure to cold working conditions.

On the scheduled day and time of the medical consultation, all patients underwent screening by a single nurse with a specialization in orthopedics and belonging to the clinical staff of the university who, for the present study, referred people who presented positive upper limb ENMG for CTS to our team.

Then, as soon as the patients entered the doctor's office, before the consultation, they were instructed on how to complete the schematic drawing of the hands. This guidance was performed by a single team member physician who was unaware of any participant data. Filling consisted of marking with a pen the region corresponding to the exact location of the paresthesia. Our study addressed only the location of the marked area in the HDP, and not the intensity of the symptoms. After the completion of the filling, the main author of the present work classified the diagram according to the criteria of Katz et al.,⁵ without knowledge of any clinical data of the studied patient.

Katz et al.,⁵ in 1990, proposed a hand diagram, in which the location of the paresthesia is marked by means of schematic drawings. The results were classified as classic, probable, possible, or unlikely.

After completing the HDP, the drawing was kept in a proper file for later statistical analysis and, then, the participant was submitted to medical care according to the outpatient routine, at which time the information on the qualitative and quantitative variables was obtained.

Electroneuromyography was performed by the same neurologist specialized in electroneuromyographic studies, belonging to the institutional clinical staff, blind to clinical data and with no specific link with the present work. The exam is performed bilaterally, according to local institutional regulations. The Neuropack EMG electroneuromyograph model S1, MEB-9400K (Nihon Kohden Corporation, Tokyo, Japan) was used, at room temperature of 28°C, available at our institution. The classification of ENMG is standardized as follows: mild degree (alteration of sensory conduction only), moderate degree (alteration of sensory and motor conduction) and severe degree (altered sensory and motor conduction and signs of denervation on needle electromyography).

The information obtained from the participants was organized in a database, according to the criteria of Katz et al.⁵ (classic, probable, possible, or unlikely) for CTS, and according to the severity of the ENMG (mild, moderate, or severe).

The HDP results were crossed with the positive result of the ENMG for CTS, using the hand as a sample unit, using the likelihood ratio test.⁷

A total of 107 people were assisted and 15 were excluded (1 pregnant woman, 2 with previous trauma to the wrist, 5 with uncontrolled diabetes and/or hypothyroidism, and 7 with previous wrist surgery), totaling 92 participants included in the present study. Regarding gender, our sample included 14 men (15.2%) and 78 women (84.8%). The mean and standard deviation (SD) of age was 55.2 ± 10.5 years old.

Of the 92 patients with ENMG positive for CTS and, using the hand as a sample unit, we obtained 75 people with positive ENMG bilaterally (150 hands) and 17 unilaterally (17 hands), totaling 167 hands with a positive result of ENMG for CTS.

To perform the analyzes, IBM SPSS Statistics for Windows, Version 20.0 (IBM Corp., Armonk, NY, USA) was used, and Microsoft Excel 2003 (Microsoft Corporation, Redmond, WA,

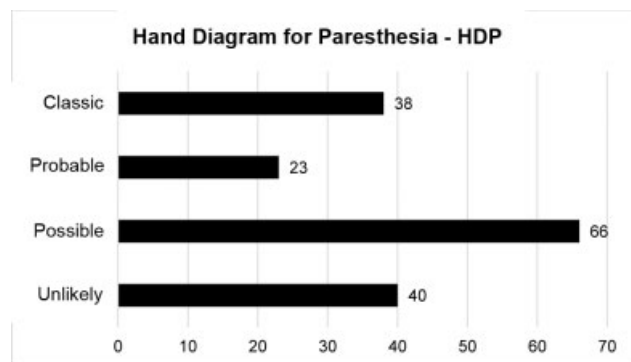


Fig. 1 Distribution of the number of hands according to the HDP.

USA) software was used to tabulate the data. The tests were performed with a significance level of 5%.

Results

► **Figure 1** shows the distribution of the 167 hands that presented positive ENMG for CTS, classified according to the criteria of Katz et al.⁵ In our study, we obtained 38 hands (22.7%) with a classic pattern, 23 (13.8%) probable, 66 (39.5%) possible and 40 (24.0%) unlikely.

► **Table 1** presents the crossing between HDP and ENMG, with the statistical results. In decreasing order of involvement, we observed that of the 22 hands with mild grade ENMG, 10 cases (45.5%) presented possible standard HDP, followed by improbable in 6 cases (27.2%), classic in 4 cases (18.2%) and probable in 2 cases (9.1%). In decreasing order of involvement, we observed that of the 67 hands with moderate degree ENMG, 26 cases (38.8%) presented possible standard MPD, followed by classic in 18 cases (26.9%), unlikely in 16 cases (23.9%) and probable in 7 cases (10.4%). Finally, in decreasing order of involvement, we observed that of the 78 hands with severe grade ENMG, 30 cases (38.5%) presented possible standard HDP, followed by improbable in 18 cases (23.1%), classic in 16 cases (20.5%) and probable in 14 cases (17.9%).

Discussion

We currently have several clinical instruments for the diagnosis of CTS, but it is essential that they are validated.⁸ We

agree with Moradi et al.⁹ when considering HDP as a screening method for the diagnosis of CTS, which was even used by our team in the initial approach. Of the 167 hands assessed in our study, we identified in the HDP that the possible pattern was the most prevalent, in 66 cases (39.5%), while the least prevalent was the likely pattern, in 23 cases (13.8%).

We observed that there are divergences of opinion on the need for ENMG to confirm the diagnosis of CTS, and the literature is controversial when it demonstrates which is the best diagnostic method. Agreement between symptoms, physical examination and ENMG is low, and Stevens has found a 5% agreement between the three parameters.¹⁰ These authors believe that the person with ENMG positive for CTS in the absence of symptoms cannot be considered as having CTS.

When evaluating the crossing between HDP and ENMG, we observed that both cases with mild, moderate, or severe ENMG had a predominance of possible standard HDP. In contrast, the probable pattern was the least prevalent in all degrees of ENMG involvement. In our results, we found that there was no statistically significant association ($p = 0.797$) between HDP and ENMG results.

As positive points of our study, we had a sample of 92 patients, totaling 167 hands. Studies by Sharma et al.¹¹ include 40 patients and 71 hands; Nelson et al.,¹² 26 patients and 34 hands; and Katz and Stirrat,⁵ 63 patients and 85 hands. In addition, ENMG was performed only by a specialized neurologist, using a single ENMG device available at our institution. As a negative point, it is possible that there was a bias regarding the classification of HDP, which, in our study, was performed by a single doctor on the team. As it is a subjective assessment tool, one of the measures to reduce this bias would be the classification of diagrams by two or more doctors.

At the time of the present study, we did not find in the literature sufficient recommendations, guidelines or criteria validated at national level indicating when ENMG should be requested for investigation of CTS, which makes the diagnosis of this condition a challenging task.

We understand that it is unwise to exclude the diagnosis of CTS in people with typical symptoms and normal ENMG, not least because there is no way to predict whether the person is experiencing transient ischemia, in which case, ENMG may be normal. We believe that ENMG is a useful exam in doubtful cases that are refractory to the initial treatment, and should be requested carefully and based on what is intended to be

Table 1 Crossing between hand diagram for paresthesia and electroneuromyography

HDP	ENMG			Total	p-value
	Mild	Moderate	Severe		
Classic	4 (18.2)	18 (26.9)	16 (20.5)	38 (22.8)	0.797
Probable	2 (9.1)	7 (10.4)	14 (17.9)	23 (13.8)	
Possible	10 (45.5)	26 (38.8)	30 (38.5)	66 (39.5)	
Unlikely	6 (27.2)	16 (23.9)	18 (23.1)	40 (24.0)	
Total	22 (100)	67 (100)	78 (100)	167 (100)	

Abbreviations: HDP, Hand Diagram for Paresthesia; ENMG, Electroneuromyography. Likelihood ratio test.

investigated, avoiding the discomfort of the exam and the anxiety of the patient. Regarding HDP, we believe that more studies are needed to prove the effectiveness and precision of this method for the diagnosis of CTS; however, we believe that this clinical tool can be used for screening this condition.

In our opinion, neither HDP nor ENMG should be used alone or in place of a detailed clinical history and thorough physical examination for the diagnosis of CTS.

We conclude that there is no association between the HDP and ENMG in the diagnosis of CTS.

Conflict of interests

The authors have no conflict of interests to declare.

References

- 1 Spahn G, Wollny J, Hartmann B, Schiele R, Hofmann GO. [Meta-analysis for the evaluation of risk factors for carpal tunnel syndrome (CTS) Part I. General factors]. *Z Orthop Unfall* 2012; 150(05):503–515
- 2 Wang WL, Buterbaugh K, Kadow TR, Goitz RJ, Fowler JR. A prospective comparison of diagnostic tools for the diagnosis of carpal tunnel syndrome. *J Hand Surg Am* 2018;43(09):833–836.e2
- 3 Rempel D, Evanoff B, Amadio PC, et al. Consensus criteria for the classification of carpal tunnel syndrome in epidemiologic studies. *Am J Public Health* 1998;88(10):1447–1451
- 4 Sears ED, Swiatek PR, Hou H, Chung KC. Utilization of preoperative electrodiagnostic studies for carpal tunnel syndrome: an analysis of National Practice Patterns. *J Hand Surg Am* 2016;41(06):665–672.e1
- 5 Katz JN, Stirrat CR. A self-administered hand diagram for the diagnosis of carpal tunnel syndrome. *J Hand Surg Am* 1990;15(02):360–363
- 6 Calfee RP, Dale AM, Ryan D, Descatha A, Franzblau A, Evanoff B. Performance of simplified scoring systems for hand diagrams in carpal tunnel syndrome screening. *J Hand Surg Am* 2012;37(01):10–17
- 7 Kirkwood BR, Sterne JA. *Essential medical statistics*. 2nd ed. Blackwell Science/Massachusetts, USA2006:502
- 8 Goulart BNG, Chiari BM. [Screening versus diagnostic tests: an update in the speech, language and hearing pathology practice]. *Pro Fono* 2007;19(02):223–232
- 9 Moradi A, Mellema JJ, Oflazoglu K, Isakov A, Ring D, Vranceanu AM. The relationship between catastrophic thinking and hand diagram areas. *J Hand Surg Am* 2015;40(12):2440–6.e5
- 10 de Krom MC, Kester AD, Knipschild PG, Spaans F. Risk factors for carpal tunnel syndrome. *Am J Epidemiol* 1990;132(06):1102–1110
- 11 Sharma V, Wilder-Smith EP. Self-administered hand symptom diagram for carpal tunnel syndrome diagnosis. *J Hand Surg [Br]* 2004;29(06):571–574
- 12 Nelson JT, Gauger MR, Whaley JD, Zinberg EM. Patient-reported symptom-mapping in carpal tunnel syndrome. *Muscle Nerve* 2019;59(03):321–325