

Laparoscopic Paraesophageal Hernia Repair with Acellular Dermal Matrix Cruroplasty

Dennis F. Diaz, MD, J. Scott Roth, MD

ABSTRACT

Background: Laparoscopic paraesophageal hernia repair (LPEHR) has been shown to be both safe and efficacious. Compulsory operative steps include reduction of the stomach from the mediastinum, resection of the mediastinal hernia sac, ensuring an appropriate intraabdominal esophageal length, and crural closure. The use of mesh materials in the repair of hiatal hernias remains controversial. Synthetic mesh may reduce hernia recurrences, but may increase postoperative dysphagia and result in esophageal erosion. Human acellular dermal matrix (HADM) may reduce the incidence of hernia recurrence with reduced complications compared with synthetic mesh.

Methods: A retrospective review of all cases of laparoscopic hiatal hernia repair using HADM from December 2008 through March 2010 at a single institution was performed evaluating demographic information, BMI, operative times, length of stay, and complications.

Discussion: Forty-six LPEHRs with HADM were identified. The mean age of patients was 60.3 years (± 13.9); BMI 30.3 (± 5.3); operative time 182 minutes (± 56); and length of stay 2.6 days (± 1.9). Nine of 46 (19.6%) patients experienced perioperative complications, including subcutaneous emphysema without pneumothorax ($n=2$), urinary retention ($n=1$), COPD exacerbation ($n=2$), early dysphagia resolving before discharge ($n=1$), esophageal perforation ($n=1$), delayed gastric perforation occurring 30 days postoperatively associated with gas bloat syndrome ($n=1$), and PEG site abscess ($n=1$). There were 2 clinically recurrent hernias (4.3%). Radiographic recur-

rences occurred in 2 of 26 patients (7.7%). Six of 46 (13%) patients reported persistent dysphagia.

Conclusion: LPEHR with HADM crural reinforcement is an effective method of repairing symptomatic paraesophageal hernias with low perioperative morbidity. Recurrences occur infrequently with this technique. No mesh-related complications were seen in this series.

Key Words: Paraesophageal hernia, Hiatal hernia, Laparoscopy, Human acellular dermis.

INTRODUCTION

The surgical approach to repair of paraesophageal hernia has shifted with the advent of minimally invasive technologies and techniques. The laparoscopic repair affords the patients a quicker recovery, shorter hospital stay, and quicker return to activity with less morbidity than with the open approach.¹ Compulsory operative steps include reduction of the stomach from the mediastinum, resection of the mediastinal hernia sac, ensuring an appropriate intraabdominal esophageal length, and crural closure. However, studies have shown that primary suture-based repairs of the crura have recurrence rates of 15% to 42%.²⁻⁵ Others have reported higher recurrence rates in those undergoing laparoscopic repair relative to open repair.² The utilization of mesh in both inguinal and ventral hernia repairs has been shown to significantly improve recurrence rates.⁶ The application of mesh-based repairs to paraesophageal hernia has also been shown to decrease recurrence rates.⁷⁻¹⁰ The dynamic nature of the esophagus relative to the esophageal hiatus raises concerns about placement of a synthetic mesh to reinforce the crural repair. Indeed, there exist reports of erosion of synthetic mesh into the esophagus and dysphagia related to mesh-associated fibrosis and scarring necessitating reoperation.¹¹⁻¹⁴

Given the concerns for mesh-related complications at the hiatus and the lower recurrence rates associated with mesh-based repairs, biologic meshes have been increasingly used in laparoscopic paraesophageal hernia repair. Biologic grafts are believed to provide an extracellular

Department of General Surgery, University of Kentucky Medical Center, Lexington, Kentucky, USA (all authors); J. Scott Roth, MD is a consultant for CR Bard Inc. No financial support was received for this study.

© 2011 by JLS, Journal of the Society of Laparoendoscopic Surgeons. Published by the Society of Laparoendoscopic Surgeons, Inc.

Address correspondence to: J. Scott Roth, MD, Associate Professor, Division of General Surgery, University of Kentucky College of Medicine, 800 Rose Street, UKMC C-222, Lexington, Kentucky 40536-0298, USA. Telephone: (859) 323-6346, ext. 242, Fax: (859) 323-6840, E-mail: jsroth2@email.uky.edu

DOI: 10.4293/108680811X13125733356594

© 2011 by JLS, Journal of the Society of Laparoendoscopic Surgeons. Published by the Society of Laparoendoscopic Surgeons, Inc.

collagen matrix that is remodeled when utilized in hernia repair to allow for a stronger repair. A multi-institutional randomized controlled trial comparing porcine small intestinal submucosa buttressed hiatal hernia repair to primary repair showed a significant decrease in recurrence without mesh-related complications.¹⁵ Human acellular dermal matrix is an allogeneic graft also increasingly utilized in abdominal wall repair as well as in paraesophageal hernia repair. Small case series have demonstrated recurrence rates with human acellular dermal matrix cruroplasty to range from 3.8% to 12%.¹⁶⁻¹⁸ In this study, the outcomes following a consecutive series of laparoscopic paraesophageal hernia repair with a human acellular dermal matrix are evaluated.

METHODS

Following Institutional Review Board approval, a retrospective review was conducted of all patients undergoing laparoscopic repair of a paraesophageal hernia with human acellular dermis from December 2008 through March 2010. Only those hiatal hernias at least 5cm in craniocaudal length, as determined by preoperative endoscopy or barium swallow, were included. The size of the hiatal hernia was determined by measuring the distance from the gastroesophageal junction to the diaphragm on preoperative imaging. Patient demographics, BMI, operative times, length of stay, and complications were recorded. Follow-up data were reviewed to identify postoperative complaints, specifically the presence or absence of dysphagia to solids. Postoperative barium esophagrams and esophagogastroduodenoscopies were reviewed to identify recurrences and/or mesh complications.

A standardized technique was utilized for all laparoscopic paraesophageal hernia repairs. A minimum of 2.5cm of intraabdominal esophageal length is obtained with extensive mediastinal dissection (**Figure 1**). Intraabdominal esophageal length is measured intraoperatively from the diaphragm to the gastroesophageal junction while the stomach is held tension-free. Complete mobilization of the fundus and cardia of the stomach is performed with preservation of the peritoneal covering of the crura. A 54 French bougie is passed per os and directed along the lesser curvature of the stomach to size the cruroplasty. The diaphragmatic crura are closed using interrupted permanent sutures (**Figure 2**) to allow for approximation of the crural fibers, allowing for a 5-mm instrument to be placed between the esophagus and crural closure while the bougie is in position, thus ensuring no extrinsic compression from the crural closure is placed on the esoph-

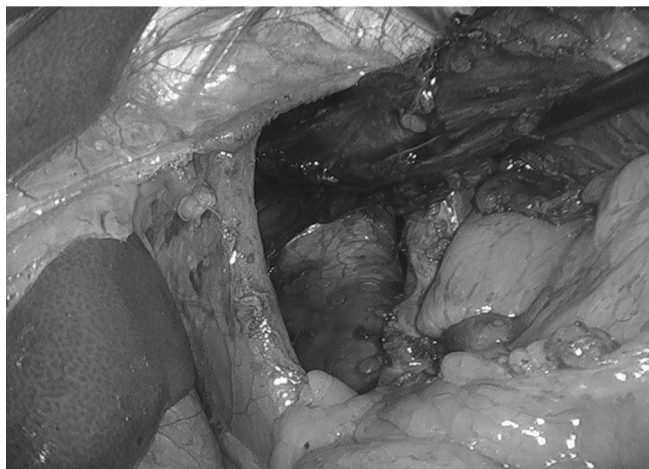

Figure 1. Hiatal defect.

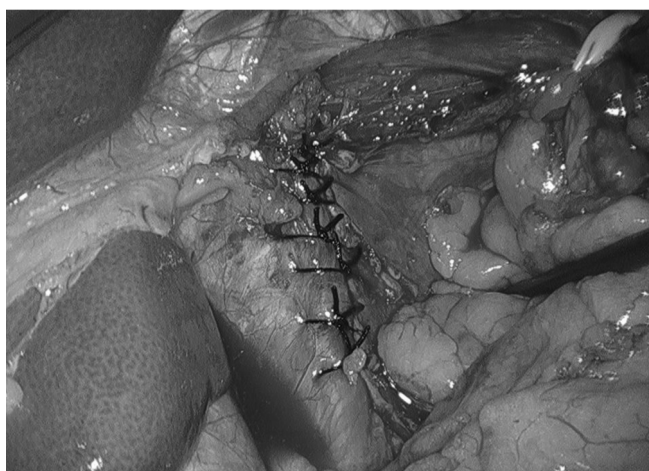

Figure 2. Cruroplasty.

agus. Hernias >5cm in size noted on preoperative barium study¹⁵ or endoscopy, or the presence of attenuated crura were criteria for the use of human acellular dermal graft. A 5cm x 8cm graft of human acellular dermis is fashioned into a “U” shape and is placed as an onlay patch over the cruroplasty posterior to the esophagus with the tails of the “U” placed to either side of the esophagus. Care is taken to ensure the mesh is not impinging on the esophagus. An Endoscopic Universal 65 Hernia Stapler (Covidien, Mansfield, MA) is used to secure the mesh to the diaphragm (**Figures 3 and 4**). A 360-degree fundoplication is then fashioned over a 54 French bougie. Completion endoscopy is performed to visualize the fundoplication and ensure no esophageal or gastric injury. Percutaneous endoscopic gastrostomy tubes are placed selectively in patients with large paraesophageal hernias in which more

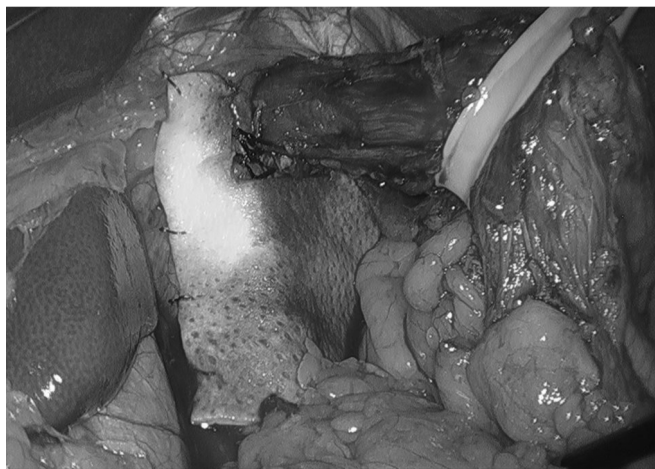


Figure 3. Human acellular dermis only.

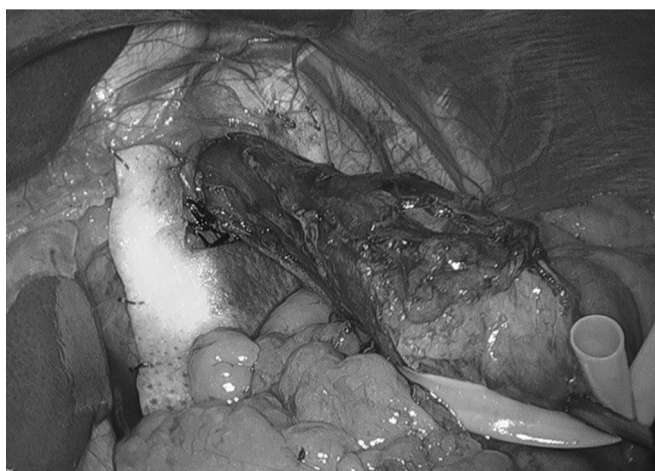

Figure 4. Human acellular dermis only.

than half of the stomach has herniated through the hiatal defect with the appearance of a dilated or atonic stomach after the completion of the dissection.

RESULTS

Forty-six patients underwent laparoscopic paraesophageal hernia repair with human acellular dermis. There were 11 male and 35 female patients (Table 1). Five patients underwent surgery for recurrent hiatal hernias, one of whom had undergone prior repair with mesh. The average age was 60.3 years (± 13.9), and the average BMI was 30.3 (± 5.3). Mean operative time was 182 minutes (± 56), and mean postoperative length of stay was 2.6 days (range, 1 to 8). Forty-three patients had AlloMax (Bard Davol, Warwick, RI), while 2 patients had Flex HD (Ethicon, Somerville, NJ), and 1 patient had AlloDerm

Age	60.3 \pm 13.9 yr
BMI	30.3 \pm 5.3
Operative Time	182 \pm 56 min
Length of stay	2.6 days (range, 1 to 8)
Recurrences	
Clinical	2/46 (4.3%)
Radiographic	2/26 (7.7%)
Dysphagia	6/46 (13%)
Early Complications	9/46 (19.6%)
Intraop esophageal perforation	1
Delayed gastric perforation	1
Subcutaneous emphysema	2
Urinary retention	1
COPD exacerbation	2
PEG site abscess	1
Early dysphagia	1

(Lifecell, Branchburg, NJ). Forty-three patients underwent primary crural closure with placement of the graft as reinforcement. Three patients had attenuated crura that were unable to be reapproximated and underwent hernia closure with a bridging graft of human acellular dermis. Two of these patients had a complete intrathoracic stomach, and the third patient presented with a 50% intrathoracic stomach, all with significant separation of the crura. Primary crural closure was unsuccessful following crural dissection in these cases, and the decision was made to perform a bridging repair with a graft. Two patients required the addition of a Collis gastroplasty to achieve adequate intraabdominal esophageal length. Nineteen patients underwent concomitant placement of a gastrostomy tube at the time of surgery. All gastrostomy tubes were removed by the sixth postoperative week. Mean follow-up was 3.6 months with a range of 1 to 14 months.

Perioperative complications occurred in 9 patients (19.5%, Table 1). Two patients developed subcutaneous emphysema without pneumothorax, 2 patients had an exacerbation of their preoperative chronic obstructive pulmonary disease requiring medical management, and 1 patient developed urinary retention. One patient experienced early postoperative dysphagia requiring a prolonged hospital stay. This patient's dysphagia resolved without long-term complication. An intraoperative esophageal perforation

related to bougie placement occurred in 1 patient. This was repaired intraoperatively with no postoperative sequelae. One patient complained of gas bloat in the postoperative setting and developed a gastric perforation of the anterior body of the stomach 30 days following hiatal hernia repair. This patient required operative intervention with primary gastric closure. One patient developed an abscess at the site of a gastrostomy tube, which was treated with local wound care. Postoperative barium esophagrams were obtained in 26 patients. Radiographic recurrence of the hiatal hernia occurred in 2 patients. One of these patients subsequently underwent laparoscopic revision without clinical or radiographic recurrence. The second recurrence was managed nonoperatively. Dysphagia for solids occurred in 6 patients (13%). There was no dysphagia for liquids. No mesh erosions or mesh-related complications were seen.

DISCUSSION

The successful repair of large paraesophageal hernias continues to be a challenge. Recurrence rates have been reported to range up to 42% with primary suture-based repairs.²⁻⁴ The utilization of mesh products at the esophageal hiatus remains controversial. Although some authors have advocated routine utilization of mesh reinforcement of the esophageal hiatus,¹⁵ others have taken a selective approach. A recent report of 662 hiatal hernia repairs demonstrated a radiographic recurrence rate of 15.7%, and a clinical recurrence rate necessitating a reoperation rate of 3.2% utilizing a selective approach to reinforcing the crura with mesh.⁵ As with abdominal wall hernia repair there is a plethora of products available to use. A recent survey of 264 SAGES members showed that biomaterials were utilized 28.3% of the time, PTFE 25.3%, and polypropylene 21.1%.¹⁹ To date, there has been one multi-center randomized prospective trial comparing suture-based repair of paraesophageal hernia to repair reinforced with a biologic mesh, porcine small intestinal submucosa. This study has shown a significant decrease in recurrence rates without evidence of mesh complications.¹⁵

Wisbach and colleagues¹⁸ reported their initial experience using human acellular dermal matrix in laparoscopic type III paraesophageal hernia repair in 11 patients with 1 recurrence on barium esophagram and 1 case of dysphagia. Lee and colleagues¹⁷ reported on a series of 17 patients undergoing laparoscopic hiatal hernia repair using human acellular dermal matrix. Two small recurrent hernias were seen on follow-up barium studies and 1 patient

reported mild dysphagia. Ringley et al²⁰ compared 22 patients undergoing cruroplasty reinforced with human acellular dermis to 22 historical controls undergoing primary suture-based cruroplasty. The authors report a 9% recurrence with primary sutured cruroplasty and 0% recurrence with the human acellular dermis onlay reinforced cruroplasty. Our current series adds to the experience with human acellular dermis in paraesophageal hernia repair. Of the 46 patients undergoing repair, 43 had AlloMax (CR Bard, Warwick, RI) while 2 had Flex HD (Musculoskeletal Transplant Foundation, Edison, NJ), and 1 had AlloDerm (LifeCell, Branchburg, NJ). Five of the repairs were performed for recurrent hernias. Four of these repairs had been performed previously at other facilities without the use of mesh. One patient had previously undergone repair with a biologic mesh. Barium esophagrams were available in 26 patients between 6 weeks and 1 year postoperatively. Our series demonstrated 2 symptomatic recurrences noted in 46 patients. Both of these patients underwent a barium esophagram as part of a clinical evaluation of their recurrent symptoms. The first patient had recurrent reflux symptoms with a barium esophagram at 4.5 months after surgery, showing a 2-cm recurrent hernia with associated reflux. The patient underwent endoscopy, which demonstrated esophagitis. He was initially treated with proton pump inhibitors but ultimately elected to proceed with revisional surgery. At the time of revisional surgery, his crural closure had separated, resulting in a posterior recurrence of the hiatal hernia. The human acellular dermal graft remained visible only in the areas overlying the crural fibers. There was no evidence of the graft in the area of the hernia recurrence. The crural defect was repaired with primary crural closure and placement of a human acellular dermal graft. He remains symptom free 6 months following his revisional surgery. The second patient with a recurrence had initially undergone repair of a recurrent hiatal hernia. She had dysphagia preoperatively and continued to complain of mild postoperative dysphagia. A small recurrent hernia was noted on barium swallow 4 months postoperatively, and EGD revealed a 2-cm sliding hiatal hernia. The patient underwent a repeat barium esophagram 1 year following her surgery, which demonstrated a stable recurrent hiatal hernia.

This series describes the utilization of a hernia stapler to secure the human acellular dermis to the diaphragm. With an open staple height of 4.0mm, care must be taken to avoid placement into tissues directly overlying vascular structures. However, the staple design allows for the tissue to be pulled into the stapler rather than pushing the

stapler firmly into the diaphragm, thus reducing the potential for injury. Although the strength of attachment of the tacks is not measured, the circumferential staples result in secure fixation of the graft. Additionally, circumferential placement of staples also allows for the graft to be placed smoothly opposed to the diaphragm to allow for maximal vascular ingrowth. In our study, no complications occurred as a result of the utilization of a stapler for placement of the mesh.

Laparoscopic paraesophageal hernia repair with human acellular dermis has low recurrences rates similar to that in other series (Table 2). Mesh-related complications, such as erosions and stricture, have been reported with synthetic mesh products at the hiatus.^{11-14,21,22} Stadlhuber et al²² compiled a 28 case series of patients with mesh complications after having undergone hiatal hernia repair with mesh. Seven of the 28 patients' complications involved biologic mesh products and include 1 esophageal erosion, 4 cases of esophageal stenosis, and 2 patients with dense fibrosis. In our series, there was no mesh erosion. This series reports a 13% incidence of postoperative dysphagia. Six patients report persistent dysphagia to solids. Two of these patients experienced dysphagia prior to their operation. Preoperative dysphagia has been shown to correlate with the incidence of postoperative dysphagia.⁵ In only 1 of the 6 patients with postoperative dysphagia was an anatomic narrowing appreciated on barium imaging. This was the patient in which an intraoperative esophageal perforation was identified and repaired primarily. This patient did not have any immediate postoperative sequelae from the iatrogenic bougie injury, but has required endoscopic esophageal dilation with improvement of her symptoms. Although biologic mesh may play a role in reducing the risk of hiatal hernia recurrence, there may be a resultant increased risk of dysphagia associated with its use at the esophageal hiatus. In the previously mentioned prospective trial, patients with mesh at the hiatus had a higher dysphagia symptom severity score 6 months following their operation than those repaired without mesh.¹⁵

The routine use of mesh as a reinforcement to the crural closure at the time of hiatal hernia repair remains a topic of debate. In a large retrospective study of hiatal hernia repairs, the selective use of reinforcing mesh in as few as 12% of patients resulted in a clinical recurrence rate of 3%.⁵ In the aforementioned study, the utilization of mesh was associated with an increased odds ratio for reoperation for recurrence, suggesting that the ideal approach is unknown. On the contrary, a prospective randomized trial utilizing small intestinal submucosal mesh as a reinforcement demonstrated a reduction in radiographic recurrences from 24% without mesh to 9% with mesh at 6 months follow-up, thus suggesting a benefit to routine mesh reinforcement. But, the long-term durability of the mesh repair remains an area of uncertainty. Laparoscopic hiatal hernia repair is a difficult operation and its successful accomplishment requires meticulous dissection to achieve adequate esophageal mobilization and crural dissection without vagal or visceral injuries. Appropriate utilization of esophageal lengthening procedures is also paramount to long-term success.

The routine utilization of mesh reinforcement of the hiatus attempts to minimize recurrences by offloading tension on the crural closure. Routine use of biologic mesh is safe with few reported mesh complications, although side effects and complications are possible. Prospective studies that delineate objective criteria for mesh utilization following hiatal hernia repair are necessary to adopt a selective approach.

In our study, 19 patients received gastrostomy tubes, resulting in 1 tube-related complication. Of the 2 recurrent hernias that occurred, one patient was treated with a gastrostomy tube and one patient was treated without a gastrostomy tube. The authors have since abandoned the utilization of gastrostomy tubes during hiatal hernia repair, because we do not feel such tubes offer any significant advantage.

CONCLUSION

Laparoscopic paraesophageal hernia repair with human acellular dermis reinforced cruroplasty is feasible and safe. Fixation of the graft may be safely performed with a hernia stapler. The use of human acellular dermis as a crural reinforcement results in a low hernia recurrence rate. However, there is likely a tradeoff between recurrence rate and dysphagia. Long-term follow-up is needed to better understand the implications of placing a human acellular dermal graft at the esophageal hiatus during paraesophageal hernia repairs.

Table 2.
Series Utilizing Human Acellular Dermal Matrix

Series	Recurrence	Dysphagia
Wisbach ¹⁷	1/11 (9.1%)	1/11 (9.1%)
Lee E ¹⁶	2/17 (11.8%)	1/17 (5.9%)
Lee Y ¹⁵	2/52 (3.8%)	Not reported
Current series	2/46 (4.3%)	6/46 (13.0%)

References:

1. Athanasakis H, Tzortzinis A, Tsiaoussis J, Vassilakis JS, Xynos E. Laparoscopic repair of paraesophageal hernia. *Endoscopy*. 2001;33:590–594.
2. Hashemi M, Peters JH, DeMeester TR, et al. Laparoscopic repair of large type III hiatal hernia: objective follow-up reveals high recurrence rate. *J Am Coll Surg*. 2000;190:553–560.
3. Mattar SG, Bowers SP, Galloway KD, Hunter JG, Smith CD. Long-term outcome of laparoscopic repair of paraesophageal hernia. *Surg Endosc*. 2002;16:745–749.
4. Diaz S, Brunt LM, Klingensmith ME, Frisella P, Soper NJ. Laparoscopic paraesophageal hernia repair, a challenging operation: medium-term outcome of 116 patients. *J Gastrointest Surg*. 2003;7:59–66.
5. Luketich JD, Nason KS, Christie NA, et al. Outcomes after a decade of laparoscopic giant paraesophageal hernia repair. *J Thorac Cardiovasc Surg*. 2010;139:395–405.
6. Luijendijk RW, Hop WCJ, Van Den Tol P, et al. A comparison of suture repair with mesh repair for incisional hernia. *N Engl J Med*. 2000;343:392–398.
7. Frantzides CT, Madan AK, Carlson MA, Stavropoulos GP. A prospective randomized trial of laparoscopic polytetrafluoroethylene (PTFE) patch repair vs simple cruroplasty for large hiatal hernia. *Arch Surg*. 2002;137:649–652.
8. Carlson MA, Richards CG, Frantzides CT. Laparoscopic reinforcement of hiatal herniorrhaphy. *Diag Surg*. 1999;16:407–410.
9. Frantzides CT, Richards CG, Carlson MA. Laparoscopic repair of large hiatal hernia with polytetrafluoroethylene. *Surg Endosc*. 1999;13:906–908.
10. Johnson JM, Carbonell AM, Carmody BJ, et al. Laparoscopic mesh hiatoplasty for paraesophageal hernias and fundoplications. A critical analysis of the available literature. *Surg Endosc*. 2006;20:362–366.
11. Casabella F, Sinanan M, Horgan S, Pellegrini CA. Systematic use of gastric fundoplication in laparoscopic repair of paraesophageal hernias. *Am J Surg*. 1996;171:485–489.
12. Carlson MA, Condon RE, Ludwig KA, Schulte WJ. Management of intrathoracic stomach with polypropylene mesh prosthesis reinforced transabdominal hiatus hernia repair. *J Am Coll Surg*. 1998;187:227–230.
13. Edelman DS. Laparoscopic paraesophageal hernia repair with mesh. *Surg Laparosc Endosc*. 1995;5:32–37.
14. Trus TL, Bax T, Richardson WS, et al. Complications of laparoscopic paraesophageal hernia repair. *J Gastrointest Surg*. 1997;1:221–228.
15. Oelschläger BK, Pellegrini CA, Hunter J, et al. Biologic prosthesis reduces recurrence after laparoscopic paraesophageal hernia repair. *Ann Surg*. 2006;244:481–490.
16. Lee YK, James E, Bochkarev V, Vitamvas M, Oleynikov D. Long-term outcome of cruroplasty reinforcement with human acellular dermal matrix in large paraesophageal hiatal hernia. *J Gastrointest Surg*. 2008;12:811–815.
17. Lee E, Frisella MM, Matthews BD, Brunt LM. Evaluation of acellular human dermis reinforcement of the crural closure in patient with difficult hiatal hernias. *Surg Endosc*. 2007;21:641–645.
18. Wisbach G, Peterson T, Thoman D. Early results of the use of acellular dermal allograft in type III paraesophageal hernia repair. *JSLS*. 2006;10:184–187.
19. Frantzides CT, Carlson MA, Loizides S, et al. Hiatal hernia repair with mesh: a survey of SAGES members. *Surg Endosc*. 2009;24:1017–1024.
20. Ringley CD, Bochkarev V, Ahmed SI, Vitamvas ML, Oleynikov D. Laparoscopic hiatal hernia repair with human acellular dermal matrix patch: our initial experience. *Am J Surg*. 2006;192:767–772.
21. Hazebroek EJ, Leibman S, Smith GS. Erosion of a composite PTFE/ePTFE mesh after hiatal hernia repair. *Surg Laparosc Endosc Percut Tech*. 2006;19:175–177.
22. Stadlhuber RJ, El Sherif A, Mittal SK, et al. Mesh complications after prosthetic reinforcement of hiatal closure: a 28 case series. *Surg Endosc*. 2009;23:1219–1226.