

Traumatic Subarachnoid Hemorrhage Resulting from Posterior Communicating Artery Rupture

This article was published in the following Dove Press journal:
International Medical Case Reports Journal

Jiha Kim ^{1,2}
Seung Jin Lee^{1,2}

¹Department of Neurosurgery, Kangwon National University School of Medicine, Chuncheon-Si, Gangwon-Do, South Korea; ²Department of Neurosurgery, Kangwon National University Hospital, Chuncheon-Si, Gangwon-Do, South Korea

Abstract: Traumatic subarachnoid hemorrhage (SAH), a common finding following head trauma, is usually a benign condition with a favorable outcome, seldom requiring surgical intervention. Unlike nontraumatic aneurysmal SAH, most cases of traumatic SAH occur in the sulci of the cerebral convexities, and only rarely arise at the base of the brain. Basal traumatic SAH can be life-threatening and is primarily associated with rupture of vertebral-basilar arteries. We herein present a rare case of basal traumatic SAH resulting from rupture of the posterior communicating artery (PCoA). A 77-year-old male was taken to the emergency department in a semicomatose state. Upon arrival at emergency room, the patient had a Glasgow coma scale (GCS) score of 6 (E1M3V2), and the neurologic examination demonstrated no focal neurologic deficit. Although the trauma history was evident from abrasions and bruising on the face and chest, brain computed tomography (CT) demonstrated basal SAH, which is typical for nontraumatic aneurysmal SAH. Subsequent digital subtraction angiography (DSA) disclosed a traumatic rupture at the mid-portion of right PCoA and ongoing extravasation of contrast media. Despite emergent trapping of the right PCoA by endovascular surgery, the patient's clinical condition only minimally improved. The patient remained bed-ridden with stuporous mentality and persistent hydrocephalus. To the best of our knowledge, this is the first reported case of basal traumatic SAH originating from rupture of the PCoA. This case demonstrates that a meticulous vascular workup is mandatory for every patient with basal SAH, even though a trauma history is clear.

Keywords: traumatic subarachnoid hemorrhage, traumatic rupture, posterior communicating artery

Introduction

Traumatic subarachnoid hemorrhage (SAH) is the pathologic presence of blood within the subarachnoid spaces, typically the superficial sulci along the cerebral convexities.^{1,2} It is the second most common acute brain injury finding on computed tomography (CT) in traumatic brain injury (TBI) patients.³ Traumatic SAH in patient with mild TBI is a favorable finding not likely to require surgical intervention;¹⁻⁷ the mortality rate in these patients is not different from that in concussion patients.³ Some investigators have even proposed that routine neurosurgical consultation⁶ or intensive care unit admission is not mandatory in the absence of other significant trauma or clinical deterioration.^{1,7}

However, if the traumatic SAH arises at the base of the brain, it can be a life-threatening condition.^{8,9} Although basal SAH usually results from a nontraumatic cause such as aneurysm rupture or vascular malformation, trauma is also a cause.⁸ Basal traumatic SAH is very rare, representing only 1.8% of all SAH cases

Correspondence: Jiha Kim
Department of Neurosurgery, Kangwon National University School of Medicine, 1 Gangwondaehak-gil, Chuncheon-Si, Gangwon-Do 24341, South Korea
Tel +82-33-258-2410
Fax +82-33-258-9489
Email dopaa@naver.com

diagnosed during autopsy.¹⁰ Its CT finding and clinical course are totally different from those of usual traumatic SAH arising within the convexity of superficial sulci. The vast majority of basal traumatic SAHs are associated with rupture of vertebrobasilar arteries.^{8,9}

In this report, we present the case of a patient with basal traumatic SAH. Our case is unique in that the basal traumatic SAH originated from a traumatic rupture of the posterior communicating artery (PCoA). To the best of our knowledge, this is the first reported case of basal traumatic SAH resulting from rupture of the PCoA.

Case Report

The case review was conducted according to all guidelines outlined in the Declaration of Helsinki. Written informed consent for publication of any case details and any accompanying images was obtained from the patient's family. A 77-year-old male was taken to our emergency department after being found at the foot of a flight of stairs in a semicomatose state. Although nobody witnessed the fall, the trauma was apparent from multiple abrasions and bruising on the face and chest. Upon arrival at the emergency room, the Glasgow coma scale (GCS) score was 6 (E1M3V2), and the pupil size and light reflex were intact. The neurologic examination demonstrated no focal neurologic deficits, including motor weakness or sensory change in all four extremities. The patient had no underlying disease such as hypertension, diabetes, or heart disease, and did not take any medication that induces coagulopathy.

Initial CT of the brain disclosed diffuse SAH of the basal cistern, accompanying intraventricular hemorrhage (IVH), and hydrocephalus, which are common in nontraumatic aneurysmal SAH (Figure 1). Despite the external wounds

and skull fracture, the appearance of the SAH was different from that of usual traumatic SAH, which typically shows small amounts of blood in the sulci of the cerebral convexities. We suspected that an aneurysm might have ruptured spontaneously just before the patient fell down the stairs, causing trauma secondarily. However, the subsequent head and neck CT angiography failed to reveal a cerebral aneurysm or other vascular malformation that could give rise to basal SAH.

We performed extraventricular drainage (EVD) emergently at the right Kocher's point to relieve the hydrocephalus. The opening pressure was as high as 15 cm H₂O and the intracranial pressure (ICP) decreased after draining the bloody cerebrospinal fluid (CSF). However, the patient showed minimal neurologic improvement postoperatively.

After stabilizing the ICP, we performed digital subtraction angiography (DSA) to identify a cerebral aneurysm or other vascular malformation that might have been missed on CT angiography. The DSA disclosed a 1.8 mm sized traumatic pseudoaneurysm at the mid-portion of the right PCoA that was inapparent on CT angiography (Figure 2). We observed extravasation of contrast media from it, resulting in basal SAH (Figure 2B). In this manner, because no other aneurysm or pre-existing vascular abnormality was found on DSA, the patient's basal SAH was confirmed as traumatic in origin.

After confirming adequate blood flow of the right posterior cerebral artery through the posterior circulation, we performed endovascular trapping from the mid- to distal portion of the right PCoA using coils (Figure 3A and B). There was no intraoperative unexpected event or thromboembolic complication. Postoperatively, we confirmed the absence of extravasated contrast media and intactness and patency of the collateral vessels (Figure 3C and D). Despite successful trapping of the PCoA, the patient had

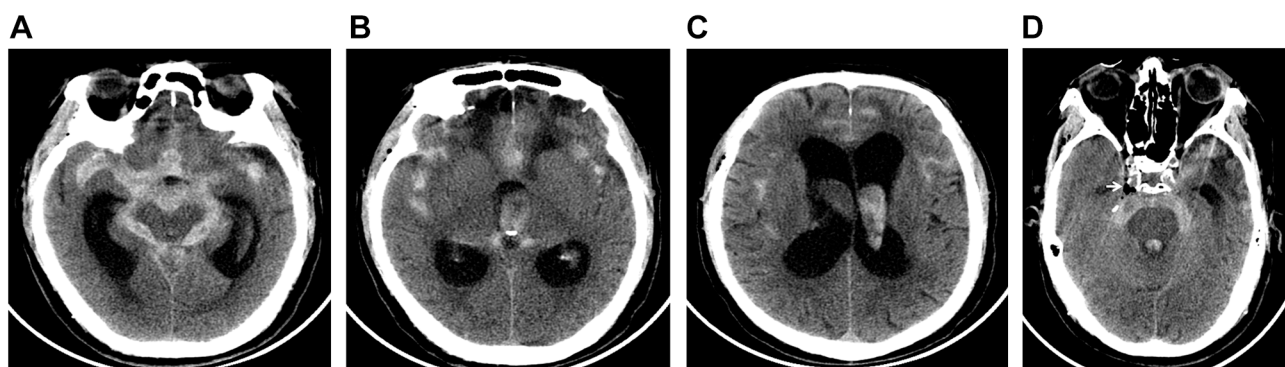


Figure 1 Initial non-enhanced brain CT showing basal SAH.

Notes: (A) Diffuse and thick SAH at the base of brain including the basal cistern, (B, C) accompanying IVH and hydrocephalus, and (D) the pneumocephalus (white arrow) suggesting basal skull fracture.

Abbreviations: CT, computed tomography; SAH, subarachnoid hemorrhage; IVH, intraventricular hemorrhage.

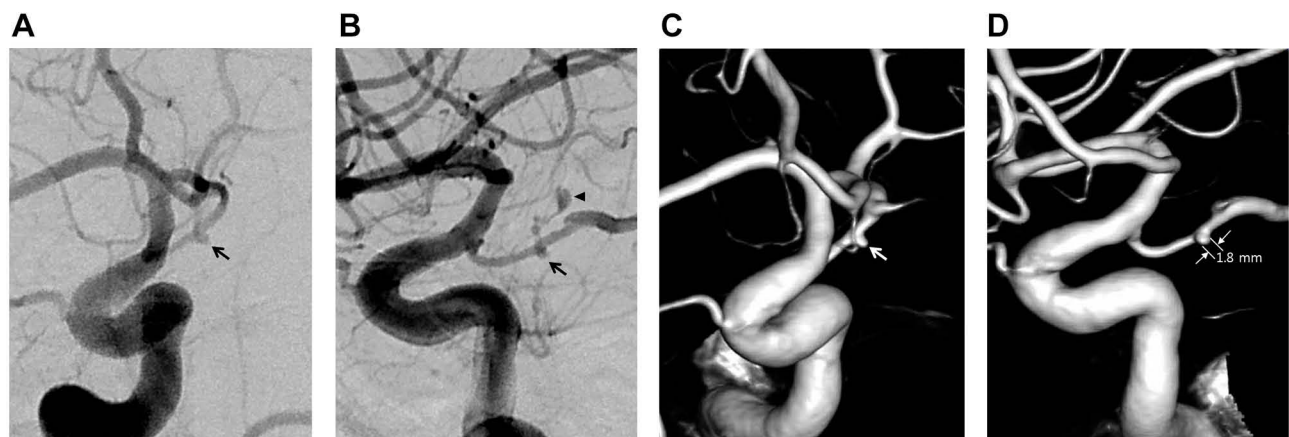


Figure 2 Subsequent DSA disclosing the rupture point at the mid-portion of the right PCoA.

Notes: (A, B) A pseudoaneurysm (black arrow) of the right PCoA and the extravasation of contrast media (black arrowhead) (A) oblique view, (B) lateral view. (C, D) Three-dimensional DSA showing a pseudoaneurysm (white arrow), 1.8 mm in diameter (C) oblique view, (D) lateral view).

Abbreviations: DSA, digital subtraction angiography; PCoA, posterior communicating artery.

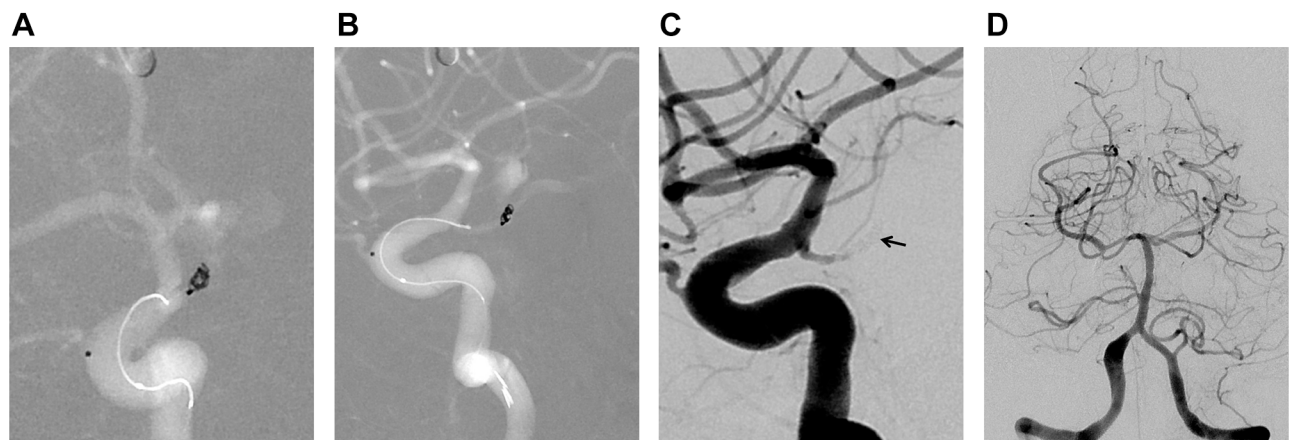


Figure 3 Endovascular surgery and postoperative DSA.

Notes: (A, B) Trapping of the right PCoA using coils (A) oblique view, (B) lateral view. (C) Complete occlusion of the right PCoA after the trapping and (D) intact flow of the right posterior cerebral artery after the trapping (C) lateral view, (D) anteroposterior view).

Abbreviations: DSA, digital subtraction angiography; PCoA, posterior communicating artery.

an unfavorable clinical course. Although the patient's mental status improved minimally, to stuporous mentality, the hydrocephalus persisted, requiring repeated EVD. The patient did not recover alert mentality and was transferred to another local hospital.

Discussion

Traumatic SAH is a common radiologic finding on CT after blunt TBI.^{1,5} The incidence of isolated traumatic SAH is reportedly up to 82% in patients with mild TBI.² CT imaging in these cases most commonly shows small amounts of blood in the sulci of the cerebral convexities.¹¹ It was clear that our patient had sustained trauma, considering the multiple external wounds and skull fracture on

initial CT. However, CT images showed a basal SAH, which usually results from a nontraumatic cause such as aneurysm rupture or vascular malformation, rather than a convexity SAH.^{8,10} The basal traumatic SAH observed in our case is a rare finding.¹⁰ Thus, we considered that the basal SAH in our patient might have stemmed from non-traumatic aneurysm rupture, followed by falling down the stairs, until the DSA demonstrated the traumatic pseudoaneurysm and the extravasation of contrast media verified it as the origin of bleeding.

Traumatic intracranial aneurysms are rare, accounting for less than 1% of all intracranial aneurysms.^{12,13} Pseudoaneurysms are considered to be the most common type of traumatic aneurysms.¹² Their risk of re-bleeding is

high because they increase in size faster than true aneurysms,¹² and re-bleeding may occur after resorption of surrounding edema and hematoma.¹¹

Although we describe the traumatic vascular lesion in our patient as a pseudoaneurysm, the condition of the arterial wall has not been confirmed pathologically. Because we performed endovascular surgery instead of craniotomy, there were limitations to explore the bleeding focus meticulously and we could not acquire any specimens for pathologic examination. Thus, the radiologic image was practically the only information to differentiate the pseudo- from true aneurysm. Most PCoA aneurysms originate from the junction of internal carotid artery (ICA) with PCoA and few of them arise from PCoA itself.¹⁴⁻¹⁶ Only 0.1%-2.8% of all intracranial aneurysm arises from PCoA itself like our cases.¹⁴⁻¹⁶ And the size of our aneurysm was only 1.8 mm, which was not detectable on CT angiography. We think that it was much smaller than most true aneurysms which are commonly seen in basal SAH. Although the location and size suggest pseudoaneurysm in our case, it is difficult to completely rule out the probability of traumatic rupture of pre-existing true aneurysm without pathological confirmation. Basal traumatic SAH is known to be primarily associated with rupture of the vertebrobasilar arteries.^{8,9} However, the rupture point in our patient was located at the mid-portion of the right PCoA, which has not been previously reported regardless of the type of aneurysm.

Unlike an idiopathic aneurysm where a true aneurysm wall exists, a pseudoaneurysm does not have a true wall and cannot be packed with detachable coils.¹⁷ Thus, the more applicable treatment option is total occlusion of the affective vessel.¹⁷ In this case, we occluded the ruptured PCoA from the mid- to distal portion by an endovascular approach and checked the patency of collateral vessels. Because bleeding was ongoing during the DSA, we opted to perform immediate endovascular surgery rather than conventional open surgery.

Nevertheless, the clinical outcome of our patient was unfavorable, probably owing to the extensive initial insult, which caused thick SAH, IVH, and hydrocephalus. The patient's traumatic SAH originated from rupture of a major artery in the circle of Willis, where collateral vessels are abundant. Unlike our case, most cases of traumatic SAH are caused by bleeding from small superficial veins rather than arteries.¹¹ In contrast to most cases of isolated traumatic SAH, which has favorable outcomes,^{5,18} basal traumatic SAH is a life-threatening condition.^{8,9}

In basal traumatic SAH, the proposed mechanisms of vertebral artery (VA) injury are: 1) direct trauma to the vessel, 2) extensive stretching of the vessel during hyperextension or rotation of the neck, 3) oscillation of the brain with shearing force, and 4) increased intravascular pressure.⁹ Saito et al¹³ also proposed that the mechanisms of traumatic aneurysm of the supraclinoid ICA are: 1) direct injury due to a basal skull fracture, 2) overstretching or torsion of the ICA, and 3) possible tearing by nearby prominent bony structures such as the anterior or posterior clinoid process. Before applying these mechanisms to our case, we believe the anatomical differences between the PCoA and these other vessels should be considered.

Considering the skull fracture in our patient, there must have been a certain degree of direct trauma to the PCoA. However, we think that the impact was not a major contributor to the vascular injury, because the direct trauma did not produce cerebral parenchymal damage such as contusion or intracerebral hemorrhage near the PCoA. Also, the PCoA is surrounded by brain tissue and CSF, which buffer the external impact. Moreover, there is no prominent bony structure along the course of PCoA, unlike that of the ICA, which has the anterior or posterior clinoid process nearby. Therefore, we believe that the effect of direct trauma to the PCoA is unlikely to be same as that of direct trauma to the VA or ICA. Furthermore, the PCoA runs deep in the skull base far from the craniocervical junction and is not likely to be affected by neck motion, in contrast to the VA, which is vulnerable to extensive stretching during excessive neck motion.

We believe that oscillation or other movement of the brain must have played an important role in our case. Oscillation of the brain may have induced overstretching or torsion of the PCoA and its perforators at the time of impact, producing their rupture. The cerebral atrophy in our patient likely affected the extent of brain oscillation and the consequent injury to the PCoA. Sato et al⁸ also reported the case of traumatic basal SAH from atrophic cerebellum. Because the brain did not fully pack the cranial cavity, it was more movable at the time of trauma, causing mechanical stress of the PCoA and its perforators.⁸

Conclusion

To the best of our knowledge, this is the first reported case of basal traumatic SAH originating from rupture of the PCoA. We believe that a meticulous vascular workup is

mandatory in patients with basal SAH, even with a clear trauma history, because the hemorrhage may originate from a traumatic pseudoaneurysm and the treatment and outcome are totally different from those of usual traumatic SAH.

Acknowledgments

This research did not receive any specific grant from funding agencies in the public, commercial, or not-for-profit sectors. This case review was approved by the Institutional Review Board (IRB) of the Kangwon National University Hospital (2020-01-009).

Disclosure

The authors declare that there are no conflicts of interest in this work.

References

1. Witiw CD, Byrne JP, Nassiri F, Badhiwala JH, Nathens AB, da Costa LB. Isolated traumatic subarachnoid hemorrhage: an evaluation of critical care unit admission practices and outcomes from a North American perspective. *Crit Care Med*. 2018;46(3):430–436. doi:10.1097/CCM.0000000000002931
2. Nassiri F, Badhiwala JH, Witiw CD, et al. The clinical significance of isolated traumatic subarachnoid hemorrhage in mild traumatic brain injury: a meta-analysis. *J Trauma Acute Care Surg*. 2017;83(4):725–731. doi:10.1097/TA.0000000000001617
3. Levy AS, Orlando A, Hawkes AP, Salottolo K, Mains CW, Bar-Or D. Should the management of isolated traumatic subarachnoid hemorrhage differ from concussion in the setting of mild traumatic brain injury? *J Trauma*. 2011;71(5):1199–1204. doi:10.1097/TA.0b013e31822067fc
4. Hayashi T, Karibe H, Narisawa A, Kameyama M. Delayed deterioration in isolated traumatic subarachnoid hemorrhage. *World Neurosurg*. 2016;86(511):e519–514. doi:10.1016/j.wneu.2015.09.108
5. Lee JJ, Segar DJ, Asaad WF. Comprehensive assessment of isolated traumatic subarachnoid hemorrhage. *J Neurotrauma*. 2014;31(7):595–609. doi:10.1089/neu.2013.3152
6. Cooper SW, Bethea KB, Skrobot TJ, et al. Management of traumatic subarachnoid hemorrhage by the trauma service: is repeat CT scanning and routine neurosurgical consultation necessary? *Trauma Surg Acute Care Open*. 2019;4(1):e000313. doi:10.1136/tsaco-2019-000313
7. Quigley MR, Chew BG, Swartz CE, Wilberger JE. The clinical significance of isolated traumatic subarachnoid hemorrhage. *J Trauma Acute Care Surg*. 2013;74(2):581–584. doi:10.1097/TA.0b013e31827d6088
8. Sato T, Tsuboi K, Nomura M, et al. Traumatic basal subarachnoid hemorrhage suspected to have been caused by contrecoup cerebellar contusions: a case report. *Leg Med (Tokyo)*. 2014;16(2):92–94. doi:10.1016/j.legalmed.2013.12.004
9. Kim S. Vague longitudinal tears of the intracranial vertebral artery in traumatic basal subarachnoid hemorrhage. *J Pathol Transl Med*. 2019.
10. Skowronek R, Kobek M, Jankowski Z, et al. Traumatic basal subarachnoid haemorrhage or ruptured brain aneurysm in 16-year-old boy? - case report. *Arch Med Sadowej I Kryminologii*. 2016;66(1):32–40. doi:10.5114/amsik.2016.62333
11. Nakstad PH, Gjertsen O, Pedersen HK. Correlation of head trauma and traumatic aneurysms. *Interv Neuroradiol*. 2008;14(1):33–38. doi:10.1177/159101990801400104
12. Purgina B, Milroy CM. Fatal traumatic aneurysm of the posterior inferior cerebellar artery with delayed rupture. *Forensic Sci Int*. 2015;247:e1–5. doi:10.1016/j.forsciint.2014.11.003
13. Saito K, Baskaya MK, Shibuya M, Suzuki Y, Sugita K. False traumatic aneurysm of the dorsal wall of the supraclinoid internal carotid artery—case report. *Neurol Med Chir (Tokyo)*. 1995;35(12):886–891. doi:10.2176/nmc.35.886
14. He W, Gandhi CD, Quinn J, Karimi R, Prestigiacomo CJ. True aneurysms of the posterior communicating artery: a systematic review and meta-analysis of individual patient data. *World Neurosurg*. 2011;75(1):64–72; discussion 49. doi:10.1016/j.wneu.2010.09.012
15. Nery B, Araujo R, Burjaili B, Smith TR, Rodrigues JC Jr., Silva MN. “True” posterior communicating aneurysms: three cases, three strategies. *Surg Neurol Int*. 2016;7:2. doi:10.4103/2152-7806.173307
16. Takeda M, Kashimura H, Chida K, Murakami T. Microsurgical clipping for the true posterior communicating artery aneurysm in the distal portion of the posterior communicating artery. *Surg Neurol Int*. 2015;6(1):101. doi:10.4103/2152-7806.158515
17. Moon TH, Kim SH, Lee JW, Huh SK. Clinical analysis of traumatic cerebral pseudoaneurysms. *Korean J Neurotrauma*. 2015;11(2):124–130. doi:10.13004/kjnt.2015.11.2.124
18. Deepika A, Munivenkatappa A, Devi BI, Shukla D. Does isolated traumatic subarachnoid hemorrhage affect outcome in patients with mild traumatic brain injury? *J Head Trauma Rehabil*. 2013;28(6):442–445. doi:10.1097/HTR.0b013e31825e19e5

International Medical Case Reports Journal

Publish your work in this journal

The International Medical Case Reports Journal is an international, peer-reviewed open-access journal publishing original case reports from all medical specialties. Previously unpublished medical posters are also accepted relating to any area of clinical or preclinical science. Submissions should not normally exceed 2,000 words or 4

published pages including figures, diagrams and references. The manuscript management system is completely online and includes a very quick and fair peer-review system, which is all easy to use. Visit <http://www.dovepress.com/testimonials.php> to read real quotes from published authors.

Submit your manuscript here: <https://www.dovepress.com/international-medical-case-reports-journal-journal>

Dovepress