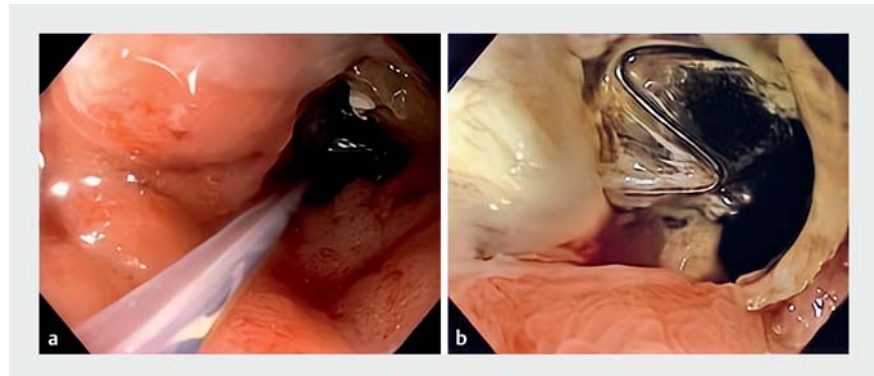


Duodenal stent fixation using through-the-scope helix tack and suture device

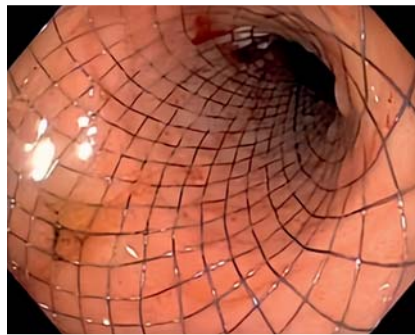


Malignant gastroduodenal strictures are often managed with endoscopic stent placement [1]. One of the main limitations of duodenal self-expanding metal stents (SEMSs) is the risk of migration [2]. Multiple techniques have been used to prevent stent migration, including stent fixation using through-the-scope (TTS) clips, over-the-scope stent fixation devices, and endoscopic suturing [3,4]. TTS suturing using the helix tack and suture device is a novel suturing method that is generally used for defect closure, though it has been rapidly gaining popularity for alternate uses [5].

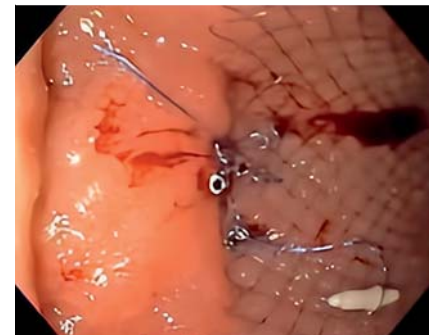
A 73-year-old man with pancreatic adenocarcinoma on neoadjuvant chemotherapy presented with 3 weeks of vomiting and abdominal distension. Imaging showed pancreatic adenocarcinoma with duodenal obstruction. Esophagogastroduodenoscopy showed duodenal stenosis caused by tumor infiltration at the duodenal sweep (► Fig. 1 a, b). The adult upper gastrointestinal (GI) endoscope was able to traverse the stenosis, which measured 2 cm in length, albeit with significant resistance. The tumor was borderline resectable, and according to our institutional protocol, endoscopic ultrasound-guided gastrojejunostomy is performed only for patients who are not surgical candidates; therefore, the decision was made to proceed with duodenal stent placement. An uncovered SEMS of 25 mm diameter and 10 cm length was placed across the stenosis (► Fig. 2). Given the upper GI endoscope had been able to traverse the stenosis, it was decided to fix the position of the stent. This would reduce any migration before stent expansion and tissue ingrowth could act to keep the stent in place. The TTS suturing device was used (X-Tack; Apollo Endosurgery, Austin, Texas, USA) and the stent was fixed with four tacks placed in a stent-mucosa-mucosa-stent fashion (► Fig. 3, ► Video 1). Finally, the Cinch component was deployed. No adverse events were reported within the first 4 weeks of the procedure. Duodenal SEMSs are widely used in the setting of malignant gastroduodenal obstruction. While uncovered stents typically carry a lower risk of migration compared to covered stents [1,2], in this case the apposition to the tissue was less than desired and thus the TTS suturing device was successfully used for stent fixation.



► Fig. 1 a Endoscopic image showing duodenal stenosis at the duodenal sweep. b Alternate view of duodenal stenosis; a previously placed biliary stent is seen.



► Fig. 2 Uncovered self-expanding metal stent placed across the duodenal stenosis.



► Fig. 3 Final view of the duodenal stent after fixation with four tacks placed in a stent-mucosa-mucosa-stent fashion using the through-the-scope tack and suture device.

Endoscopy_UCTN_Code_TTT_1AO_2AZ

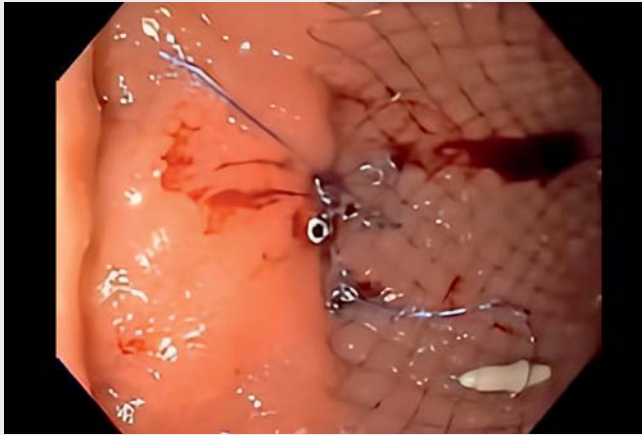
Competing interests

The authors declare that they have no conflict of interest.

The authors

Natalie Wilson¹, Nicholas McDonald², Bryant Megna², Mohamed Abdallah², Mohammad Bilal³

1 University of Minnesota Medical Center, Department of Internal Medicine, Minneapolis, MN, USA



Video 1 Duodenal stent fixation using the through-the-scope helix tack and suture device.

ENDOSCOPY E-VIDEOS

<https://eref.thieme.de/e-videos>



Endoscopy E-Videos is an open access online section, reporting on interesting cases and new techniques in gastroenterological endoscopy. All papers include a high quality video and all contributions are freely accessible online. Processing charges apply (currently EUR 375), discounts and waivers acc. to HINARI are available.

This section has its own submission website at

<https://mc.manuscriptcentral.com/e-videos>

- 2 University of Minnesota Medical Center, Division of Gastroenterology and Hepatology Minneapolis, MN, USA
- 3 Minneapolis Veterans Affairs Health Care System, Minneapolis, MN, USA

Corresponding author

Mohammad Bilal, MD

Advanced Endoscopy, Division of Gastroenterology & Hepatology, Minneapolis VA Medical Center, 1 Veterans Drive, Minneapolis, 55417, USA
billa17@hotmail.com

References

- [1] Jue TL, Storm A. ASGE Standards of Practice Committee et al. ASGE guideline on the role of endoscopy in the management of benign and malignant gastroduodenal obstruction. *Gastrointest Endosc* 2021; 93: 309–322
- [2] Tringali A, Costa D, Anderloni A et al. Covered versus uncovered metal stents for malignant gastric outlet obstruction: a systematic review and meta-analysis. *Gastrointest Endosc* 2020; 92: 1153–1163
- [3] Hori Y, Hayashi K, Naitoh I et al. Feasibility and safety of duodenal covered self-expandable metallic stent fixation: an experimental study. *Surg Endosc* 2019; 33: 4026–4031
- [4] Takahara N, Isayama H, Nakai Y et al. A novel partially covered self-expandable metallic stent with proximal flare in patients with malignant gastric outlet obstruction. *Gut Liver* 2017; 11: 481–488
- [5] Mahmoud T, Wong Kee Song LM, Stavropoulos SN et al. Initial multicenter experience using a novel endoscopic tack and suture system for challenging GI defect closure and stent fixation (with video). *Gastrointest Endosc* 2022; 95: 373–382

Bibliography

Endoscopy 2023; 55: E102–E103

DOI 10.1055/a-1944-9018

ISSN 0013-726X

published online 14.10.2022

© 2022. The Author(s).

This is an open access article published by Thieme under the terms of the Creative Commons Attribution-NonDerivative-NonCommercial License, permitting copying and reproduction so long as the original work is given appropriate credit. Contents may not be used for commercial purposes, or adapted, remixed, transformed or built upon. (<https://creativecommons.org/licenses/by-nc-nd/4.0/>)

Georg Thieme Verlag KG, Rüdigerstraße 14, 70469 Stuttgart, Germany

