

Case Report

Neurovascular complications after supracondylar humerus fractures in children☆☆☆

Maximilian Leiblein^{a,*}, Thomas Lustenberger^a, Anne-Kathrin Schulz^b,
Thomas Schmitz-Rixen^c, Ingo Marzi^a

^a Department of Trauma, Hand and Reconstructive Surgery, Hospital of the Goethe University, Theodor-Stern-Kai 7, 60590 Frankfurt am Main, Germany

^b Department of Paediatric Surgery and Paediatric Urology, University Hospital Frankfurt/M., Theodor-Stern-Kai 7, 60590 Frankfurt/M, Germany

^c Department of Vascular and Endovascular Surgery, Hospital of the Goethe University, Theodor-Stern-Kai 7, 60590 Frankfurt am Main, Germany

ARTICLE INFO

Article history:

Accepted 2 January 2017

Available online 6 January 2017

Keywords:

Median nerve

Brachial artery

Neurovascular lesion

Percutaneous pinning

Pediatric fracture

ABSTRACT

Background: Supracondylar fractures of the humerus are a common injury in pediatric traumatology. The most common operative therapy is closed reduction and percutaneous pinning using K-wires. Common complications associated with this entity are neurovascular lesions, especially of the brachial artery and the median nerve.

Methods: We report two cases of patients treated in our trauma-center with supracondylar fracture of the humerus (AO IV°) and neurovascular complications.

Results: Both patients underwent open revision and recovered completely in their further course.

Conclusion: We recommend detailed neurovascular examination initially and after reposition of the fracture. The threshold for open reduction in cases of irreducible fractures should be low. In the presence of neurovascular impairment an open revision is mandatory, even months after the initial Trauma.

Level of evidence: Level V (case report).

© 2017 Published by Elsevier Ltd. This is an open access article under the CC BY-NC-ND license (<http://creativecommons.org/licenses/by-nc-nd/4.0/>).

Introduction

Supracondylar humerus fractures are a common injury in children and account for approximately 15% of all pediatric fractures [1]. The mechanism leading to this fracture is most often a fall on the hand with fully extended elbow [2].

Primary treatment of dislocated fractures is closed reduction and percutaneous pinning with Kirschner-wires (*K-wires*) [3].

Complications following these fractures are infection, loss of reduction, non-union, cubitus varus or valgus and neurovascular lesions [4]. The incidence of vascular complications associated with supracondylar fractures ranges from 3.2 to 14.3% [5], nerve injuries are reported with a relative incidence of 12–20% [6]. Especially the brachial artery and the median nerve are at risk due to stretch forces or entrapment [2].

We report two cases of neurological and vascular complications in terms of rupture, respectively occlusion of the brachial artery and injury of the median, respectively median and ulnar nerve after closed reduction and K-wire fixation.

☆ There has been no source of support, either pharmaceutical or industry support. No funding from any organization has been received.

☆☆ None of the authors has any conflict of interests.

* Corresponding author.

E-mail address: maximilian.leiblein@kgu.com (M. Leiblein).

The aim of this article is to point out the importance of a neurovascular examination in pre- and postoperative course to prevent missing neurovascular injuries. Furthermore, we want to emphasize the good chance of an excellent outcome even after delayed revision.

Case reports

Case I

A 5-year-old boy was admitted to our clinic with a cold and pale hand as well as paralysis and hypoesthesia of the median and ulnar nerve. 2 months before he had sustained a supracondylar fracture of the right humerus (AO IV°). Primarily, closed reduction and K-wire fixation was performed via stab incision. Control X-rays showed sufficient consolidation with persisting rotationally spur as radiographic sign of rotational error. The K-wires were removed after 4 weeks (Fig. 1a, b).

Clinical and electrophysiological examination confirmed paralysis of the ulnar and median nerve, the vascular status revealed a pulseless radial and ulnar artery. MR-Angiography showed a brief but complete closure of the brachial artery (Fig. 1c).

Open revision showed immurement of the median nerve in an osseous canal of 2.5 cm length beginning at the level of the fracture. The brachial artery appeared ruptured and the ulnar nerve showed massive strictures by scar tissue. Callus was removed and extended microsurgical neurolysis of the median and ulnar nerve was performed, which both showed preserved continuity. Afterwards the brachial artery was reconstructed using a reversed segment saphenous vein graft (Fig. 2a–d).

The postoperative course was uneventful. The patient was discharged from hospital on postoperative day 2. 6 months later extensive examination detected only moderate hypoesthesia of the ulnar nerve and a limited spreading of the fingers (50% motoric recovery, partial sensory recovery). Neurological examination by electromyography (EMG) and nerve conduction velocity (NCV) study confirmed the clinical findings with gradually recovery of the nerves. Ultrasound showed an excellent flow in the distal arteries. In further course the patient recovered completely.

Case II

A 5-year-old boy presented in our emergency department 6 days after he sustained a supracondylar fracture of the right humerus (AO IV°) and underwent closed reduction and K-wire fixation (Fig. 3a–c) in an outside hospital. He complained about progressive pain, fever (37.9 °C) and postoperative hypoesthesia and impaired flexion of the index finger.

Surgical revision revealed radial fluid retention - *Staphylococcus aureus* could be isolated microbiologically and the patient was started on antibiotics. Another 10 days later pain exacerbated and impaired function of the median nerve was found.

In further open revision, a kinking of the median nerve, caused by scarred adhesions, could be found. Also, the brachial vein and artery appeared attached to the fracture gap with an arterial occlusion due to a long-distance intimal lesion. Intraoperative Doppler-sonography confirmed these findings.

The vessels were released and after a failed Fogarty-maneuver in the artery a reversed saphenous vein graft was implemented. After neurolysis of the median nerve the continuity could be preserved.

The K-wires were removed 4 weeks after the initial osteosynthesis after radiological conformation of consolidation. The infection was successfully managed by antibiotic therapy. Follow-up 3 months after discharge showed a range of motion of the elbow of 0/0/130° (extension/flexion), normal fist-closure and a persisting hypoesthesia of the index finger.

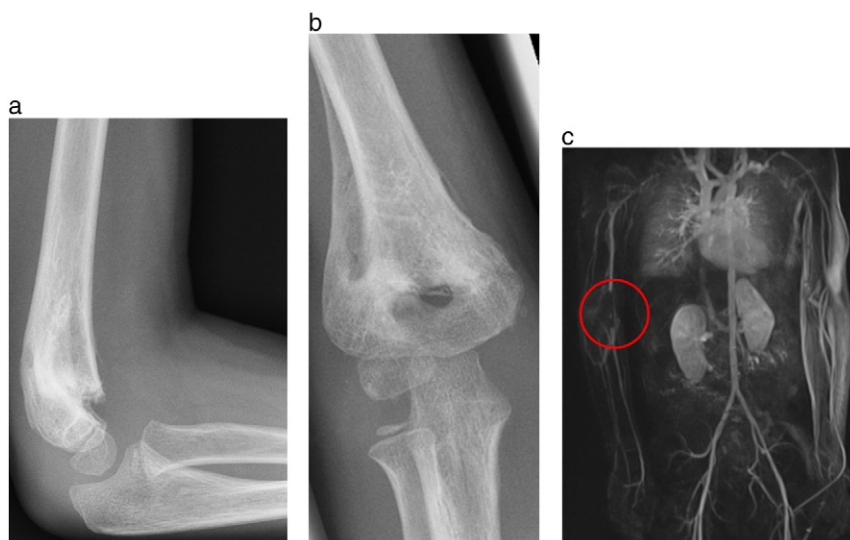


Fig. 1. a, b: postoperative X-ray after 2 months and removal of the K-wires; c: closure of the brachial artery in MR-Angiography.

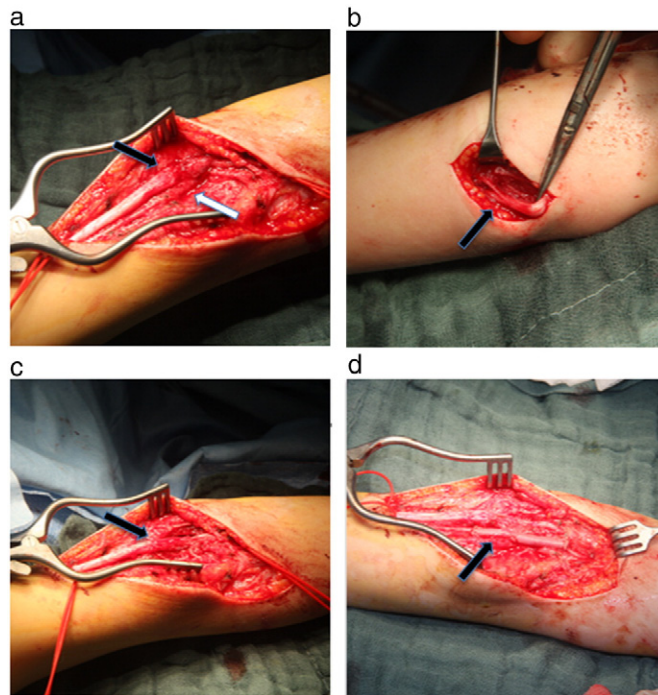


Fig. 2. a: black arrow: immurement of the median nerve, white arrow: thrombosed brachial artery; b: black arrow: scarred ulnar nerve. c: black arrow: dissected median nerve; d: black arrow: revascularisation with reversed segment saphenous vein graft.

The follow up after 6 months showed further clinical improvement with only minimal impairment of the median nerve in NCV analysis. The motion of the right hand is presented in the video (Video 1).

Discussion

About 8–10% of children with supracondylar fracture of the humerus have an associated injury of the brachial artery [2], 2.6% of the children present with a pulseless hand. Vascular compromise can be caused by arterial rupture, kinking, compression, spasm or intimal lesion and incidence increases depending on the degree of dislocation [7]. Growth-retardation can be result of conservative therapy of vascular trauma [8]. Even after reduction of the fracture, in up to 47% of the patients with initially vascular compromise, the hand remains pulseless but perfused due to entrapment of the brachial artery within the fracture side. The indication of surgical exploration and especially the appropriate timing of operation is well discussed in the literature [2,5,9,10].

Konstantiniuk et al. showed in a 14-year follow-up, that surgical reconstruction of the brachial artery is an effective therapy in regard of blood supply and growth. Still, in 7 of 10 patients they found an ectatic lesion of the saphenous vein graft [8].

The relative incidence of nerve injuries after supracondylar humerus fractures is reported with 12–20% due to traumatic tenting or entrapment and with 2–6.5% iatrogenic lesions during closed reposition or percutaneous pinning [6]. Babal et al. found the anterior interosseous nerve to be at highest risk in extension-type fractures. The ulnar nerve is most often compromised in flexion-type fractures. If pinned medially, the ulnar nerve is at risk for iatrogenic damage - the median nerve is at risk if pinning is performed laterally [11]. The median nerve is most often entrapped in the fracture [10].

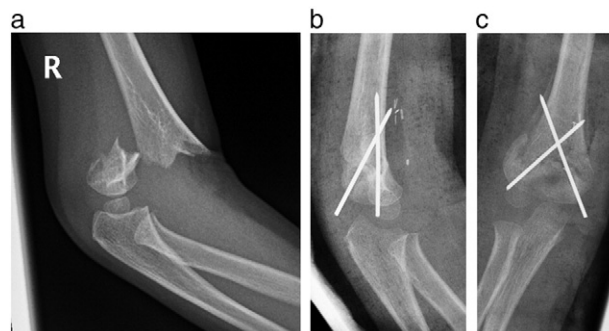


Fig. 3. a: initial X-ray after trauma; b, c: postoperative X-ray in 2 planes after revision operation.

Ramachandran et al. reported isolated nerve injuries to often recover spontaneously, however in case of co-existing ischemia they recommend a surgical exploration [6]. Mangat et al. found that in case of irreducible fractures, nerve palsy is an indication for exploration. A gap at the fracture side after reduction should alert to possible nerve or vessel entrapment [9].

Robb recommends monitoring of an initially pink and pulseless hand after closed reduction with pinning for up to 48 h. A surgical exploration of the brachial artery and affected nerve is recommended in case of deterioration of perfusion and neurological picture as well as increasing pain [12].

When a patient presents with suspected supracondylar fracture, an X-ray of the elbow in anterior-posterior and lateral projections as well as a detailed neurological and vascular examination in terms of assessment of the pulses, temperature of the limb, capillary return and pulse oximetry has to be performed [13]. Furthermore, neurological examination of median, radial and ulnar nerve (e.g. by finger crossing) is mandatory.

The most common operative therapy of AO III-IV° fractures is closed reduction and percutaneous pinning [14]. Leading to immediate fixation, reduced hospitalization and minimized risk of compartment syndrome this technique is preferable even though it is known with a “high risk for iatrogenic nerve trauma” [13]. The best timing for an operation is well discussed in literature. Schmid et al. report no significant influence of delayed treatment on rates of complications or poor outcome of displaced supracondylar humerus fractures in children. In presence of neurovascular involvement an emergent operation is indicated though [14].

In the reported cases both patients underwent closed reduction and pinning initially. In Case I the postoperative X-ray showed a remaining rotational spur indicating a probably non-anatomic reposition. Because of severe neurovascular symptoms in the further course, the patient presented in the hospital again. In open revision 2 months after trauma the median nerve appeared imbricated, in addition the brachial artery was ruptured and the ulnar nerve showed massive strictures by scar tissue. Postoperatively, the patient recovered completely after revision.

In Case II the indication to revise the fracture was given because of persisting pain and impaired function of the median nerve. We found kinking of the median nerve due to scarred adhesions and attachment of the brachial vessels to the fracture gap, probably caused by the initial reposition. This patient also showed a regular function in the further course.

We therefore recommend a precise examination of the neurovascular status initially and after reposition, if available by Doppler-sonography. In case of an irreducible fracture and neurological findings in the clinical examination an open revision is recommended.

Even months after the trauma and initial surgery, a revision is promising with regards to neurological and vascular outcome - a complete restitution is possible as both of the reported cases demonstrate.

Conclusion

The aim of this case report is to raise attention to neurovascular complications and their treatment in patients with supracondylar humerus fractures. We recommend detailed clinical examination of these patients with special attention to neurovascular findings. Furthermore, we recommend immediate surgical revision in case of nerve palsy and vascular damage. Important clinical signs are progressive or persistent pain after reduction, pulseless and cold hand, hyposensitivity and motoric deficits. A surgical revision, even after two months, can still result in excellent outcomes.

Supplementary data to this article can be found online at <http://dx.doi.org/10.1016/j.tcr.2017.01.013>.

References

- [1] L.V. Barr, Paediatric supracondylar humeral fractures: epidemiology, mechanisms and incidence during school holidays, *J. Child. Orthop.* 8 (2) (2014) 167–170.
- [2] P. Brahmamdam, M. Plummer, J.G. Modrall, et al., Hand ischemia associated with elbow trauma in children, *J. Vasc. Surg.* 54 (3) (2011) 773–778.
- [3] R.K. Bashyal, J.Y. Chu, P.L. Schoenecker, et al., Complications after pinning of supracondylar distal humerus fractures, *J. Pediatr. Orthop.* 29 (2009) 704–708.
- [4] M.E. Oetgen, G.E. Mirick, L. Atwater, et al., Complications and predictors of need for return to the operating room in the treatment of supracondylar humerus fractures in children, *Open Orthop. J.* 9 (2015) 139–142.
- [5] K.J. Griffin, S.R. Walsh, S. Markar, et al., The pink pulseless hand: a review of the literature regarding management of vascular complications of supracondylar humeral fractures in children, *Eur. J. Vasc. Endovasc. Surg.* 36 (6) (2008) 697–702.
- [6] M. Ramachandran, R. Birch, D.M. Eastwood, Clinical outcome of nerve injuries associated with supracondylar fractures of the humerus in children, *J. Bone Joint Surg. (Br.)* 88 (1) (2006) 90–94.
- [7] H. Wegmann, R. Eberl, T. Kraus, et al., The impact of arterial vessel injuries associated with pediatric supracondylar humeral fractures, *J. Trauma Acute Care Surg.* 77 (2) (2014) 381–385.
- [8] P. Konstantiniuk, G. Fritzt, T. Ott, et al., Long-term follow-up of vascular reconstructions after supracondylar humerus fracture with vascular lesion in childhood, *Eur. J. Vasc. Endovasc. Surg.* 42 (5) (2011) 684–688.
- [9] K.S. Mangat, A.G. Martin, C.E. Bache, The “pulseless pink” hand after supracondylar fracture of the humerus in children, *J. Bone Joint Surg. (Br.)* 91 (11) (2009) 1521–1525.
- [10] C.M. Blakey, L.C. Biant, R. Birch, Ischaemia and the pink, pulseless hand complicating supracondylar fractures of the humerus in childhood, *J. Bone Joint Surg. (Br.)* 91 (11) (2009) 1487–1492.
- [11] J.C. Babal, C.T. Mehlman, G. Klein, Nerve injuries associated with pediatric supracondylar humeral fractures: a meta-analysis, *J. Pediatr. Orthop.* 30 (3) (2010) 253–263.
- [12] J.E. Robb, The pink, pulseless hand after supracondylar fracture of the humerus in children, *J. Bone Joint Surg. (Br.)* 91 (11) (2009) 1410–1412.
- [13] B.K. Bhuyan, Close reduction and percutaneous pinning in displaced supracondylar humerus fractures in children, *J. Clin. Orthop. Trauma.* 3 (2) (2012) 89–93.
- [14] T. Schmid, A. Joeris, T. Slongo, et al., Displaced supracondylar humeral fractures: influence of delay of surgery on the incidence of open reduction, complications and outcome, *Arch. Orthop. Trauma Surg.* 135 (7) (2015) 963–969.