

Received: 2012.10.10  
Accepted: 2012.12.05

## Advantages of hybrid SPECT-CT imaging in preoperative localization of parathyroid glands in a patient with secondary hyperparathyroidism. A case report

Wojciech Cytawa<sup>1</sup>, Jacek Teodorczyk<sup>1</sup>, Piotr Lass<sup>1,2</sup>

<sup>1</sup> Department of Nuclear Medicine, Medical University of Gdańsk, Gdańsk, Poland

<sup>2</sup> Department of Molecular Spectroscopy, Institute of Experimental Physics, University of Gdańsk, Gdańsk, Poland

**Author's address:** Wojciech Cytawa, Department of Nuclear Medicine, Medical University of Gdańsk, Dębinki 7 St., 80-952 Gdańsk, Poland, e-mail: wcytawa@gumed.edu.pl

### Summary

<b>Background:</b>	Secondary hyperparathyroidism is a frequent complication of chronic renal failure. Patients resistant to pharmacotherapy are candidates for parathyroidectomy. Invasiveness of surgical treatment can be minimized by precise preoperative localization of parathyroid glands. Imaging modalities routinely used for this purpose are ultrasonography and MIBI-Tc99m scintigraphy.
<b>Case Report:</b>	Our case report shows advantages of co-registered computer tomography and conventional SPECT imaging (SPECT/CT) in a patient with advanced secondary hyperparathyroidism successfully treated with surgery.
<b>Results:</b>	Hybrid SPECT/CT parathyroid imaging enables better surgical planning and is superior to conventional scintigraphy.
<b>Key words:</b>	hyperparathyroidism • secondary • SPECT/CT
<b>PDF file:</b>	<a href="http://www.polradiol.com/fulltxt.php?ICID=883774">http://www.polradiol.com/fulltxt.php?ICID=883774</a>

### Background

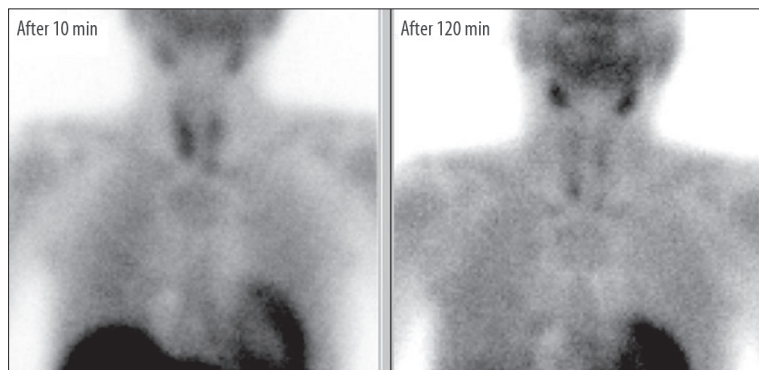
Hyperparathyroidism is a common endocrinological disorder. Primary hyperparathyroidism (PHPT) typically results from solitary parathyroid adenoma (80% of cases) and occurs in 0.1–0.35 percent of population [1–3]. Secondary hyperparathyroidism (SHPT) frequently complicates the late stages of chronic renal failure – it is encountered in 20–25% of chronically dialyzed patients [4]. The most important method of treatment of PHPT is surgical resection of hyperactive parathyroid gland, whereas in SHPT it is one of the options reserved for patients with hyperparathyroidism resistant to pharmacological therapy [5].

Effectiveness of surgical procedure is highly dependent on precise preoperative localization of lesions. A 99mTc-MIBI SPECT and neck ultrasound examination are approved as standard procedures for localizing abnormal parathyroid glands [6,7]. Sensitivity of ultrasound combined with scintigraphy in detecting single parathyroid adenomas reaches 95 percent [8,9], while in SHPT there are discrepancies in

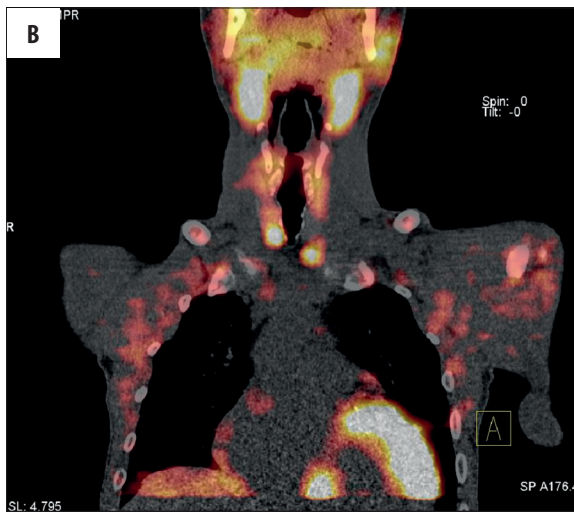
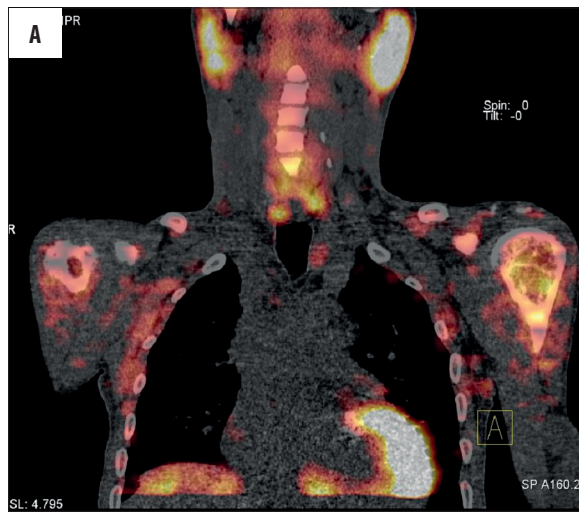
reported sensitivity of scintigraphy – it varies from 25 to 74 percent, which is much lower than in PHPT [9–12]. The role of routine MIBI scintigraphy in SHPT is still discussed, however in positive cases it can provide a surgeon with valuable information.

Several (from 5 to 6.7) percent of operated patients both with PHPT and SHPT suffer from persistent disease [13,14] after unsuccessful operation.

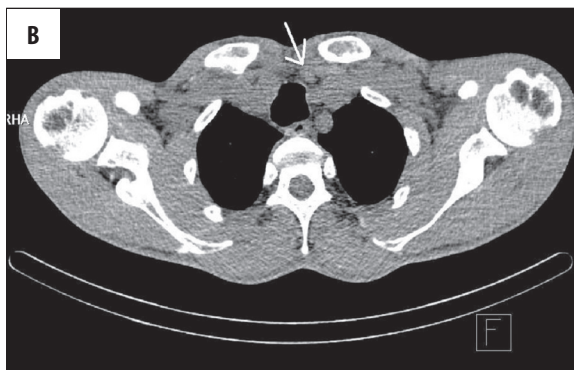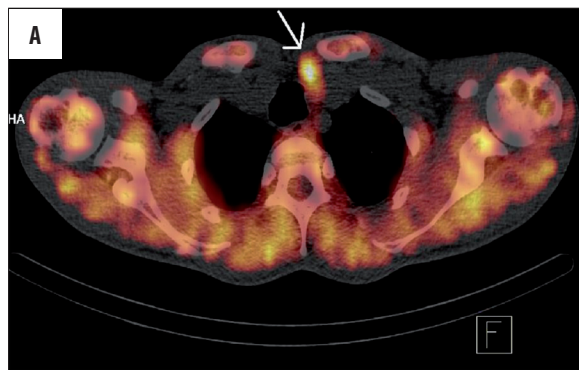
Ultrasound examination is useful in localizing eutopic adenomas and in patients with normal thyroid gland, while scintigraphy more precisely detects ectopic adenomas and is more valuable in the presence of a nodular goiter [15,16]. Some authors report that diagnostic usefulness of ultrasonography and scintigraphy is similar, but still complementary [17,18]. Hybrid SPECT-CT imaging, which integrates scintigraphic data with radiological image (computer tomography) gained high popularity and availability in recent years. However, the number of published papers evaluating clinical utility of SPECT-CT in preoperative



**Figure 1.** Dual phase 99mTc-MIBI planar scintigraphy of parathyroid glands. On the left: early phase (after 10 minutes post injection of tracer) – showing nonspecific uptake in thyroid and parathyroid glands. On the right: late phase (after 120 min) – wash-out of activity from thyroid and retention in three hyperfunctioning parathyroid glands (two inferior and left superior), one gland (right superior) is not visible.



**Figure 2.** Two images of late phase 99mTc-MIBI SPECT/CT clearly visualizing tracer retention in two inferior (A) and two superior (B) hyperactive parathyroid glands.



**Figure 3.** SPECT/CT and CT alone of the same cross-section, showing left inferior parathyroid. The best diagnostic performance is achieved by combination of detailed morphological image (CT) and functional, scintigraphic map (SPECT/CT).

mapping of hyperfunctioning parathyroid glands in SHPT exclusively is still limited [19–21]. Available articles usually encompass patients from both groups - PHPT and SHPT, predominantly the former [22–24].

**Case Report**

Our case report describes a patient who was operated due to SHPT and underwent subtotal parathyroidectomy (three and a half out of four parathyroid glands were removed) in January 2012.

In 2000, patient suffered from necrotic pancreatitis, which was complicated by renal failure. He has been hemodialyzed since 2008. In 2011, he was diagnosed with SHPT. Before the surgery, his laboratory parameters were the following: parathormone 3866 pg/ml [normal values 10–55 pg/ml], calcium 9.26 mg/dl [8.5–10.2 mg/dl], creatinine 3.57 mg/dl [0.7–1.3 mg/dl]. After surgery, parathormone level dropped to 6 pg/ml.

We performed 99mTc-MIBI scintigraphy before the surgery: traditional planar, dual-phase imaging and additional SPECT-CT imaging for precise preoperative localization of

disease sites. Planar images (Figure 1) revealed three out of four parathyroid glands depicted in SPECT/CT. Moreover, SPECT/CT provided additional information about anatomic localization of glands: superior parathyroids were situated behind the mid-lower parts of thyroid lobes, close to the esophagus (Figure 2A), while inferior glands – near the lower poles of thyroid lobes, close to the trachea (Figure 2B). Left inferior parathyroid gland is also presented on cross-section images (Figure 3A, 3B). No ectopic glands were detected.

The images are presented above.

Precise and thorough information regarding localization of lesions in our patient was delivered to the surgeon before the operation. Location of all four glands was fully confirmed by surgical exploration. A 3-mm fragment of left inferior parathyroid was left. Additionally, a tubercle of Zuckerkandl was found on the right side and removed.

## Discussion

An accurate preoperative mapping of hyperfunctioning parathyroid glands, both in PHPT and SHPT, shortens the duration of surgery, minimizes its invasiveness and decreases number of patients with recurrences, particularly in case of ectopic gland location [25].

Wimmer compared MIBI-SPECT/CT, CT alone and MIBI-SPECT alone in patients with multiglandular disease – abnormal glands were detected in 46.7%, 36.7% and 13.3% of patients, respectively [26]. Oksuz obtained different results in a group of patients with PHPT and SHPT

– sensitivity per lesion was 69 percent for planar imaging and 95 percent for both SPECT and SPECT-CT [22]. In the study by Kim, including 19 patients with PHPT and 5 patients with SHPT, SPECT/CT demonstrated 100% sensitivity per patient and had significantly better sensitivity than planar scintigraphy, SPECT and conventional imaging [23].

A 99mTc-MIBI SPECT imaging provides good localization of parathyroid glands, although our experience of cooperation with surgeons highlights the benefits of using SPECT-CT. This concerns both PHPT and SHPT. However the number of papers describing the secondary disease is small, which means that further investigation is needed to establish the value of SPECT/CT in this group of patients.

In our patient, planar imaging was insufficient, as it did not reveal all parathyroids. Furthermore, information gained from SPECT/CT allowed for their quick intraoperative localization thanks to detailed reports regarding the relation of lesions to anatomic landmarks, unavailable in both SPECT alone and planar imaging.

Additionally, effectiveness of surgery can be further improved with intraoperative detection of parathyroid glands using a hand-held gamma probe [27,28].

## Conclusions

Hybrid SPECT/CT parathyroid imaging is superior to performing SPECT imaging alone. It enables better surgical planning and improves its outcome.

## References:

- Krysiak R, Okopień B, Herman ZS: Pierwotna nadczynność przytarczyc. *Pol Arch Med Wewn*, 2005; 114: 1016–24 [in Polish]
- Mariani G, Gulec SA, Rubello D et al: Preoperative localization and radioguided parathyroid surgery. *J Nucl Med*, 2003; 44: 1443–58
- Tupikowski K, Bednarek-Tupikowska G, Zdrojowy R: Pierwotna nadczynność przytarczyc jako przyczyna kamicy nerkowej. *Urologia Pol*, 2008; 61: 1–6 [in Polish]
- Nowak Z, Konieczna M, Saracyn M et al: Doświadczenia własne w stosowaniu cynkalcectu u chorych z wtórną nadczynnością przytarczyc. *Pol Merk Lek*, 2008; 24: 303–6 [in Polish]
- Felsenfeld AJ: Considerations for the treatment of secondary hyperparathyroidism in renal failure. *J Am Soc Nephrol*, 1997; 8(6): 993–1004
- Rasmussen K, Larsen LP, Arveschoug A et al: Predictive value of parathyroid scintigraphy in the preoperative evaluation of patients with primary hyperparathyroidism. *Scand J Surg*, 2006; 95: 199–204
- Bhansali A, Masoodi SR, Bhadada S et al: Ultrasonography in detection of single and multiple abnormal parathyroid glands in primary hyperparathyroidism: comparison with radionuclide scintigraphy and surgery. *Clin Endocrinol*, 2006; 65: 340–45
- Johnson NA, Tublin ME, Ogilvie JB: Parathyroid imaging: technique and role in the preoperative evaluation of primary hyperparathyroidism. *Am J Roentgenol*, 2007; 188: 1706–15
- Gallowitsch HJ, Mikosch P, Kresnik E et al: Technetium 99m tetrofosmin parathyroid imaging. Results with double-phase study and SPECT in primary and secondary hyperparathyroidism. *Invest Radiol*, 1997; 32(8): 459–65
- Tam HT, Wong YH, Cheung SK et al: Parathyroid Scintigraphy in Primary and Secondary Hyperparathyroidism: Accuracy of Preoperative Localisation Using Combined Imaging Techniques. *J Hong Kong Col Radiol*, 2010; 13: 59–67
- Adalet I, Hawkins T, Clark F et al: Thallium-technetium-subtraction scintigraphy in secondary hyperparathyroidism. *Eur J Nucl Med*, 1994; 21(6): 509–13
- Kanegae K, Itoh K, Kato C, et al: Detection and localization of parathyroid adenomas and hyperplasias in patients with hyperparathyroidism using thallium-201/technetium-99m parathyroid subtraction scintigraphy. *Kaku Igaku*, 1994; 31(5): 441–49
- Gurrado A, Marzullo A, Lissidini G et al: Substernal oxyphil parathyroid adenoma producing PTHrP with hypercalcemia and normal PTH level. *World J Surg Oncol*, 2008; 6: 24
- Kuzdak K, Niedzialek L, Białas M: Nadczynność przytarczyc leczona chirurgicznie – doświadczenia własne i przegląd piśmiennictwa. *Pol Przegląd Chirurg*, 2005; 77: 920–34 [in Polish]
- Akerstrom G, Malmaeus J, Bergstrom R: Surgical anatomy of human parathyroid glands. *Surgery* 1984; 95: 14–21
- Fuster D, Torregrosa JV: Pre-operative Imaging in Secondary Hyperparathyroidism. *European Nephrology*, 2009; 3(1): 27–30
- Kwon JH, Kim EK, Lee HS et al: Neck ultrasonography as preoperative localization of primary hyperparathyroidism with an additional role of detecting thyroid malignancy. *Eur J Radiol*, 2012; 23
- Nasiri S, Sorush A, Hashemi A et al: Comparison Of Sestamibi Scintigraphy And Ultrasonography In Preoperative Localization Of Primary Hyperparathyroidism. *The Internet Journal of Surgery*, 2008; 16(1). DOI: 10.5580/1299
- Torregrosa JV, Félez I, Fuster D: Usefulness of imaging techniques in secondary hyperparathyroidism. *Nefrologia*, 2010; 30(2): 158–67
- Ali L, Loutfi I, Biswas G et al: Improved delineation of parathyroid lesions in patients with chronic renal failure using magnified pinhole imaging. *J Nucl Med Technol*, 2011; 39(1): 35–39
- Vaz A, Griffiths M: Parathyroid imaging and localization using SPECT/CT: initial results. *J Nucl Med Technol*, 2011; 39(3): 195–200

22. Oksüz MO, Dittmann H, Wicke C et al: Accuracy of parathyroid imaging: a comparison of planar scintigraphy, SPECT, SPECT-CT, and C-11 methionine PET for the detection of parathyroid adenomas and glandular hyperplasia. *Diagn Interv Radiol*, 2011; 17(4): 297-307
23. Kim YI, Jung YH, Hwang KT et al: Efficacy of (99m)Tc-sestamibi SPECT/CT for minimally invasive parathyroidectomy: comparative study with (99m)Tc-sestamibi scintigraphy, SPECT, US and CT. *Ann Nucl Med*, 2012; 9
24. Lavelly WC, Goetze S, Friedman KP et al: Comparison of SPECT/CT, SPECT, and planar imaging with single- and dual-phase (99m) Tc-sestamibi parathyroid scintigraphy. *J Nucl Med*, 2007; 48(7): 1084-89
25. Takami H, Ikeda Y, Kan S et al: New operative strategies in primary hyperparathyroidism. *Asian J Surg*, 2002; 25(2): 184-87
26. Wimmer G, Profanter C, Kovacs P et al: CT-MIBI-SPECT image fusion predicts multiglandular disease in hyperparathyroidism. *Langenbecks Arch Surg*, 2010; 395: 73-80
27. Takeyama H, Shioya H, Mori Y et al: Usefulness of radio-guided surgery using technetium-99m methoxyisobutylisonitrile for primary and secondary hyperparathyroidism. *World J Surg*, 2004; 28(6): 576-82
28. Takeyama H, Shioya H, Ogi S et al: Intraoperative 99mTc-MIBI-guided detection of ectopic glands in secondary hyperparathyroidism. *Int Surg*, 2009; 94(2): 154-63