

Biomolecular changes and cortical neurodegenerative lesions in *Trichinella spiralis* infected BALB/c mice: a preliminary study elucidating a potential relationship between systemic helminthic infections and idiopathic Parkinson's

M. HASBY SAAD^{1*}, O. SAFWAT², D. EL-GUINDY³, R. RAAFAT², D. ELGENDY¹, E. HASBY³

¹M.D. Medical Parasitology, Tanta University, Faculty of Medicine, *E-mail: m.hasby@yahoo.com; ²M.D. Biochemistry, Tanta University, Faculty of Medicine; ³M.D. Pathology, Tanta University, Faculty of Medicine

Article info

Received December 21, 2017
 Accepted September 28, 2018

Summary

Idiopathic Parkinson's (IP) is a neurodegenerative disease that is suspected to be due to exposure to infections during early life. Toxoplasmosis has been the only suspected parasitic infection in IP (Celik et al., 2010). Recently, some non-central nervous system bacterial and viral infections have been incriminated in IP (Çamcı & Oğuz, 2016). So in the current study, we tried to explore if the systemic inflammatory reactions triggered by some helminths like *Trichinella spiralis* can induce Parkinsonian lesions in the brain, especially that the cerebral complications have been reported in 10-20% of *Trichinella spiralis* infected patients. An experimental study was designed to assess the neurodegenerative and biomolecular changes that may occur in *Trichinella spiralis* infected BALB/C mice in comparison to rotenone induced PD model and apparently healthy ones. The motor affection was significantly lesser in the *Trichinella* infected mice than the Parkinson's model, but when the catalepsy score was calculated (through the grid and bar tests) it was found to be significantly higher in the infected mice than in the healthy ones. A significant increase in the blood advanced oxidative protein products (AOPP), IFN- γ , TGF- β , and brain DNA fragmentation was also detected in the *Trichinella spiralis* infected mice. After histopathological examination, a significant increase in the cortical apoptotic neurons and Lewy's body were observed in the *Trichinella* infected and the rotenone induced Parkinson's model sections. A significant decrease in the immunohistochemical expression of the tyrosine hydroxylase expression in the brain sections and the ELISA measured dopamine level in the brain homogenate was also reported in the infected mice group. This study findings may collectively suggest that the systemic inflammatory reactions and the oxidative stresses associated with some systemic helminthic infections like trichinellosis are possible to precipitate neurodegenerative lesions and biomolecular changes in the brain, and manifest with IPD later in life.

Keywords: *Trichinella spiralis*, Idiopathic Parkinson's, Lewy's bodies, Tyrosine hydroxylase, DNA fragmentation, proinflammatory cytokines IFN- γ & TGF- β

Introduction

The brain is considered the most defended organ in the human body. However, this doesn't prevent the continuous trials of some parasites to invade it or to initiate a status of cerebro-vascular and meningeal irritation (Filiano et al., 2015). *Trichinella spiralis* (*T. spiralis*) is a nematodal helminth that can cause systemic inflamma-

tory manifestations all over the body before habituating their final destination in the striated muscles. Infection with *T. spiralis* basically starts with ingestion of the encysted larvae in the infected undercooked pork meat. Afterward, the larvae mature into adult worm in the small intestine, and then fertilization takes place while the worms are stitched to the intestinal mucosa (Dupouy-Camet, 2000). Such location allows the newborn larvae to be spelled out

* – corresponding author

directly into the circulation to initiate the migratory phase. The larval migratory phase is considered the most dangerous phase of infection. During such phase there is a generalized intense immune inflammatory reaction due to the high antigenicity of larvae (Pozio, 2007). Cardiac and cerebral affections are of the most dangerous complications in this phase (Hall *et al.*, 2012). Within three to four weeks, most of the larvae in the circulation finally habituate the moderately active striated muscles all over the body where the chronic phase of infection will start (Gottstein *et al.*, 2005).

Parkinson's disease (PD) is considered the second most frequent neurodegenerative cerebral disease all over the world (Tabrez *et al.*, 2012). It gradually occurs after the death of the dopaminergic neurons, especially those located in the substantia nigra (Braak *et al.*, 2007). Manifestations of PD are mainly motoric e.g. akinesia, muscular rigidity, resting tremors, motion slowness and walking difficulties. Psychological problems, autonomic dysfunction, and dementia may also occur but to a less extent (Branchi *et al.*, 2008; Jilling, 2009). A considerable number of PD patients fall under the category of idiopathic Parkinson's (IP) in which there is no clear reason for the death of the dopaminergic neurons (Barbe *et al.*, 2017). There is growing evidence that exposure to high levels of injurious agents like the proinflammatory cytokines and oxidative stress product from the circulation may end with dopaminergic neurons apoptosis (Kang *et al.*, 2012). Hence, early exposure to systemic pathogens and injurious environmental agents like insecticides has been incriminated in precipitating IP (Liu *et al.*, 2003).

The dopaminergic neurons death results in a marked decrease in the brain dopamine level, which is one of the major catecholamine neurotransmitters. Moreover, any dysfunction in the tyrosine hydroxylase (TH) enzyme, which is responsible for the first step of dopamine synthesis, also results in a decrease in the brain dopamine level and the development of IP. Hence, TH expression and dopamine level in the brain are considered the most important diagnostic markers for PD (Daubner *et al.*, 2011).

Unexplained mitochondrial dysfunction and active oxidative stress reactions products are frequently recorded before the death of dopaminergic neurons in IPD (Perfeito *et al.*, 2013; Medeiros *et al.*, 2016). Moreover, advanced oxidation protein products (AOPPs) are considered of the novel oxidative stress inflammatory biomarkers that enjoy high stability in the circulation after release. They are easily detected in the circulation. Hence, and can be good indicator for the incidence of oxidative stress reactions (Gonzalez *et al.*, 2015; Qian *et al.*, 2015).

Since *T. spiralis* triggers an aggressive inflammatory reaction with the release of a massive amount of pro-inflammatory cytokines and oxidative stress products, and has been also reported as a cerebro-vascular disease in 10 – 20 % of patients; we tried to explore if *T. spiralis* infection can precipitate Parkinsonian like lesions in the brain. For this purpose, an experimental study was designed using BALB/c mice to explore if any motor dysfunction and/or brain biomolecular and histopathological changes may occur after the migratory phase of trichinellosis.

The rotenone induced Parkinson's disease model was chosen as a reference for the motor dysfunction and the brain changes in BALB/c mice. Rotenone is a highly lipophilic insecticide that is famous for its high accessibility through the blood brain barrier, and its accumulation in the brain mitochondria create a marked oxidative stress condition (Sherer *et al.*, 2003; Tansey *et al.*, 2010; Pringsheim *et al.*, 2014).

Material and Methods

Animals and Grouping

Thirty laboratory bred BALB/C male mice (about 8 weeks old and 25 ± 5 grams) were brought from the University Laboratory Animal House. The mice were housed in polypropylene cages with wire-mesh floors (ten per cage). Temperature was maintained at 25°C, with a standard 12-hour light/dark cycle. The animals were allowed to access food and water ad libitum, and the cages were cleaned daily.

After one week of acclimatization; the mice were randomly and equally divided into three groups. Ten mice were left to represent the apparently healthy control group I. Another ten mice received the rotenone drug regimen to induce the Parkinson's disease model (group II). The remaining ten mice were prepared to receive a moderate dose of the infective *T. spiralis* larvae to induce a *T. spiralis* infection model (group III).

Induction of Parkinson's disease

Rotenone was purchased from Sigma (St. Louis, MO-USA), and suspended in 0.5 % carboxy methyl cellulose sodium salt. Each mouse in this group received 30 mg/kg/day by oral gavage for 28 days (Inden *et al.*, 2009). The development of PD was confirmed by observing the development tremors, bradykinesia and rigidity in mice.

Induction of *T. spiralis* Infection

T. spiralis larvae were recovered from the muscles of the previously *T. spiralis* infected BALB/c mice that were bred in Tanta Medical Parasitology Department *T. spiralis* Life Cycle Maintenance Unit. The used strain had been previously genotyped and proved to be "*T. spiralis*" species by the European Union Reference Laboratory for Parasites in August 2015. The muscles of the euthanized infected mice were enzymatically digested and suspended in a measured inoculum of phosphate buffer solution (PBS) (Gamble, 1996). Each mouse in the infection group was left starving one night prior to the infection day, and then received on the next morning 0.25 ml of PBS loaded with 200 living muscle larvae by gastric gavage (Wang *et al.*, 2011). After four weeks the experiment was terminated to combine between the presence of adult worms remnants in the intestine, and the larvae whether the migrating newborn ones in the circulation or the incompletely encapsulated nse in muscles to measure the changes after exposure to the maximal circulatory inflammatory products (Bruschi & Murell, 2002).

Behavioural Tests (Grid and bar tests)

By the end of the experiment, behavioural tests were done for each mouse in the three groups. Each test was repeated three times to record the average score. Afterward the animals were prepared for samples collection and scarification. Bar test was done where the mouse was placed with both fore paws on a bar 9 cm above and parallel from the base, then the time needed for removal of the paw was recorded. Grid test was done by hanging the mouse by its paws on a vertical grid 25.5 cm wide and 44 cm high with a pace of 1 cm between each wire, and then the time needed by the mouse to move its paws or any sort of first movement was recorded. Catalepsy score was calculated according to the time scale as follows: score 0: 0-10 sec, 0.5: 11 – 30 sec, 1: 31 – 60 sec, 1.5: 61 – 90 sec, 2: 91 – 120 sec, 3: 121 – 150 sec, 3.5: 151 – 180 sec, 4: 181 – 210 sec, 4.5: 211 – 240 sec, and 5: >240 sec. Each test was measured for 4 min and each animal underwent three consecutive trials with 5 – 10 min interval between the tests. Catalepsy score of the test (mobility time in seconds) was done by calculating the sum of the score of the ten animals for one trial in each group, then calculating the mean for the 3 trials (Alam & Schmidt, 2004; Ghosh *et al.*, 2011; Makhija & Jagtap, 2014).

Samples collection

Plasma

After the induction of general anaesthesia by halothane, the ventral chest area was cleaned with 70 % ethanol. Afterward, blood was slowly aspirated by intracardiac puncture (Parasuraman *et al.*, 2010) and sample was collected in sodium citrate treated tubes to be centrifuged at 2,000 x g. The resultant supernatant was equally divided and transferred into three clean eppendorf tubes to be stored at -20°C till use.

Brain extraction

While still under anaesthesia, each mouse was euthanized by cervical dislocation. First, the head was sprayed with 70 % ethanol, and then decapitation was done at the base of the brain stem. The head was held at the base of the skull, and then a cut was done between the two olfactory bulbs by placing one blade of a small pair of scissors into each eye cavity and cutting coronally. Another two lateral cuts were done at the base of the skull, followed by a longitudinal one along the sagittal suture. The brain was exposed by peeling back the skull with a pair of curved forceps, and then the brain was freed by using a small spatula. The brain was immediately placed in cold PBS to be rinsed and then transferred in 10 cm plastic Petri dish containing PBS. Each brain was positioned on its ventral surface and divided longitudinally into two halves (Walker & Kempermann, 2014). One half was wrapped in foil paper to be preserved under -20°C till homogenization, and the other half was preserved in 10 % formaldehyde for histopathological examination.

Biochemical study

Detection of advanced oxidation protein products (AOPPs) in plasma

AOPPs levels were determined spectrophotometrically according to Witko-Sarsat *et al.* (1996) by semi-automated method on micro-plate reader (Model MR 5000; Dynatech, France). A volume of 200 µl of plasma diluted 1:5 in 50 mM Phosphate buffer saline PBS, pH: 7.4 was placed in test wells, followed by the addition of 10 µL of 1.16 M potassium iodide (KI) to each well, and then 20 µl of absolute acetic acid 2 min later. In standard wells, 10 µl of 1.16 M KI were added to 200 µl of chloramine-T solution 0 – 100 µmol/liter (Sigma, St, Louis, MO) followed by 20 µl of acetic acid. The absorbance of the reaction mixture was immediately read at 340 nm against a blank containing 200 µl of PBS, 20 µl of acetic acid and 10 µl of KI.

IFN-γ and TGF-β detection in plasma

IFN-γ was detected by Mouse IFN Gamma PicoKine™ ELISA kits purchased from Boster biological technology, California, USA, Catalog Number: EK0375. TGF-β was detected by Mouse TGF-beta1 Platinum ELISA kits purchased from e-bioscience, Vienna, Austria, Catalog Number: BMS608/4. Procedures were done according to the manufacturer's protocol for each kit.

Detection of DNA fragmentation in brain samples

DNA fragmentation was measured by the diphenylamine (DPA) method described by Zhu *et al.* (1998). Briefly, 20 mg of brain tissue was cut and lysed in 250 µl of the lysis buffer Tris/HCl 5 mM pH 8.0, Triton X-100 0.5 % and EDTA 20 mM with vigorous stirring, and then the mixture was incubated for 10 min at 4°C. After centrifugation at 10,000 x g for 20 min at 4°C fragmented the intact chromatin pellet (by centrifugation at 10,000xg for 20 min at 4°C) was transferred into a new clean tube. The pellet was dissolved in 500 µl TEX buffer, treated with 500 µl 10 % trichloroacetic acid (TCA), then centrifuged at 5000 x g for 10 min at 4°C. The supernatant was discarded and the precipitated DNA pellet was re-suspended in 250 µl of 5 % trichloroacetic acid and boiled for 15 min. Twenty µl of 6M perchloric acid was added to both the lysate supernatant and the treated pellet sample, in addition to 500 µl of a freshly prepared diphenylamine reagent 1.5g diphenylamine, 1.5 ml concentrated sulfuric acid and 19 µl acetaldehyde dissolved in 100 ml glacial acetic acid). The reaction mixture was incubated for 18 h at 37°C. Absorbance was measured by a semi-automated-spectrophotometer (Robonik-Prietest-Touch, India) at 600 nm, against freshly prepared diphenylamine reagent as a blank. The percentage of fragmented DNA was calculated as follows:

$$\text{Fragmented DNA} = \frac{\text{Amount of fragmented DNA in supernatant} \times 100}{\text{Amount of fragmented DNA in supernatant} + \text{amount of DNA in pellet}}$$

Table 1. Catalepsy score of Grid & Bar tests in the study groups.

	Grid test						
	Mean	SD	Kruskal-Wallis Test		Dunn's Multiple Comparisons Test		
			f	P-value	G: I & II	G: I & III	G: II & III
G-I (N=10)	6.27	0.96					
G-II (N=10)	41.55	3.44	17.818	0.0001	<0.001	>0.05	>0.05
G-III (N=10)	25.49	2.24					

	Bar test						
	Mean	SD	Kruskal-Wallis Test		Dunn's Multiple Comparisons Test		
			f	P-value	G: I & II	G: I & III	G: II & III
G-I (N=10)	7.06	1.18					
G-II (N=10)	37.9	3.07	17.818	0.0001	<0.001	>0.05	>0.05
G-III (N=10)	22.99	1.6					

N= number, G-I: healthy control, G-II= Rotenone induced Parkinson's model, G-III= *T. spiralis* infected group

Dopamine level in brain by ELISA

The Dopamine Research ELISA kit (Rocky Mountains Diagnostics, Inc., Colorado Springs, CO) was used to detect the dopamine level in the brain homogenate according to the manufacturer protocol. Each sample was divided and processed in duplicates (Ustione & Piston, 2012). The dopamine concentration range in the standard curve was 36 – 3600 pg.

Histopathological study

Histopathological staining by H&E and evaluation by image J-analyzer

Formalin fixed brain samples were processed, and embedded in paraffin blocks. Tissue sections of 4 µm thick were prepared for the hematoxylin and eosin (H&E) and the immunohistochemical staining. First, the sections were blindly examined by two pathologists to observe any neuronal loss, apoptotic neurons, cytoplasmic vacuolation, and detect Lewy's body formation in the infected and healthy sections and compare them to the typically detected changes in the brain sections retrieved from the rotenone induced Parkinson's model (Westin *et al.*, 2010). Apoptotic neurons were counted on images from 10 random fields per slide using image-J software (Java image processing program inspired by National institute of health NIH, USA) (Schneider *et al.*, 2012).

Immunohistochemical staining for Tyrosine Hydroxylase

The previously prepared brain sections were deparaffinised in xylene, rehydrated in descending concentrations of alcohol then washed in PBS phosphate buffer saline. After antigen retrieval by boiling in 10 mmol/L citrate buffer pH 6.0) for 10 minutes in a microwave, slides were immersed in 3 % hydrogen peroxide in order to block endogenous peroxidase. Background staining was blocked by placing slides in Ultra V Block Labvision, TA-015-UB, USA) for 5 minutes. Afterward, the slides were incubated with anti-tyrosine hydroxylase rabbit monoclonal antibody (Abcam, ab75875, EP1533Y, UK) in 1/200 dilution for 10 minutes at room temperature. Ultravision detection kits (TA-015-HD) were used,

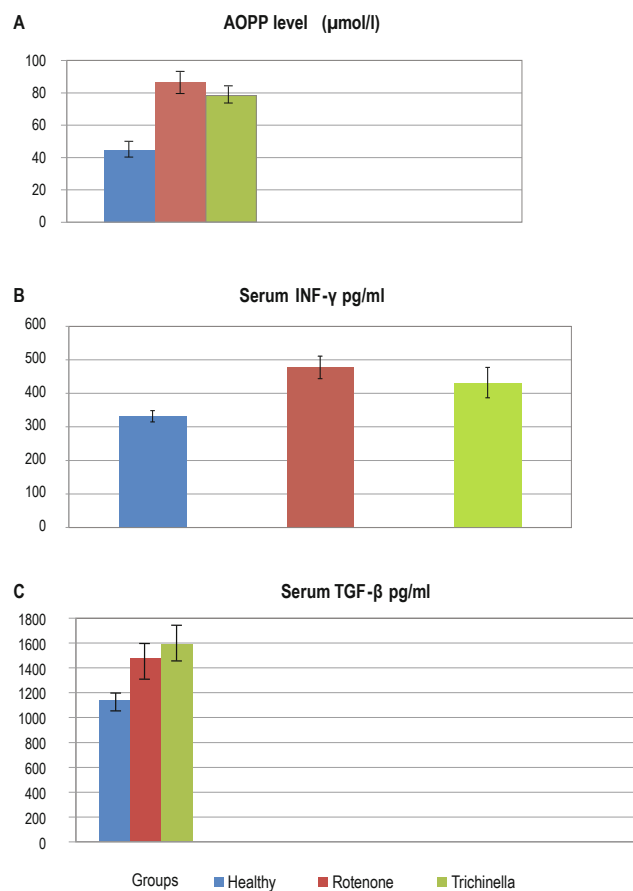


Fig. 1. A figure collects the bar charts that illustrate the statistical analysis for the AOPP (part A), IFN-γ (part B) and TGF-β (part C) levels in the different study groups. **A** – AOPP mean±SD reached 78.300±7.7331 µmol/L in the *Trichinella* infected group, 44.529±6.867 µmol/L in the healthy control group and, 86.543±9.416 µmol/L in the Parkinson's model. **B** – IFN-γ mean ±SD reached 477.69±33.73 pg/ml in the *Trichinella* infected group, 331.73±16.87 pg/ml in the healthy control group and, 432.30±45.43 pg/ml in the Parkinson's model. **C** – TGF-β mean±SD reached 1589.6±115.7 pg/ml in the *Trichinella* infected group, 1143.5±50.9 pg/ml in the healthy control group and, 1480.0±100.5 pg/ml in the Parkinson's model.

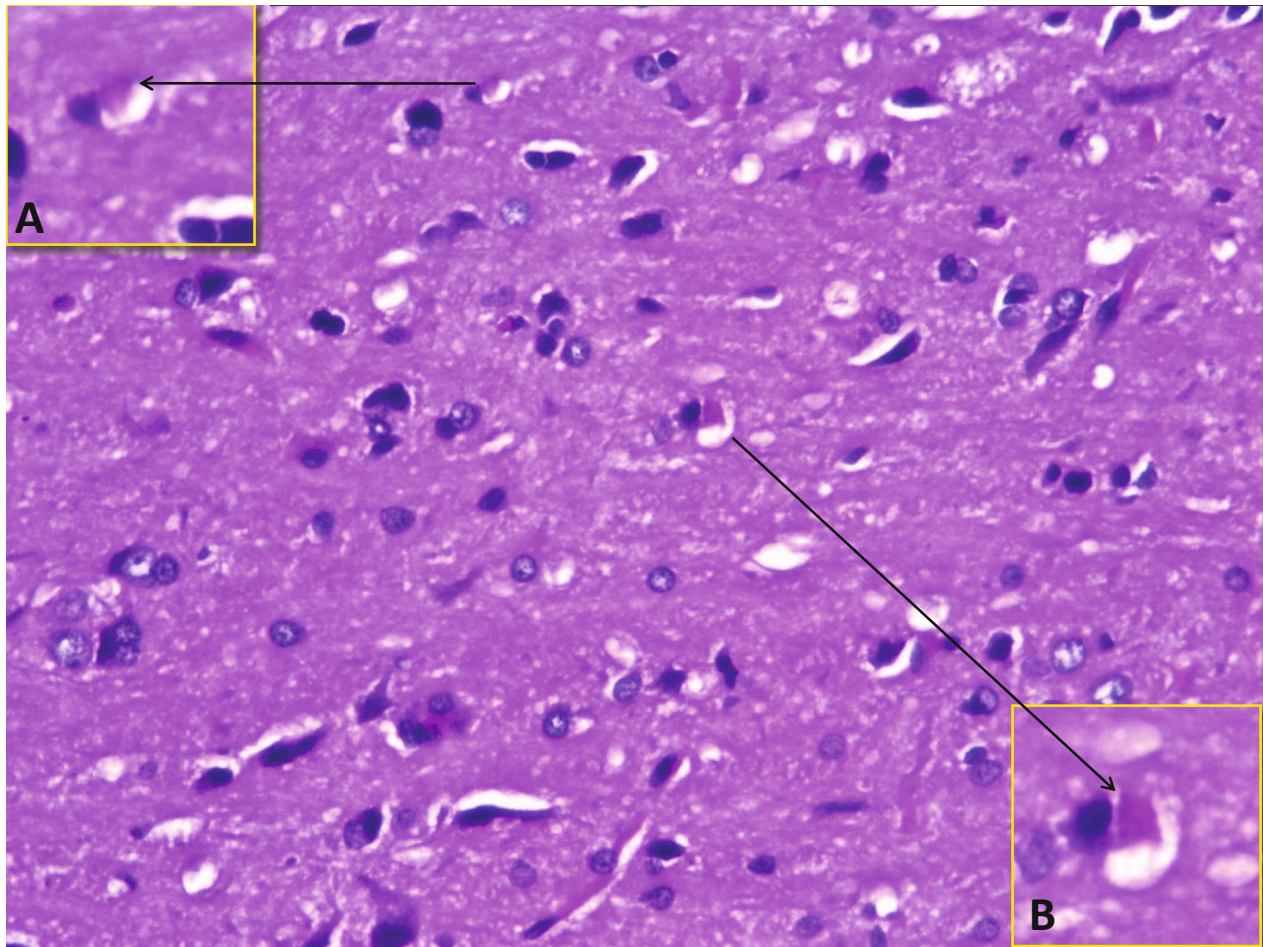


Fig. 2. H&E stained brain section (x400) from the rotenone induced Parkinson's model (group II) demonstrates the shape of Lewy's bodies that were used as a reference during examination of the other groups sections. By higher magnification (x1000 in A & B) Lewy's bodies appear as homogeneous eosinophilic cores surrounded by pale eosinophilic halos.

after incubating slides with biotinylated goat anti-polyvalent and then streptavidin peroxidase for 10 minutes with each of them. The DAB (diaminobenzidine) tetrachloride was used as a chromogen and the slides were counter stained with Meyer's haematoxylin. Tyrosine hydroxylase immunoreactivity was determined as brownish staining on neurons and fibers. Image-J software was used to determine the number of TH immune reactive neurons and percentages of TH-stained tissue. For each slide, 10 random fields were captured then opened by image-J software. Mean area of all tissue included as well as TH-stained tissue were measured, and then the percentage of TH-stained tissue was calculated. The TH-stained neurons were counted as described by Fuduka *et al.* (1999).

Statistical analysis

Statistical analysis was performed using GraphPad prism 7. Data were expressed in terms of means±standard deviation) for continuous variables. Kruskal – Wallis test was performed to compare

between groups followed by Dunn's multiple comparisons post-test. P value less than 0.05 was considered statistically significant.

Ethical Approval and/or Informed Consent

All procedures were performed according to the standards guidelines for researches on experimental animals, and after taking permission from Tanta University Faculty of Medicine Ethical Committee for Researches (permission code 31273/12/16).

Results

Induction of Parkinson's disease in group II was confirmed by the motor changes and the behavioural tests scores, while infection of group II mice was confirmed by visualization of *Trichinella* larvae in diaphragms specimens pressed between two glass slides and checked under microscope.

Table 2. Brain DNA fragmentation and dopamine level.

	Percentage of DNA fragmentation						
	Mean	SD	ANOVA		Dunn's Multiple Comparisons Test		
			f	P-value	G: I & II	G: I & III	G: II & III
G-I (N=10)	5.96	1.117					
G-II (N=10)	21.634	6.088	13.900	0.001	<0.01	<0.05	>0.05
G-III (N=10)	17.633	5.001					

	Tissue dopamine level ng/l						
	Mean	SD	ANOVA		Dunn's Multiple Comparisons Test		
			f	P-value	G: I & II	G: I & III	G: II & III
G-I (N=10)	1.066	0.026					
G-II (N=10)	0.419	0.037	14.542	0.0007	<0.001	<0.05	>0.05
G-III (N=10)	0.463	0.050					

N= number, G-I: healthy control, G-II= Rotenone induced Parkinson's model, G-III= *T. spiralis* infected group

Behavioural Test

As demonstrated in Table1; the mean score of rotenone induced Parkinson's group was significantly higher than in healthy and *Trichinella* infected groups. Still, the latter group showed a higher mean score in both tests (25.49 and 22.99) when compared with control (healthy) mice.

Biochemical study

AOPPs in plasma

AOPPs level was significantly elevated in *Trichinella* infected group III (78.300±7.7331) than in healthy control group I (44.529±6.867). No significant variation in AOPPs was recorded between rotenone induced Parkinson's model samples and *Trichinella* infected model mice (P>0.05).

IFN-γ and TGF-β in blood

IFN-γ showed a significant variation among the three groups (p=0.0006), with the highest level detected in *Trichinella* infected group (477.69 ± 33.73), followed by IPD (432.30 ± 45.43). IFN-γ

was significantly higher in *Trichinella* infected group than healthy group (331.73 ± 16.87). Groups II and III also showed a significantly higher levels of TGF-β; 1480.0 ± 100.5, 1589.6 ± 115.7, respectively) than healthy control group (1143.5 ± 50.9), with no significant difference between them.

Figure 1 demonstrates bar charts for the statistical analysis of biochemical parameters measured in blood (AOPP, IFN-γ and TGF-β).

DNA fragmentation detection in brain tissue

There was a significant difference in brain DNA fragmentation among the study groups (p<0.001). It was significantly elevated in both the Parkinson's and *Trichinella* infected groups, with no significant difference between them.

Dopamine level in brain homogenate

A marked reduction of dopamine level was detected in the brain samples from both the *Trichinella* infected mice and Rotenone induced Parkinson's groups. Still, the latter group showed a sig-

Table 3. Number of apoptotic neurons and Tyrosine hydroxylase (TH) immunoreactive neurons.

	Apoptotic neurons						
	Mean	SD	Kruskal-Wallis Test		Dunn's Multiple Comparisons Test		
			f	P-value	G: I & II	G: I & III	G: II & III
G-I (N=10)	26.86	3.04					
G-II (N=10)	79.14	10.19	14.74	<0.0001	0.029	0.001	0.734
G-III (N=10)	89.29	11.44					

	TH-immunoreactive neurons						
	Mean	SD	Kruskal-Wallis Test		Dunn's Multiple Comparisons Test		
			f	P-value	G: I & II	G: I & III	G: II & III
G-I (N=10)	18.71	3.15					
G-II (N=10)	3.86	1.46	14.38	<0.0001	0.001	0.019	0.999
G-III (N=10)	2.71	1.03					

N= number, G-I: healthy control, G-II= Rotenone induced Parkinson's model, G-III= *T. spiralis* infected group

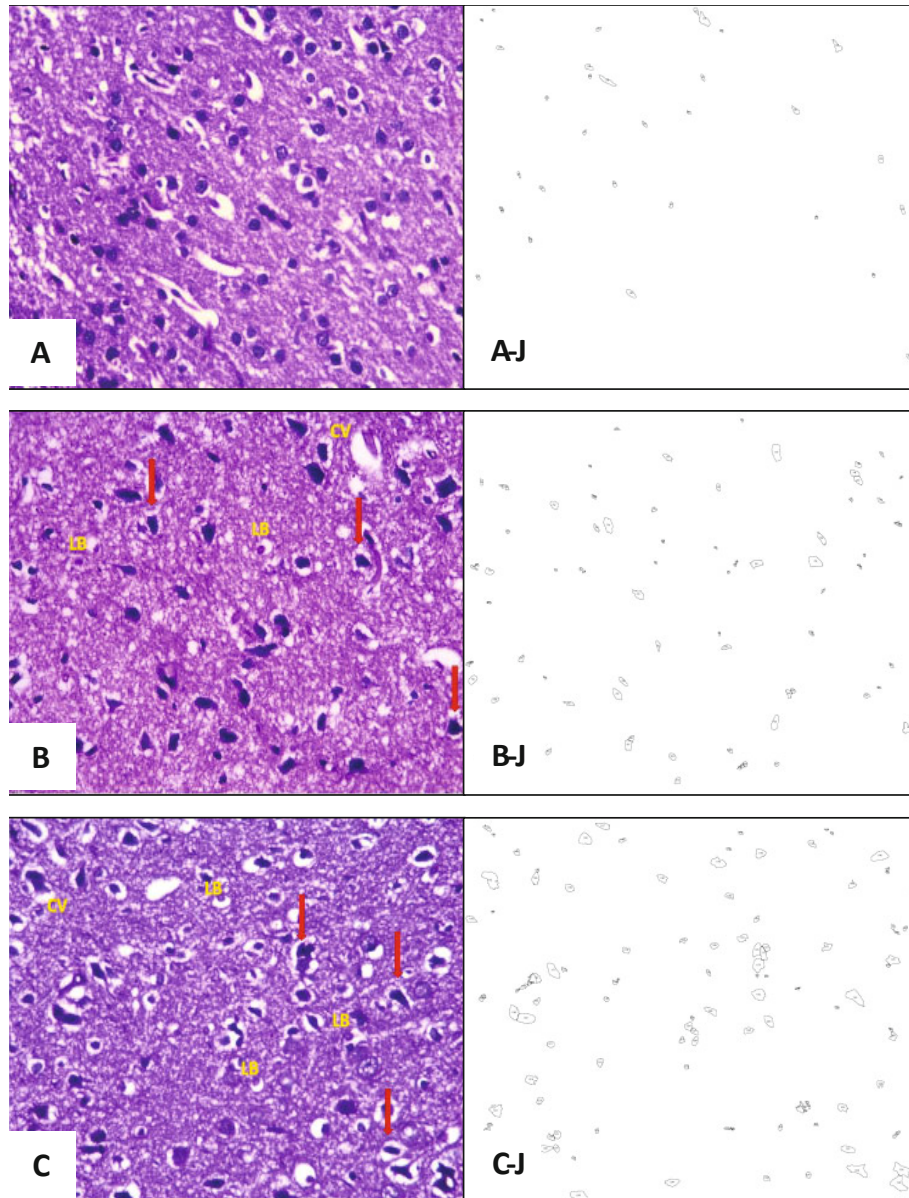


Fig. 3. A plate of H&E stained cortical sections (x400) from the different study groups (A, B & C) and the 8-bit images of the same sections (A-J, B-J & C-J) that show the outlined apoptotic neurons counted by image-J analyzer after normal neurons nuclei subtraction. **A** – section from cortical tissue of healthy control mouse (group I), showing normal neurons with round nuclei and prominent nucleoli. **B** – a section of cortical tissue from rotenone induced Parkinson's model mouse (group II), showing high density of the darkly stained pyknotic nuclei (arrow), cytoplasmic vacuolation, (CV), and Lewy's bodies (LB). **C** – a section from cortical tissue of *Trichinella spiralis* infected mouse (group III), showing higher number of the darkly stained pyknotic nuclei (arrow), cytoplasmic vacuolation, (CV), and Lewy's bodies (LB) in comparison to the section from the healthy group.

nificantly lower level. The results of brain DNA fragmentation and dopamine level are illustrated in Table 2.

Histopathological results

H&E

Sections from healthy control group showed apparently normal tissue that consists of large neurons with pale nuclei and prominent nucleoli. Sections from Rotenone group and *Trichinella* infected group revealed cortical atrophy with neuronal loss, increased ap-

optotic neurons and cytoplasmic vacuolation. Scattered Lewy's bodies, as exemplified in Figure 2, were detected in both groups. The number of apoptotic neurons in groups II and III (Mean+SD=79.14 ± 10.19, 89.29 ± 11.44, respectively) were significantly higher than in healthy mice (26.86 ± 3.04) as compared in Figure 3.

Tyrosine hydroxylase expression

Tyrosine hydroxylase (TH) immune reactivity was determined

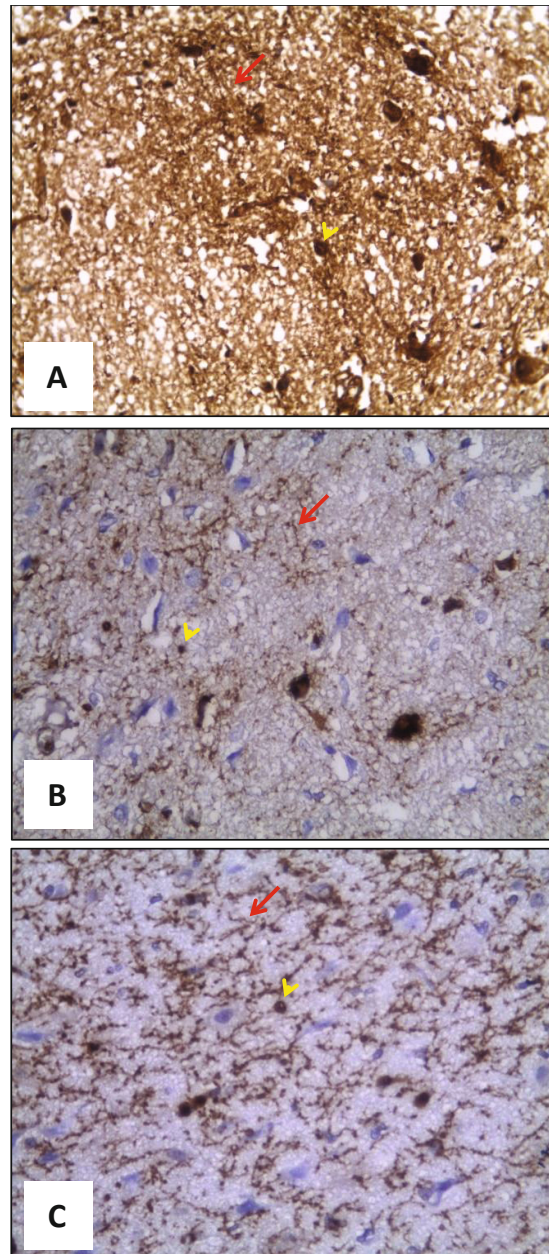


Fig. 4. Tyrosine hydroxylase immuno stained sections (x400) from cortical tissue of the different study groups. The yellow arrow heads are pointing at the neuron heads, while the red arrows at the fibers. **A** – a section from healthy control (group-I) with strong immune positivity of TH in both cortical neurons and fibers. **B** – a section from cortex of a Rotenone induced Parkinson's model mouse (group-II) with marked loss of TH immune stained neurons and fibers. **C** – a sections from cortex of a *T. spiralis* infected mouse (group-III) with marked loss of TH immune stained neurons and fibers in comparison to the healthy group.

as brownish staining in cortical neurons as well as in cortical fibers. A significant decrease in the percentage of TH reactive neurons was detected in the cortical areas of *Trichinella* infected group (mean % III= 24.29 ± 2.19), in comparison to healthy one (mean % I= 73.71 ± 6.45). No significant difference was observed between groups II and III in the percentage of reactive neurons (mean % II= 21.43 ± 2.13). Tyrosine hydroxylase expression in the different study groups is exemplified in comparative sections in

Figure 4. TH immunoreactivity was highly expressed in brain sections from the healthy group (Mean \pm SD= 18.71 ± 3.15). The least expression of TH reactive neurons was observed in *Trichinella* infected mice (2.71 ± 1.03). The mean expression in the Parkinson's model mice was 3.86 ± 1.46 , which is in between the expression in the control and the *T. spiralis* infected model. The numerical data of the histopathological study are demonstrated in Table 3.

Discussion

Idiopathic Parkinson's (IP) is a neurodegenerative disease that develops after an unexplained death of the dopaminergic neurons. Many researchers have linked between IP and exposure to infectious agents during early life. Interestingly, some of the incriminated organisms are not brain pathogens e.g. *Helicobacter pylori* (Çamcı & Oğuz, 2016), *H5N1 influenza virus* and *Hepatitis C virus* (Jang *et al.* 2009; Wu *et al.*, 2015). The mechanisms involved in the development of IP by these organisms vary between neurotoxins production (Schulz *et al.* 2006), microglial activation, phosphorylation of the presynaptic neuronal protein "α-Synuclein" (Senzolo *et al.*, 2011), and the release of a massive amount of proinflammatory cytokines and oxidative stress products (Arai *et al.*, 2004).

Regarding the relation between parasitic infections and IP; *Toxoplasma gondii* has been the only suspected parasite because of its ability to disrupt the dopaminergic neurotransmission, and the reported high anti-*Toxoplasma gondii* seropositivity in IP patients in previous studies (Celik *et al.*, 2010; Cook *et al.*, 2015; El Gendy *et al.*, 2017). The current study is considered the first to explore if the inflammatory reactions induced by a systemic helminth like "*Trichinella spiralis*" can trigger Parkinson's like lesions in the brain. Actually the brain can be affected by the parasites in two ways; first by the establishment of parasitic niches, cysts or granulomatous lesions within its tissue as occurs in neurocysticercosis, amoebic encephalitis and toxoplasmosis (Masocha & Kristensson, 2012), and second by the generalized inflammatory reactions that some parasitic infections can induce like malaria, schistosomiasis and visceral larva migrans (Pittella, 2013).

Regarding our study findings of the behavioural motor affection; the catalepsy score of the grid and bar tests was higher in the *Trichinella* infected mice than in the healthy group, but lesser than in the Parkinson's group. In fact, various neurological manifestations like behavioural disorders, tetraparesis and oculomotor paralysis have been previously reported in *T. spiralis* infected patients. However, these are considered uncommon manifestations in trichinellosis, and the mechanisms involved in pathogenesis are not clearly elucidated yet (Compton *et al.*, 1993; Neghina *et al.*, 2012).

A significant increase in the apoptotic dopaminergic neurons and a significant decrease in both the brain dopamine level and the tyrosine hydroxylase (TH) expression were observed in the brain samples from the *T. spiralis* infected group of mice. The detected lesions in the infected mice were mainly cortical. In fact, cortical dopaminergic neurons apoptosis has been previously reported in Parkinson's and dementia patients (Fukuda *et al.*, 1999; Marui *et al.*, 2003). According to Asmus *et al.* (2008) there is a subpopulation of cortical interneurons that can produce TH. A little is still known about these cortical cells despite of their potential relevance to the dopaminergic cortical circuit across the mammalian species (Benavides-Piccione & DeFelipe, 2007).

In 1999 Olson documented that in cerebral trichinellosis the le-

sions can be limited to neurons apoptosis, non purulent meningitis, and cellular infiltration. The tight junctions of the blood brain barrier (BBB) prevent the passage of larvae from the circulation (Ginhoux *et al.*, 2013). This may explain why no larvae or granuloma were detected in the brain sections retrieved from the infected group of the current study. According to Kristensson *et al.* (2015) only severe endothelia irritation, arachnoidal vasculitis and microglial activation can be seen in CNS trichinellosis. In the other hand, Lewy's bodies (LB) were significantly detected in the cortical areas of the infected mice. They are considered a major parkinsonian histopathological finding that was observed in the brain sections from the infected mice (Filiano *et al.*, 2015). The LB formation is caused by accumulation of insoluble fibrils of phosphorylated α-synuclein within the cytoplasm of the nerve cells (Prandovszky *et al.*, 2016). α-synuclein is an important protein for the maintenance of the synaptic vesicles supply in the presynaptic terminals and regulation of dopamine release (Burn *et al.*, 2004). Normally, a small fraction of α-synuclein (<4 %) becomes phosphorylated in healthy brains (Caggui *et al.*, 2016). In PD, neurons start to release small amounts of α-synuclein by exocytosis and the majority remains accumulated in the cytoplasm. Such abnormal accumulation of α-synuclein elicits a vigorous immune response (Lee *et al.*, 2014). Interestingly, cross-reactivity between human α-synuclein peptides and some infectious agents like HSV1 is now suspected after the detection of high amounts of antibodies against HSV1 homologous polypeptides in PD patients (Caggui *et al.*, 2016). Hence, the potentiality of the presence of a similar cross-reactivity between α-synuclein proteins and *T. spiralis* (or other parasitic) polypeptides (e.g. the somatic antigens and the secretory-excretory products of the adult worms and larvae) can't be excluded, especially after the detection of brain lesions in the *Trichinella* infected mice.

According to Allen Reish and Standiert (2015) both the innate and adaptive immunity are prominently activated in PD that even the interactions between them can modify the pathological process. In an experimental study on Parkinsonian monkeys; IFN-γ was documented as the most persistently high pro-inflammatory cytokine in the circulation (Mizuta *et al.*, 2001). Also in clinical studies on the sera of PD patients; high IFN-γ level was reported (Barcia *et al.*, 2011; Abdeldayem *et al.*, 2014). Such elevation was explained as the result of glial cells activation by some infectious agents and the subsequent trials of inflammatory cells to pass the blood brain barrier and attack them (Banks, 2005; Mount *et al.*, 2007). According to Perry (2004) IFN-γ is very injurious to the sensitively packed dopaminergic neurons. In the current study, IFN-γ blood level was significantly higher in the *T. spiralis* infected group in comparison to the healthy and the Parkinson's mice. In fact; IFN-γ is crucially related to the immune response against *Trichinella* larvae (Helmbly & Grecis, 2003). According to Dvorožňáková *et al.* (2011) the increase in the circulatory IFN-γ becomes prominent two weeks after *T. spiralis* infection, which coincides with giving birth to newborn larvae and the beginning of the migratory phase (Dvorožňáková

et al., 2005 and 2012). The increase in IFN- γ level during trichinellosis has been even proved to persist from day 10 to day 45 post-infection (i.e. during the phase of larval encapsulation in the muscles) even in the presence of a small number of larvae (Venturiello *et al.*, 1995; Dvorožňáková *et al.*, 2013). Moreover, Barbe *et al.* (2017) confirmed that the death of the encapsulated larvae can also enhance IFN- γ production.

TGF- β is another pro-inflammatory cytokine that strongly disturbs the function and decreases the number of the tyrosine hydroxylase (TH) immunoreactive neurons (Roussa *et al.*, 2004). In 1996 Vawter *et al.* documented a significant elevation of TGF- β in the cerebrospinal fluid of the IP patients, which was explained by the reported elevation of TGF- β in the circulation of the studied cohort. In the current study; the *Trichinella* infected mice showed the highest TGF- β blood level, and the least TH expression. During trichinellosis, high level of TGF- β was proved that it helps in the down-regulation of the post enteric inflammation, and facilitates tissue invasion by the circulating larvae. TGF- β -1 receptors were observed to become up regulated in some of the organs that are not commonly invaded by *T. spiralis* (Toms & Powrie, 2001). Bliss *et al.* (2003) also confirmed this observation when they recorded an increase in the larval capability to invade the liver in the presence of a high TGF- β level. However, despite the high TGF- β -1 level that was detected in the infected mice in the current study; no brain invasion by the *T. spiralis* larvae was recorded.

During the circulatory phase of *T. spiralis* infection; the Th1 immune response predominates and promotes the classical pathway of macrophage activation and nitric oxide (NO) production (Cunningham, 2013). The high IFN- γ production in trichinellosis is responsible for the activation of NOS-2 enzyme that transforms L-arginine into nitric oxide to destroy the circulating larvae (Fabre *et al.*, 2009). In the current study, the plasma advanced oxidation protein products (AOPPs) were significantly higher in the *Trichinella* infected mice. According to Capeillere-Blandin *et al.* (2004) on exposure of blood albumin to oxidative and carbonyl stresses products AOPPs become generated. AOPPs have a pro-inflammatory character, and act as inflammatory mediators that stimulate the recruitment of more neutrophils and monocytes and activate the T-lymphocytes oxidative ignition and dendritic cells (Cakir *et al.*, 2016).

With the continuous trials of the migrating nematodal larvae to leave the circulation, and pass to the surrounding tissues by crossing the blood tissue barriers a massive amount of INF- γ is released. Subsequently, a cyclic inflammatory process of oxidative tissue damage, excitotoxicity, mitochondrial dysfunction, and proteolysis starts. In such case; areas nearby the blood tissue barriers show the highest tissue damage (Bruschi & Chiumiento, 2011). This can be an explanation for the significant high number of apoptotic dopaminergic neurons that were detected in the cortex. They are considered the nearest dopaminergic neurons to the highly vascular arachnoid matter and choroid plexus (Venditti *et al.*, 2013). In addition, once the balance between the ROS produc-

tion and cellular antioxidant activity is disturbed; massive tissue damage occurs in the brain areas that exhibit the highest level of oxidized lipids, proteins and DNA like the cerebral cortex (Alam *et al.*, 1997; Badie *et al.*, 2000; Niedzielska *et al.*, 2016).

With the presence of a high and sustained IFN- γ production in the circulation the microglial cells and astrocytes become activated. The role of the astrocytes in the BBB is mainly to encounter the passage of larvae and blood-derived leukocytes into the brain (Glass *et al.*, 2010). In the presence of a neuroinflammatory condition as occurs in infections, the integrity and function of the BBB becomes modified to enable the passage of leukocyte to the CNS (Lee, & MacLean, 2015). Though this is important to help in elimination of the invading pathogens; it will trigger the release of two types of inflammatory molecules by the microglia; the anti- and the pro-inflammatory factors (Le *et al.*, 2016). The first is beneficial and occurs soon after the CNS insult, while the second (which persists) occurs later, and is very notorious as it inhibits the neuronal regeneration, and establishes a sustained status of CNS inflammation and glial scar formation. Since in trichinellosis there is a persistent elevation of blood IFN- γ along the different phases of infection (McGeer *et al.*, 2003), sustained activation of the microglia can be expected. The chronically activated microglia and astrocytes will release reactive oxygen intermediates, nitric oxide, inflammatory cytokines, and activate the Jak/STAT pathway with "Fas" death receptor and its ligand "FasL" up regulation (Badie *et al.*, 2000; Hayley *et al.*, 2004). These inflammatory products will be all toxic to the sensitively packed dopaminergic neurons. In addition, the dopaminergic neurons are very rich in ROS-generating enzymes like monoamine oxidase, which makes them more prone to damage and oxidative stress generation (Bruschi *et al.*, 2013; Hwang, 2013).

A significantly higher level of DNA fragmentation was detected in the *Trichinella* infected mice. With massive ROS production the sensors of irreversible DNA damage response and protein kinases become activated, and DNA fragmentation occurs (Chen *et al.*, 2012). Persistent DNA damage is considered one of the main pathogenic sign in the human neurodegenerative diseases since DNA integrity plays a cardinal role in the maintenance of the brain cells growth and regeneration (Andersen, 2004). According to Quián and Flood (2008) the accumulating brain insults due to the sustained microglial activation echoes with the slowly progressive destruction of the dopaminergic neurons that characterizes the development of idiopathic Parkinson's. Thus, there is a growing body of evidence that the presence of a pathogen in the circulation may initiate a status of microglial activation and neuroinflammation that will contribute IP development (Subramaniam & Federoff, 2017).

Conclusion

According to the previous findings; *Trichinella spiralis* infection was associated with significant brain DNA fragmentation, cortical neurodegenerative lesions in the form of Lewy's bodies, dopamin-

ergic neurons apoptosis and a significant decrease in TH activity and brain dopamine level. These findings are all documented as pathognomonic signs for the neurodegenerative diseases generally and Parkinson's disease specifically. The reported brain changes may be explained by the significant increase in AOPP, and the proinflammatory cytokines "IFN- γ and TGF- β ", which result from *Trichinella spiralis* infection. In the migratory phase of trichinellosis an intense immune stimulation is triggered by the presence of adult worms' traces in the intestine and the larvae (whether the free ones in the circulation or the incompletely encapsulated ones in the muscles). The localization of the brain lesions in the cortical areas of the dopaminergic circuit can be explained by being the closest to the meninges and the parasite induced inflammatory reactions in the circulation, and the richness of the cortical neurons with oxidized lipids, proteins and DNA. Generally, further studies are warranted to demonstrate the brain changes after different parasitic infections, infectious doses and longer duration; since Parkinson's disease is a long term disease with accumulative lesions and a progressive course. Moreover, cross-antigenicity between the different brain proteins and parasitic polypeptides must be investigated to discover any potentiality of cross-reactivity and autoimmune reaction, as was previously discovered with some viruses.

Acknowledgement

We confirm that this research was not funded by any organization, still as we are staff members in Tanta University faculty of medicine; our departments provide us with basic materials, laboratory animals and equipments. Special thanks for Dr. Rasha El-Esawy; M.D. pharmacology, for helping us in establishment of Rotenone induced Parkinson's model in BALB/c mice.

Conflict of Interest

The authors declare that there are no conflicts of interest.

References

- ABDELDAYEM, M., ANANI, M., HASSAN, H., TAHA, S. (2014): Association of Serum Interferon Gamma Level with Parkinson's disease in Egyptian patients. *Egypt. J. Med. Microbiol.*, 23(1): 1 – 5. DOI: 10.12816/0024255
- ALAM, M., SCHMIDT, W.J. (2004): L-DOPA reverses the hypokinetic behaviour and rigidity in rotenone treated rats. *Behav. Brain Res.*, 153(2): 439 – 446. DOI: 10.1016/j.bbr.2003.12.021
- ALLEN REISH, H.E., STANDAERT, D.G. (2015): Role of α -synuclein in inducing innate and adaptive immunity in Parkinson disease. *J. Parkinsons Dis.*, 5(1):1 – 19. DOI: 10.3233/JPD-140491
- ANDERSEN, J.K. (2004): Oxidative stress in neurodegeneration: cause or consequence? *Nat. Med.*, 2004: S18 – 25. DOI: 10.1038/nrn1434
- ASMUS, S.E., ANDERSON, E.K., BALL, M.W., BARNES, B.A., BOHNEN, A.M., BROWN, A.M., HARTLEY, L.J., LALLY, M.C., LUNDBLAD, T.M., MARTIN, J.B., MOSS, B.D., PHELPS, K.D., PHILLIPS, L.R., QUILLIGAN, C.G., STEED, R.B., TERRELL, S.L., WARNER, A.E. (2008): Neurochemical characterization of tyrosine hydroxylase-immunoreactive interneurons in the developing rat cerebral cortex. *Brain Res.*, 1222: 95 – 105. DOI: 10.1016/j.brainres.2008.05.053
- BADIE, B., SCHARTNER, J., VORPAH, J., PRESTON, K. (2000): Interferon-gamma induces apoptosis and augments the expression of Fas and Fas ligand by microglia in vitro. *Exp. Neurol.*, 162(2): 290 – 296. DOI: 10.1006/exnr.1999.7345
- BANKS, W.A. (2005): Blood-brain barrier transport of cytokines: a mechanism for neuropathology. *Curr. Pharm. Des.*, 11(8): 973 – 984
- BARBE, A.G., BOCK, N., DERMAN, S.H., FELSCH, M., TIMMERMANN, L., NOACK, M.J. (2017): Self-assessment of oral health, dental health care and oral health-related quality of life among Parkinson's disease patients. *Gerodontology*, 34(1): 135 – 143. DOI:10.1111/ger.12237
- BARCIA, C., ROS, C.M., ANNESE, V., GÓMEZ, A., ROS-BERNAL, F., AGUADO-YEAR, D., HERRERO, M.T. (2011): IFN- γ signaling, with the synergistic contribution of TNF- α , mediates cell specific microglial and astroglial activation in experimental models of Parkinson's disease. *Cell Death Dis.*, 2:e142. DOI: 10.1038/cddis.2011.17
- BENAVIDES-PICCIONE R., DEFELIPE J. (2007): Distribution of neurons expressing tyrosine hydroxylase in the human cerebral cortex. *J. Anat.*, 211: 212 – 222. DOI: 10.1111/j.1469-7580.2007.00760.x
- BLISS, S.K., ALCARAZ, A., APPLETON, J.A. (2003): IL-10 prevents liver necrosis during murine infection with *Trichinella spiralis*. *J. Immunol.*, 171(6): 3142 – 3147. DOI: 10.4049/jimmunol.171.6.3142
- BRAAK, H., BOHL, J.R., MULLER, C.M., RUB, U., DE VOS, R.A., DEL, T.K. STANLEY, F.L. (2006): The staging procedure for the inclusion body pathology associated with sporadic Parkinson's disease reconsidered. *Mov. Disord.*, 21(12): 2042 – 2051. DOI: 10.1002/mds.21065
- BRANCHI, I., D'ANDREA, I., ARMIDA, M., CASSANO, T., PEZZOLA, A., POTENZA, R.L., MORGESE, M.G., POPOLI, P., ALLEVA, E. (2008): Nonmotor symptoms in Parkinson's disease: Investigating early-phase onset of behavioral dysfunction in the 6-hydroxydopamine-lesioned rat model. *J. Neurosci. Res.*, 86(9): 2050 – 2061. DOI: 10.1002/jnr.21642
- BRUSCHI, F., CHIUMIENTO, L. (2011): *Trichinella* inflammatory myopathy: host or parasite strategy? *Parasit. Vectors*, 4: 42. DOI: 10.1186/1756-3305-4-42
- BRUSCHI, F., BRUNETT, E., POZIO, E. (2013): Neurotrichinellosis. In: STONE, T. E. (Ed) *Handbook of clinical Neurology*. New York: Elsevier Amsterdam, pp. 243 – 249
- BRUSCHI, F., MURRELL, K.D. (2002): New aspects of human trichinellosis: the impact of new *Trichinella* species. *Postgrad. Med. J.*, 78(915): 15 – 22
- BURN, D. J. (2004): Cortical Lewy body disease. *J. Neurol. Neurosurg. Psychiatry*, 75(2): 175 – 178

- CAGGIU, E., PAULUS, K., ARRU, G., PIREDDA, R., SECHI, G.P., SECHI, L.A. (2016): Humoral cross reactivity between α -synuclein and herpes simplex-1 epitope in Parkinson's disease, a triggering role in the disease? *J. Neuroimmunol.*, 291: 110 – 114. DOI: 10.1016/j.jneuroim.2016.01.007
- CAKIR, T., GOKTAS, B., MUTLU, M.F., MUTLU, I., BILGIHAN, A., ERDEM, M., ERDEM, A. (2016): Advanced oxidation protein products and malondialdehyde the new biological markers of oxidative stress are elevated in postmenopausal women. *Ginekol. Pol.*, 87(5): 321 – 325. DOI: 10.5603/GP.2016.0001
- ÇAMCI, G., OĞUZ, S. (2016): Association between Parkinson's disease and *Helicobacter pylori*. *J. Clin. Neurol.*, 12(2): 147 – 150. DOI: 10.3988/jcn.2016.12.2.147
- CAPEILLERE-BLANDIN, C., GAUSSON, V., DESCAMPS-LATSCHA, B., WITKO-SARSAT, V. (2004): Biochemical and spectrophotometric significance of advanced oxidized protein products. *Biochim. Biophys. Acta*, 1689(2): 91 – 102. DOI: 10.1016/j.bbadis.2004.02.008
- CELIK, T., KAMISLI, O., BABUR, C., CEVIK, M.O., OZTUNA, D., ALTINAYAR, S. (2010): Is there a relationship between *Toxoplasma gondii* infection and idiopathic Parkinson's disease? *Scand. J. Infect. Dis.*, 42(8): 604 – 608. DOI: 10.3109/00365541003716500
- CHEN, B.P., LI, M., ASAITHAMBY, A. (2012): New insights into the roles of ATM and DNA-PKcs in the cellular response to oxidative stress. *Cancer Lett.*, 327(1 – 2): 103 – 110. DOI: 10.1016/j.canlet.2011.12.004
- COMPTON, S.J., CELUM, C.L., LEE, C., THOMPSON, D., SUMI, S.M., FRITSCH, T.R., COOMBS, R.W. (1993): Trichinosis with ventilatory failure and persistent myocarditis. *Clin. Infect. Dis.*, 16(4): 500 – 504
- COOK, T.B., BRENNER, L.A., CLONINGER, C.R., LANGENBERG, P., IGBIDE, A., GIEGLING, I., HARTMANN, A.M., KONTE, B., FRIEDL, M., BRUNDIN, L., GROER, M.W., CAN, A., RUJESCU, D., POSTOLACHE, T.T. (2015): Latent[†] infection with *Toxoplasma gondii*: association with trait aggression and impulsivity in healthy adults. *J. Psychiatr. Res.*, 60: 87 – 94. DOI: 10.1016/j.jpsychires.2014.09.019
- CUNNINGHAM, C. (2013): Microglia and neurodegeneration: The role of systemic degeneration. *Glia*, 61(1): 1 – 90. DOI: 10.1002/glia.22350
- DAUBNER, S. C., LE, T., WANG, S. (2011): Tyrosine hydroxylase and regulation of dopamine synthesis. *Arch. Biochem. Biophys.*, 508(1): 1 – 12. DOI: 10.1016/j.abb.2010.12.017
- DUPOUY-CAMET, J. (2000): Trichinellosis: a worldwide zoonosis. *Vet. Parasitol.*, 93(3 – 4): 191 – 200. DOI: 10.1016/S0304-4017(00)00341-1
- DVOROŽŇÁKOVÁ, E., HURNÍKOVÁ, Z., KOŁODZIEJ-SOBOCIŃSKA, M. (2011): Development of cellular immune response of mice to infection with low doses of *Trichinella spiralis*, *Trichinella britovi* and *Trichinella pseudospiralis* larvae. *Parasitol. Res.*, 108(1): 169 – 176. DOI: 10.1007/s00436-010-2049-x
- DVOROŽŇÁKOVÁ, E., JALČOVÁ, M., HURNÍKOVÁ, Z. (2013): Differences in cellular immune responses of mice BALB/c to low and high infective doses of *Trichinella spiralis*. *Helminthologia*, 50(4): 244 – 253. DOI: 10.2478/s11687-013-0137-z
- DVOROŽŇÁKOVÁ, E., KOŁODZIEJ-SOBOCIŃSKA, M., HURNÍKOVÁ, Z. (2005): Development of T-cell immune response in experimental murine trichinellosis. *Helminthologia*, 42(4): 187 – 196
- DVOROŽŇÁKOVÁ, E., KOŁODZIEJ-SOBOCIŃSKA, M., HURNÍKOVÁ, Z. (2012): *Trichinella spiralis* reinfection: changes in cellular and humoral immune response in BALB/c mice. *Helminthologia*, 49(4): 201 – 210. DOI: 10.2478/s11687-012-0039-5
- EL GENDY W.M., YASSEN N.A.E.A., FAYED H.A.E.R., HASBY SAAD M.A., DAUD A.A. (2017): Is there a relationship between *Toxoplasma gondii* immunoglobulin G seropositivity and idiopathic Parkinson's disease and does it have a correlation with serum cortisol level? *Tanta Med. J.*, 45: 29 – 35. DOI: 10.4103/1110-1415.209096
- FABRE, V., BEITING, D.P., BLISS, S.K., GEBRESELASSIE, N.G., GAGLIARDO, L.F., LEE, N.A., LEE, J.J., APPLETON, J. (2009): Eosinophil deficiency compromises parasite survival in chronic nematode infection. *J. Immunol.*, 182(3): 1577 – 1583. DOI: 10.4049/jimmunol.182.3.1577
- FILIANO, A.J., GADANI, S.P., KIPNIS, J. (2015): Interactions of innate and adaptive immunity in brain development and function. *Brain Res.*, 1617: 18 – 27. DOI: 10.1016/j.brainres.2014.07.050
- FUKUDA, T., TAKAHASHI, J., TANAKA, J. (1999): Tyrosine hydroxylase-immunoreactive neurons are decreased in number in the cerebral cortex of Parkinson's disease. *Neuropathology* 19(1): 10 – 13. DOI: 10.1046/j.1440-1789.1999.00196.x
- GAMBLE, H.R. (1996): Detection of trichinellosis in pigs by artificial digestion and enzyme immunoassay. *J. Food Prot.*, 59(3): 295 – 298
- GHOSH, A., DHUMAL, V.R., TILAK, A.V., SINGH, A., PANDEY, M., BONDEKAR, A.A. (2011): Effect of chronic administration of low dose aspirin on haloperidol induced catalepsy in rats. *J. Pharmacol. Pharmacother.*, 23(3): 198 – 199. DOI: 10.4103/0976-500X.83292
- GLASS, C.K., SAJO, K., WINNER, B., MARCHETTO, M.C., GAGE, F.H. (2010): Mechanisms underlying inflammation in neurodegeneration. *Cell*, 140: 918 – 934. DOI: 10.1016/j.cell.2010.02.016
- GINHOUX, F., LIM, S., LOW, D., HUBER, T., HOFFEL, G. (2013): Origin and differentiation of microglia. *Front. Cell. Neurosci.*, 7(45): 6159 – 6169. DOI: 10.3389/fncel.2013.00045
- GONZALEZ, E., BAJO, M.A., CARRERO, J.J., LINDHOLM, B., GRANDE, C., SÁNCHEZ-VILLANUEVA, R., DEL PESO, G., DÍAZ-ALMIRÓN, M., IGLESIAS, P., DíEZ, J.J., SELGAS, R. (2015): An increase of plasma advanced oxidation protein products levels is associated with cardiovascular risk in incident peritoneal dialysis patients: a pilot study. *Oxid. Med. Cell. Longev.*, 2015(2015): 219569. DOI: 10.1155/2015/219569
- GOTTSTEIN, B., POZIO, E., NÖCKLER, K. (2009): Epidemiology, diagnosis, treatment, and control of trichinellosis. *Clin. Microbiol. Rev.*, 22(1): 127 – 145. DOI: 10.1128/CMR.00026-08
- HALL, R.L., LINDSAY, A., HAMMOND, C., MONTGOMERY, S.P., WILKINS, P.P., DA SILVA, A.J., MCAULIFFE, I., DE ALMEIDA, A.M., BISHOP, H., MATHISON, B., SUN, B., LARGUSA, R., JONES, J.L. (2012): Outbreak of human trichinellosis in Northern California caused by *Trichinella murrelli*. *Am. J. Trop. Med. Hyg.*, 87(2): 297 – 302. DOI: 10.4269/ajtmh.2012.12-0075

- HAYLEY, S., CROCKER, S.J., SMITH, P.D., SHREE, T., JACKSON-LEWIS, V., PRZEDBORSKI, S., MOUNT, M., SLACK, R., ANISMAN, H., PARK, D.S. (2004): Regulation of dopaminergic loss by Fas in a 1-methyl-4-phenyl-1,2,3,6-tetrahydropyridine model of Parkinson's disease. *J. Neurosci.*, 24(8): 2045 – 2053. DOI: 10.1523/JNEUROSCI.4564-03.2004
- HWANG, O. (2013): The role of oxidative stress in Parkinson's disease. *Exp. Neurobiol.*, 221(4): 11 – 17. DOI: 10.3233/JPD-130230
- JANG, H., BOLTZ, D., STURM-RAMIREZ, K., SHEPHERD, K.R., JIAO, Y., WEBSTER, R., SMEYNE, R.J. (2009): Highly pathogenic H5N1 influenza virus can enter the central nervous system and induce neuroinflammation and neurodegeneration. *Proc. Natl. Acad. Sci. U S A.*, 106(33): 14063 – 14068. DOI: 10.1073/pnas.0900096106
- JELLINGER, K.A. (2009): Significance of brain lesions in Parkinson disease dementia and Lewy body dementia. *Front. Neurol. Neurosci.*, 24: 114 – 125. DOI: 10.1159/000197890
- KANG, S.A., CHO, M.K., PARK, M.K., KIM, D.H., HONG, Y.C., LEE, Y.S., CHA, H.J., OCK, M.S., YU, H.S. (2012): Alteration of helper T-cell related cytokine production in splenocytes during *Trichinella spiralis* infection. *Vet. Parasitol.*, 186(3 – 4): 319 – 327. DOI: 10.1016/j.vetpar.2011.12.002
- KRISTENSSON, K., MASOCHA, W., BENTIVOGLIO, M. (2013): Mechanisms of CNS invasion and damage by parasites. *Handb. Clin. Neurol.*, 114: 11 – 22. DOI: 10.1016/B978-0-444-53490-3.00002-9
- LE, W., WU, J., TANG, Y. (2016): Protective Microglia and Their Regulation in Parkinson's Disease. *Front. Mol. Neurosci.*, 9: 89
- LEE, H.-J., EUN-JIN, B., SEUNG-J, L. (2014): Extracellular α -Synuclein: a Novel and Crucial Factor in Lewy Body Diseases. *Nature Reviews Neurology*, 10(2): 92 – 98. DOI: 10.1038/nrneurol.2013.275
- LEE, K. M., MACLEAN, A. G. (2015): New advances on glial activation in health and disease. *World J. Virol.*, 4(2): 42 – 55. DOI: 10.5501/wjv.v4.i2.42
- LIU, B., GAO, H.M., HONG, J.S. (2003): Parkinson's disease and exposure to infectious agents and pesticides and the occurrence of brain injuries: role of neuroinflammation. *Environ. Health Perspect.*, 111(8): 1065 – 1073
- MAKHUJA, D.T., JAGTAP, A.G. (2014): Studies on sensitivity of zebrafish as a model organism for Parkinson's disease: Comparison with rat model. *J. Pharmacol. Pharmacother.*, 5(1): 39 – 46. DOI: 10.4103/0976-500X.124422
- MARUI W, ISEKI E, KATO M, KOSAKA K. (2003): Degeneration of tyrosine hydroxylase-immunoreactive neurons in the cerebral cortex and hippocampus of patients with dementia with Lewy bodies. *Neurosci. Lett.*, 340:185 – 188
- MCGEER, P.L., SCHWAB, C., PARENT, A., DOUDET, D. (2003): Presence of reactive microglia in monkey substantia nigra years after 1-methyl-4-phenyl-1,2,3,6-tetrahydropyridine administration. *Ann. Neurol.*, 54(5): 599 – 604. DOI: 10.1002/ana.10728
- MASOCHA, W., KRISTENSSON, K. (2012): Passage of parasites across the blood-brain barrier. *Virulence*, 3(2): 202 – 212. DOI: 10.4161/viru.19178
- MEDEIROS, M.S., SCHUMACHER-SCHUH, A., CARDOSO, A.M., BOCHI, G.V., BALDISSARELLI, J., KEGLER, A., SANTANA, D., CHAVES, C.M., SCHETINGER, M.R., MORESCO, R.N., RIEDER, C.R., FIGHERA, M.R. (2016): Iron and oxidative stress in Parkinson's disease: an observational study of injury biomarkers. *PLoS ONE*, 11(1): 11. DOI: 10.1371/journal.pone.0146129
- MIZUTA, I., NISHIMURA, M., MIZUTA, E., YAMASAKI, S., OHTA, M., KUNO, S., NISHIMURA, M., OTA, M. (2001): Relation between the high production related allele of the interferon-gamma (IFN-gamma) gene and age at onset of idiopathic Parkinson's disease in Japan. *J. Neurol. Neurosurg. Psychiatry*, 71(6): 818 – 819. DOI: 10.1136/jnnp.71.6.818a
- MOUNT, M.P., LIRA, A., GRIMES, D., SMITH, P.D., FAUCHER, S., SLACK, R., ANISMAN, H., HAYLEY, S., PARK, D.S. (2007): Involvement of interferon- γ in microglial-mediated loss of dopaminergic neurons. *J. Neurosci.*, 271(12): 3328 – 3337. DOI: 10.1523/JNEUROSCI.5321-06.2007
- NEGHINA, R., MOLDOVAN, R., MARINCU, I., CALMA, C.L., NEGHINA, A.M. (2012): The roots of evil: the amazing history of trichinellosis and *Trichinella* parasites. *Parasitol. Res.*, 110(2): 503 – 508. DOI: 10.1007/s00436-011-2672-1
- NIEDZIŁSKA, E., SMAGA, I., GAWLIK, M., MONICZEWSKI, A., STANKOWICZ, P., PERA, J., FILIP, M. (2016): Oxidative stress in neurodegenerative diseases. *Mol. Neurobiol.*, 7(5): 4094 – 4125. DOI: 10.3969/j.issn.1673-5374.2012.05.009
- OLSON, J. (1999): Walsh and Hoyt's Clinical Neuro-Ophthalmology. Diseases caused by helminthic. *Br. J. Ophthalmol.*, 839: 2905
- PARASURAMAN, S., RAVEENDRAN, R., KESAVAN, R. (2010): Blood sample collection in small laboratory animals. *J. Pharmacol. Pharmacother.*, 1(2): 87 – 93. DOI: 10.4103/0976-500X.72350
- PERFEITO, R., CUNHA-OLIVEIRA, T., REGO, A.C. (2013): Revisiting oxidative stress and mitochondrial dysfunction in the pathogenesis of Parkinson disease—resemblance to the effect of amphetamine drugs of abuse. *Free Radic. Biol. Med.*, 62: 186 – 201. DOI: 10.1016/j.freeradbiomed.2013.05.042
- PERRY, V.H. (2004): The influence of systemic inflammation on inflammation in the brain: implications for chronic neurodegenerative disease. *Brain Behav. Immun.*, 18(5): 407 – 413. DOI: 10.1016/j.bbi.2004.01.004
- PITTELLA, J.E. (2013): Pathology of CNS parasitic infections. In: DEISENHAMMER, F., TEUNISSEN, C.E., TUMANI, H. (Eds) *Handbook of Clinical Neurology*. Volume 146. ELSEVIER, pp. 65 – 88
- POZIO, E. (2007): Taxonomy, biology and epidemiology of *Trichinella* parasites. In: DUPOUY-CAMET, J., MURRELL, K.D. (Eds.) *FAO/WHO/OIE Guidelines for the Surveillance, Management, Prevention and Control of Trichinellosis*. World Organisation for Animal Health Press, Paris, pp. 1 – 35
- PRANDOVŠKY, E., GASKELL, E., MARTIN H., DUBEY, J.P., WEBSTER, J.P., MCCONKEY, G.A. (2011): The neurotropic parasite *Toxoplasma gondii* increases dopamine metabolism. *PLoS ONE*, 6(9): e23866. DOI: 10.1371/journal.pone.0023866
- PRINGSHEIM, T., JETTE, N., FROLKIS, A., STEEVES, T.D. (2014): The prevalence of Parkinson's disease: a systematic review and me-

- ta-analysis. *Mov. Disord.*, 29(13): 1583 – 1590. DOI: 10.1002/mds.25945.
- QIAN, L., FLOOD, P. M. (2008): Microglial cells and Parkinson's disease. *Immunol. Res.*, 41(3): 155 – 164. DOI: 10.1007/s12026-008-8018-0
- QIAN, W., ZHAO-MING, Z., YING, P., JI-HUAN, Z.S., ZHENG, S.Z., JIAN-TING, C. (2015): Advanced oxidation protein products as a novel marker of oxidative stress in postmenopausal osteoporosis. *Med. Sci. Monit.*, 21: 2428 – 2432. DOI: 10.12659/MSM.894347.
- ROUSSA, E., FARKAS, L.M., KRIEGLSTEIN, K. (2004): TGF-beta promotes survival on mesencephalic dopaminergic neurons in cooperation with Shh and FGF-8. *Neurobiol. Dis.*, 16(2): 300 – 310. DOI: 10.1016/j.nbd.2004.03.006
- SCHNEIDER, C.A., RASBAND, W.S., ELICEIRI, K.W. (2012): NIH Image to ImageJ: 25 years of image analysis. *Nat. Methods*, 9(7): 671 – 675
- SCHULZ, J.D., HAWKES, E.L., SHAW, C.A. (2006): Cycad toxins, *Helicobacter pylori* and Parkinsonism: cholesterol glucosides as the common denominator. *Med. Hypotheses*, 66(6): 1222 – 1226. DOI: 10.1016/j.mehy.2004.12.033
- SENZOLO, M., SCHIFF, S., D'ALOISO, C.M., CRIVELLIN, C., CHOLONGITAS, E., BURRA, P., MONTAGNESE, S. (2011): Neuropsychological alterations in hepatitis C infection: The role of inflammation. *World J. Gastroenterol.*, 17(29): 3369 – 3374. DOI: 10.3748/wjg.v17.i29.3369
- SHERER, T.B., BETARBET, R., TESTA, C.M., SEO, B.B., RICHARDSON, J.R., KIM, J.H., MILLER, G.W., YAGI, T., MATSUNO-YAGI, A., GREENAMYRE, J.T. (2003): Mechanism of toxicity in rotenone models of Parkinson's disease. *J. Neurosci.*, 23(34): 10756 – 10764
- SUBRAMANIAM, S.R., FEDEROFF, H.J. (2017): Targeting microglial activation states as a therapeutic avenue in Parkinson's disease. *Front Aging Neurosci.*, 9: 176. DOI: 10.3389/fnagi.2017.00176.
- TABREZ, S., JABIR, N.R., SHAKIL, S., GREIG, N.H., ALAM, Q., ABUZENADAH, A.M., DAMANHOURI, G.A., KAMAL, M.A. (2012): A synopsis on the role of tyrosine hydroxylase in Parkinson's disease. *CNS Neurol. Disord. Drug Targets*, 11(4): 395 – 409
- TANSEY, M.G., GOLDBERG, M.S. (2010): Neuroinflammation in Parkinson's disease: its role in neuronal death and implications for therapeutic intervention. *Neurobiol. Dis.*, 37(3): 510 – 518. DOI: 10.1016/j.nbd.2009.11.004
- TOMS, C., POWRIE, F. (2001): Control of intestinal inflammation by regulatory T cells. *Microbes Infect.*, 3(11): 929
- VAWTER, M.P., DILLON-CARTER, O., TOURTELLOTTE, W.W., CARVEY, P., FREED, W.J. (1996): TGFbeta1 and TGFbeta2 concentrations are elevated in Parkinson's disease in ventricular cerebrospinal fluid. *Exp. Neurol.*, 14(2): 313 – 322. DOI: 10.1006/exnr.1996.0200
- VENDITTI, P., DI STEFANO, L., DI MEO, S. (2013): Mitochondrial metabolism of reactive oxygen species. *Mitochondrion*, 13(2): 71 – 82. DOI: 10.1016/j.mito.2013.01.008
- VENTURIELLO, S.M., GIAMBARTOLOMEI, G.H., COSTANTINO, S.N. (1995): Immune cytotoxic activity of human eosinophils against *Trichinella spiralis* newborn larvae. *Parasite Immunol.*, 17(11): 555 – 559
- WALKER, T.L., KEMPERMANN, G. (2014): One mouse, two cultures: isolation and culture of adult neural stem cells from the two neurogenic zones of individual mice. *J. Vis. Exp.*, (84): e51225. DOI: 10.3791/51225
- WANG, G.Y., DU, J.F., DUN, G.Q., SUN, W.L., WANG, J.X. (2011): Evaluation of artificial digestion method on inspection of meat for *Trichinella spiralis* contamination and influence of the method on muscle larvae recovery. *Zhongguo Xue Xi Chong Bing Fang Zhi Za Zhi*, 23(2): 211 – 213. PMID: 22164633
- WITKO-SARSAT, V., FRIEDLANDER, M., CAPELLÈRE-BLANDIN, C., NGUYEN-KHOA, T., NGUYEN, A.T., ZINGRAFF, J., JUNGERS, P., DESCAMPS-LATSCHA, B. (1996): Advanced oxidation protein products as a novel marker of oxidative stress in uremia. *Kidney Int.*, 49(5): 1304 – 1313. DOI: 10.1038/ki.1996.186
- WU, WY-Y., KANG, K-H., CHEN, SL-S., CHIU, SY-H., YEN, AM-F., FANN, JC-Y., SU, C-W. (2015): Hepatitis C virus infection: A risk factor for Parkinson's disease. *J. Viral Hepat.*, 22 (10): 784 – 791. DOI: 10.1111/jvh.12392
- ZHU, W.H., MAJLUF-CRUZ, A., OMBURO, G.A. (1998): Cyclic AMP-specific phosphodiesterase inhibitor rolipram and RO-20-1724 promoted apoptosis in HL60 promyelocytic leukemic cells via cyclic AMP-independent mechanism. *Life Sci.*, 63(4): 265 – 274. DOI: 10.1016/S0024-3205(98)00270-7