

## Clinical Report

# Fanconi syndrome with lysinuric protein intolerance

Eleonora Riccio and Antonio Pisani

Department of Public Health, University Federico II, Naples, Italy

Correspondence and offprint requests to: Eleonora Riccio; E-mail: elyriccio@libero.it

### Abstract

We present the case of a 9-year-old child with lysinuric protein intolerance and Fanconi syndrome. She was referred to our hospital with a persistent metabolic acidosis and polyuria. Renal investigations revealed all laboratory signs of Fanconi syndrome, with glucosuria, generalized aminoaciduria, phosphaturia and severe hypercalciuria. The diagnosis of Fanconi syndrome was confirmed by a renal biopsy that showed extensive lesions of proximal tubular epithelial cells with vacuolation of these cells and a sloughing of the brush border.

**Keywords:** Fanconi syndrome; hyperammonaemia; lysinuric protein intolerance

### Introduction

Lysinuric protein intolerance (LPI; OMIM 222700) is a rare autosomal recessive multiorgan disorder in which the renal and intestinal transport of the cationic amino acids lysine, arginine and ornithine is defective [1]. The molecular defect resides in mutations of the SLC7A7 gene, encoding for  $\gamma^+$  LAT-1, the catalytic light chain subunit of a complex belonging to the heterodimeric amino acid transporter family [2]. The basolateral transport defect is expressed in the epithelial cells of the intestine and the kidney tubules, hepatocytes and skin fibroblasts [3], leading to a depletion of their tissue pools and, as a consequence, to impaired functioning of the hepatic urea cycle with hyperammonaemic episodes (Figure 1). Most, but not all, of the symptoms of LPI have been linked to a secondary urea cycle derangement due to impaired transport of cationic amino acids. Typically, symptoms begin after weaning with refusal of feeding, vomiting and consequent failure to thrive. Hepatosplenomegaly, haematological anomalies and neurological involvement, including hyperammonaemic coma, are recurrent clinical features [4, 5]. Two major complications, pulmonary alveolar proteinosis and renal disease, are increasingly observed in LPI patients [5, 6]. The disease has long been erroneously considered relatively benign when appropriately treated with low-protein diet and L-citrulline supplementation. During the past years, however, other manifestations have suggested that LPI is not only a urea cycle disorder, but also a complex multisystem disease with an uncertain outcome [7], thus considerably modifying the way to view this disorder.

We describe the clinical course in a patient with LPI and renal pathology.

### Case report

The patient was diagnosed with LPI at the 7 years of age; she was born to consanguineous (first-cousin) healthy parents after three abortions. The patient had a brother who died at the age of 6 years of respiratory failure; he was diagnosed with mucopolysaccharidosis because of the findings of delayed psychomotor development, anorexia, repeated episodes of acute bronchitis, hepatosplenomegaly and pancytopenia. At 6 years, our patient presented signs and symptoms similar to those observed in her brother: in particular, she was hospitalized because of delayed psychomotor development, vomiting and mild hepatosplenomegaly. The family history and clinical features suggested a diagnosis of metabolic disease that was then investigated. Complete blood count showed that mild pancytopenia, renal and hepatic functions were normal, lactate was 2.5 mmol/L (normal <2 mmol/L), plasma ammonia was 194 mmol/L (normal <70 mmol/L), ferritin was 103 mmol/L (normal 2–59 mmol/L) and LDH was 1180 U/L (normal 26–534 U/L). LPI was diagnosed based on the findings of reduced plasma ornithine, arginine and lysine, and of an increase in their urinary levels. The final proof of a defect in the SLC7A7 amino acid transporter was given by the finding of a homozygous c.726G>A mutation in the patient's DNA [8], responsible for the premature termination of the protein at amino acid 242. Subsequently, she was put on a protein-restricted diet (0.7–1.2 g/kg per day) and L-citrulline supplementation (100 mg/kg per day), and in the following 2 years her clinical condition remained stable and the plasma ammonia levels were in the normal range. Then, at the age of 9, a persistent metabolic acidosis (pH 7.33,  $p\text{CO}_2$  28 mmHg and bicarbonate

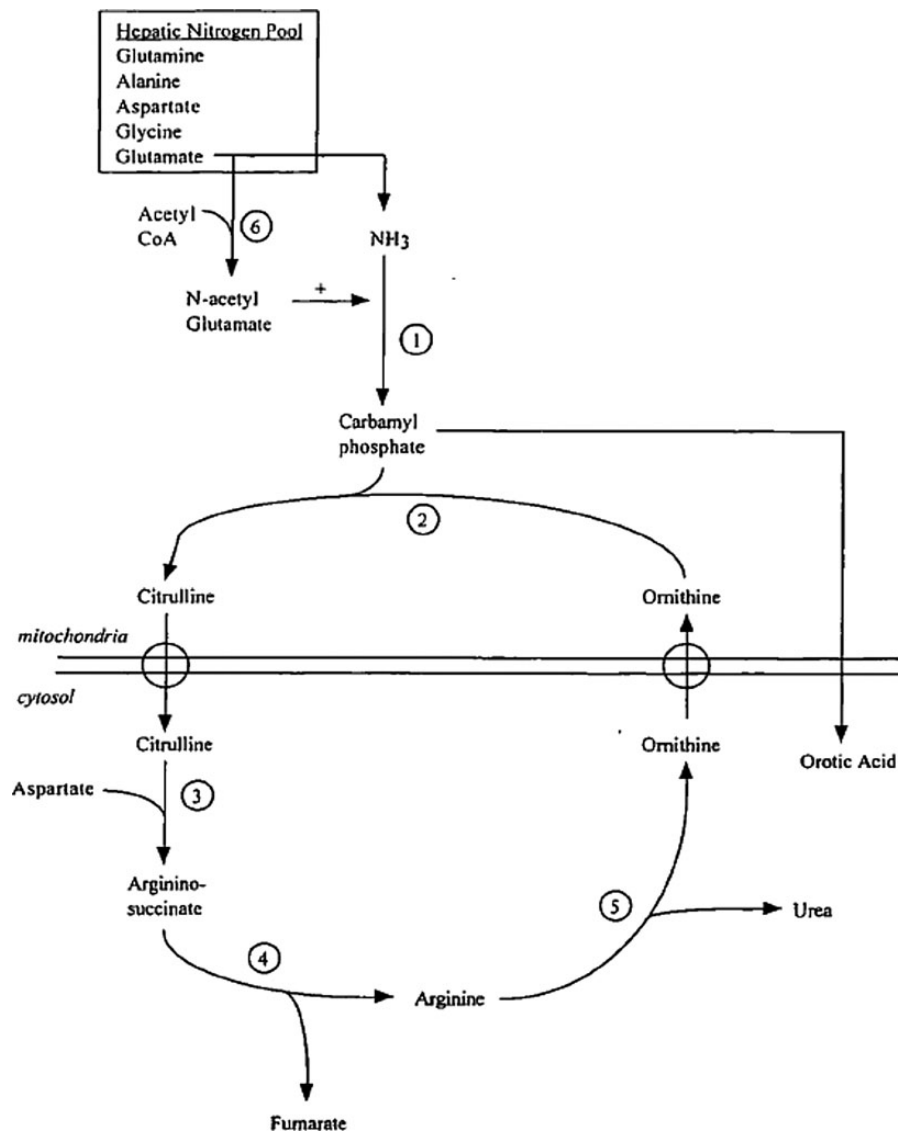


Fig. 1. Pathway for the disposal of nitrogen waste products in the urea cycle. Each number represents the following enzymes: 1, carbamylphosphate synthetase; 2, ornithine carbamyltransferase; 3, argininosuccinate synthetase; 4, argininosuccinate lyase; 5, arginase; 6, N-acetylglutamate synthetase. CoA, co-enzyme A;  $\text{NH}_3$ , ammonia.

14 mmol/L) with an elevated anion gap of 20.4 (normal <15) was observed, and the patient was referred to our hospital. Plasma organic acids were normal. Furthermore, the patient presented polyuria (diuresis >3000 mL/day) and renal investigations revealed all laboratory signs of Fanconi syndrome, with glucosuria, generalized aminoaciduria, phosphaturia and severe hypercalciuria (Table 1). The glomerular filtration rate, evaluated by the creatinine clearance (Schwartz equation), was 88 mL/min per  $1.73 \text{ m}^2$  (normal 80–120). Echosonography of the kidney was normal.

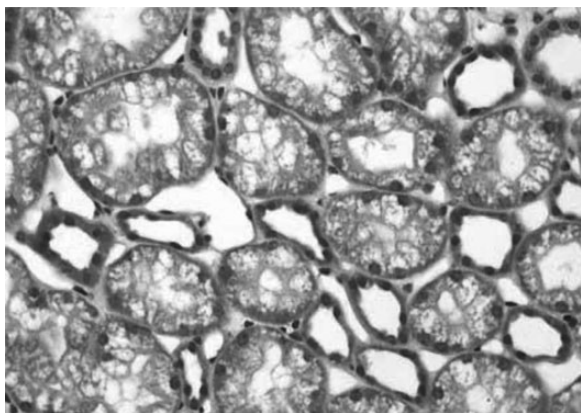
To explain the combination of a renal Fanconi syndrome and elevated levels of organic acids in the urine, a renal biopsy was performed after parental informed consent had been obtained. Consistent with the existence of a Fanconi syndrome, renal biopsy showed extensive lesions of proximal tubular epithelial cells with a dramatic vacuolation of these cells and a sloughing of the brush border. No evidence of immune deposits was shown by immunofluorescence (Figure 2).

Table 1. Laboratory data on admission

	Normal range	Patient
Serum potassium (mEq/L)	3.6–5.0	3.3
Serum phosphorus (mg/dL)	2.5–4.3	2.6
Serum uric acid (mg/dL)	2.5–7.5	2.1
Serum chloride (mEq/L)	101–109	83
Serum bicarbonate (mmol/L)	22.0–26.0	14
Anion gap (mEq/L)	$12 \pm 3$	20.4
Proteinuria	Negative (–)	(+)
Urinary pH	4.8–7.5	6.5
Urinary glucose	Negative (–)	(3+)

## Discussion

Renal involvement is a well-known manifestation of LPI. However, its progressive characteristic has recently been emphasized [9]. Most of the patients present with mild proteinuria and microscopic haematuria for years without overt consequences. However, some patients have



**Fig. 2.** Light microscopy shows proximal tubules with vacuolated cytoplasm and brush border attenuation.

glomerular dysfunction due to mild glomerulonephritis, whereas others display signs of Fanconi syndrome [9, 10]. Renal involvement may sometimes progress to end-stage renal disease requiring dialysis and renal transplantation [9]. Our patient had evidence of a full-blown Fanconi syndrome with proximal tubular acidosis. Besides a proximal tubular acidosis, other signs of a complex tubular disorder were found, i.e. diminished renal reabsorption of phosphate [11], glucose, amino acids and carnitine. The majority of cases of proximal renal tubular acidosis fit into the category of generalized tubule dysfunction with the Fanconi syndrome. This defect can be due either to backleak of solutes via the paracellular pathway or to a generalized disorder of the apical membrane and its transporters, a disorder of the basolateral  $\text{Na}^+$ ,  $\text{K}^+$ -ATPase or a metabolic disorder that lowers ATP concentration. Electron microscopy of renal tissue showed severe abnormalities in the ultrastructure of proximal tubular apical membranes. We suggest that this is the basic disorder causing proximal tubular dysfunction, either through a diminished resorptive area and decreased availability of transport proteins or through increased backleak of solutes from the proximal tubular cell. The cause of the ultrastructural changes remains to be determined; possible mechanisms are a direct toxic effect of retained metabolites on the cell membrane or a generalized disorder in cellular energy metabolism [5].

The hypothesis that the accumulation of intracellular lysine in the proximal tubule because of diminished basolateral transport might exercise a cytotoxic effect leading to renal tubular damage [12] has been confuted by the evidence that patients with hyperlysinemia due to other diseases (i.e. 2-aminoacidic semialdehyde synthetase deficiency), with a similar heavy load on the renal tubular  $\gamma$ -LAT-1 system, never develop a renal Fanconi syndrome [13].

Therefore, we consider the intratubular accumulation of lysine an unlikely candidate for the development of the renal Fanconi syndrome.

It is known that, in LPI, there is a specific defect of dibasic aminoacid transport, located at the basolateral membrane of epithelial cells. However, this defect does not cause disturbances in other basolateral transport systems, such as  $\text{Na}^+$  and  $\text{K}^+$ -ATPase. It is therefore not likely that it would be the cause of the Fanconi syndrome.

In conclusion, this case demonstrates a rapid development of a Fanconi syndrome in a child with LPI. The existence and possible cytotoxic effect of intracellular lysine accumulation in proximal tubular cells deserve further attention.

*Conflict of interest statement.* None declared.

## References

1. Perheentupa J, Visakorpi J. Protein intolerance with deficient transport of basic amino acids: another inborn error of metabolism. *Lancet* 1965; 2: 813–816
2. Torrents D, Mykkanen J, Pined M *et al.* Identification of SLC7A7, encoding  $\gamma$ -LAT-1, as the lysinuric protein intolerance gene. *Nat Genet* 1999; 21: 293–296
3. Rajantie J, Simell O, Perheentupa J. Basolateral membrane transport defect for lysine in lysinuric protein intolerance. *Lancet* 1974; 1: 219–221
4. Carpenter TO, Levy HL, Holtrop ME *et al.* Lysinuric protein intolerance presenting as childhood osteoporosis. *N Engl J* 1985; 312: 290–294
5. Di Rocco M, Garibotto G, Rossi GA *et al.* Role of haematological, pulmonary and renal complications in the long-term prognosis of patients with lysinuric protein intolerance. *Eur J Pediatr* 1993; 152: 437–440
6. Parto K, Kallajoki M, Aho H *et al.* Pulmonary alveolar proteinosis and glomerulonephritis in lysinuric protein intolerance. *Hum Pathol* 1994; 25: 400–407
7. Broer S. Lysinuric protein intolerance: one gene, many problems. *Am J Physiol Cell Physiol* 2007; 293: C540–C5419
8. Mykkänen J, Torrents D, Pineda M *et al.* Functional analysis of novel mutations in  $\gamma$ -LAT-1 amino acid transporter gene causing lysinuric protein intolerance (LPI). *Hum Mol Genet* 2001; 9: 431–438
9. Tanner LM, Nanto-Salonen K, Niinikoski H *et al.* Nephropathy advancing to end-stage renal disease: a novel complication of lysinuric protein intolerance. *J Pediatr* 2007; 150: 631–634
10. Benninga MA, Lilien M, de Koning TJ *et al.* Renal Fanconi syndrome with ultrastructural defects in lysinuric protein intolerance. *J Inherit Metab Dis* 2007; 30: 402–403
11. Walton RJ, Bijvoet OL. Nomogram for derivation of renal threshold phosphate concentration. *Lancet* 1975; 16: 309–310
12. Racusen LC, Finn WF, Whelton A *et al.* Mechanisms of lysine-induced acute renal failure in rats. *Kidney Int* 1985; 27: 517–522
13. Slingerland RJ, Ruiters JPN, Blau N *et al.* Hyperlysinemia type I: effects on urea-cycle and methylation reactions. *J Inherit Metab Dis* 2004; 27: 55

*Received for publication: 8.8.14; Accepted in revised form: 22.9.14*