



# Retroperitoneoscopic enucleation adrenalectomy: a viable surgical option for small nonsecreting adrenal tumors with low potential of malignancy

Hao Yan, Gan Cao<sup>^</sup>, Xin Cui, Jiang-Tao Wu, Tong-Wen Ou<sup>^</sup>, Qi Wang, Bo Cui, Wei Gao, Chun-Song Jia, Jian-Jun Xu

Department of Urology, Xuanwu Hospital, Capital Medical University, Beijing, China

**Contributions:** (I) Conception and design: H Yan, TW Ou; (II) Administrative support: None; (III) Provision of study materials or patients: H Yan, X Cui, JT Wu, Q Wang, B Cui, W Gao, CS Jia, JJ Xu; (IV) Collection and assembly of data: H Yan, G Cao, X Cui, JT Wu, Q Wang, B Cui, W Gao, CS Jia, JJ Xu; (V) Data analysis and interpretation: H Yan, G Cao; (VI) Manuscript writing: All authors; (VII) Final approval of manuscript: All authors.

**Correspondence to:** Tong-Wen Ou, PhD, MD. Department of Urology, Xuanwu Hospital, Capital Medical University, No. 45 Changchun Street, Beijing 100053, China. Email: outongwen1967@126.com.

**Abstract:** Laparoscopic total adrenalectomy has become the standard treatment for adrenal mass. Meanwhile, there has been a growing trend toward laparoscopic adrenal-sparing surgery worldwide to avoid the risk and potential complications of adrenal insufficiency. The objectives of this study were to describe a retroperitoneoscopic adrenal tumor enucleation technique, to assess the clinical outcomes of this technique in the treatment of 20–40 mm nonsecreting adrenal tumor (NAT) with low potential of malignancy, and to provide a feasible choice for patients who have preference on resection. This study was a retrospective analysis of 61 patients with low potential of malignancy in 20–40 mm NAT identified at the first imaging examination or during follow-up. All patients were scheduled for planned enucleation adrenalectomy by a single surgeon between July 2016 and December 2020 in Xuanwu Hospital, Beijing, China. In all patients, retroperitoneoscopic surgery was performed via a retroperitoneoscopic process for all the patients. The crucial techniques of enucleation are presented in the video. Safety and feasibility factors of enucleation technique were measured for this study. No blood transfusion or organ injury was registered during the operation. The median operation time was 75 min, and the median blood loss was 35 mL. All operations were successfully performed without open conversion. A total of 58 patients received successful enucleation surgery. Three cases were converted to retroperitoneoscopic total adrenalectomy. In this study, surgical outcomes of retroperitoneoscopic enucleation adrenalectomy as a method to remove adrenal tumors were assessed. This procedure is a feasible and safe technique with the added benefit of preserving the remaining functional adrenal tissue.

**Keywords:** Adrenalectomy; enucleation; incidentaloma; retroperitoneoscopy

Submitted Jan 25, 2023. Accepted for publication Sep 27, 2023. Published online Nov 16, 2023.

doi: 10.21037/tau-23-54

**View this article at:** <https://dx.doi.org/10.21037/tau-23-54>

<sup>^</sup> ORCID: Gan Cao, 0000-0003-4474-3490; Tong-Wen Ou, 0000-0001-8055-9418.

## Introduction

The incidence of adrenal incidentalomas (AIs) has been gradually increasing along with the widespread application of abdominal ultrasonography, computed tomography (CT), and magnetic resonance imaging (1). Nonfunctional adrenal adenoma accounts for approximately 80% of all AIs (2-4). According to the American Association of Clinical Endocrinologists and American Association of Endocrine Surgeons (AACE/AAES) guidelines for the management of AIs, for nonsecreting adrenal tumor (NAT) <40 mm with no evidence of malignancy in imaging, repeat CT examination and biochemical evaluation during follow-up is recommended. For NAT  $\geq$ 40 mm or NAT <40 mm showing potential malignancy throughout follow-up, surgical resection is recommended (5). The current strategies in many countries for the management of AIs are quite similar to the recommendations stated in the AACE/AAES guidelines (6-8). However, laparoscopic total adrenalectomy as a standard treatment to remove adrenal mass has been criticized due to the risk of potential complications of adrenal insufficiency, especially in the occurrence of contralateral adrenal disease later in life (9).

Recently, laparoscopic adrenal-sparing surgery has become increasingly popular, with the goal to resect the whole tumor and preserve a functional adrenal remnant to avoid or decrease the potential need for medical adrenal replacement in the future (9,10). In 1995, the concept of adrenal tumor enucleation was presented by Nakada

*et al.* (11) in the treatment of aldosterone-producing adenoma (APA). Its main objective is to enucleate the lesion and preserve maximal remnant adrenal tissue. Furthermore, it has been utilized in laparoscopic surgery and proven safe and effective by other studies (10,12). However, controversies remain centered around the risk of multifocality and unilateral hyperplasia in the treatment of APA (13), and detailed descriptions of the technique are rare. Such factors have restricted further application of enucleation technique in the treatment of adrenal tumor. Meanwhile, the NAT <20 mm showing very low potential both in malignancy and endocrine secretion (1). Therefore, patients with <20 mm NAT was scheduled for regular follow-up at the outpatient clinic.

The aims of this study are to describe a novel retroperitoneoscopic adrenal tumor enucleation technique, to assess the clinical outcomes of this technique in the treatment of 20–40 mm NAT with low potential of malignancy, and to provide a feasible choice for such patients who voice preference for resection. We present this article in accordance with the SUPER and STROBE reporting checklists (available at <https://tau.amegroups.com/article/view/10.21037/tau-23-54/rc>).

## Preoperative preparations and requirements

From July 2016 to December 2020, 61 patients who were scheduled to receive unilateral retroperitoneoscopic adrenal tumor enucleation therapy performed by a single surgeon (T.W.O.) were retrospectively recruited to be included in this study. All patients were identified at the first imaging examination or during follow-up with low potential of malignancy in 20–40 mm NAT in Xuanwu Hospital, Beijing, China.

The inclusion criteria: (I) the adrenal mass was incidentally detected in imaging studies for other clinical purposes; (II) the size of the tumor was 20–40 mm before operation; (III) the low potential malignancies were discovered at the first imaging examination or during follow-up; (IV) the patient voiced preference for enucleation resection treatment.

The exclusion criteria: (I) the presence of hormonal activity of adrenal tumor confirmed by biochemical evaluation; (II) any previous history of malignancies; (III) an obviously irregular tumor border as revealed by CT; (IV) the patient was unwilling to receive the enucleation therapy.

In addition, according to the imaging characteristics listed by AACE/AAES guidelines (Hounsfield units  $\geq$ 10

### Highlight box

#### Surgical highlights

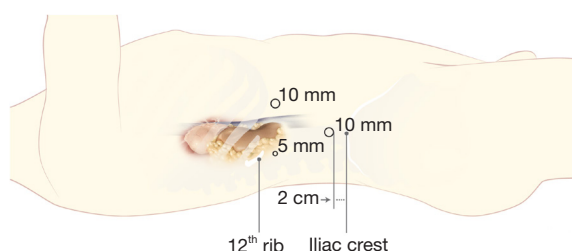
- A viable surgical option for small nonsecreting adrenal tumors (NATs) with low potential of malignancy by enucleation adrenalectomy.

#### What is conventional and what is novel/modified?

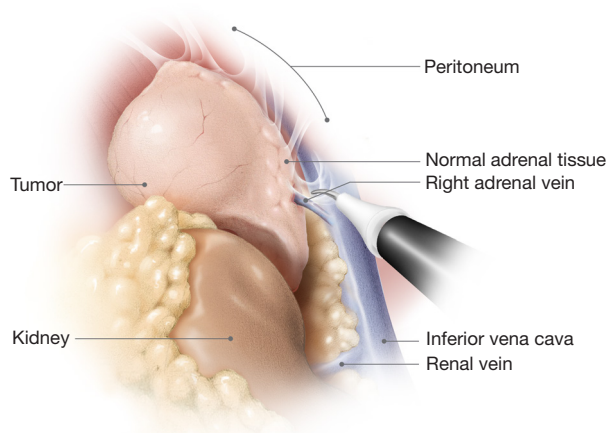
- Laparoscopic total adrenalectomy as a standard treatment to remove adrenal mass has been criticized due to the risk of potential complications of adrenal insufficiency.
- In our study, retroperitoneoscopic enucleation adrenalectomy as a method to remove adrenal tumors and preserve maximal remnant adrenal tissue.

#### What is the implication, and what should change now?

- For the patient with low potential of malignancy in 20–40 mm NAT. This procedure is a feasible and safe technique with the added benefit of preserving the maximal remaining functional adrenal tissue.



**Figure 1** Trocar placement for laparoscopic enucleation adrenalectomy performed on patient's right side. This figure is being published with permission from ELLANITTERS.COM, which retains ownership of the copyright.



**Figure 2** Distant view of mobilized adrenal gland and adrenal vein prior to enucleation step. This figure is being published with permission from ELLANITTERS.COM, which retains ownership of the copyright.

on non-contrast CT scan, significant growth in follow-up, <50% agent washout in a contrast CT delayed scan, irregular border, and inhomogeneous tumor density), any imaging characteristics found which satisfied the aforementioned list were defined as potential malignancy. Meanwhile, in this study, tumors expressing no more than two imaging characteristics from the above list, excluding an irregular tumor border, were defined as having low potential of malignancy.

The study was conducted in accordance with the Declaration of Helsinki (as revised in 2013). The study was approved by institutional ethics board of Xuanwu Hospital Capital Medical University (No. 2021145) and informed consent was obtained from the patients for publication of

this surgical technique and accompanying images and video. Patient baseline characteristics, perioperative outcome, complication and pathology findings were collected. In this study, data were presented as count (%) for categorical variables were presented as, mean  $\pm$  standard deviation (SD) for normally distributed continuous variable and median [interquartile range (IQR)] for continuous variables that do not follow a normal distribution.

## Step-by-step description

### Patient positioning and port placement

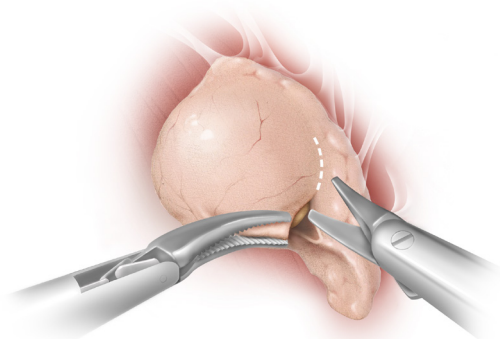
Under general anesthesia, the patient was placed in a lateral decubitus position with hyperextension, and the surgery was performed through a three-trocar routinely retroperitoneal approach (14,15).

Firstly, the retroperitoneal working space was made by index finger and balloon expansion (400–500 mL air) through a 2-cm skin incision below the tip of the 12<sup>th</sup> rib. Furthermore, a 10-mm port for the laparoscope was placed 2 cm above the iliac crest, and the other port was placed at the anterior auxiliary line. Finally, the third port was placed in the incision. Regardless of the side on which the operation was performed, the surgeon's left-hand port was the 5-mm port and the other two ports were 10 mm (Figure 1).

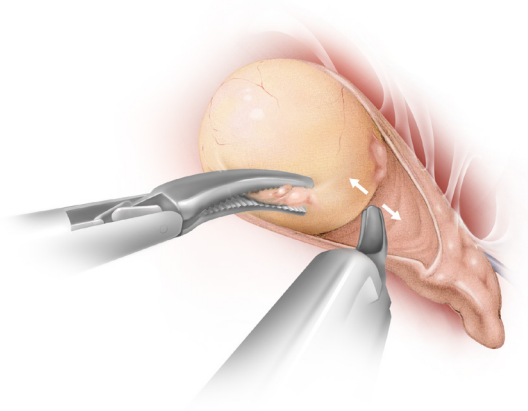
### Exposure of the adrenal gland

After entering of the retroperitoneal space, the fat tissue outside of Gerota fascia was removed by J-hook electrocautery followed by longitudinal dissection of the Gerota fascia. Furthermore, the adrenal was reached and mobilized cautiously in all three dissection planes: between the perinephric fat and the anterior renal fascia, between the perinephric fat and the posterior renal fascia, and between the bottom of the adrenal and the surface of the upper kidney.

The whole adrenal tumor and adrenal vein was carefully mobilized until the tumor was clearly exposed prior to enucleation (Figure 2). Simultaneously, the arterial and venous branches were coagulated by J-hook electrocautery or clipped with Hem-o-Lok or titanium clips. The appropriate hemostasis method was selected based on the diameter of the vessel and the experience of the surgeon. In all cases, the adrenal vein was preserved and any unnecessary resections were avoided in order to



**Figure 3** Sharp dissection of endoscopic scissors in the enucleation of adrenal tumor. This figure is being published with permission from ELLANITTERS.COM, which retains ownership of the copyright.

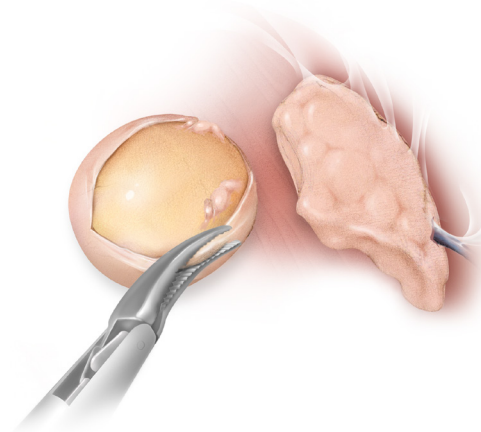


**Figure 4** Blunt dissection of endoscopic scissors in the enucleation of adrenal tumor. This figure is being published with permission from ELLANITTERS.COM, which retains ownership of the copyright.

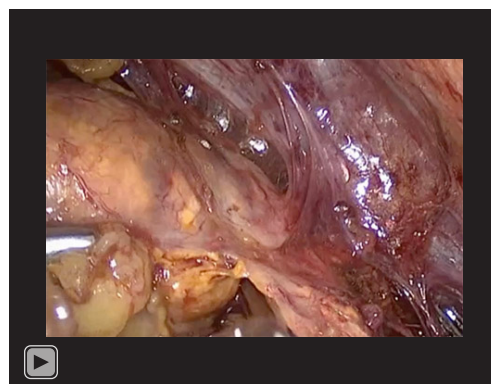
maintain the function of the remnant adrenal tissue. The intraoperative retroperitoneoscopic ultrasound was selected used to define the correct plane for enucleation in this process.

#### ***Adrenal tumor enucleation (Video 1)***

Once the tumor and adrenal vein were clearly exposed, endoscopic scissors were utilized to open the adrenal capsule between the tumor and the normal adrenal tissue in order to clearly identify the tumor margin (*Figure 3*). After distinguishing the border of the tumor, cautious blunt

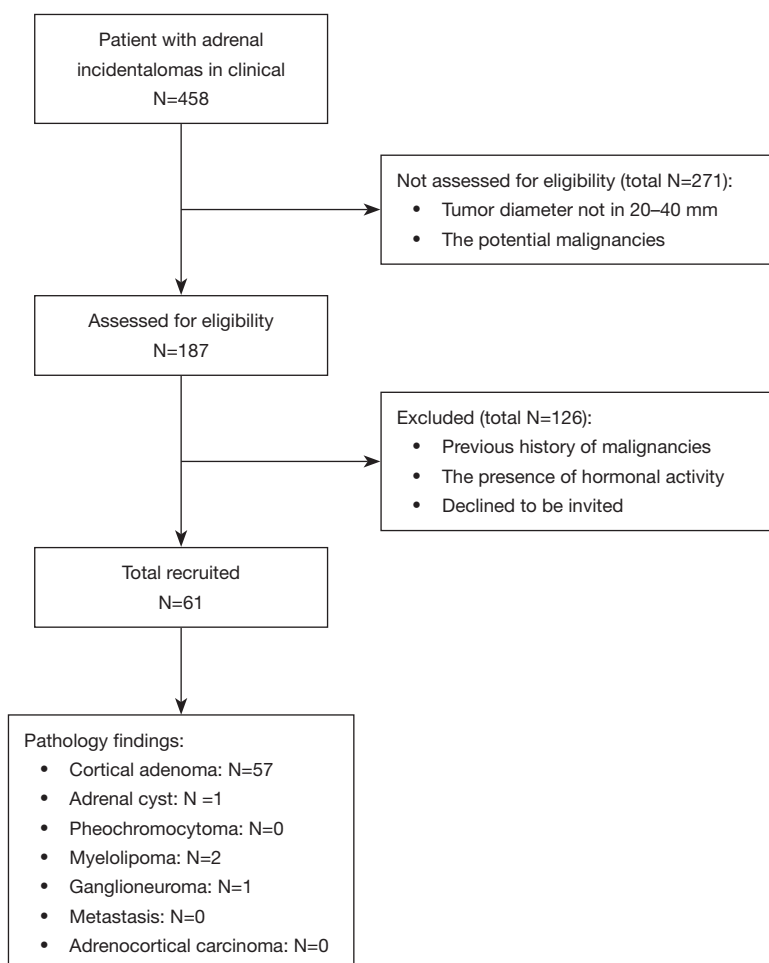


**Figure 5** Separated tumor after enucleation and preserved adrenal tissue. This figure is being published with permission from ELLANITTERS.COM, which retains ownership of the copyright.



**Video 1** laparoscopic enucleation adrenalectomy in the treatment of nonsecreting adrenal tumor.

dissection with endoscopic scissors was used to separate the tumor and normal adrenal tissue (*Figure 4*). The adrenal capsule was sharp dissected with endoscopic scissors to compliment blunt separation when necessary. Additionally, when blunt separation encountered difficulty, sharp dissection was occasionally utilized, erring on the side of normal tissue to ensure the whole tumor was enucleated *en bloc*. After the entire tumor was enucleated (*Figure 5*), suitable hemostasis was performed along the incision edge of the remnant adrenal tissue if needed. Finally, the isolated adrenal tumor was removed in an entrapment sack and successful hemostasis was reconfirmed prior to removal of the laparoscopic camera.



**Figure 6** Patients recruitment and follow-up flow diagram.

### Postoperative considerations and tasks

The estimated percentage of adrenal preserved was measured by subtracting the estimated size of the isolated adrenal tumor with little normal adrenal tissue which was removed from body from the estimated total size of the adrenal gland tissue by CT before operation. Follow-ups (6–34 months, mean: 16 months) were then conducted by phone interviews, during which the patients disclosed any adrenal imaging changes, surgically related complications, and adrenal hormonal activity symptoms.

Overall, 61 patients were retrospectively enrolled (Figure 6). The median size of the tumor was 26 mm. Imaging characteristics of tumors from all patients indicated

low potential of malignancy before surgical treatment. The baseline characteristics of patients in the study are presented in Table 1.

The perioperative outcomes are also listed in Table 1. All operations were successfully performed without open conversion. However, three cases were converted to retroperitoneoscopic total adrenalectomy due to accidental perforation of the adrenal vein. Median operation time was 75 minutes (66.5–88 minutes). Median estimated blood loss and estimated percentage of adrenal tissue preserved was 35 mL (20–50 mL) and 47% (30–57%) respectively. No blood transfusion or organ injury was registered during the operation. No drainage was required in 40 of 61 cases. For each of the remaining 21 cases, a single drainage tube



**Table 1** Patient baseline characteristics and perioperative outcome

| Variables                                     | Values             |
|---|--------------------|
| Total   | 61 (100.0)         |
| Baseline characteristics                      |                    |
| Male gender                                   | 30 (49.2)          |
| Age (years)                                   | 58 ( $\pm 7.5$ )   |
| BMI (kg/m <sup>2</sup> )                      | 25.8 ( $\pm 4.1$ ) |
| ASA score                                     | 1 [1–2]            |
| Tumor diameter (CT) (mm)                      | 26.5 ( $\pm 5.5$ ) |
| Left side                                     | 25 (41.0)          |
| Prior abdominal surgery                       | 4 (6.6)            |
| Perioperative outcomes                        |                    |
| Operation duration (min)                      | 81 ( $\pm 21$ )    |
| Estimated blood loss (mL)                     | 41 ( $\pm 35$ )    |
| Blood transfusions                            | 0                  |
| Conversion to RTA                             | 3 (4.9)            |
| Postoperative length in hospital (days)       | 1 [1–2]            |
| Estimated percentage of adrenal preserved (%) | 51 ( $\pm 16$ )    |
| Tumor defragmentation                         | 4 (6.6)            |
| Resection incomplete                          | 0                  |

Data are presented as median [IQR], mean ( $\pm$  SD) or count (percentage). BMI, body mass index; ASA, American Society of Anesthesiologists; CT, computed tomography; RTA, retroperitoneoscopy total adrenalectomy; IQR, interquartile range; SD, standard deviation.

was used, and the mean time of the drainage tube removal was 1 day.

Complications and pathology findings are shown in *Table 2*. A total of six complications were recorded among all cases. The intraoperative bleeding was dealt with by clamping the adrenal vein. Reported instances of postoperative subcutaneous emphysema and port site hematoma were resolved within 3 months of surgery. One case with small incisional hernia was recorded and surgical repair was applied. Overall, 93.4% of the tumors were cortical adenomas. No malignant tumors were found. Patients' blood pressure and the use of antihypertensive drugs were similar before and after surgery, and no other adrenal hormonal activity symptoms were registered during follow-up.

**Table 2** Complications and pathology findings

| Characteristics          | Count (%)  |
|--------------------------|------------|
| Complications            |            |
| Intraoperative bleeding  | 3 (4.9)    |
| Subcutaneous emphysema   | 1 (1.6)    |
| Port site hematoma       | 1 (1.6)    |
| Port site infection      | 0          |
| Organ injury             | 0          |
| Incisional hernia        | 1 (1.6)    |
| Total                    | 6 (9.8)    |
| Pathology findings       |            |
| Cortical adenoma         | 57 (93.4)  |
| Adrenal cyst             | 1 (1.6)    |
| Pheochromocytoma         | 0          |
| Myelolipoma              | 2 (3.3)    |
| Ganglioneuroma           | 1 (1.6)    |
| Metastasis               | 0          |
| Adrenocortical carcinoma | 0          |
| Total                    | 61 (100.0) |

## Tips and pearls

In this study, the tips are listed below: firstly, the tumor and adrenal vein should be clearly exposed before adrenal tumor enucleation. Secondly, in order to clearly identify the tumor margin, endoscopic scissors were utilized to open the adrenal capsule between the tumor and the normal adrenal tissue. Meanwhile, laparoscopic aspirator also was utilized for blunt separation when diffuse blood oozing. Thirdly, electrocautery is sufficient for hemostasis in the wound of normal adrenal tissue after tumor enucleation. Otherwise, bleeding can be well controlled with suturing or titanium clips if needed.

## Discussion

Retroperitoneoscopic total adrenalectomy as a gold standard treatment has been widely utilized to remove adrenal masses (5,16). According to the AACE/AAES guidelines, patients with NAT <40 mm showing imaging characteristics indicative of potential malignancy at the first or subsequent

follow-ups should be considered for surgery. However, in such patients, the potential for malignancy is typically low, and the prevalence of adrenocortical carcinoma (ACC) in these cases is rare (17,18). Nevertheless, most of such patients would come with emotional burden and refuse continuous follow-up by showing strongly prefer surgical resection. Additionally, laparoscopic total adrenalectomy has been criticized due to the risk of adrenal insufficiency later in life (9,19). Thus, the objective of this study was to investigate the viability of retroperitoneoscopic enucleation adrenalectomy as an option for NAT removal instead of traditional laparoscopic total adrenalectomy.

Compared with traditional open adrenalectomy, the minimally invasive advantages of laparoscopic adrenalectomy have been widely established, including shorter hospital stays, lower risk of complications, and more rapid recovery (20). In the present study, the safety and feasibility of retroperitoneoscopic tumor enucleation were found to be similar to that of laparoscopic total adrenalectomy. Moreover, the mean percentage of estimated remnant adrenal tissue was 51%. Additionally, it is known that adequate venous drainage is critical for the preservation of remnant adrenal tissue function (21). The retro-peritoneal vein plexus and adrenal vein contribute to the maintenance of adrenal function. However, some have suggested that it is difficult to preserve an intact retro-peritoneal vein while mobilizing the adrenal gland, especially in patients with smaller glands (22). Therefore, we emphasize that preservation of the adrenal vein is critical for the preservation of functional residual adrenal tissue.

During the surgical procedure, adequate hemostasis of the adrenal dissection margin is critical for surgical safety. It may be argued that utilization of endoscopic scissors would cause more bleeding during operation. Gupta *et al.* (23) recommended utilizing locking clips and pinpoint cautery for partial adrenalectomy. However, in our study, the blunt and sharp dissection features of endoscopic scissors were sufficient to clearly separate the planes between the tumor margin and normal adrenal tissue in most cases without serious bleeding. This was consistent with the results by Kok *et al.* (24) who found enucleation of the APA to be simple and bloodless. Furthermore, if electrocautery is insufficient for hemostasis, as it was in one patient, bleeding can be controlled with suturing and titanium clips. Nevertheless, due to accidental stripping of the adrenal vein during enucleation, three cases in our study in which the tumor was close to the adrenal vein were converted to retroperitoneoscopic total adrenalectomy. Because

the adrenal vein was already clearly exposed prior to enucleation, the conversion of surgical methods was quickly achieved. However, to avoid the unnecessary hemorrhagic risk in the future, we recommend total adrenalectomy for patients with tumors lying closed to the adrenal vein.

Though enucleation adrenalectomy can be successfully performed in many cases and no malignancies were found in this study, there is one notable limitation to its use. Because enucleation therapy is limited to tumors with regular border, it cannot be used to remove malignant adrenal masses such as in ACC. In our study, it was necessary to preemptively prepare an alternative surgical strategy in case ACC was discovered during surgery. In our opinion, once the tumor was suspected to be cancer after enucleation (the intraoperative frozen section of the isolated adrenal tumor which removed from body was suspected cancer), immediately salvage total adenectomy before anesthesia recovery would have been performed. Meanwhile, when cancer was found by pathology after surgery, salvage total adenectomy would have been performed better within 2 weeks. Also, in our opinion, successful enucleation requires an experienced retroperitoneoscopic adrenal oncology surgeon in order to avoid tumor fragmentation during adrenal gland mobilizing and to distinguish the malignant tumor before the enucleation step.

Recently, due to the low prevalence of ACC finding, the cost-effectiveness between the surgical treatment and follow-up strategies for NAT <40 mm showing characteristics indicative of potential malignancy has been a long-term controversy. In 2012, Wang *et al.* (25) claimed that adrenalectomy was cost-effective for neoplasms >40 mm and in patients <65 years by a Markov decision model. Moreover, a study comparing surgical outcomes of NAT ≥40 mm and potentially malignant NAT <40 mm by Pędziwiatr *et al.* (26) found the risk of malignancy in adrenal tumors <40 mm was lower (1.8%) than the risk of complications related to laparoscopic total adrenalectomy (3.6%). Although the total complication rate we reported herein was 9.8%, no organ injury and nor blood transfusions were registered in this study. In addition, no malignancies were found. The minimal invasions of laparoscopy and the low prevalence of ACC were consistent with other studies (9,10). In our opinion, the low prevalence of ACC may be partially explained by low suspicious evidence of malignancy in most patients. Thus, the pathological results provide a significant counterargument for surgical treatment. However, the risk of complications simply compared with prevalence of malignancy is unreasonable because the

clinical consequences associated with these risks are not comparable in severity.

In addition, the emotional burden on patients with potentially malignant NAT <40 mm is rarely considered. In 2013, a 2-year follow-up study of 145 patients with benign NAT (27) reported that most patients were worried when the AIs were initially found. Even though no evidence of adrenal malignancy was reported, a small number of patients in that study still expressed worry during follow-up appointments. In our experience, once any potential malignancy characteristics were found throughout follow-up, patients (especially younger patients) voiced strong preference for resection. On the other hand, the current guidelines regarding management of AIs during follow-up are still not well adhered to in some places. Failure to evaluate suspicious malignant tumors during follow-up may lead to significant patient morbidity and mortality. Thus, despite the low prevalence of ACC in patients with NAT <40 mm with low potential of malignancy, considering the above factors (minimally invasive nature of laparoscopic treatment, emotional burden, and possible poor management of follow-up), the surgical treatment recommendation by the current guidelines seems a reasonable choice for patients, especially for the young. Thus, we presented the adrenal enucleation techniques for such patients for residual adrenal tissue preservation.

Inherent limitations of the current study include the retrospective nature of the study, the absence of a statistical analysis and the small sample size. Furthermore, a prospective randomized controlled study is needed to compare the clinical efficacy and complications of enucleation therapy relative to total adrenalectomy. In addition, the strategy for avoiding ACC and the beneficial evidence of the remnant adrenal tissue should be optimized in future studies. Despite these limitations, to our knowledge, this is the first study to specifically describe the enucleation procedures and present the therapeutic outcomes of the laparoscopic enucleation adrenalectomy for 20–40 mm NAT with low potential of malignancy.

## Conclusions

In this study, laparoscopic retroperitoneoscopic enucleation adrenalectomy is presented to be a feasible and safe technique in the treatment of patients with 20–40 mm NAT. In our opinion, it is a viable choice for such patients who express preference for resection and whose tumors showcase imaging characteristics indicative of low potential

of malignancy.

## Acknowledgments

*Funding:* This study was supported by Capital's Funds for Health Improvement and Research (No. 2020-2-2015 to T.W.O.) and Beijing Municipal Administration of Hospitals Clinical Medicine Development of Special Funding (No. XMLX201829 to H.Y.).

## Footnote

*Reporting Checklist:* The authors have completed the SUPER and STROBE reporting checklists. Available at <https://tau.amegroups.com/article/view/10.21037/tau-23-54/rc>

*Peer Review File:* Available at <https://tau.amegroups.com/article/view/10.21037/tau-23-54/prf>

*Conflicts of Interest:* All authors have completed the ICMJE uniform disclosure form (available at <https://tau.amegroups.com/article/view/10.21037/tau-23-54/coif>). The authors have no conflicts of interest to declare.

*Ethical Statement:* The authors are accountable for all aspects of the work in ensuring that questions related to the accuracy or integrity of any part of the work are appropriately investigated and resolved. The study was conducted in accordance with the Declaration of Helsinki (as revised in 2013). The study was approved by institutional ethics board of Xuanwu Hospital Capital Medical University (No. 2021145) and informed consent was obtained from the patients for publication of this surgical technique and accompanying images and video.

*Open Access Statement:* This is an Open Access article distributed in accordance with the Creative Commons Attribution-NonCommercial-NoDerivs 4.0 International License (CC BY-NC-ND 4.0), which permits the non-commercial replication and distribution of the article with the strict proviso that no changes or edits are made and the original work is properly cited (including links to both the formal publication through the relevant DOI and the license). See: <https://creativecommons.org/licenses/by-nc-nd/4.0/>.

## References

1. Ebbehøj A, Li D, Kaur RJ, et al. Epidemiology of



- adrenal tumours in Olmsted County, Minnesota, USA: a population-based cohort study. *Lancet Diabetes Endocrinol* 2020;8:894-902.
2. Yilmaz N, Avsar E, Tazegul G, et al. Clinical Characteristics and Follow-Up Results of Adrenal Incidentaloma. *Exp Clin Endocrinol Diabetes* 2021;129:349-56.
  3. Patrova J, Jarocka I, Wahrenberg H, et al. CLinical outcomes in adrenal incidentaloma: experience from one center. *Endocr Pract* 2015;21:870-7.
  4. Jing Y, Hu J, Luo R, et al. Prevalence and Characteristics of Adrenal Tumors in an Unselected Screening Population : A Cross-Sectional Study. *Ann Intern Med* 2022;175:1383-91.
  5. Yip L, Duh QY, Wachtel H, et al. American Association of Endocrine Surgeons Guidelines for Adrenalectomy: Executive Summary. *JAMA Surg* 2022;157:870-7.
  6. Lee JM, Kim MK, Ko SH, et al. Clinical Guidelines for the Management of Adrenal Incidentaloma. *Endocrinol Metab (Seoul)* 2017;32:200-18.
  7. Fassnacht M, Dekkers OM, Else T, et al. European Society of Endocrinology Clinical Practice Guidelines on the management of adrenocortical carcinoma in adults, in collaboration with the European Network for the Study of Adrenal Tumors. *Eur J Endocrinol* 2018;179:G1-G46.
  8. Yanase T, Oki Y, Katabami T, et al. New diagnostic criteria of adrenal subclinical Cushing's syndrome: opinion from the Japan Endocrine Society. *Endocr J* 2018;65:383-93.
  9. Castinetti F, Qi XP, Walz MK, et al. Outcomes of adrenal-sparing surgery or total adrenalectomy in pheochromocytoma associated with multiple endocrine neoplasia type 2: an international retrospective population-based study. *Lancet Oncol* 2014;15:648-55.
  10. Nagaraja V, Eslick GD, Edirimanne S. Recurrence and functional outcomes of partial adrenalectomy: a systematic review and meta-analysis. *Int J Surg* 2015;16:7-13.
  11. Nakada T, Kubota Y, Sasagawa I, et al. Therapeutic outcome of primary aldosteronism: adrenalectomy versus enucleation of aldosterone-producing adenoma. *J Urol* 1995;153:1775-80.
  12. Flammia RS, Anceschi U, Tufano A, et al. Minimally Invasive Partial vs. Total Adrenalectomy for the Treatment of Unilateral Primary Aldosteronism: A Systematic Review and Meta-Analysis. *J Clin Med* 2022;11:1263.
  13. Bourdeau I, El Ghorayeb N, Gagnon N, et al. MANAGEMENT OF ENDOCRINE DISEASE: Differential diagnosis, investigation and therapy of bilateral adrenal incidentalomas. *Eur J Endocrinol* 2018;179:R57-67.
  14. Chiu A, Vargas-Pinto S, Abou-Azar S, et al. Contemporary Experience of Posterior Retroperitoneoscopic Adrenalectomy in the US. *J Am Coll Surg* 2021;232:815-21.
  15. Madani A, Lee JA. Surgical Approaches to the Adrenal Gland. *Surg Clin North Am* 2019;99:773-91.
  16. Funder JW, Carey RM, Mantero F, et al. The Management of Primary Aldosteronism: Case Detection, Diagnosis, and Treatment: An Endocrine Society Clinical Practice Guideline. *J Clin Endocrinol Metab* 2016;101:1889-916.
  17. Cyranska-Chyrek E, Szczepanek-Parulska E, Olejarz M, et al. Malignancy Risk and Hormonal Activity of Adrenal Incidentalomas in a Large Cohort of Patients from a Single Tertiary Reference Center. *Int J Environ Res Public Health* 2019;16:1872.
  18. Bancos I, Taylor AE, Chortis V, et al. Urine steroid metabolomics for the differential diagnosis of adrenal incidentalomas in the EURINE-ACT study: a prospective test validation study. *Lancet Diabetes Endocrinol* 2020;8:773-81.
  19. Chomsky-Higgins K, Seib C, Rochefort H, et al. Less is more: cost-effectiveness analysis of surveillance strategies for small, nonfunctional, radiographically benign adrenal incidentalomas. *Surgery* 2018;163:197-204.
  20. Bai S, Yao Z, Zhu X, et al. Comparison of transperitoneal laparoscopic versus open adrenalectomy for large pheochromocytoma: A retrospective propensity score-matched cohort study. *Int J Surg* 2019;61:26-32.
  21. Miron A, Giulea C, Nădrăgea M, et al. Laparoscopic Partial Adrenalectomy. *Chirurgia (Bucur)* 2017;112:77-81.
  22. Roukounakis N, Dimas S, Kafetzis I, et al. Is preservation of the adrenal vein mandatory in laparoscopic adrenal-sparing surgery? *JSLs* 2007;11:215-8.
  23. Gupta GN, Benson JS, Ross MJ, et al. Perioperative, functional, and oncologic outcomes of partial adrenalectomy for multiple ipsilateral pheochromocytomas. *J Endourol* 2014;28:112-6.
  24. Kok KY, Yapp SK. Laparoscopic adrenal-sparing surgery for primary hyperaldosteronism due to aldosterone-producing adenoma. *Surg Endosc* 2002;16:108-11.
  25. Wang TS, Cheung K, Roman SA, et al. A cost-effectiveness analysis of adrenalectomy for nonfunctional adrenal incidentalomas: is there a size threshold for resection? *Surgery* 2012;152:1125-32.
  26. Pędziwiatr M, Natkaniec M, Kisielewski M, et al. Adrenal

incidentalomas: should we operate on small tumors in the era of laparoscopy? *Int J Endocrinol* 2014;2014:658483.

27. Muth A, Taft C, Hammarstedt L, et al. Patient-reported

impacts of a conservative management programme for the clinically inapparent adrenal mass. *Endocrine* 2013;44:228-36.

**Cite this article as:** Yan H, Cao G, Cui X, Wu JT, Ou TW, Wang Q, Cui B, Gao W, Jia CS, Xu JJ. Retroperitoneoscopic enucleation adrenalectomy: a viable surgical option for small nonsecreting adrenal tumors with low potential of malignancy. *Transl Androl Urol* 2023;12(11):1713-1722. doi: 10.21037/tau-23-54