

Exposed Artificial Plate Covered With Perifascial Areolar Tissue as a Nonvascularized Graft

Tomoyuki Ito, MD*
 Satoshi Akazawa, MD*
 Yuichi Ichikawa, MD*
 Yusuke Yamamoto, MD*
 Shohei Aoyama, MD*
 Tomoki Kiuchi, MD*
 Junichi Nakao, MD*
 Tetsuro Onitsuka, MD†
 Jun Araki, MD*
 Masahiro Nakagawa, MD*

Summary: Perifascial areolar tissue (PAT) is a loose connective tissue on deep fascia, such as on the groin, thigh, or temporal region, which has abundant vascular plexus and mesenchymal stem cells. Nonvascularized PAT grafts can survive even on hypovascular wound beds. Therefore, PAT grafting is a possible alternative to conventional flap surgery to cover exposed bone or artifacts. In this article, we describe 2 cases of PAT grafting for the treatment of skin ulcers with exposed bone and artificial plate after mandible reconstruction. After negative-pressure wound therapy, PAT was used to covering exposed artificial plate for both cases, and a skin graft onto the PAT graft was performed in 1 case. The ulcers improved in both cases without recurrence. The gold-standard treatment of intractable ulcers and fistulas with an exposed tendon, bone, or artifact is coverage by a well-vascularized skin flap. However, PAT grafting has advantages in similar situations, occasionally together with skin grafting and/or negative-pressure wound therapy, because it is technically simple and less invasive. (*Plast Reconstr Surg Glob Open* 2019;7:e2109; doi: 10.1097/GOX.0000000000002109; Published online 5 February 2019.)

Perifascial areolar tissue (PAT), which is located between the adipofascial layer and the deep fascia, has been referred to as fascia innominate, Gallaudet's fascia, or the deepest layer of Scarpa's fascia in the lower abdomen.¹ In 2003, Kouraba et al.² reported that PAT grafting could cover tissue defects with exposed tendon and bone. PAT grafting can revascularize wounds with insufficient blood circulation, fill hypovascular tissue defects, and promote granulation to provide a foundation for a skin graft or epithelialization.

In this article, we describe 2 cases of PAT grafting for the treatment of skin ulcers with exposed bone and artificial plate after mandible reconstruction.

CASE REPORTS

Case 1

A 67-year-old man had complained of gum swelling and tongue numbness for 3 years. He was diagnosed with sublingual gland cancer (T4aN0M0, stage IVA). He under-

went segmental mandibulectomy for cancer resection and reconstruction of anterolateral thigh and left fibula with a reconstruction plate. Subsequently, partial necrosis was observed in the anterolateral thigh flap. The necrotic tissue was debrided, and the transplanted fibula and reconstruction plate were exposed. Negative-pressure wound therapy (NPWT) was used to enhance the wound healing from the 30th to the 45th day after the first surgery. The cervical wound was successfully closed by NPWT, but the transplanted fibula and reconstruction plate were still exposed. Therefore, as a second operation, a PAT graft measuring 6×7 cm was harvested from the right inguinal region and grafted on the raw surface including exposed bone and artifact. Even though the neck and mandible were treated with total postoperative irradiation of 60 Gy, the wound finally healed without any infection or ulcer recurrence.

Case 2

A 77-year-old man with diabetes mellitus complained of gum swelling and was diagnosed with left lower gingival cancer (T4aN2bM0, stage IVA). He underwent segmental mandibulectomy for cancer resection and reconstruction using a left free fibula flap with a reconstruction plate. After surgery, the wound became infected and the neck skin was partially necrotized. The necrotic tissue was debrided, and reconstruction plate was exposed. NPWT was used from the 25th to the 46th day after the first surgery. Healthy granulation occurred, but the transplanted fibula and reconstruction plate were still exposed (Fig. 1). Therefore,

*From the *Division of Plastic and Reconstructive Surgery, Shizuoka Cancer Center Hospital, Shizuoka, Japan; and †Division of Head and Neck Surgery, Shizuoka Cancer Center Hospital, Shizuoka, Japan.*

Received for publication September 12, 2018; accepted November 27, 2018.

Copyright © 2019 The Authors. Published by Wolters Kluwer Health, Inc. on behalf of The American Society of Plastic Surgeons. This is an open-access article distributed under the terms of the Creative Commons Attribution-Non Commercial-No Derivatives License 4.0 (CCBY-NC-ND), where it is permissible to download and share the work provided it is properly cited. The work cannot be changed in any way or used commercially without permission from the journal.

DOI: 10.1097/GOX.0000000000002109

Disclosure: The authors have no financial interest to declare in relation to the content of this article. The Article Processing Charge was paid for by the Shizuoka Cancer Center Hospital.

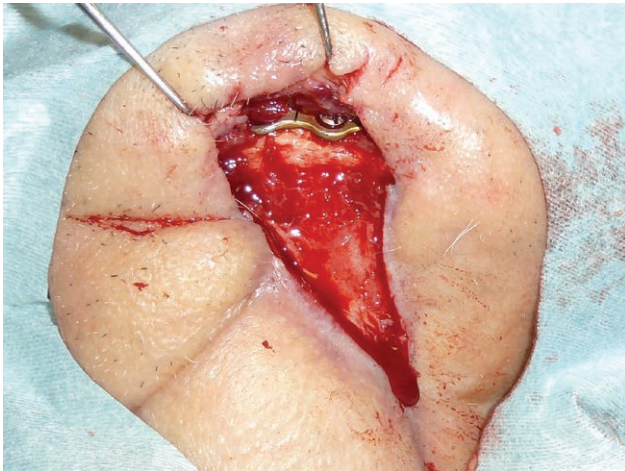


Fig. 1. Case 2 (77-year-old man): the transplanted fibula and reconstruction plate were exposed.

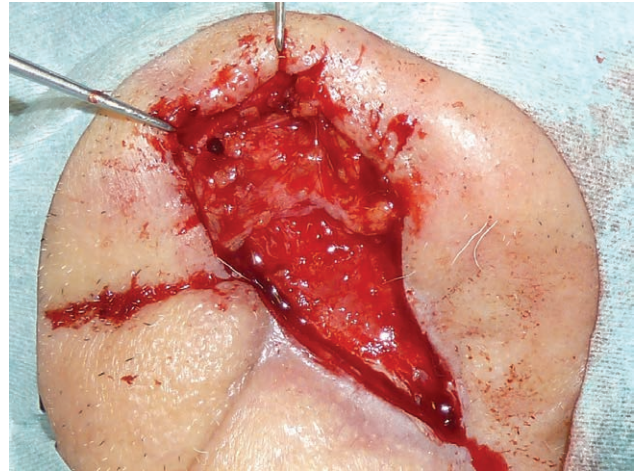


Fig. 3. The PAT graft was applied to cover the exposed bone and artifact.

as a second operation, a split-thickness skin graft measuring 2.5×6cm and a PAT graft measuring 4×4cm were harvested from the left inguinal region (Fig. 2). The PAT graft was applied to cover the exposed bone and artifact (Fig. 3), and then the skin graft was applied onto the PAT graft. Even though the neck was treated with total postoperative irradiation of 66 Gy, the skin graft on the PAT graft completely survived and the wound eventually healed without any infection or ulcer recurrence (Fig. 4).

DISCUSSION

In 2003, Kouraba et al.² reported that PAT grafting could cover tissue defects with exposed bone. Since then, PAT grafting has been applied to cover tissue defects after head and neck cancer resections, dead space, cerebrospinal fluid leakage after brain tumor resection, and vascular leakage as a sealing device.³⁻⁵ Nakajima et al.⁶⁻⁸ reported that the deep layer of the adipofascial system was formed by a mobile structure known as the lubricant adipofascial system, which is rich in blood vessels and mesenchymal

stem cells. After PAT grafting on tissue defects, the vascular network in the PAT promotes vascularization to the wound bed. Because the PAT has an abundance of mesenchymal stem cells, it promotes successful engraftment on the wound bed as granulation tissue.⁹

In surgery, about 5 cm skin incision is made along the inguinal ligament or in the middle of femoral greater trochanter and fibular head. The PAT is found between the subcutaneous fat and the deep fascia after separating the subcutaneous fat bluntly with muscle retractors. The PAT is harvested above the deep fascia sharply with a scalpel according to the size of the tissue defect. The maximum size of successful PAT graft is still unknown. It seems to depend strongly on surrounding tissue. Further evidence should be accumulated on wider wound bed.

In our cases, we debrided necrotized or infected tissue after the first reconstructive surgery, and then applied NPWT to prepare a wound bed. However, the granulation tissue was insufficient to cover the entire wound surface because the bone and artifact were still exposed. The wounds were hypovascular or even avascular, so the promotion of angiogenesis and granulation was difficult. Therefore, we

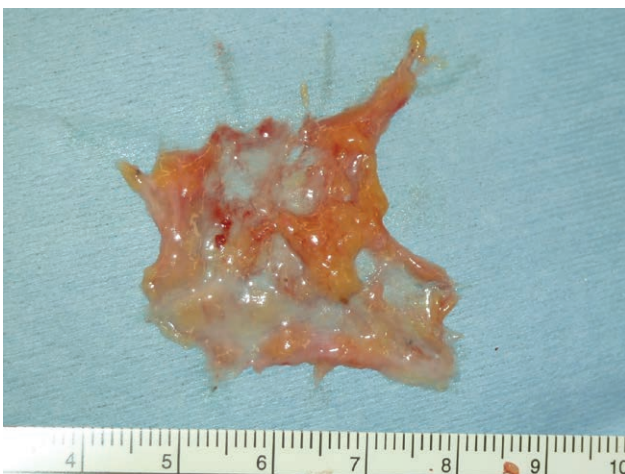

Fig. 2. A PAT graft measuring 4×4cm was harvested from the left inguinal region.

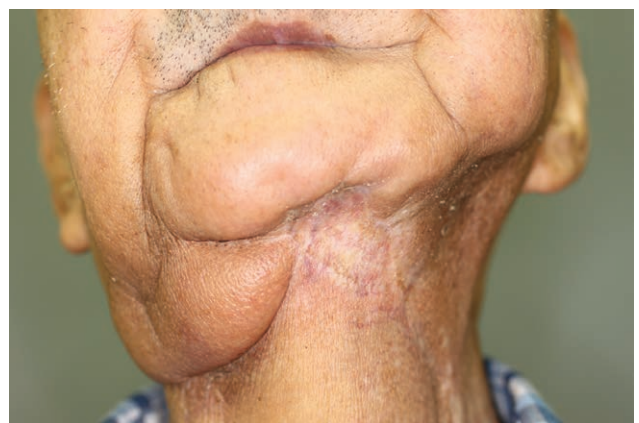

Fig. 4. The wound healed without any infection or ulcer recurrence on 6 months after the first surgery.

placed a PAT graft to cover the exposed bone and artifacts and to fill the soft-tissue defect. In case 1, even though the skin was not completely closed after PAT grafting, the wound eventually healed without any infection or ulcer recurrence. Surprisingly, in case 2, not only a PAT graft but also a skin graft was successfully engrafted on the wound with exposed bone and artifact. It seemed that the PAT graft turned into granulation tissue on the hypovascular or avascular wound bed and promoted vascularization to the skin graft, which is referred to as the bridge phenomenon.

Certain therapeutic options have been considered to treat irradiated hypovascular wounds with exposed bone or artifacts as in our cases. It is not usually possible to use local flaps because the surrounding area is also irradiated. A pedicled or free flap is well vascularized, but the surgery is technically complex, costly, and invasive. In contrast, our method is technically simple and less invasive because the PAT graft can be harvested from the external oblique fascia or the femoral fascia under local anesthesia. This approach has great potential for treating various kinds of wounds, ulcers, and tissue defects.

CONCLUSIONS

Exposed artificial plates were covered with PAT as a nonvascularized graft after mandible reconstruction in our 2 clinical cases. This method is considered to be a versatile option for the management of hypovascular or avascular wound; however, further evidence should be accumulated on wider wound bed.

Jun Araki MD, PhD/Masahiro Nakagawa, MD, PhD
 Division of Plastic and Reconstructive Surgery
 Shizuoka Cancer Center
 1007, Shimonagakubo, Nagaizumi-cho, Shunto-gun
 Shizuoka 411-8777, Japan
 E-mail: ja980079@yahoo.co.jp

ACKNOWLEDGMENTS

The authors are thankful to Keita Inoue, Hayato Nagashima, Masanori Mori, Kou Fujisawa, Masato Nagaoka, and Yoshiyuki Iida for their technical help.

REFERENCES

1. Carmine C. Muscles of abdomen. In: Goss CM, ed. *Gray's Anatomy*. 30th ed. Philadelphia, Pa.: Churchill Livingstone; 1985:819-871.
2. Kouraba S, Takeuchi A, Honda K, et al. Perifascial areolar tissue graft: novel autologous graft material and its clinical application for coverage of exposed bone and tendon. *AHZ J Surg*. 2003;73:260.
3. Koizumi T, Nakagawa M, Nagamatsu S, et al. Perifascial areolar tissue graft as a nonvascularized alternative to flaps. *Plast Reconstr Surg*. 2010;126:182e-183e.
4. Koizumi T, Nakagawa M, Nagamatsu S, et al. The versatile perifascial areolar tissue graft: adaptability to a variety of defects. *J Plast Surg Hand Surg*. 2013;47:276-280.
5. Hayashi N, Mitsuya K, Gorai K, et al. A novel graft material for preventing cerebrospinal fluid leakage in skull base reconstruction: technical note of perifascial areolar tissue. *J Neurol Surg B Skull Base*. 2015;76:7-11.
6. Nakajima H, Imanishi N, Minabe T, et al. Anatomical study of subcutaneous adipofascial tissue: a concept of the protective adipofascial system (PAFS) and lubricant adipofascial system (LAFS). *Scand J Plast Reconstr Surg Hand Surg*. 2004;38:261-266.
7. Nakajima H, Imanishi N, Minabe T, et al. Three-dimensional reconstruction of cutaneous arteries of the back by computer graphic imaging. *Plast Reconstr Surg*. 1997;100:381-389.
8. Nakajima H, Minabe T, Imanishi N. Three-dimensional analysis and classification of arteries in the skin and subcutaneous adipofascial tissue by computer graphics imaging. *Plast Reconstr Surg*. 1998;102:748-760.
9. Hayashi A, Komoto M, Tanaka R, et al. The availability of perifascial areolar tissue graft for deep cutaneous ulcer coverage. *J Plast Reconstr Aesthet Surg*. 2015;68:1743-1749.