



Since January 2020 Elsevier has created a COVID-19 resource centre with free information in English and Mandarin on the novel coronavirus COVID-19. The COVID-19 resource centre is hosted on Elsevier Connect, the company's public news and information website.

Elsevier hereby grants permission to make all its COVID-19-related research that is available on the COVID-19 resource centre - including this research content - immediately available in PubMed Central and other publicly funded repositories, such as the WHO COVID database with rights for unrestricted research re-use and analyses in any form or by any means with acknowledgement of the original source. These permissions are granted for free by Elsevier for as long as the COVID-19 resource centre remains active.



Vaccine-induced immune thrombotic thrombocytopenia and patients with cancer

Jean M. Connors^{a,*}, Toshiaki Iba^b

^a Hematology Division, Brigham and Women's Hospital, Dana Farber Cancer Institute, 75 Francis Street, Boston, MA 02115, United States of America

^b Department of Emergency and Disaster Medicine, Juntendo University Graduate School of Medicine, Tokyo, Japan

ARTICLE INFO

Keywords:

SARS-CoV-2 vaccines
Vaccine-induced thrombotic thrombocytopenia syndrome (VITT)
Cerebral venous sinus thrombosis
VITT diagnosis
VITT treatment

ABSTRACT

Vaccines to combat SARS-CoV-2 infection and the COVID-19 pandemic were quickly developed due to significant and combined efforts by the scientific community, government agencies, and private sector pharmaceutical and biotechnology companies. Following vaccine development, which took less than a year to accomplish, randomized placebo controlled clinical trials enrolled almost 100,000 people, demonstrating efficacy and no major safety signals. Vaccination programs were started, but shortly thereafter a small number of patients with a constellation of findings including thrombosis in unusual locations, thrombocytopenia, elevated D-dimer and often low fibrinogen led another intense and concentrated scientific effort to understand this syndrome. It was recognized that this occurred within a short time following administration of adenoviral vector SARS-CoV-2 vaccines. Critical to the rapid understanding of this syndrome was prompt communication among clinicians and scientists and exchange of knowledge. Now known as vaccine-induced immune thrombotic thrombocytopenia syndrome (VITT), progress has been made in understanding the pathophysiology of the syndrome, with the development of diagnostic criteria, and most importantly therapeutic strategies needed to effectively treat this rare complication of adenoviral vector vaccination. This review will focus on the current understanding of the pathophysiology of VITT, the findings that affected patients present with, and the rationale for therapies, including for patients with cancer, as prompt recognition, diagnosis, and treatment of this syndrome has resulted in a dramatic decrease in associated mortality.

1. Introduction

Although it has been two years since SARS-CoV-2 was first identified as a new virus capable of infecting humans and resulting in a disorder known as COVID-19, the world is still grappling with controlling this virus, with over 388 million reported cases and over 5.7 million deaths attributable to COVID-19 [1]. With emerging variants, initially the Delta variant and now the Omicron variant that are more readily spread [2,3], containing the virus has proved to be more difficult than expected. In a tremendous cooperative effort between government agencies and private pharmaceutical and biotechnology companies, vaccines against SARS-CoV-2 were rapidly developed, tested, and under emergency use

authorization administered to citizens in many countries around the world to combat the spread of COVID-19.

The vaccines used different strategies to deliver the antigenic substance. All used genetic material that code for the SARS-CoV-2 spike protein but differ in mode of delivery. Of the four vaccines that were the first to be available, two are mRNA containing vaccines that package mRNA coding for the spike protein in a lipid solution (BNT162b2 and mRNA-1273 SARS-CoV-2 vaccines), while two other vaccines use DNA that codes for the spike protein packaged in an adenoviral vector (ChAdOx1 nCov-19, and Ad26.COV2.S vaccines). Randomized blinded placebo-controlled vaccine trials were launched quickly and enrolled over 97,805 participants. Excellent efficacy was demonstrated with all

Abbreviations: CVST, cerebral venous sinus thrombosis; CBC, complete blood count; COVID-19, Coronavirus disease 2019; DVT, deep vein thrombosis; ELISA, enzyme linked immunosorbent assay; HIT, heparin induced thrombocytopenia; ICH, intracranial hemorrhage; IV IgG, intravenous immunoglobulin G; NETs, neutrophil, extracellular traps; PE, pulmonary embolus; PF4, platelet factor 4; UFH, unfractionated heparin; VITT, vaccine-induced immune thrombotic thrombocytopenia syndrome.

This article is published as part of a supplement sponsored by the International Conference on Thrombosis and Hemostasis Issues in Cancer.

* Corresponding author.

E-mail addresses: jconnors@bwh.harvard.edu (J.M. Connors), toshiiba@juntendo.ac.jp (T. Iba).

<https://doi.org/10.1016/j.thromres.2022.02.009>

Received 11 November 2021; Received in revised form 7 February 2022; Accepted 8 February 2022

Available online 26 May 2022

0049-3848/© 2022 Elsevier Ltd. All rights reserved.

four vaccines, with all achieving high levels of anti-spike protein antibodies in those receiving active vaccine compared to placebo, with no major safety signals [4–7].

These vaccines demonstrated the ability to protect from infection with SARS-CoV-2 as well as decreased the severity of COVID-19 if infection occurred [8,9]. However, shortly after the roll out of the ChAdOx1 nCoV-19 adenoviral vector vaccine in Europe, and subsequently the Ad26.COV2-S in the US, cases of patients presenting with unusual sites of thrombosis in the cerebral venous sinuses (CVST) or splanchnic vessels, accompanied by surprising clinical and lab findings, emerged. The most important observation was the short duration of time from vaccination, but findings also included thrombocytopenia, elevated D-dimer and low fibrinogen. Some patients had marked worsening of clinical status with increased thrombosis with the use of UFH leading observant clinicians to note the similarity with heparin induced thrombocytopenia (HIT). Identification of these early findings and close and rapid communications between clinicians caring for these patients and basic scientists routinely working on HIT led to the identification of a new syndrome now known as “vaccine-induced immune thrombotic thrombocytopenia” or VITT; sometimes referred to as thrombotic thrombocytopenia syndrome (TTS), the term VITT more accurately reflects the underlying pathophysiology of this syndrome that is distinct from other syndromes associated with thrombosis and thrombocytopenia.

COVID-19 has presented even more challenges for patients with cancer. Initial anxiety about increased susceptibility to SARS-CoV-2 infection, as well as increased morbidity and mortality, led to changes in the delivery of cancer care including alteration of schedule and type of anti-cancer treatments to try to avoid immunosuppression [10]. With the availability of vaccines, similar concerns about efficacy in the often immunocompromised cancer patients arose, as patients with cancer were mostly excluded from vaccine trials. Real world data [11,12] have found that cancer patients have a lower response to vaccination. Although the suppressed immune activity in cancer patients may be protective against developing VITT, we do know that patients with cancer can develop HIT [13]. Cancer patients were in the first group of patients to be vaccinated in the US; as mRNA vaccines were the first available fewer patients with cancer likely received an adenoviral vector vaccine. This manuscript will review what is known today about the pathophysiology of VITT in general, the use of clinical findings and appropriate lab tests to make the diagnosis of VITT, and treatment of patients with suspected or confirmed VITT. Application of existing knowledge to patients with cancer will also be discussed.

2. Pathophysiology

The similarity of findings of thrombocytopenia, thrombosis, and apparent worsening of thrombosis with the use of unfractionated heparin (UFH) as with cases of HIT led to the use of platelet factor 4 (PF4) tests in the first few reported cases. Results of the PF4 ELISA tests were surprisingly positive in these patients despite lack of prior exposure to heparin, with higher results than typically seen with HIT. Similarity to auto-immune HIT, a rare occurrence, was made as none of these patients had had prior heparin exposure [9]. Excellent reviews on HIT and autoimmune HIT have been published but reviewing the pathophysiology of HIT will aid understanding what is known about the mechanisms of developing VITT [14,15].

HIT occurs when a patient makes an IgG antibody to a neoantigen on PF4 that is exposed when highly positively charged PF4 tetramers bind to highly negatively charged heparin. PF4, released from platelet alpha granules following platelet activation and belonging to the chemokine CXC family of small molecules with roles in inflammation and wound repair, functions to neutralize heparins at the vascular endothelial surface allowing coagulation to proceed [16]. The longer the UFH molecule, the more PF4 molecules it can bind which then bind anti-PF4 antibodies in close proximity along the UFH polymer. These bound IgG

antibodies can then bind to FCyRIIa receptors on platelets; clustering of IgG-FCyRIIa leads to platelet activation, release of platelet PF4, and ultimately results in thrombosis and the clinical manifestations of HIT. These antibodies can also bind to FCy receptors on granulocytes that participate in thrombosis formation. HIT is associated with 50% mortality if not appropriately treated. In auto-immune HIT, an endogenous polyanion takes the place of UFH, providing the same backbone of a negatively charged long polymer chain for PF4 to bind to, resulting in the exposure of the same neoantigen [9]. It is on the basis of this knowledge that a similar process was suspected in patients with this syndrome who were found to have high positive PF4 ELISA tests [17–20].

Detailed investigations into the appropriate lab tests to diagnose VITT using patient plasma or serum found that standard plate based PF4 ELISA assays identified positive samples whereas rapid immunoassays did not [21]. Platelet activation studies using VITT patient plasma to activate platelets resulting in aggregation were often at first negative, until exogenous PF4 was added to the test. Detailed testing demonstrated that platelet activation by serum from patients with VITT did not require heparin to activate platelets but activity could be blocked by high heparin concentrations. Platelet activation was also inhibited with an anti-FCyRIIa antibody, and could be augmented with PF4 [17,19]. Although very sensitive, these types of tests are primarily available at research or reference labs, as with the serotonin release assay used to diagnose HIT. Variations in the reagents, particularly the addition and type of exogenous PF4, can be critical to the assay function; the gold standard SRA test for HIT performs variably to diagnose VITT based on whether exogenous PF4 is added [17,19]. IgG antibodies were isolated from VITT patient samples and demonstrated binding to PF4 and activation of platelets in the presence of PF4. ELISA assays can be performed even in the setting of treatment. A small number of patients with VITT have been followed with serial PF4 ELISA and platelet activation studies over 11–12 weeks. Findings demonstrate that functional assays become negative in about 90% of patients by this time and although the ELISA titers decreased, results were still positive in the majority of patients [22].

Work from Norway by Holm and colleagues and by others demonstrate that excessive activation of neutrophils occurs in VITT, in addition to platelet activation, and plays a significant role in thrombus development [23,24]. The crosstalk between innate inflammatory responses and activation of coagulation, known as thromboinflammation, appears to play a key role in the development of VITT. The participation of neutrophils and the formation of neutrophil extracellular traps (NETs) has been noted previously in HIT as well as in COVID-19 [25,26]. VITT is first an immune response and not a hypercoagulable state. Specific recipient factors such as ability to control inflammatory or coagulation response may also play a role in the development of VITT. The vaccine components associated with the development of the anti-PF4 antibodies in cases of VITT were first thought to be any one of the constituents of the vaccine itself, including the adenoviral vector, or EDTA, however recent data suggests that the probable polyanion that binds PF4 appears to be an adenovirus viral capsid protein, the hexon protein [24]. Although three cases of VITT have been suspected following mRNA vaccine administration, to date none have had positive lab test results or been otherwise confirmed. Fig. 1 depicts the current proposed pathophysiology of VITT. Other detailed figures and descriptions depicting the pathophysiologic mechanisms involved in auto-immune HIT, HIT, and VITT by Greinacher, Warkentin, Holm, and others are available for review for greater understanding of the similarities and differences between these disorders [14,15,23,27].

3. Clinical assessment and diagnosis

Recognition of VITT is based on clinical findings, radiographic imaging, and laboratory tests. VITT is defined as a syndrome following either of the two COVID-19 adenoviral vector vaccines, with thrombosis,

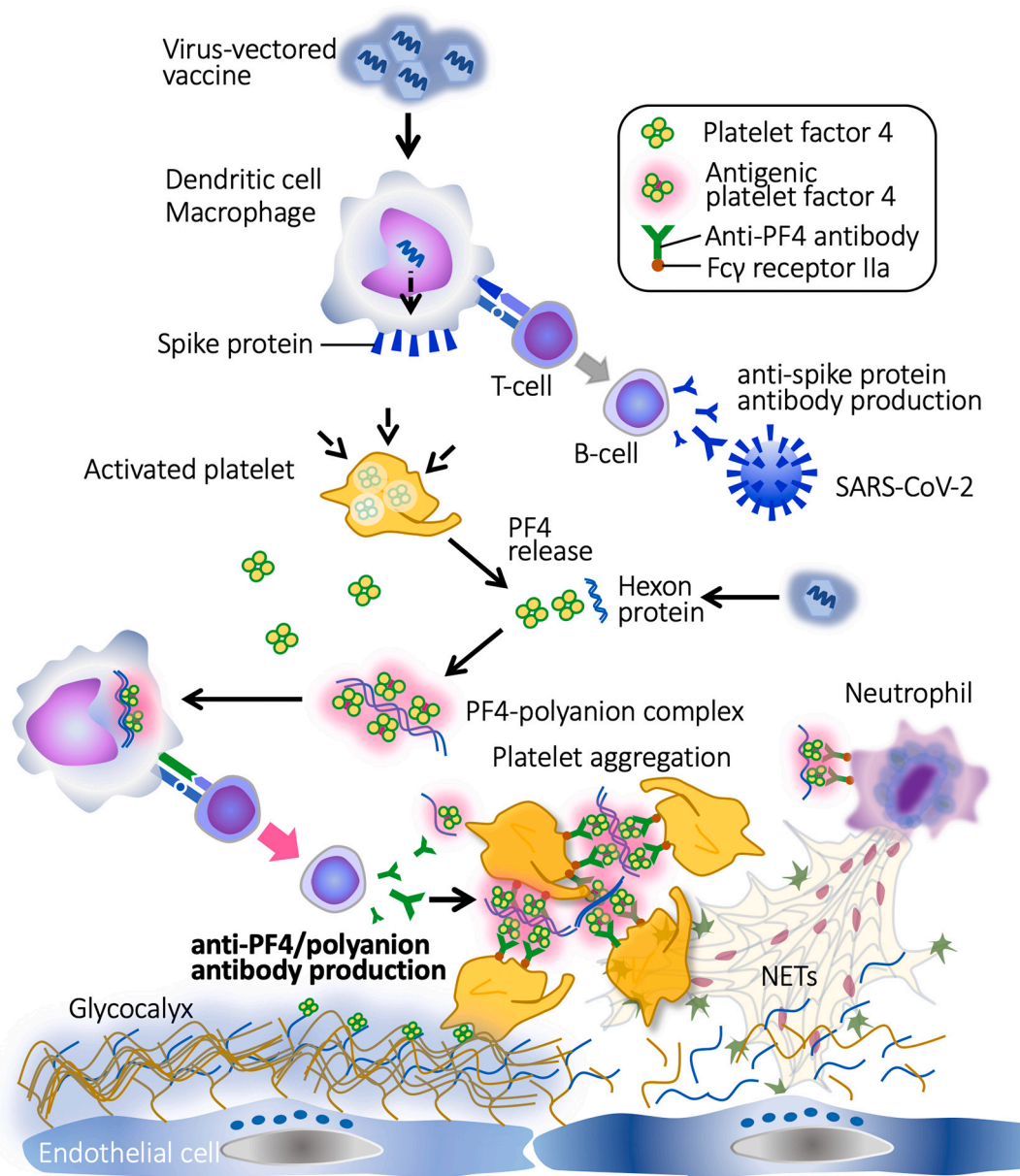


Fig. 1. Proposed mechanism of VITT: Adenoviral vector-based SARS-CoV-2 vaccination results in the release of adenovirus hexon capsid protein in the circulation which binds PF4 present in the blood from platelets that have been activated. The hexon protein/PF4 complex exposes a neoepitope on PF4, as in heparin induced thrombocytopenia (HIT) or autoimmune HIT in which heparin or large endogenous polyanion bind PF4. Antibody directed against this neoepitope is produced which binds the hexon protein/PF4 complex. The hexon protein, like heparin or other polyanions, can bind multiple PF4/antibody complexes which can engage and cluster platelet FcγRIIa receptors, resulting in platelet activation and release of PF4, perpetuating the thrombotic milieu and activating other inflammatory pathways such as formation neutrophil extracellular traps.

thrombocytopenia, elevated D-dimer, and often low fibrinogen, and positive PF4 ELISA. One of the most important clinical factors is timing of symptom onset after vaccination. The symptoms are not the typical flu like symptoms that occur within 24–48 h after receiving many types of vaccines, such as headache, myalgia, low grade fevers or chills. Symptoms of VITT do not appear until 4 to 5 days after vaccination and are usually due to the presence of thrombosis leading to headache and neurologic symptoms if the patient develops a cerebral venous sinus thrombosis (CVST), or abdominal or back pain if splanchnic vein thrombosis, or symptoms associated with pulmonary embolism (PE) or deep vein thrombosis (DVT) [17,18,19,28]. Some patients may develop headache without CVST, or other VTE manifestations, early in the course of development of VITT; these patients have appropriate laboratory findings of elevated D-dimer and positive PF4 ELISA with the

headaches attributed to possible microvascular thrombosis [29]. It is the cases of thrombosis in unusual locations that initially called attention to this syndrome as the index case had CVST. In rapid succession new cases of CVST following the ChAdOx1 nCov-19 and Ad26.COV2-S vaccines were identified. The location of thrombosis in unusual sites is credited with likely early identification of this syndrome, but typical sites of thrombosis such as PE or DVT, or thrombosis in multiple sites also occur. While earliest onset is approximately 5 days, the median has been reported to be 14 days (IQR10,16) [28] in the largest series, with cases identified out to at least 28 days, although some outliers have been diagnosed past 28 days. One case report notes presentation of a woman with bruising and petechiae who was diagnosed with VITT despite the lack of thrombosis on imaging; the use of aspirin to control post vaccine symptoms is likely what prompted early medical attention and early

recognition of VITT by alert clinicians [30].

While the first reported cases from European countries noted that age less than 50 and female sex appeared to be risks factors for developing VITT, in a larger data set only younger age has held up as a risk, with a median age of 48 years albeit with a wide a range from 18 to 79 years. Demographic factors at the time of administration of the ChAdOx1 nCov-19 vaccine were likely responsible for this impression of sex as a predisposition, with young female healthcare workers making up the majority of recipients in the first round of vaccination. In the large UK experience 45% of patients diagnosed with VITT were men [28].

Evaluation of patients with suspected VITT should include symptom directed imaging and laboratory tests including a CBC to check platelet count, D-dimer level, fibrinogen, and if available a PF4 ELISA. Assessment for other causes of thrombotic thrombocytopenia syndromes including thrombotic microangiopathies such as thrombotic thrombocytopenic purpura is critical. Contrast must be used with CT or MR imaging of the head to assess for CVST and the abdomen for splanchnic vein thrombosis. PE, DVT, arterial events, and thrombosis in multiple vascular beds have also been reported and can be assessed based on symptoms. (Table 1) Platelet count should be low, D-dimer level should be significantly elevated even in the absence of thrombosis, and fibrinogen can be normal, low normal or significantly low as in some reported cases in which fibrinogen was less than 100 mg/dl [17,18,19,28].

The UK has developed a set of criteria for diagnosing VITT as definite, probable, possible, and unlikely [28]. The World Health Organization has also established criteria, with major and minor criteria, and classification as Level 1 confirmed, Level 2 probable, and Level 3 possible VITT (see Table 1). A risk prediction score for risk of mortality has also been developed [31]. Based on 49 early cases, 5 variables were found to be associated with mortality including age less than 60 years, platelet count less than 25,000/ul, fibrinogen less than 150 mg/dl, intracranial hemorrhage, and CVST, with the risks additive. The more severely abnormal the lab tests, the higher the risk of death. Further validation of this score is required.

Making a diagnosis of VITT in patients with cancer can be challenging, as many of the criteria can be affected by cancer treatments or the underlying cancer itself. Specifically, platelet count and D-dimer can be affected by chemotherapy, radiotherapy, and even immunotherapy, to mimic VITT with thrombocytopenia and an increased D-dimer—both of which can also be seen in advanced stages of cancer with metastases to the bones. The rates of thrombosis are increased in patients with cancer at baseline, and many types of cancer, particularly GI tract cancers can be associated with splanchnic vein thrombosis. Thrombotic microangiopathies including DIC can also have similar findings as VITT. There is one case report of development of VITT in a patient who was diagnosed with pancreatic cancer following presentation with an

Table 1
Comparison of World Health Organization criteria and United Kingdom case definitions for diagnosis of Vaccine-induced immune thrombotic thrombocytopenia.

	Thrombosis	Thrombocytopenia	PF4 ELISA	D-dimer	Timing
WHO					
Major criteria	Unusual location <ul style="list-style-type: none">• Cerebral vein• Splanchnic vein• Multiple veins	< 50 × 10 ⁹ /L Smear: no clumping	+ OR + functional assay		na
Minor criteria	Common location—imaging confirmed OR Suggestive imaging or clinical findings <ul style="list-style-type: none">• Pulmonary v• Limb vein• Coronary a• Cerebral a• Other arteries/veins	>50 × 10 ⁹ /L – < 150 × 10 ⁹ /L OR >50% decrease from baseline		>4000 FEU	na
Level 1 confirmed	Major or minor	Major or minor	Major	Major	na
Level 1 confirmed	Major	Major	Minor	Minor	na
Level 2 probable	Minor	Major	Minor	Minor	na
Level 2 probable	Major	Minor	Minor	Minor	na
Level 3 possible	Minor	Minor	Minor OR No values	Minor OR no values	na
UK Case Definition					
Definite	Presence of thrombosis	<150 × x 10 ⁹ /L	+	>4000 FEU	Symptom onset 5–30 days post vaccination
Probable	D-dimer significantly elevated but one of the other 4 criteria not met			>4000 FEU	
Probable	Presence of thrombosis	<150 × x 10 ⁹ /L	+	Unknown OR 2000–4000 FEU	Symptom onset 5–30 days post vaccination
Possible	One or two criteria not met			Unknown OR 2000–4000 FEU	
Unlikely	No thrombosis	<150 × x 10 ⁹ /L	+/-	<2000 FEU	
Unlikely (alternative diagnosis more likely)	Thrombosis	>150 × x 10 ⁹ /L	+/-	<2000 FEU	

Abbreviations: PF4, platelet factor 4; ELISA, enzyme linked immunosorbent assay; FEU, fibrinogen equivalent units.

ischemic stroke. Review of the peripheral smear showing absence of schistocytes and a positive PF4 ELISA lead to a diagnosis of VITT [32] in this case 12 days following administration of mRNA-1273 (Moderna) vaccination. It is unclear whether this patient who died after aggressive support did in fact have VITT as pancreatic cancer itself could have resulted in the ischemic stroke, the PF4 ELISA was low titer compared to that found in other reports [17,18,19,20], and suspected cases of VITT following mRNA vaccines have not been confirmed by platelet activation assays.

4. Management

Heightened suspicion for the diagnosis with onset of symptoms at an appropriate time following adenoviral vector vaccination is important, as early recognition of the VITT syndrome and early institution of appropriate treatment appears to be responsible for decreasing the mortality rate. Mortality with the first reported cases in April 2021 was over 40%; this decreased to approximately 20% by the end of the summer 2021, with the rate of fatal cases at 5% (8/158) to date in Australia after an extensive education campaign on recognition, diagnosis, and treatment [33].

Management of VITT is modeled after management of HIT, in which the important first steps are to avoid heparin anticoagulants and platelet transfusions. Heparin perpetuates the pathophysiology of HIT and platelet transfusions just add more PF4 and thrombotic substrate. Whether avoidance of heparin is mandatory is unclear as it has been found that the antibody that triggers VITT binds to the same site on PF4 as heparin, ostensibly making simultaneous binding of both unlikely. However some patients with VITT do have antibodies that can cross react with heparin/PF4 complexes and the sophisticated testing required to determine this is not widely available [33]. Given the high morbidity and mortality of VITT and the uncertainty with the use of heparin, non-heparin anticoagulants should be used if available [33]. Non-heparin anticoagulants such as parenteral direct thrombin inhibitors (argatroban, bivalirudin), fondaparinux a recombinant molecule which is the short 5 pentasaccharide sequence of heparin that binds antithrombin but has been shown to be relatively safe in HIT [34], or direct oral anticoagulants including the direct thrombin inhibitor dabigatran or the Xa inhibitors (apixaban, rivaroxaban, edoxaban), can be used depending on the severity of illness of the patient, renal function, and other factors. As with HIT, anticoagulation should be given despite thrombocytopenia, although with careful supervision in cases of significant bleeding such as intracranial hemorrhage (ICH).

In many countries, non-heparin anticoagulants such as parenteral direct thrombin inhibitors or oral Xa inhibitors are not available. As above, the VITT antibody binds within the same area on PF4 that heparin binds, making simultaneous binding of both mutually exclusive, and thus heparin should not contribute to the pathophysiology of HIT. Expert consensus panels suggest that heparin be given if no alternative anticoagulants are available to shut off the intense thrombin generation in VITT, as this is safer than no anticoagulation [33].

High dose intravenous immunoglobulin G (IV IgG) of 1 g per kilogram per day for two days has been used with success as treatment for both auto-immune HIT and HIT, and so is recommended for the treatment of VITT although data for efficacy of IgG use alone in VITT are lacking [35–37]. IgG interferes with the activation of platelets by the VITT antibody/PF4 complexes and will down regulate immune activity and subsequent antibody production. Similarly, the use of steroids to interfere with immunologic response has been suggested, especially if IV IgG is not available, and in severe cases plasmapheresis to remove the VITT antibody has been reported [33,38]. A summary of management strategies appears in Table 2. Many guidelines have been developed with treatment algorithms for the management of VITT. (see Appendix) Management of VITT in patients with cancer should not differ from the management in patients without cancer. VITT is an aberrant immunologic response to vaccination. The recommended VITT treatment

Table 2

Vaccine-induced immune thrombotic thrombocytopenia syndrome: treatment

-
1. Confirmed or probable diagnosis: WHO Level 1 or 2; UK definite, probable, possible
 - Non-heparin anticoagulant
 - Argatroban
 - Bivalirudin
 - Apixaban
 - Rivaroxaban
 - Edoxaban
 - IV IgG: 1 g/kg/day x 2 doses
 - Avoid platelet transfusions
 - Severe cases
 - Steroids
 - Plasma exchange
 2. Possible Diagnosis: WHO Level 3 or UK unlikely
 - No thrombosis BUT appropriate timing, thrombocytopenia AND very high or rising D-dimer OR positive PF4 ELISA: may be early presentation of VITT, monitor closely or use IV IgG and consider empiric anticoagulation
 - Thrombosis but no other findings; unlikely to be VITT but advise avoidance of heparin
 - Thrombocytopenia but no other findings: unlikely to be VITT more likely to be immune mediated thrombocytopenia (ITP)
-

strategies will not harm patients with cancer but a correct diagnosis must be made.

Once the acute treatment of VITT has been established, with increase in platelet count, stabilization of other coagulation parameters, and continued anticoagulation, current consensus is to treat the thromboses as a provoked event with a minimum of three months of therapeutic dose anticoagulation. In 14 of 15 patients followed for more than 12 weeks, the median time for PF4 dependent platelet activation assays to become negative was 12 weeks, although PF4 ELISA positivity persisted longer, as is often the case with HIT [39,40]. What this means for treatment is unclear, but a conservative approach is warranted, with continued anticoagulation determined by individual patient thrombosis risk factors. Whether these patients are at increased risk for HIT and avoid heparin in the future is currently unknown. Long term follow-up data are needed to identify best practice.

Vaccination is the best defense against SARS-CoV-2 infection. Even if breakthrough infection occurs, vaccinated patients experience less associated morbidity and mortality [41]. Patients with a history of VITT are still at risk for COVID-19. Although data are limited, reports of subsequent vaccination with mRNA vaccine in five patients following a diagnosis of VITT did not lead to recurrence [22]. A more recent publication from the UK that evaluated 40 patients with VITT reported that none developed recurrent VITT or other adverse reactions, following subsequent vaccination with mRNA vaccines [42]. Primary vaccination in the USA, like Canada and the UK, for the majority of people will now be with the mRNA type vaccines given that the CDC recommends the mRNA vaccine in preference to the Ad26.COV2.S vaccine due to the risk of VITT [43]. As boosters are now recommended, for those who received the Ad26.COV2.S and the ChAdOx1 nCov-19, subsequent immunization against SARS-CoV-2 should be with an mRNA type vaccine. For those that are immunosuppressed including patients with cancer or receiving cancer treatments, a series of three mRNA vaccine doses are recommended at the full dose and not the lower booster dose given after the first two doses due to the decreased efficacy of vaccination in this population. If the first vaccination was with an adenovirus vaccine subsequent use of mRNA vaccines will provide a good response and effective levels of anti-Spike protein antibodies, with no safety signals to date [44]. With data to support an mRNA booster showing improved efficacy against the omicron variant, those with a history of VITT or with cancer should strongly consider mRNA vaccination and boosters in consultation with their medical care team [45].

5. Conclusion

The rapid development and roll-out of vaccines against SARS-CoV-2 is a remarkable feat that has relied on science, technology, and medicine. These vaccines have proven efficacy, have decreased morbidity, and have saved lives. VITT is a rare complication of adenoviral vector vaccines, with variable reported incidences from country to country based on population vaccination strategy, timing of halting use of adenoviral vector vaccines, and ascertainment limitations including recognition of the syndrome with retrospective diagnosis. Recent data from the US noted 54 cases out of 14.1 million administered doses of the Ad26.COV2-S, representing a case rate of 3.8 cases per million doses [43]. The UK reports based on age, found an incidence of 1:100,000 in patients over age 50 years after almost 8 million doses of the ChAdOx1 nCov-19 vaccine, and at least 1:50,000 after 16 million doses in those age less than 50 years [27]. While some countries have halted use of the adenoviral vector vaccines, for many countries in which vaccine options are limited, strategies for administration based on age with heightened surveillance for complications and rapid treatment at the first signs or symptoms of VITT may be necessary to help curtail the SARS-CoV-2 pandemic.

Although VITT is a serious complication of adenoviral vector vaccines with varying incidence from country to country, it is rare; whether patients with cancer can develop VITT is unknown. The complications associated with SARS-CoV-2 infection are more frequent and often even more severe and concerning for patients with cancer. Many countries have issued guidance for differential use of the mRNA and adenoviral vector vaccines based on specific patient characteristics; readers should refer to local guidance from their country to inform practice; representative guidance documents can be found in the see Appendix. Early recognition and diagnosis of VITT with prompt initiation of appropriate treatment including non-heparin anticoagulants, IV IgG, with consideration for use of steroids or plasma exchange, have significantly decreased the mortality associated with this syndrome and are expected to be just as effective in patients with cancer. Over 7 billion doses of vaccine have been administered to date [1]. The continued rapid pace of development of scientific knowledge about COVID-19 and the vaccines against SARS-CoV-2 is needed to ultimately control this devastating pandemic.

Funding

No sources of funding were used for this manuscript.

Declaration of competing interest

JMC reports personal fees for scientific advisory boards and consulting from Abbott, Anthos, Alnylam, Bristol Myers Squibb, Five Prime Therapeutics, Pfizer, Takeda and research funding from CSL Behring. TI has received a research grant from Japan Blood Products Organization and JIMRO.

Appendix A. Supplementary data

Supplementary data to this article can be found online at <https://doi.org/10.1016/j.thromres.2022.02.009>.

References

- <https://coronavirus.jhu.edu/map.html>.
- S.M. Kissler, J.R. Fauver, C. Mack, C.G. Tai, M.I. Breban, A.E. Watkins, R. M. Samant, D.J. Anderson, J. Metti, G. Khullar, R. Baits, D. Salgado, T. Baker, J. T. Dudley, C.E. Mason, D.D. Ho, N.D. Grubaugh, Y.H. Grad, M. MacKay, Viral dynamics of SARS-CoV-2 variants in vaccinated and unvaccinated persons, *N. Engl. J. Med.* 385 (26) (2021) 2489–2491, <https://doi.org/10.1056/NEJM2102507>. Epub 2021 Dec 1.
- V. Kumar, J. Singh, S.E. Hasnain, D. Sundar, Possible link between higher transmissibility of alpha, kappa and delta variants of SARS-CoV-2 and increased structural stability of its spike protein and hACE2 affinity, *Int J Mol Sci.* 22 (17) (2021) 9131, <https://doi.org/10.3390/ijms22179131>.
- P.M. Folegatti, K.J. Ewer, P.K. Aley, B. Angus, S. Becker, S. Belij-Frammerstorfer, D. Bellamy, S. Bibi, M. Bittaye, E.A. Clutterbuck, C. Dold, S.N. Faust, A. Finn, A. L. Flaxman, B. Hallis, P. Heath, D. Jenkin, R. Lazarus, R. Makinson, A. M. Minassian, K.M. Pollock, M. Ramasamy, H. Robinson, M. Snape, R. Tarrant, M. Voysey, C. Green, A.D. Douglas, Hill AVS, T. Lambe, S.C. Gilbert, A.J. Pollard, Oxford COVID Vaccine Trial Group, Safety and immunogenicity of the ChAdOx1 nCov-19 vaccine against SARS-CoV-2: a preliminary report of a phase 1/2, single-blind, randomised controlled trial, *Lancet* 396 (10249) (2020) 467–478, [https://doi.org/10.1016/S0140-6736\(20\)31604-4](https://doi.org/10.1016/S0140-6736(20)31604-4). Epub 2020 Jul 20. Erratum in: *Lancet*. 2020 Aug 15;396(10249):466. Erratum in: *Lancet*. 2020 Dec 12;396(10266):1884. PMID: 32702298; PMCID: PMC7445431.
- F.P. Polack, S.J. Thomas, N. Kitchin, J. Absalon, A. Gurtman, S. Lockhart, J. L. Perez, G. Pérez Marc, E.D. Moreira, C. Zerbini, R. Bailey, K.A. Swanson, S. Roychoudhury, K. Koury, P. Li, W.V. Kalina, D. Cooper, R.W. Frenck Jr., L. L. Hammit Jr., Ö. Türeci Jr., H. Nell Jr., A. Schaefer Jr., S. Ünal Jr., D. B. Tresnan Jr., S. Mather Jr., P.R. Dormitzer Jr., U. Şahin Jr., K.U. Jansen Jr., W. C. Gruber Jr., C4591001 Clinical Trial Group, Safety and efficacy of the BNT162b2 mRNA covid-19 vaccine, *N. Engl. J. Med.* 383 (27) (2020) 2603–2615, <https://doi.org/10.1056/NEJMoa2034577>. Erratum in: *Thromb Res.* 2008;123(1):187-90.
- L.R. Baden, H.M. El Sahly, B. Essink, K. Kotloff, S. Frey, R. Novak, D. Diemert, S. A. Spector, N. Rouphael, C.B. Creech, S. Khetan, N. Segall, J. Solis, A. Brosz, C. Fierro, H. Schwartz, K. Neuzil, L. Corey, P. Gilbert, H. Janes, D. Follmann, M. Marovich, J. Mascola, L. Polakowski, J. Ledgerwood, B.S. Graham, H. Bennett, R. Pajon, C. Knightly, B. Leav, W. Deng, H. Zhou, S. Han, M. Ivarsson, J. Miller, T. Zaks, J. McGettigan, COVE Study Group, Efficacy and safety of the mRNA-1273 SARS-CoV-2 vaccine, *N. Engl. J. Med.* 384 (5) (2021) 403–416, <https://doi.org/10.1056/NEJMoa2035389>. Epub 2020 Dec 30.
- J. Sadoff, M. Le Gars, G. Shukarev, D. Heerwegh, C. Truysers, A.M. de Groot, J. Stoop, S. Tete, W. Van Damme, I. Leroux-Roels, P.J. Berghmans, M. Kimmel, P. Van Damme, J. de Hoon, W. Smith, K.E. Stephenson, S.C. De Rosa, K.W. Cohen, McElrath MJ, E. Cormier, G. Schepers, D.H. Barouch, J. Hendriks, F. Struyf, M. Dougouih, J. Van Hoof, H. Schuitemaker, Interim results of a phase 1-2a trial of Ad26.COV2.S Covid-19 vaccine, *N. Engl. J. Med.* 384 (19) (2021) 1824–1835, <https://doi.org/10.1056/NEJMoa2034201>. Epub 2020 Dec 30.
- N. Dagan, N. Barda, E. Kepten, O. Miron, S. Perchik, M.A. Katz, M.A. Hernán, M. Lipsitch, B. Reis, R.D. Balicer, BNT162b2 mRNA Covid-19 vaccine in a nationwide mass vaccination setting, *N. Engl. J. Med.* 384 (15) (2021) 1412–1423, <https://doi.org/10.1056/NEJMoa2101765>. Epub 2021 Feb 24.
- M.G. Thompson, J.L. Burgess, A.L. Naleway, H. Tyner, S.K. Yoon, J. Meece, Olsho LEW, A.J. Caban-Martinez, A.L. Fowlkes, K. Lutrick, H.C. Groom, K. Dunnigan, M.J. Odean, K. Hegmann, E. Stefanski, L.J. Edwards, N. Schaefer-Solle, L. Grant, K. Ellingson, J.L. Kuntz, T. Zunie, M.S. Thiese, L. Ivacic, M. G. Wesley, J. Mayo Lamberte, X. Sun, M.E. Smith, A.L. Phillips, K.D. Groover, Y. M. Yoo, J. Gerald, R.T. Brown, M.K. Herring, G. Joseph, S. Beitel, T.C. Morrill, J. Mak, P. Rivers, B.P. Poe, B. Lynch, Y. Zhou, J. Zhang, A. Kelleher, Y. Li, M. Dickerson, E. Hanson, K. Guenther, S. Tong, A. Bateman, E. Reisdorf, J. Barnes, E. Azziz-Baumgartner, D.R. Hunt, M.L. Arvay, P. Kuty, A.M. Fry, M. Gaglani, Prevention and attenuation of Covid-19 with the BNT162b2 and mRNA-1273 vaccines, *N. Engl. J. Med.* (2021), <https://doi.org/10.1056/NEJMoa2107058>. Epub ahead of print.
- N.M. Kuderer, T.K. Choueiri, D.P. Shah, Y. Shyr, S.M. Rubinstein, D.R. Rivera, S. Shete, C.Y. Hsu, A. Desai, G. de Lima Lopes Jr., P. Grivas Jr., C.A. Painter Jr., S. Peters Jr., M.A. Thompson Jr., Z. Bakouny Jr., G. Batist Jr., T. Bekaii-Saab Jr., M. A. Bilen Jr., N. Bouganim Jr., M.B. Larroya Jr., D. Castellano Jr., S.A. Del Prete Jr., D.B. Doroshov Jr., P.C. Egan Jr., A. Elkrief Jr., D. Farmakiotis Jr., D. Flora Jr., M. D. Galsky Jr., M.J. Glover Jr., E.A. Griffiths Jr., A.P. Gulati Jr., S. Gupta Jr., N. Hafez Jr., T.R. Halfdanarson Jr., J.E. Hawley Jr., E. Hsu Jr., A. Kasi Jr., A. R. Khaki Jr., C.A. Lemmon Jr., C. Lewis Jr., B. Logan Jr., T. Masters Jr., McKay RR Jr., R.A. Mesa Jr., A.K. Morgans Jr., M.F. Mulcahy Jr., O. A. Panagiotou Jr., P. Peddi Jr., N.A. Pennell Jr., K. Reynolds Jr., L.R. Rosen Jr., R. Rosovsky Jr., M. Salazar Jr., A. Schmidt Jr., S.A. Shah Jr., J.A. Shaya Jr., J. Steinharter Jr., K.E. Stockerl-Goldstein Jr., S. Subbiah Jr., D.C. Vinh Jr., F. H. Wehbe Jr., L.B. Weissmann Jr., J.T. Wu Jr., E. Wulf-Burchfield Jr., Z. Xie Jr., A. Yeh Jr., P.P. Yu Jr., A.Y. Zhou Jr., L. Zubiri Jr., S. Mishra Jr., G.H. Lyman Jr., B. I. Rini Jr., J.L. Warner Jr., COVID-19 and Cancer Consortium, Clinical impact of COVID-19 on patients with cancer (CCC19): a cohort study, *Lancet* 395 (10241) (2020) 1907–1918, [https://doi.org/10.1016/S0140-6736\(20\)31187-9](https://doi.org/10.1016/S0140-6736(20)31187-9). Epub 2020 May 28. Erratum in: *Lancet*. 2020 Sep 12;396(10253):758. PMID: 32473681; PMCID: PMC7255743.
- I. Del Molino Del Barrio, T. Alaguthurai, C. Domingo-Vila, T.S. Hayday, C. Graham, J. Seow, S. Abdul-Jawad, S. Kamdar, E. Harvey-Jones, R. Graham, J. Cooper, M. Khan, J. Vidler, H. Kakkassery, S. Sinha, R. Davis, L. Dupont, I. Francos Quijorna, C. O'Brien-Gore, P.L. Lee, J. Eum, M. Conde Poole, M. Joseph, D. Davies, Y. Wu, A. Swampillai, B.V. North, A. Montes, M. Harries, A. Rigg, J. Spicer, M. H. Malim, P. Fields, P. Patten, F. Di Rosa, S. Papa, T. Tree, K.J. Doores, A. C. Hayday, S. Irshad, Safety and immunogenicity of one versus two doses of the COVID-19 vaccine BNT162b2 for patients with cancer: interim analysis of a prospective observational study, *Lancet Oncol.* 22 (6) (2021) 765–778, [https://doi.org/10.1016/S1470-2045\(21\)00213-8](https://doi.org/10.1016/S1470-2045(21)00213-8).
- R. Palich, M. Veyri, S. Marot, A. Vozy, J. Gligorov, P. Maingon, A.G. Marcelin, J. P. Spano, Weak immunogenicity after a single dose of SARS-CoV-2 mRNA vaccine in treated cancer patients, *Ann. Oncol.* 32 (8) (2021) 1051–1053, <https://doi.org/10.1016/j.annonc.2021.04.020>. Epub 2021 Apr 29.

- [13] P. Prandoni, A. Falanga, A. Piccioli, Cancer, thrombosis and heparin-induced thrombocytopenia, *Thromb Res.* 120 (Suppl 2) (2007) S137–S140, [https://doi.org/10.1016/S0049-3848\(07\)70143-3](https://doi.org/10.1016/S0049-3848(07)70143-3). Erratum in: *Thromb Res.* 2008;123(1):187–90.
- [14] A. Greinacher, K. Selleng, T.E. Warkentin, Autoimmune heparin-induced thrombocytopenia, *J. Thromb. Haemost.* 15 (11) (2017) 2099–2114, <https://doi.org/10.1111/jth.13813>. Epub 2017 Sep 28.
- [15] A. Greinacher, Clinical practice. Heparin-induced thrombocytopenia, *N. Engl. J. Med.* 373 (3) (2015) 252–261, <https://doi.org/10.1056/NEJMc1411910>.
- [16] R. Eisman, S. Surrey, B. Ramachandran, E. Schwartz, M. Poncz, Structural and functional comparison of the genes for human platelet factor 4 and PF4alt, *Blood* 76 (2) (1990) 336–344.
- [17] Greinacher A, Thiele T, Warkentin TE, Weisser K, Kyrle PA, Eichinger S. Thrombotic thrombocytopenia after ChAdOx1 nCoV-19 vaccination. *N Engl J Med.* doi:10.1056/NEJMoa2104840.
- [18] N.H. Schultz, I.H. Sørvoll, A.E. Michelsen, L.A. Munthe, F. Lund-Johansen, M. T. Ahlen, M. Wiedmann, A.H. Aamodt, T.H. Skattør, G.E. Tjønnfjord, P.A. Holme, Thrombosis and thrombocytopenia after ChAdOx1 nCoV-19 vaccination, *N. Engl. J. Med.* 384 (22) (2021) 2124–2130, <https://doi.org/10.1056/NEJMoa2104882>.
- [19] M. Scully, D. Singh, R. Lown, A. Poles, T. Solomon, M. Levi, D. Goldblatt, P. Kotoucek, W. Thomas, W. Lester, Pathologic antibodies to platelet factor 4 after ChAdOx1 nCoV-19 vaccination, *N. Engl. J. Med.* 384 (23) (2021) 2202–2211, <https://doi.org/10.1056/NEJMoa2105385>. Epub 2021 Apr 16.
- [20] I. See, J.R. Su, A. Lale, E.J. Woo, A.Y. Guh, T.T. Shimabukuro, M.B. Streiff, A. K. Rao, A.P. Wheeler, S.F. Beavers, A.P. Durbin, K. Edwards, E. Miller, T. A. Harrington, A. Mba-Jonas, N. Nair, D.T. Nguyen, K.R. Talaat, V.C. Urrutia, S. C. Walker, C.B. Creech, T.A. Clark, K.R. Broder, F. DeStefano, US Case Reports of Cerebral Venous Sinus Thrombosis With Thrombocytopenia After Ad26.COV2.S Vaccination, March 2 to April 21, 2021, *JAMA* 325 (24) (2021) 2448–2456, <https://doi.org/10.1001/jama.2021.7517>.
- [21] S. Platton, A. Bartlett, P. MacCallum, M. Makris, V. McDonald, D. Singh, M. Scully, S. Pavord, Evaluation of laboratory assays for anti-platelet factor 4 antibodies after ChAdOx1 nCoV-19 vaccination, *J. Thromb. Haemost.* 19 (2021) 2007–2013, <https://doi.org/10.1111/jth.15362>.
- [22] L. Schönborn, T. Thiele, L. Kaderali, A. Greinacher, Decline in pathogenic antibodies over time in VITT, *N. Engl. J. Med.* 385 (19) (2021) 1815–1816, <https://doi.org/10.1056/NEJMc2112760>. Epub 2021 Sep 8.
- [23] S. Holm, H. Kared, A.E. Michelsen, X.Y. Kong, T.B. Dahl, N.H. Schultz, T.A. Nyman, C. Fladeby, I. Seljeflot, T. Ueland, M. Stensland, S. Mjaaland, G.L. Goll, L.S. Nissen-Meyer, P. Aukrust, K. Skagen, I. Gregersen, M. Skjelland, P.A. Holme, L.A. Munthe, B. Halvorsen, Immune complexes, innate immunity, and NETosis in ChAdOx1 vaccine-induced thrombocytopenia, *Eur Heart J.* 42 (39) (2021) 4064–4072, <https://doi.org/10.1093/eurheartj/ehab506>.
- [24] A. Greinacher, K. Selleng, R. Palankar, J. Wesche, S. Handtke, M. Wolff, K. Aurich, M. Lalk, K. Methling, U. Volker, C. Hentschker, S. Michalik, L. Steil, A. Reder, L. Schönborn, M. Beer, K. Franzke, A. Büttner, B. Fehse, E.X. Stavrou, C. Rangaswamy, R.K. Mailer, H. Englert, M. Frye, T. Thiele, S. Kochanek, L. Krutzke, F. Siegerist, N. Endlich, T.E. Warkentin, T. Renné, Insights in ChAdOx1 nCoV-19 vaccine-induced immune thrombotic thrombocytopenia (VITT), *Blood* (2021), <https://doi.org/10.1182/blood.2021013231>. Erratum in: *Thromb Res.* 2008;123(1):187–90.
- [25] J. Perdomo, H.H.L. Leung, Z. Ahmadi, F. Yan, J.J.H. Chong, F.H. Passam, B. H. Chong, Neutrophil activation and NETosis are the major drivers of thrombosis in heparin-induced thrombocytopenia, *Nat. Commun.* 10 (1) (2019) 1322, <https://doi.org/10.1038/s41467-019-09160-7>.
- [26] Y. Zuo, M. Zuo, S. Yalavarthi, K. Gockman, J.A. Madison, H. Shi, W. Woodard, S. P. Lezak, N.L. Lugogo, J.S. Knight, Y. Kanthi, Neutrophil extracellular traps and thrombosis in COVID-19, *J. Thromb. Thrombolysis* 51 (2) (2021) 446–453, <https://doi.org/10.1007/s11239-020-02324-z>. Epub 2020 Nov 5.
- [27] A. Huynh, J.G. Kelton, D.M. Arnold, et al., Antibody epitopes in vaccine-induced immune thrombotic thrombocytopenia, *Nature* 596 (2021) 565–569.
- [28] S. Pavord, M. Scully, B.J. Hunt, W. Lester, C. Bagot, B. Craven, A. Rampotas, G. Ambler, M. Makris, Clinical features of vaccine-induced immune thrombotic thrombocytopenia and thrombosis, *N. Engl. J. Med.* 385 (18) (2021) 1680–1689, <https://doi.org/10.1056/NEJMoa2109908>. Epub 2021 Aug 11.
- [29] F. Salih, L. Schönborn, S. Kohler, C. Franke, M. Möckel, T. Dörner, H.C. Bauknecht, C. Pille, J.A. Graw, A. Alonso, J. Pelz, H. Schneider, A. Bayas, M. Christ, J. B. Kuramatsu, T. Thiele, A. Greinacher, M. Endres, Vaccine-induced thrombotic thrombocytopenia with severe headache, *N. Engl. J. Med.* 385 (22) (2021) 2103–2105, <https://doi.org/10.1056/NEJMc2112974>. Epub 2021 Sep 15.
- [30] J. Thaler, C. Ay, K.V. Gleixner, A.W. Hauswirth, F. Cacioppo, J. Grafeneder, P. Quehenberger, I. Pabinger, P. Knöbl, Successful treatment of vaccine-induced prothrombotic immune thrombocytopenia (VIPIT), *J. Thromb. Haemost.* 19 (7) (2021) 1819–1822, <https://doi.org/10.1111/jth.15346>. Epub 2021 Jun 11.
- [31] J. Hwang, S.H. Park, S.W. Lee, S.B. Lee, M.H. Lee, G.H. Jeong, M.S. Kim, J.Y. Kim, A. Koyanagi, L. Jacob, S.Y. Jung, J. Song, D.K. Yon, J.I. Shin, L. Smith, Predictors of mortality in thrombotic thrombocytopenia after adenoviral COVID-19 vaccination: the FAPIC score, *Eur. Heart J.* 42 (39) (2021) 4053–4063, <https://doi.org/10.1093/eurheartj/ehab592>.
- [32] P.H. Su, Y.C. Yu, W.H. Chen, H.C. Lin, Y.T. Chen, M.H. Cheng, Y.M. Huang, Case report: vaccine-induced immune thrombotic thrombocytopenia in a pancreatic cancer patient after vaccination with messenger RNA-1273, *Front. Med. (Lausanne)* 8 (2021) 772424, <https://doi.org/10.3389/fmed.2021.772424>. COVID-19 vaccine weekly safety report - 04-11-2021 [Therapeutic Goods Administration (TGA)].
- [33] A. Greinacher, F. Langer, M. Makris, M. Pai, S. Pavord, H. Tran, T.E. Warkentin, Vaccine-induced immune thrombotic thrombocytopenia (VITT) - update on diagnosis and management considering different resources, *J. Thromb. Haemost.* (2021), <https://doi.org/10.1111/jth.15572>. Epub ahead of print.
- [34] T.E. Warkentin, M. Pai, J.I. Sheppard, S. Schulman, A.C. Spyropoulos, J. W. Eikelboom, Fondaparinux treatment of acute heparin-induced thrombocytopenia confirmed by the serotonin-release assay: a 30-month, 16-patient case series, *J. Thromb. Haemost.* 9 (12) (2011) 2389–2396.
- [35] T.E. Warkentin, High-dose intravenous immunoglobulin for the treatment and prevention of heparin-induced thrombocytopenia: a review, *Expert Rev Hematol.* 12 (8) (2019) 685–698, <https://doi.org/10.1080/17474086.2019.1636645>. Epub 2019 Jul 5. PMID: 31274032.36.
- [36] M. Irani, E. Siegal, A. Jella, R. Aster, A. Padmanabhan, Use of intravenous immunoglobulin G to treat spontaneous heparin-induced thrombocytopenia, *Transfusion* 59 (3) (2019) 931–934, <https://doi.org/10.1111/trf.15105>. Epub 2018 Dec 17.
- [37] Günalp Uzun, Karina Althaus, Anurag Singh, Peter Möller, Ulf Ziemann, Annerose Mengel, Peter Rosenberger, Martina Guthoff, Gabor C. Petzold, Jens Müller, Martin Büchsel, Katharina Feil, Hans Henkes, Nils Heyne, Matthias Maschke, Caroline Limpach, Simon Nagel, Ulrich J. Sachs, Falko Fend, Tamam bakchouli; the use of IV immunoglobulin in the treatment of vaccine-induced immune thrombotic thrombocytopenia, *Blood* 138 (11) (2021) 992–996.
- [38] C.J. Patriquin, V. Laroche, R. Selby, J. Pendergrast, D. Barth, B. Côté, N. Gagnon, G. Roberge, M. Carrier, L.A. Castellucci, D. Scarvelis, J.P. Mack, Therapeutic plasma exchange in vaccine-induced immune thrombotic thrombocytopenia, *N. Engl. J. Med.* 385 (9) (2021) 857–859, <https://doi.org/10.1056/NEJMc2109465>. Epub 2021 Jul 7.
- [39] J. Thaler, P. Jilma, N. Samadi, F. Roitner, E. Mikušková, S. Kudrnovsky-Moser, J. Retzl, R. Preiss, P. Quehenberger, I. Pabinger, P. Knoebl, C. Ay, Long-term follow-up after successful treatment of vaccine-induced prothrombotic immune thrombocytopenia, *Thromb Res.* 207 (2021) 126–130, <https://doi.org/10.1016/j.thromres.2021.09.017>. Epub ahead of print.
- [40] L. Schönborn, T. Thiele, L. Kaderali, A. Greinacher, Decline in Pathogenic Antibodies over Time in VITT, *N Engl J Med.* 385 (19) (2021) 1815–1816, <https://doi.org/10.1056/NEJMc2112760>. Epub 2021 Sep 8.
- [41] M.G. Thompson, E. Stenehjem, S. Grannis, S.W. Ball, A.L. Naleway, T.C. Ong, DeSilva MB, K. Natarajan, C.H. Bozior, N. Lewis, B. Dascomb, B.E. Dixon, R.J. Birch, S.A. Irving, S. Rao, E. Kharbanda, J. Han, S. Reynolds, K. Goddard, N. Grisel, W. F. Fadel, M.E. Levy, J. Ferdinands, B. Fireman, J. Arndorfer, N.R. Valvi, E. A. Rowley, P. Patel, O. Zerbo, E.P. Griggs, R.M. Porter, M. Demarco, L. Blanton, A. Steffens, Y. Zhuang, N. Olson, M. Barron, P. Shifflett, S.J. Schrag, J.R. Verani, A. Fry, M. Gaglani, E. Azziz-Baumgartner, N.P. Klein, Effectiveness of Covid-19 vaccines in ambulatory and inpatient care settings, *N. Engl. J. Med.* 385 (15) (2021) 1355–1371, <https://doi.org/10.1056/NEJMoa2110362>. Epub 2021 Sep 8.
- [42] J. Lacy, S. Pavord, K.E. Brown, VITT and second doses of Covid-19 vaccine, *N. Engl. J. Med.* (2021), <https://doi.org/10.1056/NEJMc2118507>. Epub ahead of print.
- [43] <https://www.cdc.gov/coronavirus/2019-ncov/vaccines/safety/adverse-events.html>.
- [44] R.L. Atmar, K.E. Lyke, M.E. Deming, L.A. Jackson, A.R. Branche, H.M. El Sahly, C. A. Rostad, J.M. Martin, C. Johnston, R.E. Rupp, M.J. Mulligan, R.C. Brady, R. W. Frenc, M. Bäcker, A.C. Kottkamp, T.M. Babu, K. Rajakumar, S. Edupuganti, D. Dobryzynski, C.M. Posavad, J.I. Archer, S. Crandon, S.U. Nayak, D. Szydlo, J. Zemanek, Islas CPD, E.R. Brown, M.S. Suthar, McElrath MJ, McDermott AB, S. E. O'Connell, D.C. Montefiori, A. Eaton, K.M. Neuzil, D.S. Stephens, P.C. Roberts, J. H. Beigel, DMID 21-0012 Study Group, Heterologous SARS-CoV-2 booster vaccinations - preliminary report, medRxiv (2021), <https://doi.org/10.1101/2021.10.10.21264827>, 2021.10.10.21264827.
- [45] N.A. Doria-Rose, X. Shen, S.D. Schmidt, S. O'Dell, W. Feng, J. Tong, A. Eaton, M. Maglinao, H. Tang, R.L. Atmar, K.E. Lyke, L. Wang, Y. Zhang, M.R. Gaudinski, W.P. Black, I. Gordon, M. Guech, J.E. Ledgerwood, J.N. Misasi, A. Widge, P. C. Roberts, J. Beigel, B. Korber, R. Pajon, J.R. Mascola, D.C. Montefiori, C. McDaniel, Booster of mRNA-1273 vaccine reduces SARS-CoV-2 omicron escape from neutralizing antibodies, medRxiv (2021), <https://doi.org/10.1101/2021.12.15.21267805>.