

CASE REPORT

Open Access



Endoluminal vacuum therapy in the management of an esophago-pleural fistula as a complication of Boerhaave syndrome in a patient with eosinophilic esophagitis

Carlos Tuñón¹, Juan De Lucas¹, Jan Cubilla¹, Rafael Andrade², Miguel Aguirre² and Julio Zúñiga Cisneros^{3*} 

Abstract

Background: Boerhaave syndrome is an uncommon condition that represents about 15% of all esophageal perforation. A subset of these patients has eosinophilic esophagitis, a chronic inflammatory disease of the esophagus, that carries a risk of perforation of about 2%. Esophageal perforations can rarely result in the development of an esophago-pleural fistula. Treatment of esophago-pleural fistula represent a challenge due to lack of high quality evidence and scarce reported experience. Endoluminal vacuum-assisted therapy could have a role in the management by using the same principle applied in external wounds which provide wound drainage and tissue granulation.

Case presentation: We report a unique case of a 24-year-old man with eosinophilic esophagitis complicated with an esophageal rupture who developed an esophago-pleural fistula and was successfully managed with a non-surgical approach using endoluminal vacuum-assisted therapy. To our knowledge this could be the first experience reported in a patient with eosinophilic esophagitis.

Conclusion: Endoluminal vacuum-assisted therapy might be an effective and novel strategy in patients with eosinophilic esophagitis and esophago-pleural fistula as a consequence of Boerhaave syndrome. Appropriately designed studies are required.

Keywords: Boerhaave syndrome, Eosinophilic esophagitis, Vacuum-assisted closure, Endoscopy, Case report

Background

Effort rupture of the esophagus, also known as Boerhaave syndrome is uncommon. It represents about 15% of all esophageal perforation which have an incidence of 3.1 per 1,000,000 per year [1, 2]. A subset of patients with Boerhaave syndrome have underlying eosinophilic esophagitis. On the other hand, approximately 2% of patients with eosinophilic esophagitis can develop an effort rupture of the esophagus [3]. Amid the complications of Boerhaave

syndrome, esophago-pleural fistula is uncommon despite the anatomical proximity of these structures [2].

The mortality of Boerhaave syndrome can be 10% if diagnosed within less than 24 h of symptoms and can be as high as 50% if diagnosed late. Management of esophageal perforation depends on the size, location, and complications associated with perforation; as well as the comorbidities of the patient and the baseline status of the esophagus [2, 4]. Surgery is the mainstay of treatment, but lately nonoperative management has been the preferred approach in a substantial number of patients. Non-operative treatment options include conservative esophageal stenting and endo-clip application. However,

*Correspondence: juliozc22@gmail.com

³ Department of Internal Medicine, Santo Tomas Hospital, Bella Vista, Panama City, Panama

Full list of author information is available at the end of the article



© The Author(s) 2021. **Open Access** This article is licensed under a Creative Commons Attribution 4.0 International License, which permits use, sharing, adaptation, distribution and reproduction in any medium or format, as long as you give appropriate credit to the original author(s) and the source, provide a link to the Creative Commons licence, and indicate if changes were made. The images or other third party material in this article are included in the article's Creative Commons licence, unless indicated otherwise in a credit line to the material. If material is not included in the article's Creative Commons licence and your intended use is not permitted by statutory regulation or exceeds the permitted use, you will need to obtain permission directly from the copyright holder. To view a copy of this licence, visit <http://creativecommons.org/licenses/by/4.0/>. The Creative Commons Public Domain Dedication waiver (<http://creativecommons.org/publicdomain/zero/1.0/>) applies to the data made available in this article, unless otherwise stated in a credit line to the data.

their routine use in the context of an esophago-pleural fistula have not been established [4].

During the last years, there has been some reports the role of endoluminal vacuum therapy in the management of esophageal perforations and leaks with acceptable high success rates of up to 83%. Nonetheless, the experience in the setting of Boerhaave syndrome and esophago-pleural fistula is limited [5, 6]. There are no reported cases in eosinophilic esophagitis.

We report the case of a patient with eosinophilic esophagitis that was complicated with an esophageal perforation developing esophago-pleural fistula and was managed successfully with endoscopy vacuum-assisted closure with sponge.

Case presentation

A 24-year-old man was admitted to our hospital 48 h after developing an acute retrosternal chest pain that was radiated to the upper back, associated with multiple episodes of vomit (food content), and progressive dyspnea. Additionally, he describes intermittent difficulty swallowing solid food. His medical history is significant for well-controlled asthma using salbutamol as needed.

Initial evaluation revealed a temperature of 38.4 degrees; blood pressure, 100/60 mmHg; heart rate, 118/min; respiratory rate, 26/min, and SpO₂, 94% on room air. Additionally, the physical examination showed subcutaneous emphysema in the cervical and thoracic regions, shallow breathing, dullness to percussion in both lung bases. His investigation results on admission revealed white blood cell count of 21,000/ μ L (91% Neutrophils), C-reactive protein (CRP) and procalcitonin were 39.2 mg/dL and 9 ng/mL respectively. Liver and renal function were normal. The patient was admitted with sepsis of unclear etiology, although there was a suspicious for esophageal perforation predisposing mediastinitis and sepsis.

A contrast-enhanced thoracic computed tomography (CT), showed a pneumomediastinum, cervical emphysema, bilateral pleural effusion, as well as extraluminal oral contrast surrounding the distal portion of the gastroesophageal junction region and fluid-air level indicating a collection in the posterior mediastinum (Fig. 1a–d). Initial management included intravenous fluid, nothing per oral (NPO), broad spectrum antibiotics, and analgesia. Due to the clinical condition of the patient, time of the rupture and inaccessibility to an intensive care unit due to the Covid 19 pandemic situation, the thoracic surgery and gastroenterology teams decided a nonoperative approach based on endoscopic therapy. The patient underwent endoscopy that showed a distal esophageal lineal tear just above Z line of approximately 4 cm with irregular edges. Irrigation and drainage of food

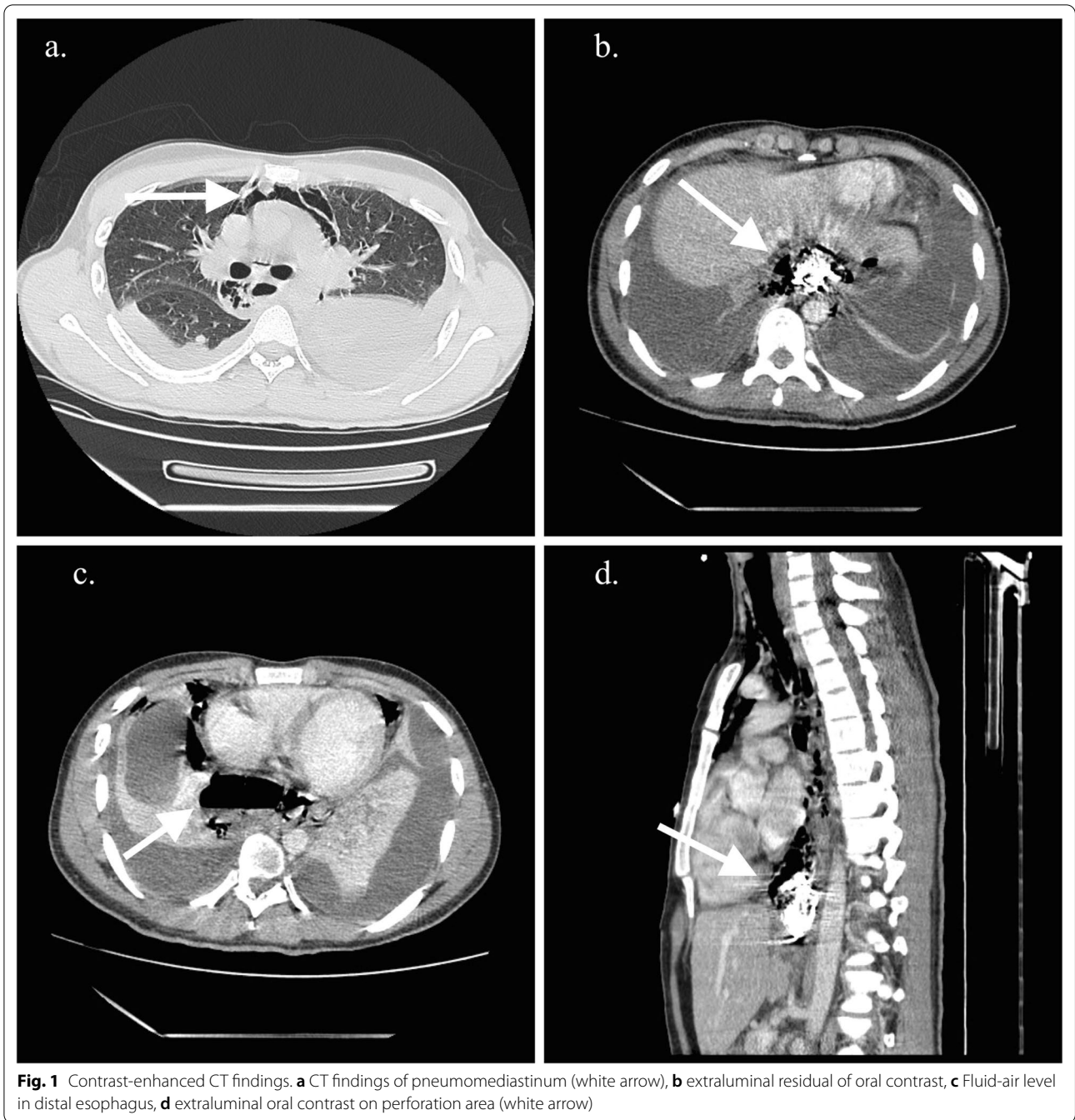
debris of the cavity was performed before a distal auto-expandable esophageal prosthesis SX-ELLA (ELLA-CS) of 25 mm \times 18 mm \times 15 cm with antimigration technology and anti-reflux valve was placed (Fig. 2). The thoracic surgeon decided to put a bilateral pleural tube oriented toward the perforation preventing future complications. Biopsies of the esophageal mucosa were obtained confirming the clinical suspicion of eosinophilic esophagitis (Fig. 2a).

Esophago-pleural Fistula and endoluminal vacuum-assisted closure with sponge

Five days after admission, a new endoscopic procedure was performed, showing migration of the esophageal stent into the stomach, a persistent perforation defect in the lower third of the esophagus with granulation tissue and two small cavities suggesting a fistulous tract. A fistulogram was performed confirming the fistulous tract between the esophagus and the pleura (Fig. 3a, b). Based on these findings and previous case reports found in the literature it was decided to place an endoluminal vacuum-assisted closure with sponge in the area of perforation with the fistula (Fig. 3c–e) to control both complications. The sponge was cutted to 7 cm, adjusted and grasped with a tripod equipped endoscope and introduced in the cavity under direct visualization. After placement of the sponge, a vacuum device was connected and set to a continuous 125 mmHg sub-atmospheric, moderate intensity pressure.

In the second intervention for dressing change of the sponge, two OVESCO clips (OTSC[®]) were placed as a strategy to reduce the size of the tear and closure of the fistula, reducing up to 30% of the longitudinal size. The patient required four additional dressing changes of endoscopic vacuum-assisted closure with sponge, each one performed every 72 h, until the fistulogram showed resolution of the esophago-pleural fistulous tract (Fig. 4a–c).

Despite good progress of the esophago-pleural fistula, the patient condition got worse due *Clostridium difficile* colitis. Despite appropriate antibiotic treatment, and resuscitation with fluids the patient developed shock with severe acute respiratory distress syndrome requiring vasopressor support and mechanical ventilation with neuromuscular blockade. The gastroenterology team decided to place a new esophageal prosthesis in order to avoid dressing changes of the sponge and worsening of the clinical condition. Considering *Clostridium difficile* infection, a recto-sigmoidoscopy was performed which reported ischemic colitis and pseudomembranes. Due to lack of improvement despite treatment due to uncontrolled foci of infectious (colon), an emergency left hemicolectomy and a Hartmann's procedure were performed.



Over the next 7 days, the patient condition improved, allowing to perform an endoscopy with fistulogram that showed a recurrent fistulous esophago-pleural tract (Fig. 5a). The esophageal prosthesis was removed and a new vacuum-assisted closure with sponge was placed. Three dressing changes of endoscopic vacuum-assisted closure with sponge were performed before esophago-pleural fistula resolution was evident (Fig. 5b, c). The

sponge and the OTSC[®] was retired due to a complete fistula resolution.

A follow-up endoscopy performed 3 days after the last vacuum-assisted closure with sponge was removed, that showed epithelized esophageal mucosa with granulation tissue (Fig. 5d). After 46 days the patient was discharged with outpatient follow-up.

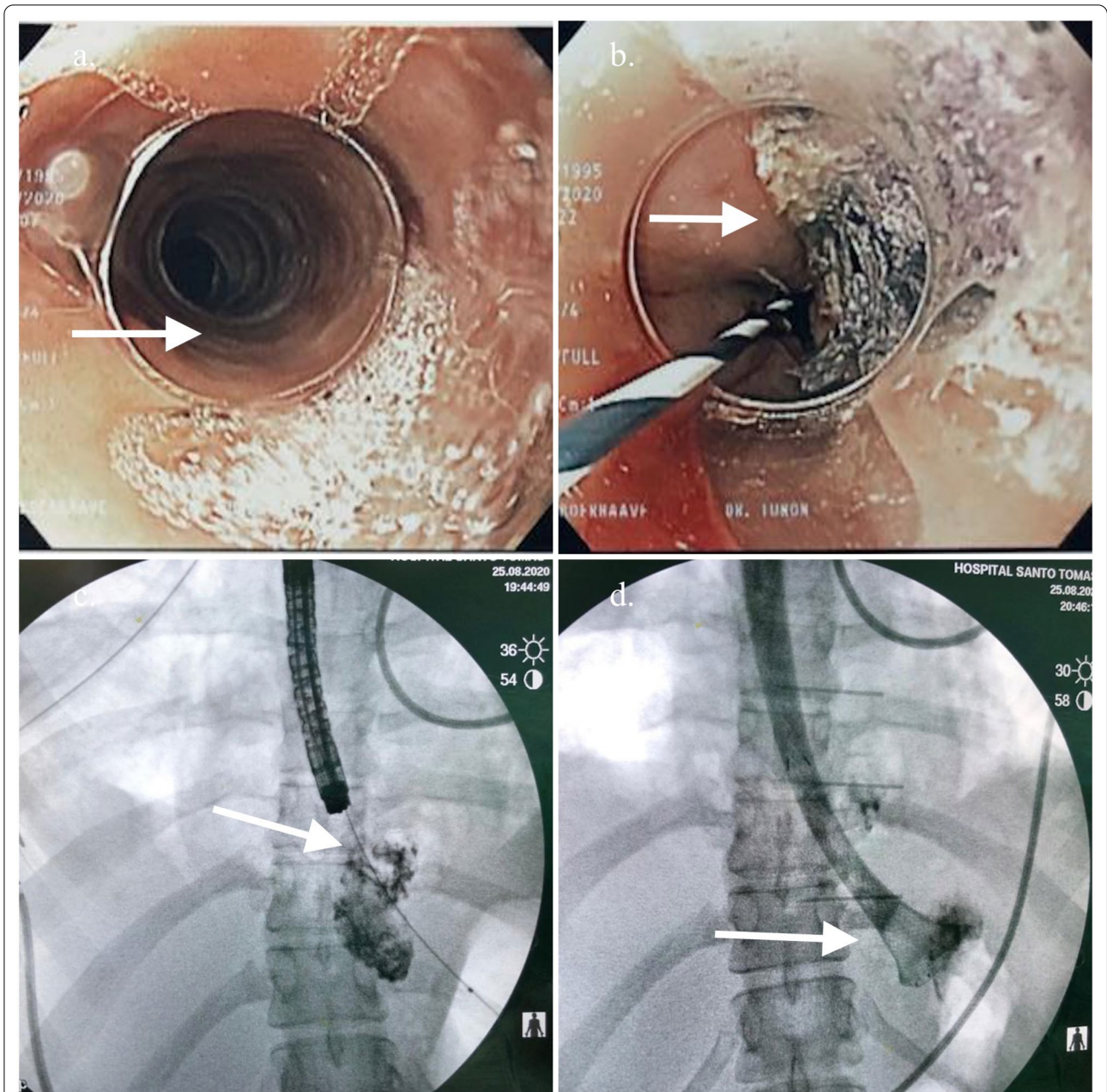
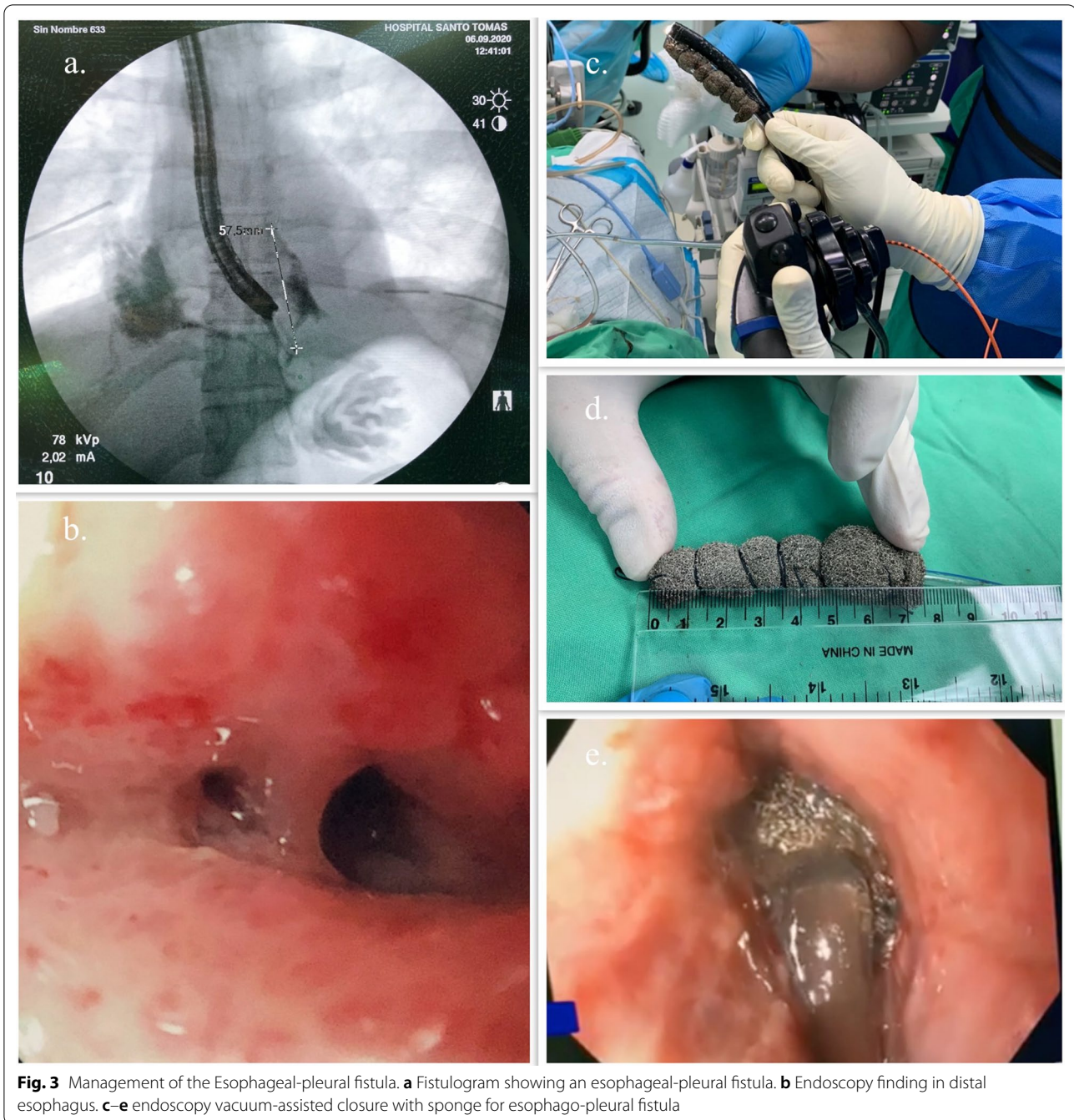


Fig. 2 Intraoperative endoscopy. **a** Typical endoscopic findings of eosinophilic esophagitis, circular rings and linear furrows. **b** Narrow banding imaging with endoscopy showing the esophageal tear (with different color). **c** Endoscopy vision of esophageal perforation area with residual oral contrast and detritus. **d** fluoroscopy showing extraluminal residual oral contrast

Two months later, the patient was asymptomatic, tolerating solids in the diet. A prednisone base therapy and food elimination diet were initiated as a measure of control of his eosinophilic esophagitis.

Discussion and conclusion

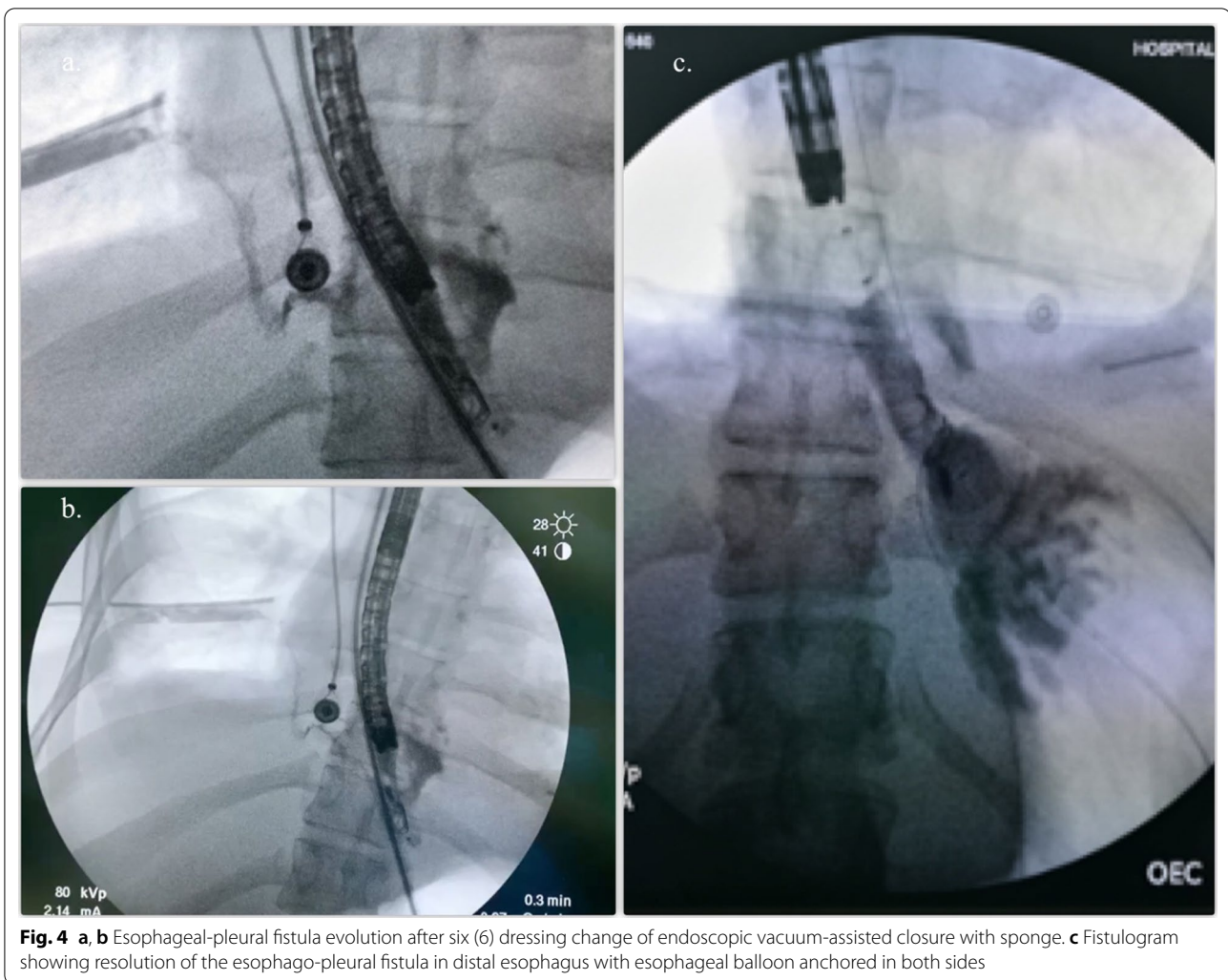
To our knowledge, the case presented here could be the first case reported of eosinophilic esophagitis and esophago-pleural fistula secondary to Boerhaave



syndrome managed successfully with endoluminal vacuum-assisted closure with sponge.

The best management strategy for esophageal perforation and esophago-pleural fistula, regardless of the cause, is still controversial due to the lack of appropriate clinical studies comparing interventions. In addition, there is scarce information about esophago-pleural fistula and Boerhaave syndrome in patients with eosinophilic esophagitis [2, 6].

Endoluminal vacuum therapy has become an alternative endoscopic strategy in patients with contraindications for surgery. It can be used in critically ill and hemodynamically unstable patients that need source control, allowing removal of necrotic debris while promoting tissue healing and granulation tissue in the first 3–5 days of therapy [6–8]. Our patient was managed with a non-surgical strategy given his critical condition and time of presentation. Initially, the defect was managed



unsuccessfully with a distal auto-expandable esophageal prosthesis; however, due to migration of the prosthesis and development of an esophago-pleural fistula the gastroenterologist chose an endoluminal vacuum therapy as a possible therapy based on previous reports of successfully treated patients [8–10]. There are no current guidelines defining the indications for vacuum therapy in the setting of esophageal rupture and its complications. Although two successful cases in a postoperative esophageal anastomotic leak and bronchogenic cyst communicating with the esophagus has been reported [9].

In our case we decided a novel approach considering the size of the rupture and the development of a fistulous tract with an off-label use of two OVESCO clip (OTSC®) to minimize the defect; however, it was not successful. In the literature we found a case reporting healing of a fistulous tract in a patient with a traumatic esophago-pleural fistula using Over-the-Scope-Clip System with good outcome, although in our case the inflammation and

eosinophilic infiltration of the esophageal tissue could have played an important setback for success due to persistent inflammation [11].

There are reports describing the beneficial effects of vacuum therapy to promote healing effect; based on different mechanism included macro and microdeformation, changes in perfusion, exudate control, and bacterial clearance [6, 8]. These mechanisms might have had an impact in our patient, unlike other treatment options initially used. We hope the successful outcome of this case offers a new treatment alternative in this scenario. As a single case experience, more studies are required to validate our observation and establish a true efficacy, however we think it could open new avenues for future research.

This case suggests that an endoluminal vacuum sponge therapy with negative pressure might be an effective and novel strategy in patient with eosinophilic esophagitis who developed esophago-pleural fistula as a consequence

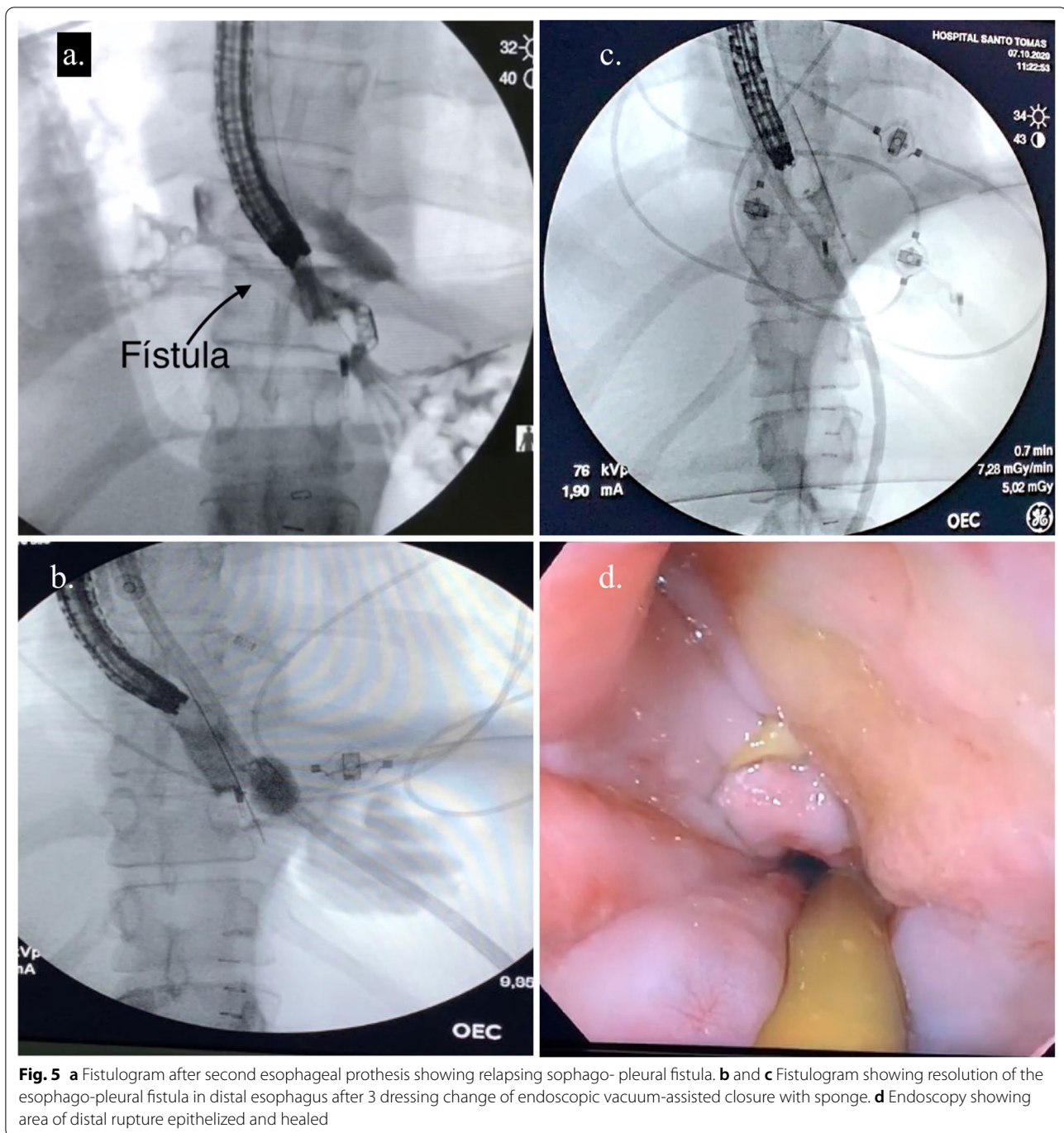


Fig. 5 **a** Fistulogram after second esophageal prosthesis showing relapsing sophago- pleural fistula. **b** and **c** Fistulogram showing resolution of the esophago-pleural fistula in distal esophagus after 3 dressing change of endoscopic vacuum-assisted closure with sponge. **d** Endoscopy showing area of distal rupture epithelized and healed

of Boerhaave Syndrome. We hypothesize that in the context of Boerhaave syndrome in patients with eosinophilic esophagitis, new strategies such as the vaccum therapy could provide another resource for managing these patients.

Abbreviations

SpO₂: Oxygen saturation; CRP: C reactive protein; CT: Computed tomography.

Acknowledgements

We thank Dr. Irma Barrera for his advice regarding the pathological diagnosis of patient’s disease.

Authors’ contributions

CT, JL, JC, RA, MA and JZ conceptualized this case reports and participate in the literature search. All authors read and approved the final manuscript.

Funding

This case report was completed without any financial support from government or non-government agencies.

Availability of data and materials

All data generated or analyzed during this case report are included in this published article.

Declarations**Ethics approval and consent to participate**

Written Informed consent was obtained from the patient. The clinical case report was approved by Hospital Santo Tomas Bioethics Committee and following the principles established in the declaration of Helsinki.

Consent for publication

Written informed consent was obtained from the patient for publication of this case report and any accompanying images. A copy of the written consent is available for review by the editor of this journal.

Competing interests

CT, JL, JC, RA, MA and JZ declares that they have no competing interests.

Author details

¹Department of Gastroenterology, Santo Tomas Hospital, Panama City, Panama. ²Department of Thoracic Surgery, Santo Tomas Hospital, Panama City, Panama. ³Department of Internal Medicine, Santo Tomas Hospital, Bella Vista, Panama City, Panama.

Received: 11 June 2021 Accepted: 7 December 2021

Published online: 20 December 2021

References

- Vidarsdottir H, Blondal S, Alfredsson H, Geirsson A, Gudbjartsson T. Oesophageal perforations in Iceland: a whole population study on incidence, aetiology and surgical outcome. *Thorac Cardiovasc Surg.* 2010;58:476–80.
- Sdralis EK, Petousis S, Rashid F, Lorenzi B, Charalabopoulos A. Epidemiology, diagnosis, and management of esophageal perforations: systematic review. *Dis Esophagus.* 2017;30:1–6.
- Runge TM, Eluri S, Cotton CC, Burk CM, Woosley JT, Shaheen NJ, et al. Causes and outcomes of esophageal perforation in eosinophilic esophagitis. *J Clin Gastroenterol.* 2017;51:805–13.
- Kaman L. Management of esophageal perforation in adults. *Gastroenterology Res.* 2011;6:66.
- Still S, Mencio M, Ontiveros E, Burdick J, Leeds SG. Primary and rescue endoluminal vacuum therapy in the management of esophageal perforations and leaks. *Ann Thorac Cardiovas.* 2018;24:oa.17-00107.
- de Moura DTH, de Moura BFBH, Manfredi MA, Hathorn KE, Bazarbashi AN, Ribeiro IB, et al. Role of endoscopic vacuum therapy in the management of gastrointestinal transmural defects. *World J Gastrointest Endosc.* 2019;11:329–44.
- Möschler O, Nies C, Mueller M. Endoscopic vacuum therapy for esophageal perforations and leakages. *Endosc Int Open.* 2015;03:E554–8.
- Heits N, Stapel L, Reichert B, Schafmayer C, Schniewind B, Becker T, et al. Endoscopic endoluminal vacuum therapy in esophageal perforation. *Ann Thorac Surg.* 2014;97:1029–35.
- Rubicondo C, Lovece A, Pinelli D, Indriolo A, Lucianetti A, Colledan M. Endoluminal vacuum-assisted closure (E-Vac) therapy for postoperative esophageal fistula: successful case series and literature review. *World J Surg Oncol.* 2020;18:301.
- Loske G, Schorsch T, Müller C. Endoscopic intracavitary vacuum therapy of Boerhaave's syndrome: a case report. *Endoscopy.* 2010;42S02:E144–5.
- Kim JH, Park J-J, Jung IW, Kim SH, Kim HD, Choe JW, et al. Treatment of traumatic esophagopleural fistula using the over-the-scope-clip system. *Clin Endosc.* 2014;48:440–3.

Publisher's Note

Springer Nature remains neutral with regard to jurisdictional claims in published maps and institutional affiliations.

Ready to submit your research? Choose BMC and benefit from:

- fast, convenient online submission
- thorough peer review by experienced researchers in your field
- rapid publication on acceptance
- support for research data, including large and complex data types
- gold Open Access which fosters wider collaboration and increased citations
- maximum visibility for your research: over 100M website views per year

At BMC, research is always in progress.

Learn more biomedcentral.com/submissions

