

A Novel Approach to Dilatation of Complete Colorectal Anastomotic Stricture Using Transillumination

Umair M. Nasir, DO¹, Brandon Rodgers, BS¹, Catherine Choi, MD¹, Dayna Panchal, DO¹, Qasim Salimi, MD², and Sushil Ahlawat, MD²

¹Department of Medicine, Rutgers New Jersey Medical School, Newark, NJ

²Division of Gastroenterology, Department of Medicine, Rutgers New Jersey Medical School, Newark, NJ

ABSTRACT

Colorectal anastomotic strictures are a well-known complication of low anterior resection. Depending on their location, strictures are amendable to different forms of endoscopic intervention. However, all endoscopic interventions are contingent on passing a guidewire across the anastomotic stricture. We present the case of a patient with a complete anastomotic stricture that could not be traversed by conventional endoscopy and the unique method by which a lumen was created in the anastomotic strictures that allowed for a guidewire to be passed across.

INTRODUCTION

Low anterior resection is often the management of choice in patients with early-nonmetastatic colorectal carcinoma. One of the most common postsurgical complications after a low anterior resection is anastomotic strictures, which can occur in up to 22% of patients.¹ Colonic strictures have previously been defined as the inability to pass a colonoscope through the stenosis and may go unnoticed because strictures are rarely symptomatic.^{2,3} When symptomatic, patients are likely to present with signs of bowel obstruction. The pathophysiology of colonic anastomotic strictures is not entirely understood, but factors such as ischemia, anastomotic leaks, and radiotherapy have been found to be associated with development.² Management of these strictures may require multiple strategies, including endoscopic stents, balloon dilatation, electrocautery, sphincterotomies, laser or argon plasma coagulation incisions, repeat surgery, or colostomy.^{1,2,4,5} Endoscopic balloon dilatation has become the preferred method in the management of strictures because of excellent efficacy and decreased risks compared with surgery.⁵ Endoscopic management is contingent on the ability to advance a guidewire across the stenotic stricture. In a completely stenotic stricture, it is difficult if not impossible to advance the guidewire across the stricture. We present the case of a patient with a complete anastomotic stricture that could not be traversed and the method by which a guidewire was passed allowing for therapeutic intervention.

CASE REPORT

A 44-year-old man with a medical history of invasive rectal adenocarcinoma (T1N0M0) treated surgically presented to the gastrointestinal clinic for constipation. Two months before, the patient had a low anterior resection of rectal adenocarcinoma with the formation of colorectal anastomosis and loop ileostomy. Ileostomy barium study and barium enema study revealed a complete stricture at the anastomotic site (Figure 1). Flexible sigmoidoscopy confirmed the complete stricture (Figure 2). Despite multiple attempts, a guidewire could not be passed retrograde through the stricture. At this point, ileoscopy was attempted; a pediatric colonoscope was used to intubate the ileostomy and reach the proximal end of the anastomotic stricture; however, advancement of the guidewire antegrade was unsuccessful. As such, biopsy of the colorectal stricture was performed, which revealed acute and chronic inflammation and granulation tissue, with no evidence of recurrent adenocarcinoma.

Two weeks afterward, an ileoscopy with a pediatric colonoscope was performed. The scope was advanced antegrade to the proximal side of the stricture. Concurrently, an adult upper endoscope was inserted into the rectum and advanced to the distal side of

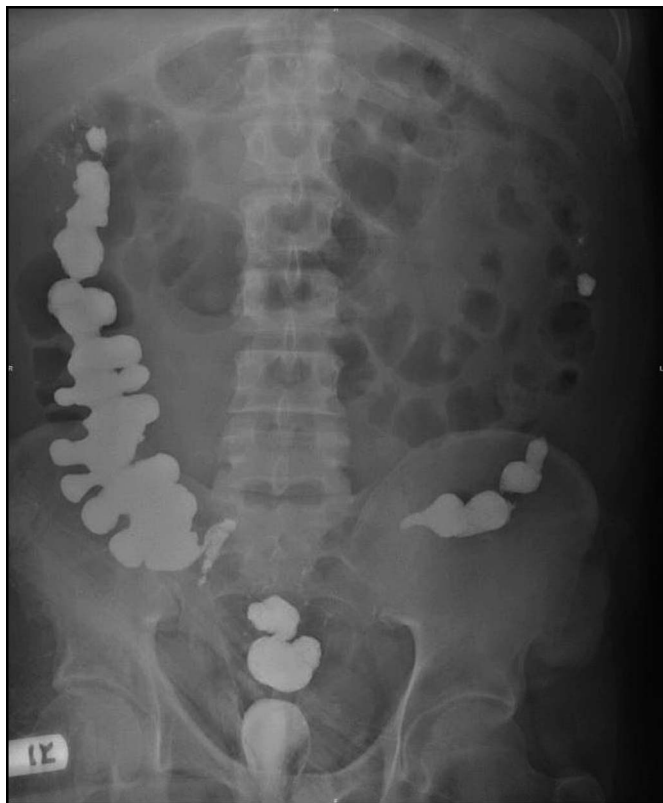

Figure 1. Ileostomy barium study and barium enema showing a complete obstruction to retrograde and anterograde passage of contrast at the level of the rectosigmoid anastomosis.

the stricture. The position of both scopes was confirmed via fluoroscopy. The pediatric colonoscope was used to transilluminate the stricture that was visualized on the adult upper endoscope. The adult upper endoscope was directed precisely toward the transilluminating site, and a 19-gauge needle from the adult scope was used to puncture through the stricture. A

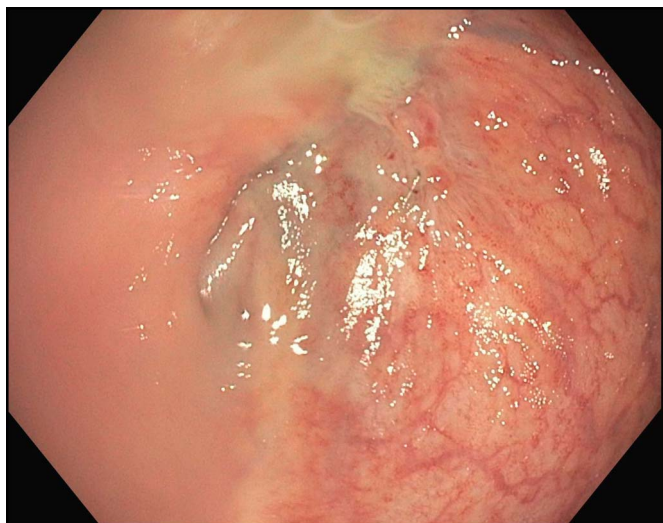


Figure 2. Sigmoidoscopy showing a complete anastomotic stricture that could not be traversed with an endoscope nor a guidewire.

0.035 endoscopic retrograde cholangiopancreatography guidewire was advanced through the newly created lumen in a retrograde fashion. The tract was serially dilated up to 8 mm with balloon dilation (Figure 3). A 10Fr \times 3 cm double pigtail plastic stent was then inserted across the newly created tract (Figure 4).

Two weeks later, colonoscopy was repeated; the double pigtail stent was removed, and the stricture was dilated up to 15 mm (Figure 5). Subsequent colonoscopy was repeated at 5 and 9 weeks, during which the stricture was upsized to 18 and 20 mm, respectively. As the patient's constipation and bowel habits improved, loop ileostomy was reversed at 10 weeks.

The patient was followed up in the gastrointestinal clinic at 1, 4, 7, 12, and 18 months after ileostomy reversal. During this time, the patient presented without complaints of constipation or obstipation. However, flexible sigmoidoscopy performed at 1-, 4-, and 7-month intervals revealed a stricture of 18 mm that was subsequently dilated to 20 mm. Flexible sigmoidoscopy repeated at 12 and 16 months revealed a stricture of 18 mm at which point no intervention was repeated.

DISCUSSION

Anastomotic strictures can develop weeks, months, or even years after surgical intervention.⁶ Endoscopic management has become the treatment of choice, in such cases, because of increased success and decreased complications compared with surgery.⁷ Many endoscopic interventions are available in the management of anastomotic strictures including endoscopic balloon dilation, sphincterotomies, and metal, silicon, or plastic stents. Sphincterotomies can be an effective and safe treatment option for colorectal anastomotic stricture.⁴ However,

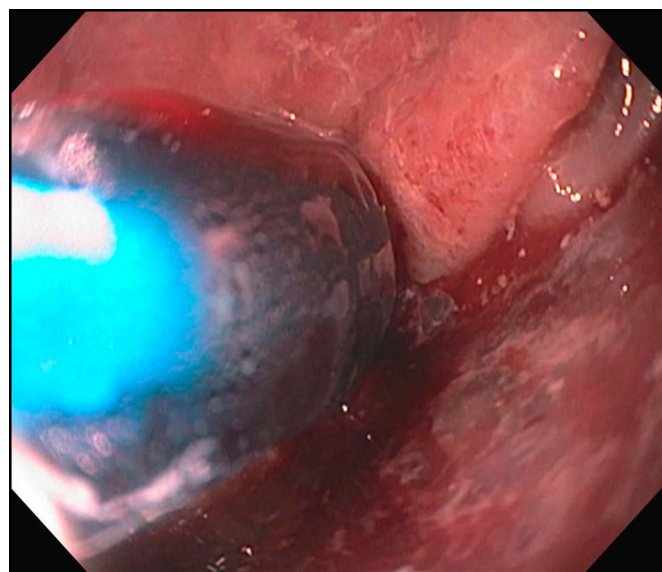


Figure 3. Retrograde balloon dilation of newly created lumen retrograde.

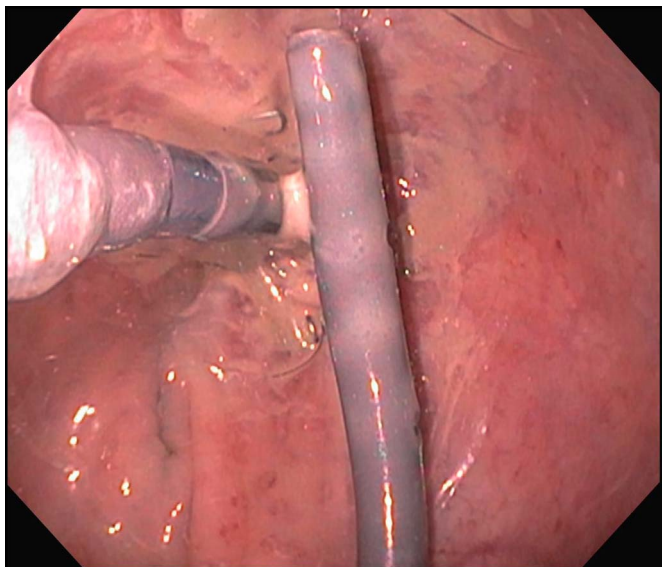


Figure 4. The stricture postdilation and insertion of a 10Fr \times 3 cm double pigtail plastic stent in place.

endoscopic balloon dilation has become first-line in management because of lower risk of complications such as bleeding and perforation compared with endoscopic electrocautery.^{2,4,8} Endoscopic intervention (balloon or electrocautery) is often followed by stenting of the stricture.^{5,9}

In patients who develop complete colorectal anastomotic strictures, endoscopic dilation is contingent on passing a guidewire across the stricture. Combined antegrade and retrograde endoscopy, often known as the rendezvous technique, may aid in the management of such strictures. The rendezvous technique is well documented in aiding the recannulation of complex/complete esophageal obstructions.¹⁰⁻¹² However, only 3 other cases address endoscopic management of complete colonic obstruction using a rendezvous technique.

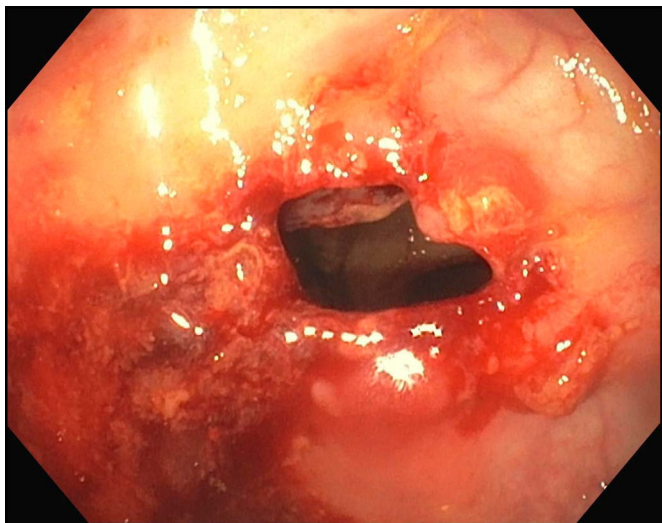


Figure 5. The stricture after removal of the stent and dilation to 15 mm.

Dever et al reported ileoscopy and concurrent retrograde proctoscopy and then using a 22-gauge needle to puncture stricture site, followed by balloon dilation and a polyester-covered silicone self-expanding stent.¹³ Kaushik et al reported antegrade ileoscopy while performing retrograde colonoscopy and using a 19-gauge needle to puncture stricture, followed by balloon dilation.¹⁴ Grossman et al reported antegrade fistuloscopy of a percutaneous cecostomy fistula with a concurrent retrograde colonoscopy.¹⁵

In our case, after confirmation of a nonmalignant stricture, concurrent antegrade ileoscopy with retrograde colonoscopy was performed. The anastomotic stricture was punctured in a retrograde fashion that was followed by balloon dilation to 8 mm and placement of a plastic pigtail stent. Colonoscopy was repeated multiple times thereafter. In total, colonoscopy was performed 4 times at an interval of every 2–3 weeks over 3 months during which the stricture was serially dilated to 8, 15, 18, and 20 mm, respectively. After serial dilation, the patient was able to tolerate ileostomy reversal. Subsequently, close follow-up with flexible sigmoidoscopy revealed minimal narrowing of stricture, and the patient remained without clinical symptoms.

Our case in conjunction with previous cases demonstrates the concept of rendezvous endoscopy and using transillumination to create a lumen in a complete anastomotic stricture. This technique allowed for endoscopic intervention, leading to significant improvement of the stricture and resolution of obstructive symptoms, without surgical interventions.

DISCLOSURES

Author contributions: UM Nasir wrote and revised the manuscript for intellectual content. D. Panchal wrote the manuscript. C. Choi revised the manuscript for intellectual content. B. Rodgers edited the manuscript and reviewed the literature. Q. Salimi and S. Ahlawat provided the endoscopic images and edited the manuscript. UM Nasir is the article guarantor.

Acknowledgements: The authors would like to acknowledge the Department of Medicine and Department of Gastroenterology at Rutgers New Jersey Medical School for their assistance in the development of the drafts and the final manuscript.

Financial disclosure: None to report.

Previous presentation: This case was presented at the American College of Gastroenterology Annual Scientific Meeting, October 25-30, 2019; San Antonio, Texas.

Informed consent was obtained for this case report

Received December 24, 2019; Accepted May 8, 2020

REFERENCES

1. Ridditid W, Siripun A, Rerknimitr R. Stricture at colorectal anastomosis: To dilate or to incise. *Endosc Int Open*. 2018;6(03):E340–1.
2. Suchan KL, Muldner A, Manegold BC. Endoscopic treatment of post-operative colorectal anastomotic strictures. *Surg Endosc*. 2003;17(7):1110–3.
3. Bannura GC, Cumsille MAG, Barrera AE, Contreras JP, Melo CL, Soto DC. Predictive factors of stenosis after stapled colorectal anastomosis: Prospective analysis of 179 consecutive patients. *World J Surg*. 2004;28(9):921–5.
4. Chen TA, Hsu WL. Successful treatment of colorectal anastomotic stricture by using sphincterotomes. *Front Surg*. 2014;1:22.
5. Kwon YH, Jeon SW, Lee YK. Endoscopic management of refractory benign colorectal strictures. *Clin Endosc*. 2013;46(5):472.
6. Weinstock LB, Shatz BA. Endoscopic abnormalities of the anastomosis following resection of colonic neoplasm. *Gastrointest Endosc*. 1994;40(5):558–61.
7. Oz MC, Forde KA. Endoscopic alternatives in the management of colonic strictures. *Surgery*. 1990;108(3):513–9.
8. Dinneen MD, Motson RW. Treatment of colonic anastomotic strictures with “through the scope” balloon dilators. *J R Soc Med*. 1991;84(5):264–6.
9. Guan YS, Sun L, Li X, Zheng XH. Successful management of a benign anastomotic colonic stricture with self-expanding metallic stents: A case report. *World J Gastroenterol*. 2004;10(23):3534.
10. Bueno R, Swanson SJ, Jaklitsch MT, Lukanich JM, Mentzer SJ, Sugarbaker DJ. Combined antegrade and retrograde dilation: A new endoscopic technique in the management of complex esophageal obstruction. *Gastrointest Endosc*. 2001;54(3):368–72.
11. Baumgart DC, Veltzke-Schlieker W, Wiedenmann B, Hintze RE. Successful recanalization of a completely obliterated esophageal stricture by using an endoscopic rendezvous maneuver. *Gastrointest Endosc*. 2005;61(3):473–5.
12. McGrath K, Brazer S. Combined antegrade and retrograde dilation: A new endoscopic technique in the management of complex esophageal obstruction. *Gastrointest Endosc*. 2002;56(1):163.
13. Dever J, Schembre D, Brandabur JJ, Kozarek RA. Novel use of simultaneous dual endoscopy to reconstitute completely obstructed esophagi and colon. *Gastrointest Endosc*. 2009;69(5):AB230.
14. Kaushik N, Rubin J, McGrath K. Treatment of benign complete colonic anastomotic obstruction by using an endoscopic rendezvous technique. *Gastrointest Endosc*. 2006;63(4):727–30.
15. Grossman EB, Schattner MA, DiMaio CJ, Gerdes H, Wong DW, Markowitz AJ. Endoscopic management of complete colonic obstruction. *J Interv Gastroenterol*. 2011;1(4):179.

Copyright: © 2020 The Author(s). Published by Wolters Kluwer Health, Inc. on behalf of The American College of Gastroenterology. This is an open-access article distributed under the terms of the Creative Commons Attribution-Non Commercial-No Derivatives License 4.0 (CCBY-NC-ND), where it is permissible to download and share the work, provided it is properly cited. The work cannot be changed in any way or used commercially without permission from the journal.