

# Technical feasibility and clinical success of direct “free hand” EUS-guided gastroenterostomy in patients with gastric outlet obstruction



## Authors

Hanna Fischer<sup>1</sup>, Katharina Rütger<sup>2</sup>, Mohamed Abdelhafez<sup>2</sup>, Manuela Götzberger<sup>1</sup>, Markus Dollhopf<sup>1</sup>, Christoph Schlag<sup>3</sup>

## Institutions

- 1 Klinik für Gastroenterologie und Hepatologie, München Klinik Neuperlach, Munich, Germany
- 2 II. Medizinische Klinik, Klinikum rechts der Isar, Technische Universität, Munich, Germany
- 3 UniversitätsSpital Zürich, Klinik für Gastroenterologie und Hepatologie, Raemistrasse 100, Zurich 8091, Switzerland

submitted 26.3.2022

accepted after revision 8.7.2022

published online 22.7.2022

## Bibliography

Endosc Int Open 2022; 10: E1358–E1363

DOI 10.1055/a-1907-5393

ISSN 2364-3722

© 2022. The Author(s).

This is an open access article published by Thieme under the terms of the Creative Commons Attribution-NonDerivative-NonCommercial License, permitting copying and reproduction so long as the original work is given appropriate credit. Contents may not be used for commercial purposes, or adapted, remixed, transformed or built upon. (<https://creativecommons.org/licenses/by-nc-nd/4.0/>)

Georg Thieme Verlag KG, Rüdigerstraße 14,  
70469 Stuttgart, Germany

## Corresponding author

Christoph Schlag, UniversitätsSpital Zürich, Klinik für Gastroenterologie und Hepatologie, Raemistrasse 100, Zurich 8091, Switzerland  
Fax: +41432531370  
[Christoph.Schlag@usz.ch](mailto:Christoph.Schlag@usz.ch)

## ABSTRACT

**Background and study aims** Endoscopic ultrasound-guided gastroenterostomy (EUS-GE) with lumen-apposing metal stents (LAMS) appears to be a promising intervention in management of gastroduodenal out obstruction (GOO), particularly for patients for whom surgery is high risk or in a palliative setting. This study aimed to evaluate the technical feasibility, procedure-associated adverse events (AEs), and clinical outcome of direct “free hand” EUS-GE.

**Patients and methods** This retrospective two-center study included patients who underwent direct “free hand” EUS-GE (April 2017 to March 2021) investigating technical success (correctly placed LAMS), clinical outcome (successful oral nutrition), and management of procedure-associated AEs. “Free hand” was defined as the use of the electrocautery enhanced stent delivery system alone without additional guidewire-assistance for EUS-GE creation.

**Results** Forty-five patients (58% women/42% men; mean age 65 years) with malignant (n=39), benign (n=4) or unclear (n=2) GOO underwent direct “free hand” EUS-GE. The technical success rate was 98% (44/45). Of the patients, 95% (42/44) had less vomiting and increased ability to tolerate oral food intake after the intervention. In one patient, a second EUS-GE was necessary to achieve sufficient clinical improvement. Procedure-associated AEs were observed in 24% (11/45) of cases including stent misplacement (n=7), leakage (n=1), development of a gastrojejunal fistula (n=1), and bleeding (n=2), which could be all managed endoscopically.

**Conclusions** Direct EUS-GE has a favorable risk-benefit profile for patients with GOO, showing high technical success rates, manageable AEs, and rapid symptom relief.

## Introduction

Gastric outlet obstruction (GOO) of malignant or benign cause often leads to remarkably reduced quality of life. Affected patients suffer from nausea and vomiting after oral food intake accompanied by progressive weight loss. In patients with a life expectancy of at least several months, surgical gastroenterost-

omy (GE) is still regarded as the treatment of choice. However, as an invasive procedure with prolonged recovery time and increased risk for adverse events (AEs), it is often not appropriate for critically ill patients [1]. If so, less invasive endoluminal stenting using self-expanding metal stents (SEMS) is considered the preferred treatment option in palliative settings. However, this approach often can be limited due to tumor ingrowth

or stent migration and multiple reinterventions can become necessary to preserve the gastrointestinal passage. Furthermore, endoluminal stent placement is not free of AEs such as perforation or bleeding [2].

Endoscopic ultrasound-guided gastroenterostomy (EUS-GE) with lumen apposing metal stents (LAMS) appears to be a promising intervention in the management of GOO combining advantages of both surgical GE and endoluminal stenting. This approach first was described by Binmoeller et al. [3] in a porcine study in 2012, and has recently gained growing attention among highly experienced EUS interventionalists [4–6]. However, data are still limited about this promising and evolving technique and there is an ongoing discussion about the best technical approach (such as balloon-assisted, guidewire-assisted or direct EUS-GE).

Thus, the aim of this study was to evaluate the technical feasibility, clinical outcome, and management of procedure-associated AEs of direct “free hand” EUS-GE in patients with GOO whom surgery would be high risk or in a palliative setting. Direct “free hand” EUS-GE is was performed without additional guidewire-assistance; stent placement was performed by the electrocautery enhanced stent delivery system alone.

## Patients and methods

### Patients

This retrospective two-center study included 45 patients with GOO who underwent direct “free hand” EUS-GE with LAMS between April 2017 and March 2021 at two high-volume referral hospitals in Germany (Klinikum rechts der Isar and München Klinik Neuperlach). Patients were identified in the digital endoscopic databases and electronic medical records were systematically assessed for the medical history of the patients as well as on procedure details such as technical feasibility and adverse events (AEs). Furthermore, follow-up-data were collected via additional telephone interviews with the patients. Data from both institutions were merged in a structured blinded database.

### Direct “free hand” EUS-GE

Patients were explicitly informed about the off-label use of LAMS and procedure-associated risks prior to the intervention. Interventions were performed by three highly experienced interventional endoscopists (MA, MD, CS). EUS-GE was performed in an endoscopy room with the possibility of fluoroscopy under conscious sedation (96%) or general anesthesia (4%; in the case of high risk of aspiration). In preparation for the puncture, the stenosis was either passed by an endoscope (Olympus XP190, GIF H190, GIF (pediatric)) and filling of the target loop was done over the working channel of the scope (40%) or the stenosis was passed by a guidewire and the target loop was filled by a 7F nasobiliary tube (60%). Therefore, clear fluid was supplemented by a contrast agent and blue dye, which was applied anterogradely. In addition, intravenous scopolamine butylbromide was used to reduce peristalsis if needed. The Hot-AXIOS-Stent (Boston Scientific; Marlborough, Massachusetts, United States) was used as stent delivery system in

all cases: A EUS linear array scanner (either Pentax or Olympus GF-UCT 180) was advanced into the stomach. After identification of the fluid-filled target loop a direct puncture of this loop (without using a guidewire – so called “free hand”) with the electrocautery enhanced stent delivery system was performed under endosonographic control. The catheter sheath was retracted as soon as the tip of the catheter was visualized inside the lumen of the target loop and the AXIOS-Stent was deployed (► Fig. 1).

### Study outcome and definitions

Technical and clinical success were defined as correctly placed LAMS and clinical symptom relief after technically correct stent placement (specifically, regained ability to tolerate at least a liquid diet with absence of nausea and vomiting respectively). We used the Gastric Outlet Obstruction Scoring System (GOOSS) presented by Adler in 2002 (0 = no/inadequate oral intake, 1 = liquids/thickened liquids, 2 = semisolids/low residue diet, 3 = unmodified diet) to classify the level of oral intake [7]. Further parameters evaluated were procedure-related adverse events, which were graded according to the American Society for Gastrointestinal Endoscopy (ASGE) lexicon [8], and length of hospital stay.

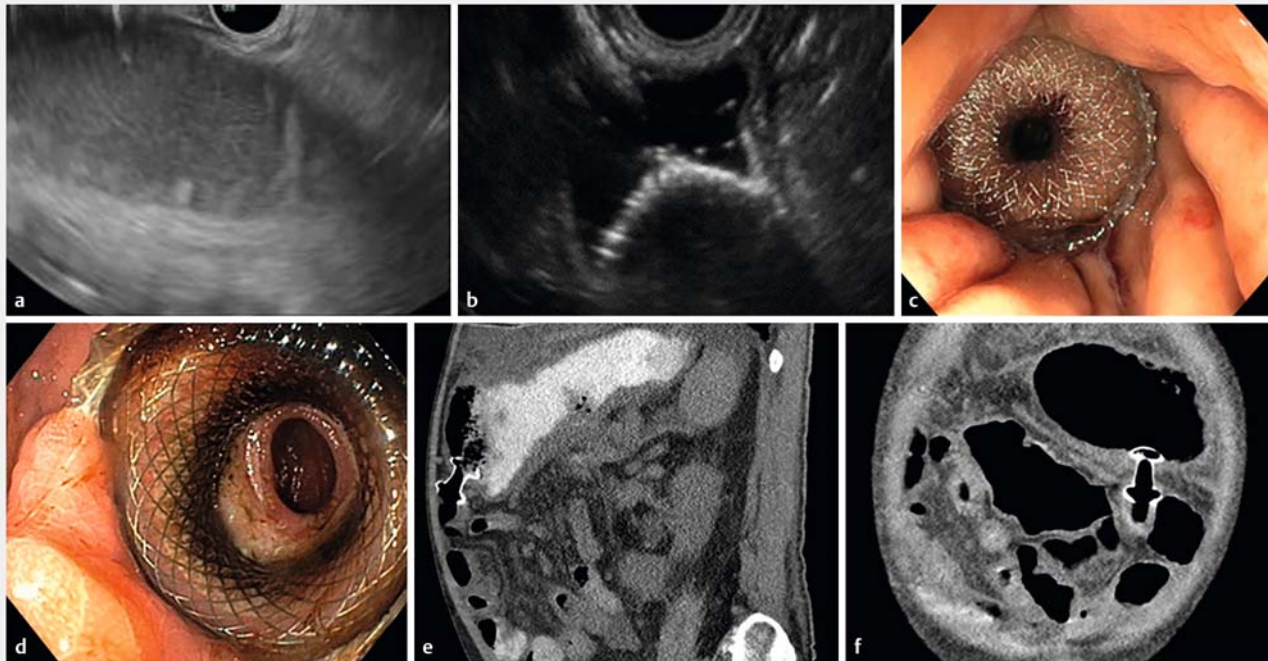
### Postprocedural course

Patients were allowed to drink clear fluids on the day of intervention in case of a regular postinterventional course as soon as sedative effects had completely subsided. Postinterventional gastrointestinal x-ray series with oral contrast were routinely performed the day after intervention to validate unimpeded contrast passage over the stent without leakage. In case of unremarkable findings, oral food intake was allowed with strained food and – if tolerated well – expanded by solid food within the following days. In case of successful symptom relief and missing evidence of procedure-associated adverse events no further endoscopic follow-up was scheduled.

## Results

Of all patients, 26 were female and 19 were male. Mean age at intervention (EUS-GE) was 65 years (range 36–84 years). Patients suffered from the inability of oral food intake (n = 9/45; GOO-Score: 0 = 18/45, 1 = 11/45, 2 = 8/45, 3 = 8/45), nausea and vomiting (n = 36/45) as well as progressive weight loss (n = 22/45).

In most cases (n = 39/45), gastroduodenal obstruction was caused by a local malignant process such as pancreatic, gastric, cholangiocellular or papillary carcinoma (33%, 13%, 9% and 4%, respectively) or by peritoneal carcinomatosis/metastasis of other malignant diseases (ovarian/urothelial/endometrial/colorectal carcinoma, leiomyosarcoma or CUP). In 11% cases (5/45) the obstruction derived from benign etiology such as postoperative or peptic scarred stenosis or after acute pancreatitis. In two cases, the etiology of the stenosis remained unclear. Of the patients, 24% (11/45) had received endoluminal stenting attempts with ongoing symptoms before EUS-GE. Detailed patient characteristics are listed in ► Table 1.



► **Fig. 1** Stent placement. **a** Endosonographic visualization of the liquid-filled intestinal target loop. **b** Puncture and deployment of the distal flange of the stent. **c** Endoscopic picture of the correctly placed LAMS right after placement, and **d** four weeks after EUS-GE. **e + f** Correctly placed LAMS on sagittal and coronal CT-imaging.

### Technical feasibility, AEs, and management of AEs

Overall, the technical success rate for correctly placed LAMS was 98% (44/45) in patients treated with direct “free hand” EUS-GE for GOO. However, in 16% of patients (7/45) contact with the target loop was lost after the gastrostoma was created during the first EUS-GE attempt. Two of these patients had ascites. In three of these cases, the distal flange was deployed in the intraperitoneal cavity; in the other cases, the stent delivery system was retracted before deployment of the distal flange. Correct stent placement succeeded in a second attempt in 86% (6/7) of these cases, mostly within the same session (5/6). Only in one patient (1/7) no second EUS-GE-attempt was performed during the session because prospects of success were limited due to extensive target loop mobility associated with ascites and instability of the patient.

Overall, we observed 11 procedure-related AEs in 10 patients (24%), one of which was mild, eight moderate, and two severe according to the ASGE classification system. Occurrence of AEs did not correlate with stent diameter.

In case of initial stent placement failure ( $n = 7/45$ ), the stent delivery system was retracted, the LAMS extracted (if already deployed), and intravenous (IV) antibiotics were administered for several days after intervention prophylactically to prevent peritonitis. Furthermore, the gastric perforation site was closed by over-the-scope-clipping (OTSC) in two of seven cases. In five of seven cases, no clips were applied to the gastric perforation site because defect size was considered small. None of these patients had further AEs in the postinterventional period.

In one case, postinterventional gastrointestinal x-ray raised the suspicion for a jejunal contrast leakage close to the LAMS, which had been placed in a second attempt beforehand. Diagnostic endoscopy showed correct LAMS placement; the stent was dilated to enable passage of the endoscope to rule out mucosal defects in the jejunum. Thereby, the proximal flange of the stent dislocated into the peritoneal cavity accidentally and the patient developed a pneumoperitoneum and respiratory insufficiency requiring tracheal intubation. After suction of ascites and gentamycin instillation into the peritoneal cavity, the gastroenterostomy was reestablished with guidewire-assisted placement of a fully-covered esophageal stent through the partially dislocated LAMS from the stomach into the jejunal loop. Further treatment was conservative with IV antibiotics under close monitoring leading to gradual clinical improvement; the patient was discharged after recovery.

One patient presented with reoccurring vomiting and diarrhea 3 weeks after primarily successful EUS-GE. The cause was a gastrojejunal fistula, which had developed due to accidental interposition of collapsed colon between stomach and jejunum during the puncture. The distal flange of the stent had then migrated from the jejunal loop back into the colon so the fistula was clinically noticeable. This AE was managed by placing a fully covered esophageal stent through the LAMS reaching from the stomach through the colon into the jejunal target loop.

Bleeding complications were observed in two cases. One occurred immediately after LAMS deployment and could be suffi-

**► Table 1** Patient characteristics.

Number of patients	45
Gender	
▪ Female	26 (58%)
▪ Male	19 (42%)
Mean age at EUS-GE	65 years (range: 36–84 years)
GOO-Score before EUS-GE	
▪ 0	18 (40%)
▪ 1	11 (24%)
▪ 2	8 (18%)
▪ 3	8 (18%)
Cause of stenosis	
▪ Malignant	39 (87%)
▪ Benign	4 (9%)
▪ Unclear	2 (4%)
Site of obstruction	
▪ Gastric	16 (35%)
▪ Duodenal	29 (65%)
Ascites	6 (13%)
Endoluminal stenting before EUS-GE	
▪ 0 attempts	34 (76%)
▪ 1–2 attempts	9 (20%)
▪ >2 attempts	2 (4%)
EUS-GE, endoscopic ultrasound-guided gastroenterostomy; GOO, gastric outlet obstruction.	

ciently treated by sclerotherapy. Another patient developed a hemorrhagic shock few hours after an unsuccessful stenting attempt due to extraluminal bleeding originating from the gastric defect detected by CT-scans. The patient was transferred to the intensive care unit for stabilization and conservatively treated with blood transfusion and intravenous antibiotics. No further endoscopic, radiographic or surgical intervention was required since the hemorrhage was self-limiting.

We observed no intervention-associated deaths. Patients were discharged on average 5 days (range: 1–17) after the intervention.

### Clinical outcome

Median follow-up duration was 131 days (range 2–667). Of the patients, 95% (42/44) benefited from the intervention by showing reduced nausea and a regained ability of oral food intake within just a few days. GOO score improved one level on average. Patients with a lower pre-procedural GOOSS (0–1) had an average improvement of two levels.

However, in 16% patients (7/44) reintervention was necessary to achieve long-lasting symptom relief. In one patient, symptom relief and oral food intake could only be achieved by

placement of a second LAMS (10×15 mm each). In another case, a fully-covered esophageal stent was placed through the LAMS (stent in stent placement) to improve passage through the LAMS (size: 20×10 mm), which was impaired by jejunal mucosal edema. Balloon-dilatation of the LAMS up to 15 mm was performed in three cases within 3 days after LAMS-placement to support clinical improvement.

In two cases LAMS occlusion (size: 15×10 mm and 20×10 mm) by food impaction occurred after 3 days and 14 months, respectively. Endoscopic “cleaning” of the LAMS was performed and additional balloon dilatation of the LAMS was done in the case of early stent occlusion.

Five percent of patients (2/44) did not benefit from EUS-GE. One of these patients who had advanced ovarian cancer developed cholangitis and died due to hepatic metastases a few days after EUS-GE placement; no causal connection to the intervention was assumed. Another patient did not benefit from the intervention clinically although postinterventional gastrointestinal x-rays with oral contrast showed unimpeded contrast passage. This patient was also suffering from rapidly progressive ovarian cancer with peritoneal carcinomatosis.

In our cohort there was nearly no difference in rates of AEs between patients with lower (GOOSS 0–1) or a higher (GOOSS 2–3) pre-procedural GOOSS (21% vs. 25%).

Detailed data about technical success, clinical success, and AEs are listed in ► **Table 2**.

### Discussion

Symptomatic GOO significantly impairs quality of life due to perseverative postprandial nausea and increasing inability to ingest food orally. EUS-GE appears to be a promising, less invasive and effective treatment option in the management of GOO leading to rapid postprocedural recovery and symptom relief [9].

Several specific techniques are used to perform EUS-GE, which can be divided into assisted procedures (EUS-guided double-balloon-occluded gastrojejunostomy, balloon-assisted or guidewire-assisted EUS-GE) and direct EUS-GE. Yet, it is not clear if one technique is superior to the other. Chen et al. [6] reported significantly lower procedure times (35.7 min vs. 89.9 min) in the direct EUS-GE group compared to the balloon-assisted group; technical and clinical success rates as well as the rate of adverse events did not differ. In our study, we used the modified so-called direct “free hand” EUS-GE and observed a high technical success rate of 98%, comparable to those for surgical GE and endoluminal stenting [2, 10].

Performing an EUS-GE remains a challenging intervention even for advanced endoscopists, and LAMS are still of off-label when used for EUS-GE. Particularly, the transperitoneal puncture of a mobile structure – specifically, the intestinal target loop which is collapsed in its natural condition – is associated with a severe risk for procedure-associated AEs, such as unintended intraperitoneal stent release with gastrostoma, and peritonitis. In addition, bleeding complications or accidental gastrocolic fistulas have been reported in recent meta-analyses [11].



► **Table 2** Technical success, clinical success, and adverse events.

Number of EUS-GE-attempts	45
▪ 1 attempt	39 (87%)
▪ 2 attempts	6 (13%)
Number of correctly placed LAMS	44 (98%)
▪ at 1st attempt	38 (84%)
▪ at 2nd attempt	6 (14%)
▪ Failed placement	1 (2%)
LAMS size (AXIOS)	
▪ 20 x 10 mm	30 (67%)
▪ 10 x 15 mm	14 (31%)
▪ 10 x 10 mm	1 (2%)
Clinical success	42 (95%)
Adverse events	11 (24%)
▪ Stent misplacement	7 (16%)
▪ Bleeding	2 (4%)
▪ Leakage	1 (2%)
▪ Gastrojejunal fistula	1 (2%)
Procedure related deaths	0 (0%)
Required reinterventions	8 (18%)
▪ Balloon dilatation	3 (6%)
▪ Stent in stent – dilatation	1 (2%)
▪ Stent in stent – bridging	2 (4%)
▪ Foreign body extraction	2 (4%)
▪ Placement of a 2 <sup>nd</sup> LAMS	1 (2%)
EUS-GE, endoscopic ultrasound-guided gastroenterostomy; LAMS, lumen apposing metal stent	

Independent of the technique, stent misplacement is one of the most often reported procedure failures; frequencies described range from 7% to 10% [4, 6, 10, 12, 13]. In our collective, it even initially occurred in 16% (7/45) of the interventions, but except for one case, EUS-GE succeeded in a second attempt during the same session (5/6) or in a separate procedure (1/6). Endoscopic clipping of the gastric defect was not routinely performed, but all patients received postprocedural antibiotics for at least 3 days, preventing further complications. The majority of stent misplacements (5/7; 71%) happened during procedures on the first half of the treated patients when direct EUS-GE was newly established. This strongly indicates that experienced interventional endoscopists also may have a learning curve when performing this procedure. The development of easily-applicable anchoring systems may also be desirable to increase stability and safety while puncturing.

In our cohort, one patient (1/45; 2%) developed peritonitis due to a jejunal leakage after a failed EUS-GE-attempt; the leakage, presumably, resulted from jejunal wall laceration caused

by the electrocautery enhanced catheter tip. This AE could be treated conservatively by antibiotics. Tyberg et al. reported one case of peritonitis with fatal course in a patient with distal flange misplacement despite over-the-scope-clipping of the gastric perforation site [14]. In meta-analyses, post-procedure peritonitis after EUS-GE occurs in 0% to 4% of cases [11], in line with our data.

In one patient, a gastrojejunal fistula (GJCF) occurred due to accidental trapping of collapsed colon while performing the puncture. It was bridged by a fully-covered stent from the stomach through the colon into the jejunum. In a meta-analysis, Iqbal et al. reported a gastrocolic fistula (GCF) in one of 285 cases, where the colon was accidentally punctured instead of the intestinal loop. Closure of the GCF was successfully carried out by endoscopic suturing [5, 11]. Optimal dilatation and visualization of the target structure via fluid filling is of great importance to avoid misplacement. Additional rectal application of contrast agent might help distinguish colon from intestinal loops.

Our observed numbers of bleeding-related AEs (4%) were comparable to numbers reported by Iqbal et al [11] (1%). However, one patient required intensive care treatment and blood transfusion due to an extraluminal bleeding with missing endoscopic treatment option; the case could still be managed conservatively. Chavan et al. reported a case of luminal and extraluminal bleeding during EUS-guided double balloon-occluded gastrojejunostomy in a patient with portal hypertension with extensive perigastric collaterals. Luminal bleeding at the gastric and jejunal site could be stopped by endoscopically applied hemoclips. The extraluminal hematoma near the proximal jejunum revealed by a post-procedure computed tomography scan was also treated conservatively with packed cell transfusion, IV antibiotics, and analgesic agents, leading to clinical recovery [15]. Generally, a thorough endoscopic ultrasound investigation should allow sufficient identification of vessels at possible puncture sites. Obvious vessel interposition must be considered as contraindication for EUS-GE, requiring termination of the intervention if no safe puncture site can be outlined.

After technically successful EUS-GE, rapid symptom relief and restoration of ability to ingest food orally was observed in 95% of patients, comparable to those reported after surgical GE and endoluminal stenting. A mean post-procedural hospitalization time of 5 days in our study was remarkably shorter than recovery time after surgical approaches, with a mean length of stay of 10 to 12 days [12, 16].

Because most of the patients in our cohort suffered from a malignant disease in an advanced stage, weight loss could not be prevented in these cases throughout the follow-up period. However, enabling oral food intake preserves quality of life, which is encountered as a basic objective in a palliative setting. Once clinical success is achieved by EUS-GE it appears to be persistent. Tumor ingrowth into the stent or stent dislocation was not observed in our cohort. Similar data were reported in recent meta-analyses by Iqbal et al. [11] and Chandan et al. [9] with clinical success rates of 90.0% to 93.3%. Stent occlusion by foreign bodies, which occurred in two patients (stent size: 15×10 mm and 20×10 mm), could be managed with gastro-

scopic extraction with no complications. A large luminal stent diameter (20 mm) may appear to be advantageous to achieve the best prospects for clinical success, but in our study, patients treated with smaller LAMS (10 mm/15 mm) also benefited from the intervention.

Because we only treated four patients with benign GOO with EUS-GE, it is not possible to derive representative evidence about long-term effectiveness and safety. However, in these cases there were no signs of deteriorating stent functionality throughout the whole follow-up period of 177 days on average. A study of Chadan et al. evaluating EUS-GE in management of benign GOO reported clinical success in 21 of 25 patients (84%) at a median follow-up of 177 days (47–445). In two cases, elective stent removal was performed 12 weeks after EUS-GE; one of these removals was complicated by a gastric leak requiring surgery [13]. In our cohort, LAMS extraction was successfully performed by a forceps without complications in one patient after 14 months who had recovered from benign GOO caused by necrotic pancreatitis.

Our study is restricted by some limitations. We only performed a retrospective analysis of consecutive interventions performed in two specialized referral centers with significant expertise in interventional EUS at which EUS-GE is performed routinely. Thus, the high rates of technical success and solely endoscopic management of possible AEs is not necessarily transferrable to smaller centers with less volume and expertise with such interventions. The new concept of EUS-GE seems to have advantages in comparison to surgical GE regarding patient comfort and recovery with a reasonable risk-benefit ratio. However, only prospective randomized trials comparing EUS-GE versus conservative an endoscopic stent approach and versus surgical GE can answer the question about which approach is truly most favorable. Furthermore, prospective studies should be conducted of the outcome of patients with benign GOO treated with EUS-GE.

## Conclusions

In conclusion, direct “free hand” EUS-GE with LAMS results in high technical and clinical success rates for patients with GOO. Thus, it should be considered as a treatment alternative to surgical GE and endoluminal stenting, particularly in patients for whom surgery is high risk or in palliative settings due to rapid symptom relief and short hospitalization time. Because most AEs were caused by stent misplacement (7/11; 64%), which could be managed conservatively or by endoscopic reintervention, the overall risk-benefit profile seems acceptable, particularly compared to more invasive surgical alternatives. However, EUS-GE remains a sophisticated intervention requiring advanced endosonographic experience and knowledge about strategies for management of complications to maximize safety.

## Competing interests

The authors declare that they have no conflict of interest.

## References

- [1] Takeno A, Takiguchi S, Fujita J et al. Clinical outcome and indications for palliative gastrojejunostomy in unresectable advanced gastric cancer: multi-institutional retrospective analysis. *Ann Surg Oncol* 2013; 20: 3527–3533
- [2] Nagaraja V, Eslick GD, Cox MR. Endoscopic stenting versus operative gastrojejunostomy for malignant gastric outlet obstruction—a systematic review and meta-analysis of randomized and non-randomized trials. *J Gastrointest Oncol* 2014; 5: 92–98
- [3] Binmoeller KF, Shah JN. Endoscopic ultrasound-guided gastroenterostomy using novel tools designed for transluminal therapy: a porcine study. *Endoscopy* 2012; 44: 499–503
- [4] Itoi T, Ishii K, Ikeuchi N et al. Prospective evaluation of endoscopic ultrasonography-guided double-balloon-occluded gastrojejunostomy bypass (EPASS) for malignant gastric outlet obstruction. *Gut* 2016; 65: 193–195
- [5] Kerdsirichairat T, Irani S, Yang J et al. Durability and long-term outcomes of direct EUS-guided gastroenterostomy using lumen-apposing metal stents for gastric outlet obstruction. *Endosc Int Open* 2019; 7: E144–e150
- [6] Chen YI, Kunda R, Storm AC et al. EUS-guided gastroenterostomy: a multicenter study comparing the direct and balloon-assisted techniques. *Gastrointest Endosc* 2018; 87: 1215–1221
- [7] Adler DG, Baron TH. Endoscopic palliation of malignant gastric outlet obstruction using self-expanding metal stents: experience in 36 patients. *Am J Gastroenterol* 2002; 97: 72–78
- [8] Cotton PB, Eisen GM, Aabakken L et al. A lexicon for endoscopic adverse events: report of an ASGE workshop. *Gastrointest Endosc* 2010; 71: 446–454
- [9] Chadan S, Khan SR, Mohan BP et al. EUS-guided gastroenterostomy versus enteral stenting for gastric outlet obstruction: Systematic review and meta-analysis. *Endosc Int Open* 2021; 9: E496–E504
- [10] Ge PS, Young JY, Dong W et al. EUS-guided gastroenterostomy versus enteral stent placement for palliation of malignant gastric outlet obstruction. *Surg Endosc* 2019; 33: 3404–3411
- [11] Iqbal U, Khara HS, Hu Y et al. EUS-guided gastroenterostomy for the management of gastric outlet obstruction: A systematic review and meta-analysis. *Endosc Ultrasound* 2020; 9: 16–23
- [12] Khashab MA, Bukhari M, Baron TH et al. International multicenter comparative trial of endoscopic ultrasonography-guided gastroenterostomy versus surgical gastrojejunostomy for the treatment of malignant gastric outlet obstruction. *Endosc Int Open* 2017; 5: E275–E281
- [13] Chen YI, James TW, Agarwal A et al. EUS-guided gastroenterostomy in management of benign gastric outlet obstruction. *Endosc Int Open* 2018; 6: E363–E368
- [14] Tyberg A, Perez-Miranda M, Sanchez-Ocaña R et al. Endoscopic ultrasound-guided gastrojejunostomy with a lumen-apposing metal stent: a multicenter, international experience. *Endosc Int Open* 2016; 4: E276–E281
- [15] Chavan R, Ramchandani M, Nabi Z et al. Luminal and extraluminal bleeding during EUS-guided double-balloon-occluded gastrojejunostomy bypass in benign gastric outlet obstruction with portal hypertension. *VideoGIE* 2020; 5: 64–67
- [16] Fiori E, Lamazza A, Volpino P et al. Palliative management of malignant antro-pyloric strictures. Gastroenterostomy vs. endoscopic stenting. A randomized prospective trial. *Anticancer Res* 2004; 24: 269–271