

Coats' disease of adult-onset in 48 eyes

Ekta Rishi, Pukhraj Rishi, Bindu Appukuttan, Mahesh Uparkar, Tarun Sharma, Lingam Gopal

Background: Coats' disease diagnosed in adulthood is an idiopathic, retinal exudative vascular disease without an inciting factor and has retinal features different from the childhood disease. **Aim:** To describe clinical features, treatment, and outcomes of eyes with Coats' disease first diagnosed in patients 35 years or older. **Materials and Methods:** Retrospective chart review of patients first diagnosed with Coats' disease at the age of 35 years or more at a tertiary eye care center between January 1995 and 2012. Eyes with retinal exudation or Coats'-like response from secondary causes were excluded. **Results:** Forty-five of 646 patients (7%) diagnosed with Coats' disease had adult-onset disease. Mean age at presentation was 47 years. Systemic hypertension was the most common (22%) systemic association and decreased vision the predominant presenting feature (83%). Localized (<6 clock h) presentation (74%) was unique to adults as against diffuse involvement (69%) in children ($P < 0.001$). Eyes were treated with laser photocoagulation 29 (60%), cryotherapy (4%), or both (2%) with surgical intervention in three (6%) eyes. Following treatment eight (35%) eyes improved, 11 (48%) eyes were stable while four (12%) eyes worsened due to complications. **Conclusion:** Adult-onset Coats' disease has less extensive involvement, more benign natural course, and a more favorable treatment outcome as against the childhood-onset disease. The bilateral presentation emphasizes the need for regular follow-up to detect possible future involvement of the fellow eye.

Key words: Adult, Coats' disease, retina, retinal telangiectasia

The classic description of Coats' disease is reported among young male subjects and the disease diagnosed in adulthood is a rare entity.^[1-4] It is possible to detect a Coats'-like response in patients with ocular inflammation, infection, retinal degeneration, and postradiation therapy. However, a clear history and distinct clinical presentation help differentiate such patients from the "idiopathic" form of retinal exudation with telangiectasia that characterize Coats' disease.^[5] Systemic conditions such as hypertension, diabetes mellitus, and hypercholesterolemia have been reported with adult-onset Coats' disease,^[6] whereas no such association has been reported with the childhood-onset disease. Coats' disease diagnosed in adulthood is an idiopathic, retinal exudative vascular disease without an inciting factor and has retinal features different from the childhood disease [Fig. 1].^[7-13] Vascular abnormalities are often present in both peripheral as well as juxtamacular areas and adults more commonly demonstrate localized lipid deposition, hemorrhage around macroaneurysms, and slower disease progression.

There is very few information in the published literature about Coats' disease of adult-onset. Most of the reports exist in the form of isolated case reports or small case series.^[6-11,14-16] We have earlier published our data of Coats' disease in 307 eyes,^[12] and the present study aims to fill gaps in our current knowledge about Coats' disease of adults-onset in terms of disease presentation and treatment outcomes.

Shri Bhagwan Mahavir Vitreoretinal Services, Sankara Nethralaya, Chennai, Tamil Nadu, India

Correspondence to: Dr. Pukhraj Rishi, Shri Bhagwan Mahavir Vitreoretinal Services, Sankara Nethralaya, 18 College Road, Chennai - 600 006, Tamil Nadu, India. E-mail: docrishi@yahoo.co.in

Manuscript received: 10.01.14; **Revision accepted:** 19.02.16

Access this article online

Website:

www.ijo.in

DOI:

10.4103/0301-4738.190141

Quick Response Code:



Materials and Methods

A retrospective chart review of patients diagnosed with Coats' disease of adult-onset at a tertiary care center between January 1995 and January 2012 was carried out. All methods adhered to the tenets of the Declaration of Helsinki for research involving human subjects. As per the existing institutional policy at the time of the study, Ethics Committee clearance was not deemed necessary at our institute in view of the retrospective nature of the study. Patients first diagnosed with Coats' disease at 35 years of age or more were included. This criterion was based on our previous series on Coats' disease with a bimodal peak of presentation, the second peak being beyond 35 years of age. Supposedly, this approach would also help decrease the possibility of including cases that actually began during childhood or adolescence. Six hundred and forty-six patients were diagnosed with Coats' disease. Among these, 45 patients (48 eyes) had Coats' disease of adult-onset. A complete history with special attention to systemic disease (systemic hypertension, diabetes mellitus, dyslipidemia, etc.) was elicited.

Clinical parameters which were evaluated included best-corrected visual acuity, intraocular pressure (IOP), and

This is an open access article distributed under the terms of the Creative Commons Attribution-NonCommercial-ShareAlike 3.0 License, which allows others to remix, tweak, and build upon the work non-commercially, as long as the author is credited and the new creations are licensed under the identical terms.

For reprints contact: reprints@medknow.com

Cite this article as: Rishi E, Rishi P, Appukuttan B, Uparkar M, Sharma T, Gopal L. Coats' disease of adult-onset in 48 eyes. Indian J Ophthalmol 2016;64:518-23.

anterior and posterior segment features. Coats' disease was diagnosed if an eye had idiopathic retinal telangiectasia with or without intra- or sub-retinal exudation. Retinal telangiectasia was defined as abnormal dilatation of the terminal precapillary vessels often present in clusters and possibly associated with exudation or subretinal fluid. Retinal exudation was defined as discrete yellow subretinal/intraretinal deposits with sharp edges. We excluded patients with secondary causes of exudation and telangiectasia such as radiation retinopathy, retinal vascular occlusions, postinflammatory causes, and retinal capillary hemangioblastoma.

The disease extent was classified into three zones, the macula (area between the temporal vascular arcades) being zone 1, the mid-periphery, between the retinal vascular arcades and equator being zone 2, and the peripheral fundus anterior to this being zone 3. Staging of the disease was done based on the extent and the quadrant (s) of retina involved according to classification by Shields *et al.*^[2] Fundus fluorescein angiography confirmed active telangiectatic leakage, areas of capillary nonperfusion, and also helped rule out other differential diagnosis. Optical coherence tomography (OCT) was done in selected eyes depending on physician discretion. Ultrasound B-scan was performed when extensive bullous retinal detachment with exudation resulted in a diagnostic dilemma.

Treatment was advised if deemed necessary by the treating physician. Laser photocoagulation or cryotherapy was done to the leaking vascular lesions. Vitrectomy or scleral buckling along with laser photocoagulation or cryotherapy to the leaking areas was done for patients with rhegmatogenous or tractional retinal detachment. Operated patients were followed up on the first postoperative day, 1st week, 6 weeks, 6 months, and at 1 year. Patients in the observation group were followed up at 6 monthly intervals. At each follow-up, visual acuity (Snellen's chart), IOP, presence or absence of neovascular changes in the iris or angle, and fundus evaluation for disease progression were carried out.

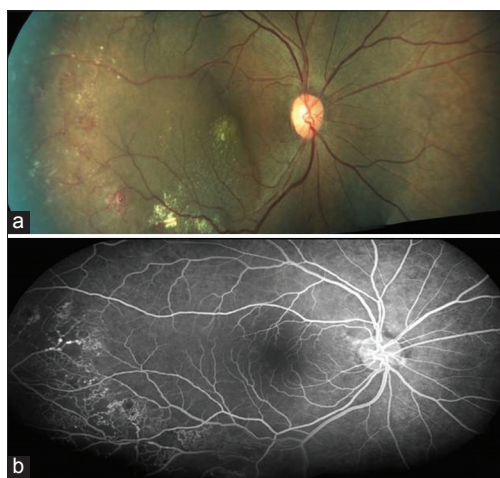


Figure 1: (a) Color fundus montage picture revealing telangiectasias in the temporal periphery with the presence of exudates and subretinal fluid. (b) Fundus fluorescein angiogram (arteriovenous phase) of the corresponding area depicting telangiectasias with typical light bulb appearance with areas of capillary nonperfusion

Visual improvement and worsening were defined as gain or loss of two or more lines on Snellen's chart while vision change <2 Snellen's lines was considered as stabilization of visual acuity. The Snellen's visual acuity was converted to logarithm of the minimum angle of resolution (logMAR) for the ease of statistical analysis. The resolution of telangiectasia, retinal exudation, status of the retina (attached or detached), and presence or absence of complications like neovascular glaucoma were determined. Based on follow-up examinations, the final ocular outcome (improved, stable, or worse) was assessed. Statistical analysis was done using parametric and nonparametric tests of significance to look for differences between presentations of adult-onset and childhood-onset Coats' disease and also for the difference between adult-onset Coats' disease in Indian and the Western counterparts. The SPSS version 13.0 (SPSS Science, Chicago, IL, USA) was used for statistical analysis.

Results

Between January 1995 and January 2012, 45 of 646 (7%) patients presenting at 35 years of age or above were diagnosed of Coats' disease, with 33 (73%) being males. The mean age at presentation was 47 years (range: 35–70 years). Systemic hypertension was the most common associated systemic condition in ten (22%) patients [Table 1]. Forty-two (93%) patients had unilateral presentation [Table 1] with diminution of vision being the most common presenting complaint in forty (83.3%) patients. Incidental diagnosis of Coats' disease was made in four (8%) patients [Table 2a]. The average duration of complaint (s) was 14 months (range: 10 days to 5 years). Family history was negative in all cases. Visual acuity recorded with Snellen's chart was converted to logMAR for ease of evaluation. Mean logMAR visual acuity was 1.13 ± 0.91 . Eighteen eyes (38%) had visual acuity of 20/60 (logMAR 0.47) or better [Table 2a]. Eighteen eyes (38%) had vision between 20/80 and 20/200 (logMAR 0.6–1), and 12 eyes (25%) had visual acuity worse than 20/200 (logMAR 1); three eyes had only light perception (LP) vision. Myopia was an ocular association in five (10%) eyes, whereas lattice degeneration was seen in two (4%) eyes. Anterior segment evaluation revealed the presence of a cataract in 13 (29%) eyes, exotropia in three (6%) eyes, and neovascular glaucoma in one (2%) eye. Details of fundus examination and the staging of Coats' disease are presented in

Table 1: Coats' disease of adult-onset in 48 eyes patient demographics

Demographics	Current series (n=45) (%)	Smithen <i>et al.</i> (n=13) (%)	P
Gender			
Males	33 (73.3)	12 (92)	0.148
Females	12 (26.6)	1 (8)	-
Mean age	47.2±8.1	50.4±11.6	0.366
Laterality			
Unilateral	42 (93.3)	13 (100)	0.439
Bilateral	3 (6.6)	0	-
Systemic associations	33 (73)	5 (38.4)	0.0210
No association	10 (22)	4 (30.7)	0.517
Systemic hypertension	10 (22)	2 (15.3)	0.831
Diabetes mellitus	2 (4)	2 (15.3)	0.146
Hypercholesterolemia	8 (18)	3 (23)	0.686

Table 2b and c. Features of OCT are summarized in Table 2d. None of the eyes showed the presence of vasoproliferative tumor.

Thirty-five (73%) eyes underwent treatment [Table 3] while 13 (27%) were observed. Laser photocoagulation to the

Table 2a: Differences in presenting symptoms among adult, pediatric, and Western subjects

Presenting features	Current series (1) n=48 eyes (%)	Smithen (2) n=13 eyes (%)	Pediatric (3) n=162 eyes (%)	P (1 vs. 2)	P (1 vs. 3)
Decreased vision	40 (83.3)	6 (46.1)	92 (56.7)	0.006	0.001
Leukocoria	0	0	62 (38.2)	-	-
Squint	4 (8.3)	0	52 (32)		0.001
Routine exam	4 (8.3)	3 (23)	1 (0.6)	0.139	0.002
Floater	3 (6.2)	4 (30.7)	0	0.0138	-
Painful blind eye	0	0	7 (4.3)	-	-
Scotoma	1 (2)	0	0	-	-
Presenting visual acuity \geq 20/40 (logMAR 0.3)	18 (37.5)	9 (69)	17 (10.4)	0.0425	<0.001

logMAR: Logarithm of the minimum angle of resolution

Table 2b: Differences in presenting signs among adult, pediatric, and Western subjects

Clinical presentation	Current series (1) n=48 eyes (%)	Smithen <i>et al.</i> (2) n=13 eyes (%)	Pediatric (3) n=162 eyes (%)	P (1 vs. 2)	P (1 vs. 3)
Telangiectasia	48 (100)	13 (100)	162 (100)	-	-
Macular	6 (12.5)	0	25 (15.4)	-	0.619
Peripheral	20 (41.6)	1 (7.6)	21 (12.9)	0.022	<0.001
Perimacular and peripheral	17 (35.4)	12 (92.3)	19 (11.7)	0.003	<0.001
Diffuse	5 (10.4)	0	97 (59.8)	-	<0.001
Exudates	45 (94)	13 (100)	161 (99.3)	-	-
Macular	12 (25)	0	25 (15.4)	-	0.125
Peripheral	19 (40)	1 (7.6)	20 (12.3)	0.028	<0.001
Perimacular and peripheral	22 (45.8)	12 (92.3)	19 (11.7)	0.003	<0.001
Diffuse	4 (8)	0	97 (59.8)	-	<0.001
Hemorrhages	11 (22.9)	10 (77)	7 (4.3)	<0.001	<0.001
Intraretinal hemorrhage	3 (6.2)	0	0	-	-
Preretinal hemorrhage	3 (6.2)	7 (62)	0	<0.001	-
Vitreous hemorrhage	5 (10.4)	0	7 (4.3)	-	0.110
Subretinal hemorrhage	0	2 (15)	0	-	-
Retinal detachment	10 (20.8)	4 (30.7)	127 (78.3)	0.451	<0.001

Table 2c: Differences in disease extent and severity among adult, pediatric, and Western subjects

Clinical features	Present series (1) n=48 eyes (%)	Smithen <i>et al.</i> (2) n=13 eyes (%)	Pediatric (3) n=162 eyes (%)	P (1 vs. 2)	P (1 vs. 3)
Stage of disease					
1	2 (4)	Data unavailable	1 (1)	-	0.156
2A	17 (34.6)		8 (4)	-	<0.001
2B	18 (37.5)		26 (16)	-	0.0013
3A1	3 (6)		18 (11)	-	0.307
3A2	3 (6)		12 (7)	-	0.809
3B	5 (10)		70 (43.2)	-	<0.001
4	0		24 (12)	-	-
5	0		3 (1)	-	-
Clock hours of fundus involvement (h)					
<3	15 (31.25)	3 (23.07)	9 (5.5)	0.566	<0.001
3-6	21 (43.7)	10 (76.9)	21 (12.9)	0.034	<0.001
12	6 (12.5)	2 (15.3)	111 (68.5)	0.025	<0.001

Table 2d: Summary of optical coherence tomography features in eight eyes with adult-onset Coats' disease

Age (years)	Sex	Laterality	OD/OS	VA baseline	OCT baseline	OCT posttreatment	Baseline foveal thickness (μ)	Remarks
49	Female	U/L	OD	20/60	IRT-D, SFF	IRT, IRCX, IRS with peaked scarring, and foveal contour maintained	357	VA improved to 20/30, foveal thickness improved to 186 μ at 7 months follow-up s/p focal laser photocoagulation
50	Male	U/L	OS	20/160	IRT-D, IRT-S, IRCX, PED, SRF	NA	329	VA improved to 20/120 at 8 months follow-up s/p focal laser photocoagulation
63	Male	U/L	OS	20/400	IRT-D, IRT-S, IRCX, RTV	Nil	1327	None
30	Male	U/L	OD	20/60	IRT-D, IRT-S, IRCX, FTn, XMRT	NA	96	VA changed to 20/80, at 5 months follow-up s/p focal laser photocoagulation
46	Male	U/L	OS	20/60	IRT-D, IRT-S, IRCX, XMRT	LMH, reduced RT	190	VA improved to 20/30 at 18 months follow-up s/p focal laser photocoagulation
46	Male	U/L	OD	20/400	IRT-D, IRT-S, IRCX, XMRT, FTn	NA	114	None
53	Female	U/L	OD	6/6	Normal	Normal	195	Peripheral laser photocoagulation
31	Male	U/L	OS	20/600	SRF	SRF	NA	VA was maintained at 8 months follow-up s/p focal laser photocoagulation

OD: Right eye, OS: Left eye, VA: Visual acuity, U/L: Unilateral, PVD: Posterior vitreous detachment, RT: Retinal thickness, IRT-D: Increased retinal thickness (diffuse), IRT-S: Increased retinal thickness (spongiform), SFF: Subfoveal fluid, SRF: Subretinal fluid, IRCX: Intraretinal clump of hard exudates, IRS: Intraretinal scarring, PED: Pigment epithelial detachment, RTV: Retinal telangiectatic vessel, FTn: Foveal thinning, XMRT: Extramacular retinal thickening, LMH: Lamellar macular hole, NA: Not available, s/p: Status post, CF: Counting fingers

Table 3: Differences in the management of adult, pediatric, and Western subjects with Coats' disease

Management	Current series n=48 eyes (%)	Smithen <i>et al.</i> n=13 eyes (%)	Pediatric n=162 eyes (%)	P (current vs. Smithen)	P (current vs. pediatric)
Observation	13 (27.08)	2 (15.3)	46 (28.3)	0.382	0.869
Laser	29 (60.4)	11 (84.6)	44 (27.16)	0.103	<0.001
Surgery	3 (6.2)	0	42 (25.9)	-	0.003
Cryotherapy	2 (4)	0	19 (11.7)	-	0.117
Laser + cryotherapy	1 (2)	0	2 (1.2)	-	0.677
Enucleation	0	0	16 (9.8)	-	-

telangiectatic vessels was the most common treatment modality used in 29 (60%) eyes. A single session of laser was adequate in 25 patients; two sessions in five patients and up to four sessions were required in two eyes. The pre- and post-treatment visual acuity of patients treated with a laser is depicted in Fig. 2. Eleven (23%) eyes presented with retinal detachment; five with total retinal detachment and six had subtotal detachment. Two eyes with total rhegmatogenous retinal detachment underwent surgical repair. Three eyes with long-standing detachment and atrophic retina were observed in view of the poor visual potential. Of the two patients, one was lost to follow-up after surgery. The other patient had a recent-onset total retinal detachment and was managed with scleral buckling plus vitrectomy and silicone oil endotamponade. He maintained a vision of 6/36 in this eye at 4 years of follow-up.

Subtotal retinal detachment was seen in six (13%) eyes (three eyes each with stage 3A1 and 3A2). Of these, four eyes underwent laser photocoagulation to telangiectatic vessels.

Among four eyes subjected to laser photocoagulation, two eyes showed improvement in visual acuity, one maintained same vision, while one was lost to follow-up. The remaining two eyes with retinal detachment required surgical intervention; one eye had vitrectomy with scleral buckling for nonresolving vitreous hemorrhage and tractional retinal detachment. This patient developed cataract and underwent phacoemulsification with intraocular lens implantation after 1½ years. His retinal condition and vision remained stable at the last follow-up. The second patient was treated with laser photocoagulation and encirclage for exudative retinal detachment and vitreoretinal traction. This patient was lost to follow-up after 2 months.

The mean follow-up of patients was 40 months (range: 1–122 months). Thirty-two (67%) eyes had a follow-up of more than 6 months. Of these, 23 (48%) eyes were treated and nine (15%) eyes were observed. A favorable structural outcome in the form of reduced exudation was seen in 13 (57%)

treated eyes versus three (33%) untreated eyes [Table 4]. With respect to the visual outcome, four (12%) eyes worsened due to the presence of multiple complications such as glaucoma, disc pallor, recurrent retinal detachment, persistent macular edema, and macular scarring [Fig. 3]. It was decided to observe the eyes not amenable to treatment, eight (88%) such eyes maintained vision, one (11%) worsened but none of them improved. Glaucoma was the most common complication in four (8%) eyes, three eyes developed secondary angle closure in treated group, and one eye developed neovascular glaucoma in the untreated group. Retinal detachment was seen in two eyes and vitreous hemorrhage in one eye. None of the eyes progressed to painful blind eye necessitating enucleation.

A comparative analysis of the presenting features between the childhood^[12] and adult-onset Coats' disease was done and also compared to the published literature [Table 2].^[6] Adult-onset Coats' disease was found to have more localized presentation with 36 (74%) eyes having ≤ 2 quadrant of involvement. Comparing the treatment and outcomes [Table 3], more adults were treatable with laser (60% vs. 27%, $P < 0.001$) and surgery was required in only three eyes (6% vs. 26%, $P < 0.003$). None of the eyes required enucleation (0 vs. 10%) when compared with the pediatric series. Visual outcomes in published literature were significantly better than the current

series as the presenting visual acuity was better to begin with (69% vs. 38%, $P = 0.04$) [Table 2].

Discussion

Coats' disease is a disease typically seen in childhood and less commonly among adults.^[6] Bilaterality (7% vs. 0%) and increased female affection (27% vs. 7%) were noticeable in our series [Table 1] than in the published literature.^[16] Decreased vision was the most common presenting complaint (83%) probably due to more prevalent macular involvement in our subjects. Our series, as well as published literature, show that leukocoria is never a presenting feature in adults as the disease is never that extensive and also probably due to earlier diagnosis in adults as compared to children. Systemic associations observed in our series were similar to the series by Smithen *et al.*^[6] with systemic hypertension being the most common followed by diabetes mellitus and hypercholesterolemia [Table 1]. Anterior segment abnormalities like cataract, exotropia, and neovascular glaucoma were unique to our series and not reported by Smithen *et al.*^[6] Hemorrhage was seen in fewer eyes in our series (18% vs. 77%). Preretinal and subretinal hemorrhages were commonly noted and vitreous hemorrhage was an unusual presenting feature noted in the current series. It has been postulated by Tripathi and Ashton^[13] that retinal capillary nonperfusion, vessel wall changes, breakdown of the blood-retinal barrier could be the causes for hemorrhage from microaneurysms or macroaneurysms.

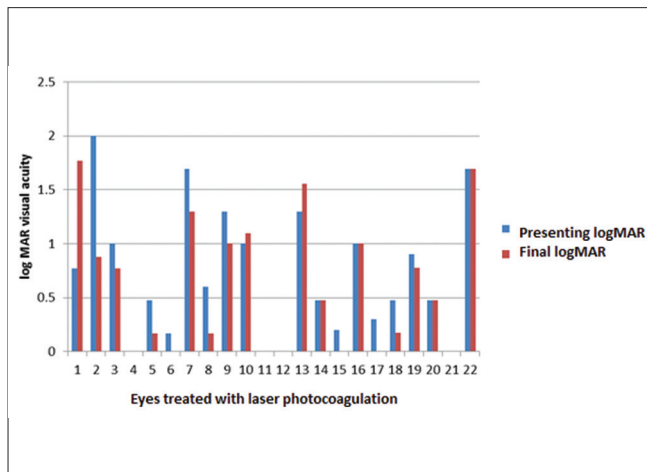


Figure 2: Bar diagram depicting the pre- and post-treatment visual acuity of eyes treated with laser photocoagulation

Table 4: Difference in outcomes between treated and untreated eyes with adult-onset Coats' disease at final follow-up

Visual outcome	Untreated <i>n</i> =9 eyes (%)	Treated <i>n</i> =23 eyes (%)	<i>P</i> (<i>P</i> <0.05)
Functional outcome			0.023
Improved (>2 Snellen line improvement)	0 (0)	8 (34.7)	-
Same	8 (88)	11 (47.8)	-
Worsened (>2 Snellen line decrease)	1 (11)	4 (17.3)	-
Anatomical outcome			
Exudates reduced	3 (33)	13 (56.5)	0.232
Retina attached	6 (66)	22 (95.6)	0.023

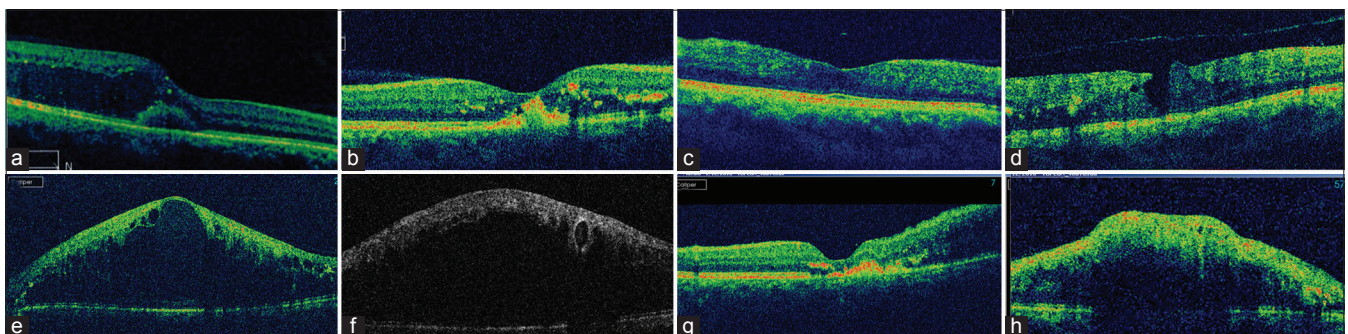


Figure 3: (a) Diffuse retinal thickness with subfoveal fluid (b) following treatment foveal thickness reduced with a resolution of fluid and subretinal scarring (c) near normal macula at presentation (d) lamellar macular hole and chronic cystoid changes developed despite laser to peripheral lesions. (e) Diffuse and spongiform retinal thickness with massive schitic changes (f) line scan through telangiectatic vessel shows area of signal void with shadowing (g) subfoveal scarring and adjacent diffuse retinal thickening (h) line scan through organized retinal exudation reveals increased retinal thickening with shadowing and back-scattering

The presence of <2 quadrant involvement in adults as against the diffuse involvement in the childhood disease [Table 2c] probably explains why the disease is milder with slower progression in adults as against the childhood-onset disease, which is known to be rapidly progressive, often presenting with end-stage complications such as total retinal detachment or neovascular glaucoma leading to phthisis bulbi or painful blind eye.^[6,12] Although not statistically significant, the results are very encouraging when compared with the outcome of treatment in the classic childhood disease. Neovascular glaucoma, a dreaded complication of untreated childhood Coats' disease,^[3,12] was seen in only one of the adult patients in this series. The few older adults in the series by Shields *et al.*^[3] had findings identical to the children in that series, and they had no other underlying conditions to predispose to exudative retinopathy.

Exudative retinal detachment in our series responded to laser or cryotherapy similar to series by Smithen *et al.*^[6] where all four patients responded well to laser. Three patients in our series necessitated surgical intervention due to the development of breaks/traction at the site of telangiectasia. None of the patients required surgical intervention in the series by Smithen *et al.* Antivascular endothelial growth factor (VEGF) has also been tried in several cases as an adjunct to treatment modalities like laser and cryotherapy.^[10] However, Ramasubramanian and Shields^[17] have advised caution in the use of anti-VEGF as they observed vitreoretinal traction and progressive tractional detachment in their series. Anti-VEGF was not used in any of our patients. In our series, loss of vision was mainly attributable to factors such as glaucoma (secondary angle closure), disc pallor, recurrent retinal detachment, persistent macular edema, and macular scarring, whereas Smithen *et al.*^[6] observed persistent macular edema, epiretinal membrane, and foveal ischemia as the causes for visual loss.

Distinct features in our series included bilateral presentation, presence of anterior segment changes (cataract and exotropia), more frequent macular involvement, vitreous hemorrhage, relatively poor visual acuity at presentation, and exudative retinal detachment with associated tractional or rhegmatogenous component necessitating surgical intervention. Genetic and other demographic factors may underlie these differences. We did not have a genetic workup done in any of our cases. Larger studies with a comprehensive genetic workup may reveal these disparities.

Conclusion

Just like the childhood-onset disease, retinal exudation and telangiectasia remain the hallmarks for diagnosis in adult-onset Coats' disease too, though with less extensive involvement, more benign natural course and a more favorable treatment outcome. Disease progression and possible bilateral affection underscores the need for long-term follow-up.

Financial support and sponsorship

Nil.

Conflicts of interest

There are no conflicts of interest.

References

1. Coats G. Forms of retinal disease with massive exudation. R Lond Ophthalmol Hosp Rep 1908;17:440-525.
2. Shields JA, Shields CL, Honavar SG, Demirci H, Cater J. Classification and management of Coats disease: The 2000 proctor lecture. Am J Ophthalmol 2001;131:572-83.
3. Shields JA, Shields CL, Honavar SG, Demirci H. Clinical variations and complications of Coats disease in 150 cases: The 2000 Sanford Gifford memorial lecture. Am J Ophthalmol 2001;131:561-71.
4. Shields JA, Shields CL. Review: Coats disease: The 2001 LuEsther T. Mertz lecture. Retina 2002;22:80-91.
5. Kan E, Yilmaz T, Aydemir O, Güler M, Kurt J. Coats-like retinitis pigmentosa: Reports of three cases. Clin Ophthalmol 2007;1:193-8.
6. Smithen LM, Brown GC, Brucker AJ, Yannuzzi LA, Klais CM, Spaide RF. Coats' disease diagnosed in adulthood. Ophthalmology 2005;112:1072-8.
7. Jarin RR, Teoh SC, Lim TH. Resolution of severe macular oedema in adult Coat's syndrome with high-dose intravitreal triamcinolone acetate. Eye (Lond) 2006;20:163-5.
8. Vázquez-Pulido N, Laliena Santamaría JL, Del Buey Sayas MA, Burdeus Gómez R, Osan Tello M. Adult-onset of recurrent Coats disease. Arch Soc Esp Oftalmol 2007;82:555-8.
9. Jun JH, Kim YC, Kim KS. Resolution of severe macular edema in adult Coats' disease with intravitreal triamcinolone and bevacizumab injection. Korean J Ophthalmol 2008;22:190-3.
10. Goel N, Kumar V, Seth A, Raina UK, Ghosh B. Role of intravitreal bevacizumab in adult onset Coats' disease. Int Ophthalmol 2011;31:183-90.
11. Beselga D, Campos A, Mendes S, Carvalheira F, Castro M, Castanheira D. Refractory Coats' disease of adult onset. Case Rep Ophthalmol 2012;3:118-22.
12. Rishi P, Rishi E, Uparkar M, Sharma T, Gopal L, Bhende P, *et al.* Coats' disease: An Indian perspective. Indian J Ophthalmol 2010;58:119-24.
13. Tripathi R, Ashton N. Electron microscopical study of Coat's disease. Br J Ophthalmol 1971;55:289-301.
14. Otani T, Yasuda K, Aizawa N, Sakai F, Nakazawa T, Shimura M. Over 10 years follow-up of Coats' disease in adulthood. Clin Ophthalmol 2011;5:1729-32.
15. Andonegui J, Aranguren M, Berástegui L. Coats disease of adult onset. Arch Soc Esp Oftalmol 2008;83:117-20.
16. Kim J, Park KH, Woo SJ. Combined photodynamic therapy and intravitreal bevacizumab injection for the treatment of adult Coats' disease: A case report. Korean J Ophthalmol 2010;24:374-6.
17. Ramasubramanian A, Shields CL. Bevacizumab for Coats' disease with exudative retinal detachment and risk of vitreoretinal traction. Br J Ophthalmol 2012;96:356-9.