

A study of the analgesic efficacy of rectus sheath block in single-port total laparoscopic hysterectomy: a randomized controlled study

Journal of International Medical Research

2022, Vol. 50(10) 1–10

© The Author(s) 2022

Article reuse guidelines:

sagepub.com/journals-permissions

DOI: 10.1177/03000605221133061

journals.sagepub.com/home/imr



Byung Jo Choi¹, Se Gyu Choi²,
Ohnchae Ryeon² and Woojin Kwon² 

Abstract

Objective: To investigate the postoperative analgesic effects of rectus sheath block (RSB) in combination with patient-controlled analgesia (PCA) compared with PCA alone after single-port total laparoscopic hysterectomy (TLH)

Methods: This randomized, single-blind study enrolled female patients that underwent single-port TLH. The patients were randomized to receive either fentanyl PCA (PCA group) or RSB with the same PCA. The primary outcomes were fentanyl consumption at 8 h postoperatively and visual analogue scale (VAS) pain scores, which represented the severity of postoperative pain.

Results: A total of 36 patients were enrolled in the study: 18 in the PCA group and 18 in the RSB group (two patients were excluded). The primary outcome of fentanyl consumption was significantly lower at 8 h postoperatively in the RSB group than in the PCA group ($148 \pm 61 \mu\text{g}$ versus $222 \pm 107 \mu\text{g}$, respectively). VAS scores were significantly lower at arrival in the post-anaesthesia care unit and at 30 min after arrival in the RSB group compared with the PCA group. There were no significant differences in the nausea/vomiting score and in additional analgesic consumption between the two groups.

Conclusions: RSB can be used as a multimodal approach for pain control in single-port TLH procedures.

Clinical Research Information Service (no. KCT0001461).

¹Department of Surgery, Daejeon St. Mary's Hospital, College of Medicine, The Catholic University of Korea, Daejeon, Republic of Korea

²Department of Anaesthesiology and Pain Medicine, Daejeon St. Mary's Hospital, College of Medicine, The Catholic University of Korea, Daejeon, Republic of Korea

Corresponding author:

Woojin Kwon, Department of Anaesthesiology and Pain Medicine, Daejeon St. Mary's Hospital, The Catholic University of Korea, 64 Daeheung-ro, Jung-gu, Daejeon, 34943, Republic of Korea.

Email: ankwon81@catholic.ac.kr



Creative Commons Non Commercial CC BY-NC: This article is distributed under the terms of the Creative

Commons Attribution-NonCommercial 4.0 License (<https://creativecommons.org/licenses/by-nc/4.0/>) which permits non-commercial use, reproduction and distribution of the work without further permission provided the original work is attributed as specified on the SAGE and Open Access pages (<https://us.sagepub.com/en-us/nam/open-access-at-sage>).

Keywords

Acute pain service, hysterectomy, laparoscopic surgery, gynaecological operation, visual analogue scale, rectus sheath block

Date received: 18 May 2022; accepted: 27 September 2022

Introduction

Rectus sheath block (RSB) has been widely used as a pain control method in procedures involving the abdominal wall. It is administered by injecting local anaesthetics between the abdominal rectus muscle and posterior rectus sheath and acts by blocking sensations from the anterior cutaneous nerve of the dorsal root of the T12 spinal nerve at the level of T7.¹⁻³ Conventional methods used previously included the two-pop technique, which involved feeling for a loss of resistance when the needle penetrated the anterior rectus sheath and posterior rectus sheath; however, it was not certain as to whether anaesthesia was achieved in the correct location and this method presented a risk of peritoneal puncture. Accurate needle positioning and pattern of spread of the anaesthesia can be seen in ultrasound (US)-guided RSB techniques, due to increased levels of safety, reproducibility and a higher success rate than the conventional method.^{4,5} This new method, a fascia plane block, has been reinvented as laparoscopic surgery has become a more popular procedure.

Ultrasound-guided RSB is known to be a useful neural block for postoperative pain control in the surgical treatment of umbilical and paraumbilical hernias.^{2,3,6,7} In gynaecological laparoscopy operations, it has been reported that RSB reduced postoperative pain more effectively as compared with a group that received no nerve block and another that received either intraperitoneal or incisional local filtration.⁸⁻¹¹

Since the visual analogue scale (VAS) pain scoring system is a subjective opinion of the patient there is interindividual variation and researcher bias can occur when obtaining the data. In this current study, if the postoperative pain was severe in the RSB group it may be an ethical problem, but it could be solved because intravenous (i.v.) analgesics were additionally injected whenever there was pain via patient-controlled analgesia (PCA). Both groups were given i.v. PCA and the opioid consumption was compared between the two groups so that postoperative pain could be assessed accurately.

To the best of our knowledge, no research has been undertaken on the effects of RSB following a single-port total laparoscopic hysterectomy (TLH). Therefore, this current randomized, single-blind study investigated the postoperative analgesic effects of RSB after a single-port TLH. This study aimed to demonstrate the effectiveness of the RSB as a multimodal analgesic procedure, using opioid consumption and VAS score as the main outcomes.

Patients and methods

Study population

This randomized, single-blind study enrolled patients in the Department of Anaesthesiology and Pain Medicine, Daejeon St. Mary's Hospital, College of Medicine, The Catholic University of Korea, Daejeon, Republic of Korea

between June 2015 and November 2015. The inclusion criteria were as follows: (i) females within an age range of 19–70 years; (ii) patients that underwent single-port TLH. The exclusion criteria were as follows: (i) patients with characteristics or underlying diseases unacceptable to this study, such as clinically considerable blood clotting disorders, infection at the procedure site, allergies to local anaesthetics, severe cardiovascular problems, American Society of Anesthesiologists (ASA) classification ≥ 3 , body mass index (BMI) $\geq 35 \text{ kg/m}^2$, diabetic neuropathy, intake of chronic pain medication and suspected malignancies; (ii) operation took $>3 \text{ h}$; (iii) TLH changed from single-port to multi-port during surgery.

Patients were randomly assigned to the RSB group or PCA group upon entry into the operating room using a computer program that created a random number table and number assignments were sealed in individual envelopes. The research coordinator opened a sealed envelope for each individual to assign them either to the PCA or RSB group, after which he or she informed the practitioner as to which group the patient belongs. All TLH procedures were performed by three skilled gynaecologists that have gained expertise in TLH surgery for more than 10 years. In order to reduce bias, the researchers were divided into two groups as well, that of practitioners and evaluators, and each group had an independent role, as described as follows: (i) practitioner: if assigned to the RSB group, the practitioner prepared the i.v. PCA drug as well as the local anaesthetic for the RSB, and the syringe containing the local anaesthetic was labelled 'i.v. prohibition, patient name and for research use'. If assigned to the PCA group, the practitioner arranged for the patient to only receive the i.v. PCA drug; (ii) evaluator: the evaluator studied and collected various data from all the patients including the pain

scores, opioid consumption and side-effects. The evaluators were blinded to the group assignment information of each patient.

This study was approved by Daejeon St. Mary's hospital institutional review board (no. DC13OISI0076; approval date was 3 March 2015). Written informed consent was obtained from all patients participating in the study. The trial was registered prior to patient enrolment at Clinical Research Information Service (no. KCT0001461). This manuscript adheres to the applicable CONSORT guidelines. An anaesthesiologist visited the patients 1 day before the surgery, gave a thorough explanation of the procedures and its risks, and obtained informed written consent from all patients. All patients underwent a routine preoperative evaluation, along with the collection of information on demographic characteristics and medical/surgical history, a physical examination and a routine laboratory blood test.

Study protocol

General anaesthesia was induced with 2 mg/kg propofol and 0.8 mg/kg rocuronium followed by tracheal intubation with a 7.0 mm tube. Intraoperative anaesthesia was maintained with desflurane 1 MAC so that the bispectral index value was in a range between 40–60 and remifentanyl was used as an additional anaesthetic, adjusted to a dose of $0.07 \mu\text{g/kg}$ per min according to the blood pressure, which was maintained within 30% relative to the mean blood pressure at the time of admission. After induction of anaesthesia, 5 mg dexamethasone (Dexamethasone[®]; Huons BioPharma, Seongnam, Republic of Korea) and 0.3 mg ramosetron (Astellas Pharma Inc., Tokyo, Japan) were injected intravenously to prevent postoperative nausea and vomiting. Ten minutes before the end of the surgery, $1 \mu\text{g/kg}$ fentanyl was injected intravenously.

Ultrasound-guided RSB technique

After post-surgical dressing, the practitioner prepared to perform RSB in the relevant group, while maintaining inhalation anaesthetic. The patient was laid in a supine position and the site of injection was disinfected using chlorhexidine. All nerve blocks were performed using an US machine (WS80A; Samsung Medison, Seoul, Republic of Korea) with a linear array transducer (3–12 MHz). First, the rectus sheath muscle was located by aligning the US probe with the lateral side of the umbilicus. The anterior and posterior rectus sheath covering the top and bottom of the abdominal rectus muscle was also located and a colour Doppler was used to identify the inferior epigastric vessels so as not to damage them during needle insertion (Figure 1). A 22G tuohy needle (TaeChang Industrial, Useong-myeon, Republic of Korea) was inserted at a 30° angle using the in-plane technique, from the left lateral abdominal wall to the medial side. After placing the needle between the rectus muscle and the posterior rectus sheath, a small dose (1 ml) of local anaesthetic was injected to confirm that the two layers were well separated. If yes, a total of 20 ml of local anaesthetic (0.375% ropivacaine) was administered. If not, the tip of the needle was carefully advanced until the optimal layer separation was achieved. Similarly, on the right, the same procedure was repeated. The total amount of fentanyl used was 10 µg/kg and 0.3 mg ramosetron was added to 100 ml normal saline. The PCA machine (Hospira Gemstar infusion pump; Hospira, Lake Forest, IL, USA) was set using the following parameters: fentanyl 0.5 µg/kg for bolus, 5-min lock time, 4-h total dose of 200 µg/kg and no background infusion.

Postoperative care

Postoperatively, patients were transferred to the post-anaesthesia care unit (PACU).

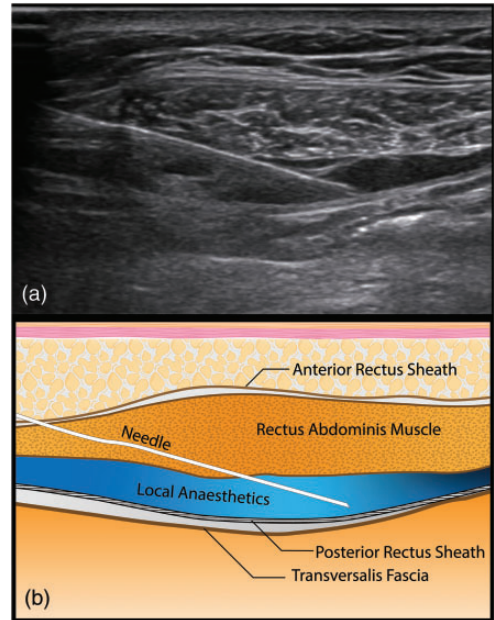


Figure 1. Ultrasound image (a) and corresponding schematic diagram (b) of ultrasound-guided rectus sheath block showing that the needle is inserted from the lateral abdominal wall using the in-plane technique. Local anaesthetic agent is diffused between the rectus abdominis muscle and posterior rectus sheath. The colour version of this figure is available at: <http://imr.sagepub.com>.

The highest pain and nausea/vomiting score was recorded at 15-min. Pain levels were scored using a VAS scoring system as follows: VAS 0 means no pain, whereas a score of 10 means the most extreme pain imaginable. If the pain score was >4 on the VAS, 30 mg ketorolac was injected intravenously. If the pain still persisted for 30 min (VAS: > 4), 50 mg tramadol i.v. was administered by the attending anaesthetist.

All patients followed the routine Acute Pain Service protocol after being transferred to a ward after surgery on the same day. Oral 80 mg zaltoprofen was taken in the evening of the first operative day. From the next day, 80 mg zaltoprofen was taken orally three times a day and PCA was maintained for 48 h. If the patient

complained of persistent pain, rescue 30 mg ketorolac i.v. and 50 mg tramadol i.v. were also administered, similar to what was done in the PACU.

Antiemetic drugs were administered according to a routine protocol. The first-line rescue treatment was 10 mg metoclopramide i.v.. On the day of surgery, 0.3 mg ramosetron i.v. and 5 mg dexamethasone i.v. were injected during the intraoperative period; and 8 h postoperatively, 0.3 mg ramosetron was injected intravenously. On days 1 and 2 postoperatively, patients received 5 mg mosapride citrate orally three times a day. Nausea and vomiting were recorded according to a 4-point scale routinely used in our PACU: 0: no nausea; 1: occasional nausea; 2: persistent nausea requiring treatment; and 3: vomiting.¹²

Data collection

The patients were assigned a special code to make sure that the evaluators were blinded to whether they had received RSB or not. At 48 h postoperatively, the PCA pump was collected and opioid consumption was checked from the PCA data log, after which the PCA data were downloaded to a computer. Accumulated infused volume given via i.v. PCA were analysed. Consumption of additional analgesics and antiemetics was also investigated using medical records that were retrospectively collected from the intraoperative anaesthetic records, drug administration records and nursing logs.

Study outcomes

Patient demographic data, perioperative conditions and short-term outcomes were investigated, which included a recording of parameters that included age, BMI, ASA score, duration, estimated blood loss, number and dose of opioids given to the

patient in the operating and recovery rooms. Postoperative pain severity was assessed using a VAS pain score and opioid consumption was recorded at 1 h, 8 h, 12 h, 24 h and 48 h after surgery. After surgery, the nausea/vomiting score and the use of additional analgesics was investigated.

Statistical analyses

In order to undertake a power calculation, a pilot study was conducted on 20 patients that were divided into two equal groups with or without the use of RSB. In this pilot study, the primary aim was to record the VAS pain score at 8 h after surgery and the R statistical package (version 3.0, R Foundation for Statistical Computing, Vienna, Austria) was used. The mean \pm SD VAS pain score of the control group (i.v. PCA group) was 5.2 ± 1.3 compared with 2.9 ± 0.54 for the test group (RSB + i.v. PCA). The effect size of the pilot study was 2.37, α was 0.05 and power was 90%. The number of patients required for each group was calculated to be approximately 13. Considering that approximately 30% of the total patients were eliminated or excluded due to complications, a total of 36 people were enrolled in this study, with 18 people in each group.

All statistical analyses were performed using the SPSS[®] statistical package, version 18.0 (SPSS Inc., Chicago, IL, USA) for Windows[®]. Continuous variables were analysed using Student's *t*-test and categorical variables were analysed using Fisher's exact test, χ^2 -test and Mann-Whitney *U*-test. Normally distributed continuous data are presented as mean \pm SD and continuous data that were not normally distributed are presented as the median (interquartile range). Categorical data are presented as *n* of patients (%). A *P*-value < 0.05 was considered statistically significant.

Results

This randomized, single-blind study enrolled 36 patients (Figure 2). All patients in the PCA group qualified for inclusion in the data analysis, but two patients in the RSB group were excluded due missing PCA data after the procedure. There were no significant differences in age, ASA score, height, weight, BMI, adhesions, operation time, anaesthesia time, intraoperative fluid administration, intraoperative bleeding volume and preoperative haemoglobin between the two groups (Table 1).

Compared with the PCA group, accumulated fentanyl consumption was

significantly reduced in the RSB group throughout the postoperative observation period (1–48 h) ($P < 0.05$ for all comparisons) (Table 2). The primary outcome of fentanyl consumption was significantly lower at 8 h postoperatively in the RSB group than in the PCA group ($148 \pm 61 \mu\text{g}$ versus $222 \pm 107 \mu\text{g}$, respectively; $P = 0.021$) (Table 2).

The VAS pain score was significantly lower in the RSB group at the PACU and 30 min postoperatively compared with the PCA group ($P = 0.017$, $P = 0.003$, respectively), but not significantly different at other times (Table 2). The dose of ketorolac 30 mg used as a rescue analgesic was not

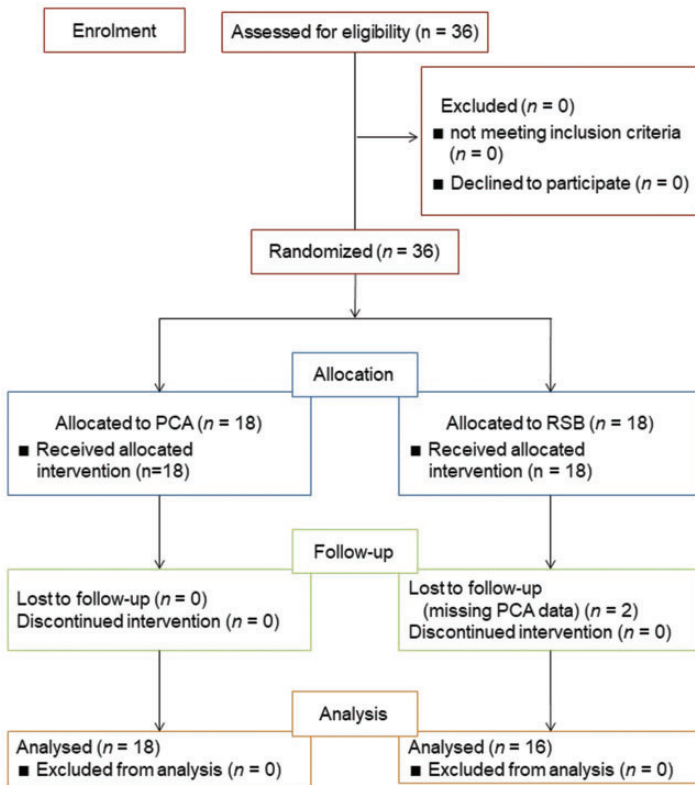


Figure 2. Flow diagram showing patient numbers at various stages in this prospective, randomized, single-blind study of the effects of ultrasound-guided rectus sheath block (RSB) in combination with patient-controlled analgesia (PCA) compared with PCA alone for pain relief following single-port total laparoscopic hysterectomy.

Table 1. Demographic and clinical characteristics of patients ($n = 34$) that were included in a prospective, randomized, single-blind study of the effects of ultrasound-guided rectus sheath block (RSB) in combination with patient-controlled analgesia (PCA) compared with PCA alone for pain relief following single-port total laparoscopic hysterectomy.

Characteristic	PCA group $n = 18$	RSB group $n = 16$
Age, years	37.7 ± 12.9	39.6 ± 11.1
ASA score		
1	11 (61)	8 (50)
2	7 (39)	8 (50)
Height, cm	158.0 ± 5.1	160.2 ± 5.8
Weight, kg	59.2 ± 8.5	57.1 ± 10.4
BMI, kg/m^2	23.7 ± 3.4	22.3 ± 3.8
Adhesiolysis required		
Yes	10 (56)	10 (63)
No	8 (44)	6 (38)
Operation time, min	93.1 ± 35.4	103.3 ± 40.2
Anaesthesia time, min	132.1 ± 37.1	142.5 ± 40.6
Intraoperative fluid administration, ml	539.5 ± 231.3	595.5 ± 382.8
Intraoperative bleeding, ml	50 (50–100)	100 (43–175)
Preoperative haemoglobin, g/dl	13.1 ± 1.3	12.5 ± 2.1

Data presented as mean \pm SD, median (interquartile range) or n of patients (%).

No significant between-group differences ($P \geq 0.05$); continuous variables were analysed using Student's t -test; categorical variables were analysed using Fisher's exact test, χ^2 -test and Mann-Whitney U -test.

ASA, American Society of Anesthesiologists; BMI, body mass index.

significantly different between the two groups (Table 2).

Nausea and vomiting were not significantly different between the two groups at any time-point (Table 3). In addition, there was no significant difference in the administration of antiemetics between the two groups for 48 h after surgery. There were no significant side-effects such as deep sedation, respiratory depression, systemic toxicity due to local anaesthesia and infection in either group.

Discussion

This randomized, single-blind study aimed to investigate the analgesic efficacy of RSB in single-port TLH. Compared with the PCA group, the opioid-sparing effect was superior in the RSB group throughout the postoperative observation period, even though the VAS score, which was the

primary outcome measure, did not appear to be significantly different between the two groups from 8–48 h after surgery.

The umbilical area is known to be innervated by the anterior cutaneous branch of the ventral ramus of the spinal nerve of T10. Since the nerves form a plexus around the inferior epigastric artery, T9 and T11 spinal nerves also supply pain and sensory sensations.¹³ In 2006, a previous study reported excellent pain relief by performing ultrasound-guided RSB after a paediatric umbilical herniorrhaphy.⁴ Other similar studies have also shown that RSB is an appropriate pain management modality in surgery of the umbilical area.^{3,6,7,14}

Rectal sheath block is a fascia plane block that reduces only somatic pain in the umbilical area. Therefore, if a patient complains of severe pain that is arising from a visceral or perineal site, the use of RSB will not be effective. In a study of pain

Table 2. Fentanyl consumption, pain scores and ketorolac administration in patients ($n = 34$) that were included in a prospective, randomized, single-blind study of the effects of ultrasound-guided rectus sheath block (RSB) in combination with patient-controlled analgesia (PCA) compared with PCA alone for pain relief following single-port total laparoscopic hysterectomy.

	PCA group $n = 18$	RSB group $n = 16$	Statistical analysis ^a
Total fentanyl consumption, μg			
1 h	120 \pm 46	79 \pm 40	$P = 0.008$
4 h	166 \pm 56	117 \pm 58	$P = 0.017$
8 h	222 \pm 107	148 \pm 61	$P = 0.021$
12 h	277 \pm 170	161 \pm 77	$P = 0.017$
24 h	333 \pm 192	214 \pm 114	$P = 0.032$
48 h	371 \pm 214	240 \pm 147	$P = 0.041$
Visual analogue pain score			
Arrival at PACU			
30 min	3.63 \pm 1.16	2.75 \pm 0.86	$P = 0.017$
8 h	3.37 \pm 1.38	2.19 \pm 0.66	$P = 0.003$
12 h	3.32 \pm 1.06	2.88 \pm 1.08	NS
24 h	2.89 \pm 1.20	2.94 \pm 1.48	NS
48 h	2.79 \pm 1.47	2.06 \pm 1.12	NS
Ketorolac administration, μg			
8 h	9.5 \pm 14.3	7.5 \pm 13.4	NS
8–48 h	7.9 \pm 16.9	1.9 \pm 7.5	NS
Total	17.4 \pm 25.1	9.4 \pm 14.4	NS

Data presented as mean \pm SD.

^aContinuous variables were analysed using Student's *t*-test.

PACU, post-anaesthesia care unit; NS, no significant between-group difference ($P \geq 0.05$).

levels recorded after TLH surgery, visceral pain was reported to be the highest and perineal pain was greater than the incision site pain in 30% of the patients.¹⁵ However, the definition of visceral pain was not precisely defined in this previous study.¹⁵ A similar pain pattern study on laparoscopic cholecystectomy revealed that somatic pain was the most important factor of discomfort amongst patients.¹⁶

In the current study, the postoperative pain scores in the RSB group varied significantly from the PCA group in the PACU and the fentanyl consumption was found to be significantly lower, which was suggestive of the fact that somatic pain might have played an important role in postoperative pain in these patients. Other gynaecological research comparing RSB with intraperitoneal (IP) injection as a modality to reduce

visceral pain found that pain significantly increased in the IP group 6 h after surgery.⁹ Several papers have been published that suggest that even if RSB does not resolve visceral pain, it can reduce overall pain, as seen in the case of open gynaecological surgery,¹⁷ multi-port laparoscopic gynaecological surgery¹¹ and single-port laparoscopic adnexectomy.¹⁰

One noteworthy point is that most of the above studies investigated multi-port laparoscopic surgery or open surgery, whereas in recent years, the popularity of single-port laparoscopic surgery, which uses the umbilicus as the lone port, has increased. There is much controversy as to which of the two surgeries is better pertaining to pain control and this subject requires more discussion.^{18–20} However, RSB can be used effectively in single-port laparoscopic

Table 3. Nausea and vomiting scores and antiemetic administration in patients ($n = 34$) that were included in a prospective, randomized, single-blind study of the effects of ultrasound-guided rectus sheath block (RSB) in combination with patient-controlled analgesia (PCA) compared with PCA alone for pain relief following single-port total laparoscopic hysterectomy.

Nausea/ vomiting score	PCA group $n = 18$	RSB group $n = 16$
Arrival at PACU		
0	10 (56)	8 (50)
1	6 (33)	7 (44)
2	2 (11)	1 (6)
3	0 (0)	0 (0)
12 h		
0	14 (78)	11 (69)
1	2 (11)	5 (31)
2	2 (11)	0 (0)
3	0 (0)	0 (0)
Postoperative antiemetic administration at 48 h	2 (11)	1 (6)

Data presented as n of patients (%).

No significant between-group differences ($P \geq 0.05$); categorical variables were analysed using Fisher's exact test and Mann-Whitney U -test.

PACU, post-anaesthesia care unit.

surgery, given that the umbilical area has been identified as the main source of somatic pain.

This current study had several limitations. First, the control group did not receive a sham block to exclude the placebo effect. Secondly, it was not easy to distinguish whether the pain relief observed was due to the effect of RSB or systemic absorption of local anaesthetics.

In conclusion, ultrasound-guided RSB is a multimodal method of pain control that can provide effective relief after single-port TLH.

Author contributions

B.J.C.: conducted the study, accessed the data and prepared the manuscript; S.G.C.: data acquisition and analysis; O.R.: data acquisition

and analysis; W.J.: acted as the study guarantor, prepared the protocol, data acquisition and prepared the artwork. All authors approved the final version of the manuscript.

Acknowledgements

The authors thank the gynaecologists participating in the study and Professors Incheol Jeong, Song-min Jong, and Yongseok Lee.

Declaration of conflicting interests

The authors declare that there are no conflicts of interest.

Funding

This research received no specific grant from funding agency in the public, commercial, or not-for-profit sectors.

ORCID iD

Woojin Kwon  <https://orcid.org/0000-0001-6806-5677>

References

- Smith BE, Suchak M, Siggins D, et al. Rectus sheath block for diagnostic laparoscopy. *Anaesthesia* 1988; 43: 947–948. 1988/11/01. DOI: 10.1111/j.1365-2044.1988.tb05658.x.
- Ferguson S, Thomas V and Lewis I. The rectus sheath block in paediatric anaesthesia: new indications for an old technique? *Paediatr Anaesth* 1996; 6: 463–466. 1996/01/01. DOI: 10.1046/j.1460-9592.1996.d01-24.x.
- Courreges P, Poddevin F and Lecoutre D. Para-umbilical block: a new concept for regional anaesthesia in children. *Paediatr Anaesth* 1997; 7: 211–214. 1997/01/01. DOI: 10.1046/j.1460-9592.1997.d01-79.x.
- Willschke H, Bosenberg A, Marhofer P, et al. Ultrasonography-guided rectus sheath block in paediatric anaesthesia—a new approach to an old technique. *Br J Anaesth* 2006; 97: 244–249. 2006/06/27. DOI: 10.1093/bja/ael143.
- Dolan J, Lucie P, Geary T, et al. The rectus sheath block: accuracy of local anesthetic placement by trainee anesthesiologists

- using loss of resistance or ultrasound guidance. *Reg Anesth Pain Med* 2009; 34: 247–250. 2009/07/10. DOI: 10.1097/AAP.0b013e31819a3f67.
6. Dingeman RS, Barus LM, Chung HK, et al. Ultrasonography-guided bilateral rectus sheath block vs local anesthetic infiltration after pediatric umbilical hernia repair: a prospective randomized clinical trial. *JAMA Surg* 2013; 148: 707–713. 2013/06/14. DOI: 10.1001/jamasurg.2013.1442.
 7. Gurnaney HG, Maxwell LG, Kraemer FW, et al. Prospective randomized observer-blinded study comparing the analgesic efficacy of ultrasound-guided rectus sheath block and local anaesthetic infiltration for umbilical hernia repair. *Br J Anaesth* 2011; 107: 790–795. 2011/08/23. DOI: 10.1093/bja/aer263.
 8. Yentis SM, Hills-Wright P and Potparic O. Development and evaluation of combined rectus sheath and ilioinguinal blocks for abdominal gynaecological surgery. *Anaesthesia* 1999; 54: 475–479. 2000/09/20. DOI: 10.1046/j.1365-2044.1999.00805.x.
 9. Azemati S and Khosravi MB. An assessment of the value of rectus sheath block for post-laparoscopic pain in gynecologic surgery. *J Minim Invasive Gynecol* 2005; 12: 12–15. 2005/05/21. DOI: 10.1016/j.jmig.2004.12.013.
 10. Chung W, Yoon Y, Kim JW, et al. Comparing two different techniques of rectus sheath block after single port laparoscopic surgery in benign adnexal mass patients: Surgical versus ultrasonography guidance-A randomized, single-blind, case-controlled study. *Eur J Obstet Gynecol Reprod Biol* 2017; 217: 29–33. 2017/08/28. DOI: 10.1016/j.ejogrb.2017.08.020.
 11. Cho S, Kim YJ, Jeong K, et al. Ultrasound-guided bilateral rectus sheath block reduces early postoperative pain after laparoscopic gynecologic surgery: a randomized study. *J Anesth* 2018; 32: 189–197. 2018/02/10. DOI: 10.1007/s00540-018-2457-0.
 12. White H, Black RJ, Jones M, et al. Randomized comparison of two anti-emetic strategies in high-risk patients undergoing day-case gynaecological surgery. *Br J Anaesth* 2007; 98: 470–476. 2007/02/24. DOI: 10.1093/bja/aem001.
 13. Rozen WM, Tran TM, Ashton MW, et al. Refining the course of the thoracolumbar nerves: a new understanding of the innervation of the anterior abdominal wall. *Clin Anat* 2008; 21: 325–333. 2008/04/23. DOI: 10.1002/ca.20621.
 14. Selvi O, Tulgar S, Senturk O, et al. Is a Combination of the Serratus Intercostal Plane Block and Rectus Sheath Superior to the Bilateral Oblique Subcostal Transversus Abdominis Plane Block in Laparoscopic Cholecystectomy? *Eurasian J Med* 2020; 52: 34–37. 2020/03/12. DOI: 10.5152/eurasianjmed.2019.19048.
 15. Choi JB, Kang K, Song MK, et al. Pain Characteristics after Total Laparoscopic Hysterectomy. *Int J Med Sci* 2016; 13: 562–568. 2016/08/09. DOI: 10.7150/ijms.15875.
 16. Bisgaard T, Klarskov B, Rosenberg J, et al. Characteristics and prediction of early pain after laparoscopic cholecystectomy. *Pain* 2001; 90: 261–269. 2001/02/24. DOI: 10.1016/S0304-3959(00)00406-1.
 17. Crosbie EJ, Massiah NS, Achiampong JY, et al. The surgical rectus sheath block for post-operative analgesia: a modern approach to an established technique. *Eur J Obstet Gynecol Reprod Biol* 2012; 160: 196–200. 2011/11/23. DOI: 10.1016/j.ejogrb.2011.10.015.
 18. Chung JH, Baek JM, Chung K, et al. A comparison of postoperative pain after transumbilical single-port access and conventional three-port total laparoscopic hysterectomy: a randomized controlled trial. *Acta Obstet Gynecol Scand* 2015; 94: 1290–1296. 2015/09/06. DOI: 10.1111/aogs.12767.
 19. Xie W, Cao D, Yang J, et al. Single-Port vs Multiport Laparoscopic Hysterectomy: A Meta-Analysis of Randomized Controlled Trials. *J Minim Invasive Gynecol* 2016; 23: 1049–1056. 2016/10/25. DOI: 10.1016/j.jmig.2016.08.826.
 20. Pontis A, Sedda F, Mereu L, et al. Review and meta-analysis of prospective randomized controlled trials (RCTs) comparing laparoscopic single site and multiport laparoscopy in gynecologic operative procedures. *Arch Gynecol Obstet* 2016; 294: 567–577. 2016/05/12. DOI: 10.1007/s00404-016-4108-8.