

Received: 2013.09.27
Accepted: 2013.12.19
Published: 2014.04.28

Authors' Contribution:

- A** Study Design
- B** Data Collection
- C** Statistical Analysis
- D** Data Interpretation
- E** Manuscript Preparation
- F** Literature Search
- G** Funds Collection

Mitral annulus caseous calcification mimicking cardiac mass in asymptomatic patient – multimodality imaging approach to incidental echocardiographic finding

Olga Możeńska¹, Sławomir Sypuła¹, Małgorzata Celińska-Spoder¹,
Jerzy Walecki², Dariusz A. Kosior^{1,3}

¹ Department of Noninvasive Cardiology and Hypertension, Central Clinical Hospital of the Ministry of the Interior, Warsaw, Poland

² Postgraduate Medical Center, Warsaw, Poland

³ Łazarski University, Warsaw, Poland

Author's address: Dariusz A. Kosior, Department of Noninvasive Cardiology and Hypertension, Central Clinical Hospital of the Ministry of the Interior, Wofoska 137 Str., 02-507 Warsaw, Poland, e-mail: dariusz.kosior@cskmswia.pl

Summary

Background:

Caseous calcification of mitral annulus is rather rare echocardiographic finding with prevalence of 0.6% in pts. with proven mitral annular calcification and 0.06% to 0.07% in large series of subjects in all ages. Echocardiographic images of caseous calcification are often heterogenous due to calcium and lipid deposits, and the masses show hyperechogenic and hypoechogenic areas. However the appearance of caseous calcification can imitate that of abscess, tumors and cysts, surgical treatment may not be needed when there is no obstruction.

Case Report:

76-year old obese (BMI 32 kg/m²), female patient with history of hypertension, stable coronary artery disease, diabetes type 2 and hyperlipidemia presented with no symptoms of mitral valve dysfunction and had no abnormalities on physical exam. Transesophageal echocardiography identified well-organized, composite, immobile lesion (22×15 mm) localized in the posterior part of the mitral annulus, with markedly calcified margins, and no significant impact on the valve function. In computed tomography (CT) lesion was described as calcified (24×22×17.5 mm), connected with posterior leaflet and posterior part of the mitral annulus, reducing posterior leaflet mobility. CT brought the suggestion of caseous mitral annular calcification. Coming to a conclusion, bearing in mind no mitral valve dysfunction at that time, patient was offered conservative treatment.

Conclusions:

Although caseous mitral annular calcification is typically an incidental finding, accurate recognition is needed to avoid mistaking the lesion for a tumor or abscess, which may result in unnecessary cardiac surgery. However this entity is diagnosed on cardiac MRI, multi-modality imaging, especially non-contrast CT, allows for the confident, prospective diagnosis.

Keywords:

Multimodality Imaging • Mitral Annulus Calcification • Mitral Valve

PDF file:

<http://www.polradiol.com/download/index/idArt/889830>

Background

Mitral annular calcification is a chronic, degenerative process, which occurs predominantly in older female patients, as well as in subjects with end-stage renal disease on chronic dialysis [1]. Caseous calcification of mitral annulus is rather rare, with echocardiographic prevalence

of 0.6% in patients with mitral annular calcification and 0.06% to 0.07% in large series of patients of all ages [2,3]. Echocardiographic images of caseous calcification are often heterogenous due to calcium and lipid deposits, and the masses show hyperechogenic and hypoechogenic areas [4]. However the appearance of caseous calcification can imitate that of an abscess, tumors and cysts. Surgical

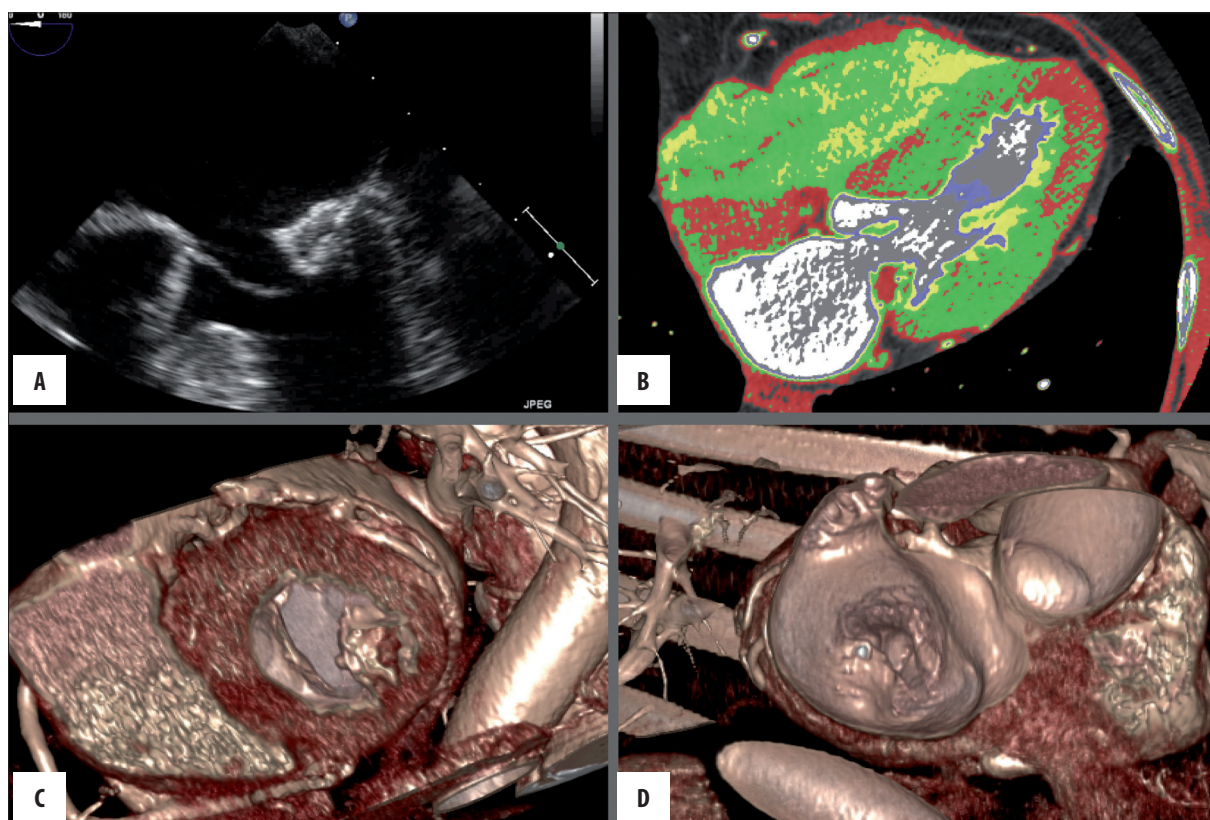


Figure 1. Caseous mitral annular calcification: (A) Transesophageal echocardiography, (B) computed tomography, (C, D) computed tomography – 3D reconstruction.

treatment may not be necessary if there is no obstruction [4,5].

We present a case of a 76-year-old woman referred to our centre with suspected left atrial myxoma without coexisting valve dysfunction.

Case Report

76-year-old obese (BMI 32 kg/m²) female patient with history of hypertension, stable coronary artery disease, type 2 diabetes and hyperlipidemia was admitted to our Department due to suspected left atrial myxoma identified with transthoracic echocardiography performed in the outpatient clinic. Patient presented with no symptoms of mitral valve dysfunction and physical exam was unremarkable. Electrocardiography and laboratory tests showed no significant abnormalities. Transthoracic echocardiography (TTE) revealed the following: chamber sizes within normal ranges, slight hypertrophy visible in the basal segment of intraventricular septum (maximum 13 mm), preserved LV ejection fraction, mild left ventricular outflow tract obstruction with maximum PG across mitral valve of 20 mmHg, negligible mitral insufficiency and irregular, hyperechogenic, immobile lesion suggestive of atypical calcification of mitral annulus in the left atrium, posterior to the mitral annulus. Transesophageal echocardiography (TEE) identified a well-organized, complex, immobile lesion (22×15 mm) localized in the posterior part of the mitral annulus, with markedly calcified margins, not exerting significant effect on valve function

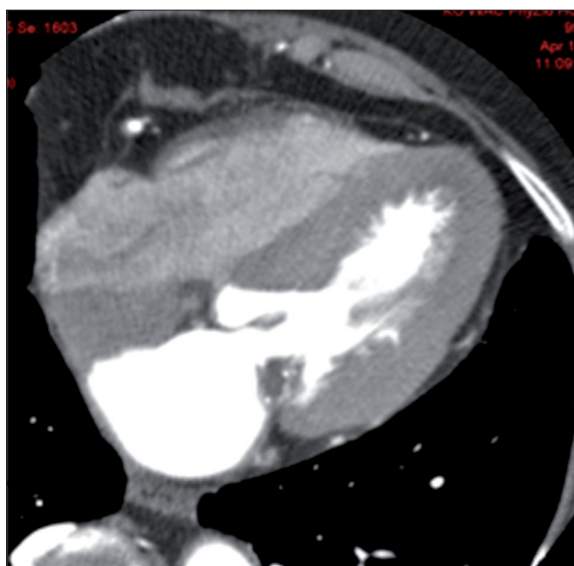


Figure 2. Caseous mitral annular calcification: Computed tomography.

(Figure 1A). In computed tomography (CT), the lesion was described as calcified (24×22×17.5 mm), connected to the posterior leaflet and posterior part of mitral annulus, reducing posterior leaflet mobility (Figure 1B, Figure 2; 3D reconstructions Figure 1C, 1D). Additionally, CT description revealed hypertrophy of the subvalvular segment of intraventricular septum. In conclusion, CT brought the suggestion of caseous mitral annular calcification. Coming

to a conclusion, bearing in mind lack of mitral valve dysfunction at that time, patient was offered conservative treatment.

Discussion

Mitral annular calcification is a rather common echocardiographic finding, especially in elderly patients and those undergoing dialysis due to end-stage renal failure [5-7]. Caseous mitral annular calcification is a rare and relatively unknown form of mitral annular calcification with an unidentified pathomechanism [8]. Echocardiographically it is described as a round mass with a central echolucent area consisting of a putty-like admixture of fatty acids, cholesterol and calcium [9,10]. It can easily be mistaken for a tumor or abscess, which may sometimes lead to unnecessary surgery. Differentiation between caseous mitral annular calcification and a tumor should be based on different clinical presentations. Calcification is in a typical location, may extend to the entire mitral annulus and may involve the base of mitral leaflets and/or papillary muscles and tendinous cords. It also has well-defined borders, an echolucent internal area, and may be characterized by acoustic shadowing. As for an abscess, it usually lacks large amounts of calcification, is located in the mitral-aortic

fibrosa, sometimes with systolic flow within its cavity visualized by Doppler imaging.

Caseous calcification should not be treated as malignant disease. Surgical treatment is reserved for cases that are ambiguous [5,7] or present with mitral valve dysfunction.

Bearing all that in mind we diagnosed caseous mitral annular calcification in this case. And once it is correctly identified using various imaging modalities patient should be treated with pharmacotherapy and clinical follow-up unless it is associated with mitral valve dysfunction, when cardiac surgery seems to be the best option. Regular clinical and echocardiographic follow-up is recommended, as was done in this case.

Conclusions

Although caseous mitral annular calcification is usually an incidental finding, accurate identification is needed to avoid mistaking the lesion for a tumor or abscess, which may result in unnecessary cardiac surgery. However, this entity is diagnosed on cardiac MRI and multimodality imaging, especially non-contrast CT, allows for a confident, reliable diagnosis [11-17].

References:

1. Stone E, Cohn D, Deal C, Pollock C: Calcific atrial mass in end-stage renal failure. *Nephrol Dial Transplant*, 1997; 12(4): 807-10
2. Harpaz D, Auerbach I, Vered Z et al: Caseous calcification of the mitral annulus: a neglected, unrecognized diagnosis. *J Am Soc Echocardiogr*, 2001; 14(8): 825-31
3. Kronzon I, Winer HE, Cohen ML: Sterile, caseous mitral annular abscess. *J Am Coll Cardiol*, 1983; 2(1): 186-90
4. Chahal M, Temesy-Armos P, Stewart WJ: Big MAC: caseous calcification of the mitral annulus referred for possible cardiac tumor. *Echocardiography*, 2011; 28(4): E76-78
5. Teja K, Gibson RS, Nolan SP: Atrial extension of mitral annular calcification mimicking intracardiac tumor. *Clin Cardiol*, 1987; 10(9): 546-48
6. Izgi C, Cevik C, Basbayraktar F: Caseous calcification and liquefaction of the mitral annulus: a diagnostic confounder. *Int J Cardiovasc Imaging*, 2006; 22(3-4): 543-45
7. Borowski A, Korb H, Voth E, de Vivie ER: Asymptomatic myocardial abscess. *Thorac Cardiovasc Surg*, 1988; 36(6): 338-40
8. Gramenzi S, Mazzola AA, Tagliaferri B et al: Caseous calcification of the mitral annulus: unusual case of spontaneous resolution. *Echocardiography*, 2005; 22(6): 510-13
9. Deluca G, Correale M, Ieva R et al: The incidence and clinical course of caseous calcification of the mitral annulus: a prospective echocardiographic study. *J Am Soc Echocardiogr*, 2008; 21(7): 828-33
10. Di Bella G, Carerj S, Ando G et al: Cardiac imaging in the evaluation of mitral annulus caseous calcification. *Int J Cardiol*, 2006; 113(1): E30-31
11. Lee C, Yoon AJ, Klipfel NE et al: Caseous mitral annular calcification along the anterolateral annulus causing mild mitral regurgitation: multi-modality imaging and diagnosis. *Circ J*, 2012; 76(12): 2898-900
12. Fujiwara T, Fujita T, Toda K, Kobayashi J: Multimodality imaging of caseous calcification of mitral annulus. *Eur J Cardiothorac Surg*, 2012; 41(2): 451
13. Biteker M, Duran NE, Ozkan M: Caseous calcification of the mitral annulus imaged with 64-slice multidetector CT. *Echocardiography*, 2009; 26(6): 744-45
14. Zeina AR, Makhoul N, Nachtigal A: Mitral annulus caseous calcification imaged with 64-slice MDCT. *Acute Card Care*, 2009; 11(2): 121-22
15. Blankstein R, Durst R, Picard MH, Cury RC: Progression of mitral annulus calcification to caseous necrosis of the mitral valve: complementary role of multi-modality imaging. *Eur Heart J*, 2009; 30(3): 304
16. Lubarsky L, Jelnin V, Marino N, Hecht HS: Images in cardiovascular medicine. Caseous calcification of the mitral annulus by 64-detector-row computed tomographic coronary angiography: a rare intracardiac mass. *Circulation*, 2007; 116(5): e114-15
17. Vanovermeire OM, Duerinckx AJ, Duncan DA, Russell WG: Caseous calcification of the mitral annulus imaged with 64-slice multidetector CT and magnetic resonance imaging. *Int J Cardiovasc Imaging*, 2006; 22(3-4): 553-59