



Since January 2020 Elsevier has created a COVID-19 resource centre with free information in English and Mandarin on the novel coronavirus COVID-19. The COVID-19 resource centre is hosted on Elsevier Connect, the company's public news and information website.

Elsevier hereby grants permission to make all its COVID-19-related research that is available on the COVID-19 resource centre - including this research content - immediately available in PubMed Central and other publicly funded repositories, such as the WHO COVID database with rights for unrestricted research re-use and analyses in any form or by any means with acknowledgement of the original source. These permissions are granted for free by Elsevier for as long as the COVID-19 resource centre remains active.

# Gastrointestinal Diseases of Ferrets

Heidi L. Hoefler, DVM, Diplomate ABVP (Avian)

## OUTLINE

### Disorders of the Oral Cavity, 27

- Dental Disease, 27
- Salivary Mucocele, 27
- Oral Ulceration and Fistulas, 27
- Oral Neoplasia, 28

### Disorders of the Esophagus, 28

### Disorders of the Stomach and Gastrointestinal Ulceration, 29

- General Gastritis and Ulceration, 29
- Helicobacter Mustelae* Gastritis, 30
- Gastrointestinal Polyps, 30
- Gastrointestinal Foreign Bodies, 30
- Gastric Distention (Bloat), 30

### Enteritis and Diarrhea, 32

- Bacterial Disease, 32
  - Salmonellosis*, 32
  - Mycobacteriosis*, 32
  - Campylobacteriosis*, 32
  - Proliferative Bowel Disease*, 32

### Viral Disease, 32

- Coronavirus*, 32
- Rotavirus*, 33
- Canine Distemper*, 33
- Influenza*, 33

### Parasitic Disease, 33

### Inflammatory Disease, 33

- Inflammatory Bowel Disease*, 33
- Eosinophilic Gastroenteritis*, 34

### Rectal Disease, 34

### Gastrointestinal and Pancreatic Neoplasia, 35

### Hepatobiliary Disease, 35

- Inflammatory Hepatitis, 35
- Copper Toxicosis, 35
- Neoplasia, 35
- Other Hepatopathies, 35
- Gall Bladder Disease, 35

Disease of the gastrointestinal (GI) tract is quite common in ferrets. Clinicians should be familiar with the more prevalent GI disorders, be able to recognize clinical signs, and be prepared to differentiate among potential diagnoses.

## DISORDERS OF THE ORAL CAVITY

### Dental Disease

Dry kibble diets appear to result in significant wear to ferret premolars and molars.<sup>12</sup> Moist or semi-moist diets have been associated with the formation of dental calculi; however, most ferrets on a dry kibble diet also develop tartar and gingivitis that progress with age. Periodontal disease is pervasive in pet ferrets.<sup>18,40,58</sup>

Gnawing often results in discoloration, wearing, and blunting of the canine teeth. This does not usually result in obvious discomfort unless the dental pulp is exposed. Root canal restoration or surgical removal of affected teeth may be necessary. Extrusion and gingival recession of the canine teeth is common in ferrets; however, tooth root abscesses, periapical disease, caries, and tooth resorption are not.<sup>18,58</sup> Dental disease is often an incidental finding during physical examination.

Follow the basic principles for dental disease management that apply to dogs and cats. Daily at-home prophylaxis using an enzymatic pet toothpaste and finger brush is recommended.

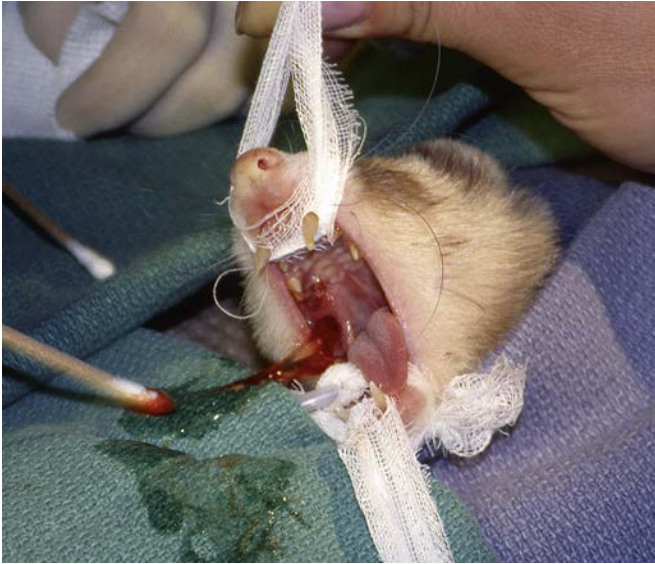### Salivary Mucocele

Although uncommon, mucoceles have been described in ferrets. Salivary mucoceles can develop secondary to trauma to a salivary gland, and salivary microliths may contribute to adenitis and possible mucocele formation.<sup>50</sup> Salivary mucoceles may result in fluctuant facial swellings involving the commissures of the mouth, the top of the skull, or the orbital area.

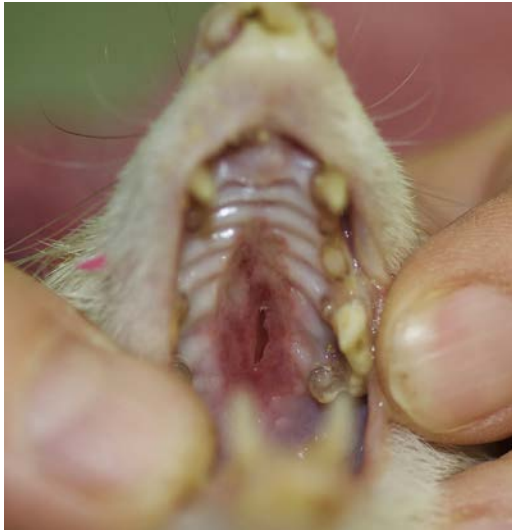Although mucoceles that bulge into the oral cavity can be marsupialized into the mouth, recurrence is possible (Fig. 3.1). Surgical excision of the affected salivary gland is preferred.<sup>66</sup> Injecting contrast medium into the mucocele may help trace the route of saliva.

### Oral Ulceration and Fistulas

Oral ulcers may be associated with dental disease or concurrent diseases that cause nausea and pawing at the roof of the mouth (e.g., hypoglycemia from insulinoma, gastric reflux or pain from ulcers or foreign bodies, or *Helicobacter* gastritis). Perform serum chemistries, hematology, radiographs, and GI palpation under sedation. Address predisposing factors and treat oral



**Fig. 3.1** The medial aspect of this mucocoele is marsupialized into the mouth.



**Fig. 3.2** Ulceration of the palate and oronasal fistula in a ferret.

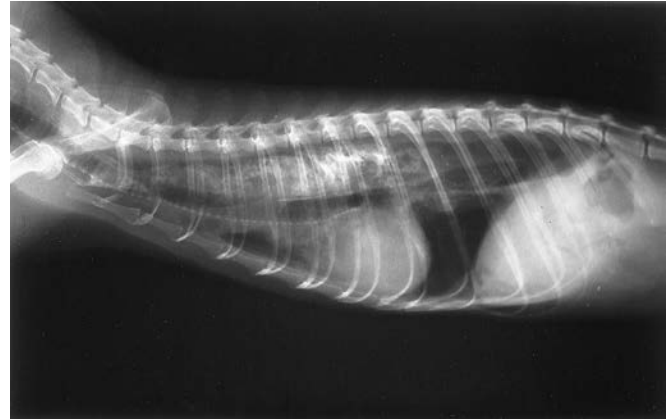ulcers with liquid sucralfate (100 mg/kg every 6 hours) and a gruel made of soaked kibble until the ulcer heals. In advanced cases, oronasal fistulas can form and can be difficult to repair surgically (Fig. 3.2).<sup>80</sup>

### Oral Neoplasia

The oral cavity is an uncommon site of neoplasia in ferrets. Squamous cell carcinoma is the most commonly reported oral tumor in ferrets and typically manifests as a firm swelling of the upper or lower mandible.<sup>5,29,43</sup> Chapter 8 contains more information about oral neoplasia in ferrets.

## DISORDERS OF THE ESOPHAGUS

Esophageal diseases are uncommon in ferrets. Megaesophagus, which describes an esophagus that is enlarged (dilated) on radiographic examination and that lacks normal motility, has been reported in ferrets and is associated with regurgitation,



**Fig. 3.3** Lateral radiograph of a ferret with megaesophagus. Orally administered barium sulfate delineates the esophagus.

lethargy, inappetence or anorexia, dysphagia, and weight loss.<sup>7,33</sup> Some ferrets exhibit coughing or choking motions or labored breathing. The differential diagnosis includes an esophageal or gastrointestinal foreign body, gastritis, and respiratory disease.

On survey radiographs, the entire esophagus may be dilated and food may be seen in the lumen. Gastric gas is sometimes seen, and aspiration pneumonia may be evident. In suspect cases, always take abdominal radiographs to exclude lower GI disease. Administer barium sulfate or iohexol (8–10 mL/kg by mouth [PO]) to delineate the esophagus and evaluate for mural lesions, strictures, or obstructions (Fig. 3.3). Ferrets will take barium force-fed from a syringe; however, use iohexol instead of barium in cases of possible esophageal rupture. Use fluoroscopy, if available, to determine the motility of the esophagus after a barium swallow.

Palliative management of ferrets with megaesophagus is similar to that of dogs but is less successful. Proton pump inhibitors such as metoclopramide and cisapride work on smooth muscle only, and the esophageal muscle in ferrets is striated along its entire length. These drugs act to increase lower esophageal sphincter pressure, potentially delaying esophageal emptying; therefore they are not useful for megaesophagus. Use ranitidine, famotidine, or omeprazole for reflux and esophagitis (see Table 3.1 for doses). Ferrets with megaesophagus may have malnutrition, hepatic lipidosis, and aspiration pneumonia. Most individuals die or are euthanized within days of being diagnosed with megaesophagus.

The cause of megaesophagus in ferrets is unknown. Autoimmune myasthenia gravis has been documented in two unrelated ferrets, but neither had signs of megaesophagus.<sup>3,14</sup> Diagnosis and treatment of myasthenia gravis is discussed in Chapter 10.

Esophageal foreign bodies have been successfully managed surgically or via endoscopic retrieval.<sup>9,31</sup> This author treated a ferret with a toy sponge foreign body lodged in its distal esophagus. The sponge was broken into smaller pieces by using a 2.7-mm rigid endoscope, and the foreign material passed through the GI tract without incident. Esophageal strictures have been reported and corrected with endoscopic balloon dilation and esophageal stenting.<sup>31</sup>

Ferrets with disseminated idiopathic myofasciitis—a musculoskeletal disease with generalized weakness, joint pain,

**TABLE 3.1 Summary of Suggested Treatment Regimens for *Helicobacter mustelae* Gastritis, Inflammatory Bowel Disease, Proliferative Bowel Disease, and Eosinophilic Gastroenteritis**

Disease	Drug	Dosage
<i>Helicobacter mustelae</i> gastritis		
Original triple therapy <sup>a</sup>	Amoxicillin	10 mg/kg PO every 8 h <sup>60</sup>
	Metronidazole	20 mg/kg PO every 8 h
	Bismuth subsalicylate	17.5 mg/kg (1 mL/kg) PO every 8 h
Alternative therapy <sup>a</sup>	Clarithromycin	12.5 mg/kg PO every 8 h <sup>48</sup>
	Ranitidine bismuth citrate	24 mg/kg PO every 8 h <sup>48</sup>
	or	
	Enrofloxacin	5 mg/kg PO every 12 h <sup>22</sup>
Acid suppressants	Omeprazole	6 mg/kg PO every 12 h
	Famotidine	0.5-1 mg/kg PO, SC, IV every 12-24 h
Inflammatory bowel disease	Sucralfate	1 mg/kg PO every 12 h
	Azathioprine <sup>b</sup>	100 mg/kg PO every 6 h
	Prednisone	0.9 mg/kg PO every 24-72 h
Proliferative bowel disease	Sucralfate	1 mg/kg PO every 12 h
	Chloramphenicol	50 mg/kg PO, IM, SC every 12 h
Eosinophilic gastroenteritis	Prednisone	1.25-2.5 mg/kg PO every 24 h
	Ivermectin	0.4 mg/kg SC, PO once; repeat in 14 days

<sup>a</sup>Treat for a minimum of 21 days.

<sup>b</sup>Bone marrow suppression possible side effect. Monitor with complete blood count. PO, by mouth; SC, subcutaneously; IM, intramuscularly; IV, intravenously.

fever, and anorexia—may have severe suppurative or pyogranulomatous inflammatory lesions of the esophagus, as well as other skeletal muscles and surrounding connective tissue (see Chapter 10).<sup>68</sup>

## DISORDERS OF THE STOMACH AND GASTROINTESTINAL ULCERATION

### General Gastritis and Ulceration

Gastric and duodenal ulcers are common in pet ferrets. Causes of GI ulceration include foreign body or toxin ingestion, *Helicobacter mustelae* infection, neoplasia of the intestinal tract, treatment with nonsteroidal antiinflammatory drugs (NSAIDs), and azotemia. Use NSAIDs cautiously, because overdose or prolonged use can cause ulceration. It is rare, however, for ferrets to have GI bleeding with corticosteroids, even at dosages as high as 2 to 3 mg/kg per day.

Signs of gastritis or duodenal ulceration include melena, anorexia, lethargy, and weight loss. Ferrets experiencing nausea or abdominal pain often hypersalivate, paw at the roof of the mouth, or display teeth-grinding. Vomiting is not common, but owners may describe coughing or gagging that could represent gastric reflux.

Diagnostic tests include whole-body radiography and blood tests. Fast the ferret for 4 to 6 hours to facilitate visualization of a gastric foreign body or hairball. The stomach should be empty; thus any ingesta may represent hair or other material. *Helicobacter mustelae* gastritis may be a diagnosis of exclusion of other common disorders, such as a GI foreign body.

Left untreated, ferrets with melena may die from blood loss or intestinal perforation. Hospitalize debilitated and anorexic

ferrets for fluid therapy and parenteral treatment. Use an antiemetic, such as maropitant citrate (Cerenia; Zoetis, Kalamazoo, MI; 1 mg/kg every 24 hours), metaclopramide (0.5 mg/kg SQ, PO or [intravenously] IV every 8 hours), or ondansetron (0.5 mg/kg IM, IV, or PO every 8 hours). An antibiotic combination that targets *Helicobacter* is recommended for debilitated ferrets (see treatment for *Helicobacter* gastritis).

For ferrets that are not vomiting, offer multiple small feedings of a bland, moist diet (e.g., a/d Canine/Feline; Hill's Pet Nutrition, Inc., Topeka, KS) or a carnivore recovery diet (e.g., Carnivore Care, Oxbow Animal Health, Murdock, NE; or Emerald Carnivore, EmerAid LLC, Cornell, IL). Calculate a minimum daily intake of 400 kcal/kg body weight and divide into four to six feedings per day. Avoid dry, high-fiber foods. For vomiting animals, withhold food for 4 to 6 hours and monitor for signs of hypoglycemia (older ferrets often have subclinical insulinomas). If vomiting resolves, introduce small frequent feedings. Antiemetics can also be used.

Bismuth compounds may inhibit development of peptic ulcers. Administer bismuth subsalicylate (17.5 mg/kg PO every 8 hours) or colloidal bismuth subcitrate (6 mg/kg PO every 8 hours). A suspension of sucralfate—a cytoprotective agent that binds to erosion sites—can be dosed at 100 mg/kg PO every 6 hours.

The H<sub>2</sub>-receptor antagonists, such as ranitidine or famotidine, reduce gastric acid secretion. Ranitidine bismuth citrate has the added benefit of bismuth but is unavailable in the United States.<sup>77</sup> Famotidine is available for parenteral administration. Recent studies in dogs and cats have demonstrated superior acid suppression using proton pump inhibitors like omeprazole.<sup>63,81</sup> Use a compounding pharmacy or an omeprazole equine paste (GastroGard,



Merial, Iselin, NJ). Dilute the paste to the desired concentration using cod liver oil or corn oil.<sup>81</sup> See [Table 3.1](#) for doses.

### Helicobacter Mustelae Gastritis

*Helicobacter mustelae*—a gram-negative bacterial rod—is related to *Helicobacter pylori*, a human pathogen associated with gastritis and ulcers.<sup>20</sup> In fact, ferrets are used as animal models for the study of *H. pylori* infection in people. Virtually all North American ferrets are likely to become persistently infected with *H. mustelae* at weaning unless they are treated or hand-reared in isolation.<sup>78</sup> Infection is lifelong in untreated ferrets. It may become clinically apparent in animals that are stressed by concurrent disease or recent surgery, and the severity of chronic *H. mustelae* gastritis increases with age.<sup>22</sup>

*Helicobacter* colonizes the antral area of the stomach and pyloric area of the duodenum. Chronic *H. pylori* gastritis in humans can lead to gastric adenocarcinoma or mucosa-associated lymphoid tissue (MALT) lymphoma.<sup>17</sup> Gastric MALT lymphoma associated with *H. mustelae* infection has also been reported in adult ferrets.<sup>17</sup> Spontaneously occurring gastric adenocarcinoma has been reported in pet ferrets,<sup>70,76</sup> and silver-stained (Warthin-Starry) organisms morphologically compatible with *H. mustelae* were seen in neoplastic tissues of one report.<sup>21</sup>

Whereas diagnosis is often based on history and clinical signs, definitive diagnosis of *Helicobacter* infection is confirmed by histopathologic examination of a gastric mucosal sample obtained by endoscopic or surgical biopsy. The organism can be seen in silver-stained sections of gastric mucosa. Gastric mucosa or fecal samples can be submitted for polymerase chain reaction (PCR)-based analysis (University of Georgia Veterinary Diagnostic Laboratory, Athens, GA; Veterinary Molecular Diagnostics, Milford, OH).

Treatment for *Helicobacter* includes antibiotic therapy, as well as the supportive treatment for ulcers outlined previously. Initial treatment is commonly a combination of amoxicillin, metronidazole, and bismuth subsalicylate (see [Table 3.1](#) for dosing protocols).<sup>60</sup> Amoxicillin and metronidazole must be used in combination for at least 21 days with the goal of eradicating *Helicobacter*. Oral amoxicillin suspensions are palatable and well accepted by most ferrets. Metronidazole can be compounded into an oral suspension, but most ferrets find it unpalatable. Clarithromycin-based double therapy (used with either ranitidine bismuth citrate or omeprazole) was found to be more effective than amoxicillin-based triple therapy.<sup>2,48</sup> Either protocol is based on a three-times-daily dosing schedule, which is impractical for some owners. Enrofloxacin plus colloidal bismuth subcitrate is also effective.<sup>22</sup> Antacids can also decrease discomfort and reduce effects of acid reflux on esophageal mucosa (see treatment above for ulcers).

### Gastrointestinal Polyps

Gastrointestinal polyps are rare in ferrets. One 6-year-old ferret had an adenomatous polyp of the descending colon that resulted in an intussusception.<sup>11</sup> The ferret had chronic diarrhea and straining. Removal was uneventful, and the tumor was benign. Two ferrets with GI polyps have been seen by the author

at the Animal Medical Center (New York, NY). Both ferrets exhibited lethargy, inappetence, melena, and weakness from anemia. Abdominal radiographs suggested GI abnormalities. On abdominal exploration, one ferret had a gastric polyp, and the other had a small intestinal polyp. Both ferrets recovered well after resection of the polyps, which were benign.

### Gastrointestinal Foreign Bodies

GI foreign bodies are common in ferrets.<sup>54,85</sup> Foreign objects (particularly rubber or sponge products) are commonly ingested by ferrets younger than 2 years of age, whereas trichobezoars are more common in older ferrets. Linear foreign bodies are rare in ferrets.

The most common clinical signs of GI foreign bodies in ferrets are lethargy, inappetence, and diarrhea. Vomiting is uncommon but should always raise suspicion of a GI foreign body ([Table 3.2](#)). Some ferrets display bruxism, ptyalism, face-rubbing, and pawing at the mouth. Acutely obstructed ferrets may be recumbent. Chronic trichobezoars can be incidental findings during examination or surgery, but some can become acute outflow obstructions.

Palpate the abdomen carefully. Small intestinal foreign bodies are associated with localized discomfort or pain and can usually be palpated, especially with the animal under sedation. Gastric foreign bodies are more difficult to palpate. Hold the sedated ferret vertically to allow the spleen and stomach to drop down for easier palpation.

If a foreign body is suspected, obtain whole-body survey radiographs, including the thorax to evaluate the esophagus. Abnormal radiographic findings include segmental ileus, gas distention of the stomach, and, occasionally, a visible foreign object or trichobezoar. Contrast studies, using barium sulfate or iohexol (8–10 mL/kg PO), or a negative gastrogram with air can be helpful in determining the presence of hairballs ([Fig. 3.4](#)).<sup>85</sup>

Ferrets rarely pass GI foreign bodies unassisted. Occasionally, a small, partially obstructing object may pass after treatment with intestinal lubricants (i.e., hairball laxatives—e.g., Laxatone [Vetoquinol USA, Fort Worth, TX] at 1 mL every 8–12 hours) and replacement fluids. In some cases, small gastric foreign bodies can be removed endoscopically (see [Chapter 35](#)). However, most must be removed surgically. Stabilize debilitated ferrets, and then perform an exploratory laparotomy as soon as possible. Collect biopsy samples from the stomach, intestines, or other organs as indicated. Explore the abdomen carefully, because concurrent abdominal disease (e.g., involving the pancreas or adrenal glands) is common. Ferrets can often eat soft foods within 12 hours after GI foreign body removal, and most ferrets are discharged within 48 hours after surgery.

Prevention of foreign body obstructions includes regular use of a hairball laxative preparation during active shedding seasons and “ferret-proofing” the household. Ferrets should not be left uncaged or unsupervised. Advise owners to avoid small rubber “squeak” toys for pet ferrets and to remove rubber objects (e.g., rubber-soled shoes and earphones) from the ferret’s environment.

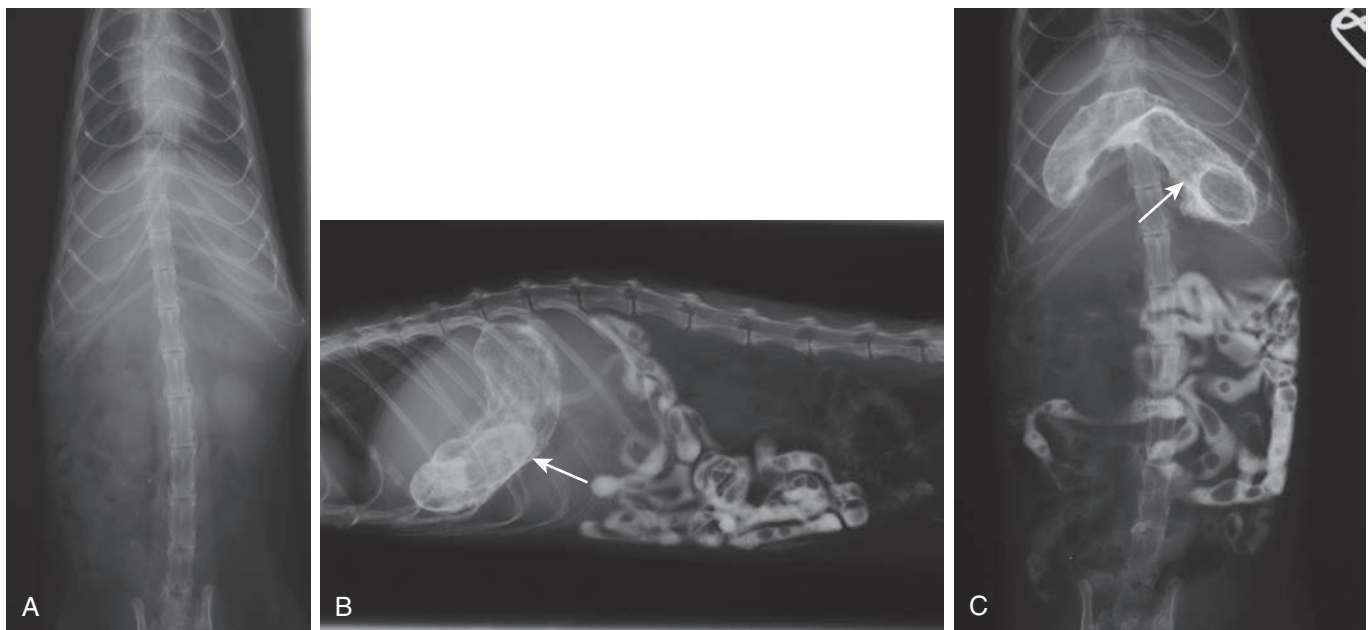
### Gastric Distention (Bloat)

Pet ferrets occasionally experience acute gastric or small intestinal foreign body blockage that results in a distended, fluid-filled stomach. These ferrets are acutely very weak.

**TABLE 3.2 Differentiation of Common Gastrointestinal Diseases That Cause Weight Loss and Diarrhea in Ferrets by Typical History, Clinical Findings, and Laboratory and Radiographic Results<sup>a</sup>**

Disease	Typical Diarrhea	Vomiting/ Bruxism	Prolapsed Rectum/ Tenesmus	Physical Findings	Laboratory/ Radiographic Results	Comments
Eosinophilic gastroenteritis	Mucoid, green	Possible	No	± Thickened intestinal loops	Eosinophilia ± reactive hepatitis	Rare; multiple tissue involvement (visceral lymph nodes, spleen)
Ferret enteric coronavirus/ (epizootic catarrhal enteritis)	Acute: profuse, green Chronic: grainy (“bird seed”)	Possible	No	Thickened or fluid-filled intestines	± Reactive hepatitis	Acute onset, can become chronic; exposure to new or young ferrets
Foreign body	Black, tarry or mucoid, green	Yes	No	Palpable gastric or intestinal gas; painful on abdominal palpation	± Reactive hepatitis Anemia (chronic) Gas in stomach or intestinal loops	Acute or chronic Young ferrets: rubber objects, toys Older ferrets: hairballs more common
<i>Helicobacter mustelae</i> gastritis	Black, tarry or mucoid, green	Yes	No	Enlarged mesenteric lymph nodes	± Reactive hepatitis ± Anemia Gas in stomach	Recent stress (i.e., surgery or concurrent disease); can increase in severity with age
Inflammatory bowel disease	Mucoid, tan or green	Possible	Possible	± Enlarged mesenteric lymph nodes	Reactive hepatitis ± Elevated globulins ± Elevated lipase	May develop secondary to other GI disease
Proliferative bowel disease	Mucoid, green	Rare	Yes	Palpably thickened large bowel; proliferative rectal mucosa	± Elevated globulins	Primarily affects young ferrets

<sup>a</sup>Although typical findings are listed, clinical signs and physical findings are variable in any of the described diseases. GI, Gastrointestinal.



**Fig. 3.4** (A) Ventrodorsal radiograph of a ferret with a gastric trichobezoar. The trichobezoar appears as a tubular soft tissue density poorly delineated in the stomach in upper left abdomen. Contrast studies were performed. (B) Lateral and (C) ventrodorsal radiographic view of the same ferret 30 minutes after administration of barium sulfate. Note the delineation of trichobezoars in the stomach (arrows).

Full-body radiographs can confirm the diagnosis. Affected animals are in shock and need immediate aggressive therapy. Relieve gastric pressure by placing an orogastric tube (8- or 10-Fr red rubber feeding tube) with the ferret under sedation, treat the hypovolemic shock, and prepare for surgical exploration when stable.

Pyloric stenosis and gastric outflow obstruction can manifest as acute bloat in ferrets. Pyloric adenocarcinoma has been associated with *H. mustelae* infection.<sup>70,76</sup> Pyloric stenosis caused by muscular hypertrophy of the pylorus has been seen clinically by the author, with one case occurring in a 4-month-old ferret. Pyloromyotomy and dilation of the pyloric outflow is the recommended treatment, especially where *Helicobacter* and neoplasia are not present.

Other than associated with obstructive disease, gastric bloat is rare in pet ferrets. However, gastric bloat has been reported on domestic ferret farms and in black-footed ferrets (*Mustela nigripes*).<sup>35,73</sup> Clinical signs are usually seen in weanlings, but adult ferrets have also been affected. Signs can include acute gastric distention, dyspnea, cardiovascular compromise, and sudden death. The cause is unknown but is believed to be related to an abrupt dietary change and overgrowth of *Clostridium perfringens* type A (previously called *Clostridium welchii*).

## ENTERITIS AND DIARRHEA

Normal ferrets nibble on food all day. Their GI transit time is only 3 hours, so defecation is frequent in the healthy state. Normal stool is slightly soft and formed. Anorexic ferrets may pass a very dark green (bile) stool that can resemble melena. Diarrhea in ferrets is difficult to classify by origin in the small intestine or colon. More important are the onset, duration, and severity of diarrhea, as well as concurrent clinical signs. Because the gut flora of ferrets is simple and plays no vital role in digestion, long-term administration of broad-spectrum antibiotics does not cause dysbiosis and diarrhea in ferrets.

### Bacterial Disease

#### Salmonellosis

Salmonellosis is a contagious disease characterized by fever, bloody diarrhea, and lethargy. Conjunctivitis and anemia may also be present. Incidence is very low in pet ferrets, and infection may be associated with feeding raw or undercooked meat and meat by-products. Therapy consists of aggressive supportive care and antimicrobial therapy.

#### Mycobacteriosis

*Mycobacterium bovis* and *Mycobacterium avium* infections have been recognized in research, farm, and feral ferrets in England, Europe, and New Zealand. These infections have been associated with the feeding of raw meat and unpasteurized dairy products, or—in feral ferrets—feeding on carrion infected with *M. bovis*.<sup>46</sup> Infections with *M. avium*, *M. genavense*, *M. abscessus*, and *M. celatum* have also been reported in domestic ferrets.<sup>45,47,52,65,72,74,83</sup>

Ferrets with mycobacteriosis can have diarrhea, weight loss, lymph node enlargement, conjunctival lesions, splenomegaly, and pneumonia.<sup>52,56</sup> Diagnosis is confirmed by histopathologic

examination of tissue samples, acid-fast staining, PCR testing, and culture. Mycobacterial granulomas grossly resemble those seen with systemic coronavirus disease (see below) and must be differentiated histopathologically.<sup>52</sup> In several reported cases, treatment regimens for mycobacteriosis, including rifampicin monotherapy or in combination with enrofloxacin and azithromycin, have resulted in variable success. The zoonotic potential of mycobacteriosis in ferrets is unknown but should be discussed with owners before beginning treatment.

#### Campylobacteriosis

The importance of *Campylobacter jejuni* as a primary pathogen in pet ferrets is unknown. Ferrets experimentally infected with *C. jejuni* developed self-limiting diarrhea with mucous and blood, and the organism was recovered from the small and large intestine and from the liver.<sup>59</sup> In one report, two commercial vendors screened asymptomatic ferrets and found 8 of 10 and 43 of 73 cultured positive for *C. jejuni*.<sup>6</sup> Nonclinical shedding can cause infection in more susceptible species, including people. Diagnosis is through culture under microaerophilic conditions, or PCR testing of intestinal tissue. Treatment consists of supportive care, and antibiotics (e.g., erythromycin) are used to hasten the resolution of diarrhea in outbreaks.

#### Proliferative Bowel Disease

Proliferative bowel disease is a rare bacterial disease that causes intestinal thickening and diarrhea in ferrets 4 to 6 months of age.<sup>23,79</sup> The causative agent, *Lawsonia intracellularis*, primarily involves the colon and less commonly the small intestine.<sup>13</sup>

Ferrets with proliferative bowel disease have chronic diarrhea that varies from dark liquid feces streaked with bright red blood to scant stool, often with bright green mucus. Affected animals cry while straining to defecate, and rectal tissue may prolapse. Some ferrets lose weight rapidly in spite of eating. Affected intestines are palpable on physical examination.

Diagnosis is usually supported by clinical signs, gross or histopathologic lesions, and PCR performed on a rectal swab, feces, or intestinal biopsy sample. Severely affected animals will die if not treated appropriately. *Lawsonia intracellularis* is sensitive to chloramphenicol dosed at 50 mg/kg PO every 12 hours for at least 10 days.<sup>42</sup> Ferrets with rectal prolapse generally heal with medical treatment; therefore placement of a purse-string suture is rarely necessary (see below).

### Viral Disease

#### Coronavirus

Ferret coronavirus is an important cause of enteric disease. The two closely related but genetically distinct forms of this ribonucleic acid (RNA) virus are an enteric coronavirus and a systemic coronavirus resembling feline infectious peritonitis (FIP). Ferret enteric coronavirus is the causative agent of epizootic catarrhal enteritis (ECE), a highly transmissible diarrheal disease of ferrets that was initially called “green slime diarrhea” disease.<sup>88,89</sup> Adult ferrets are most susceptible to ECE, and the typical history includes recent exposure to a new young ferret that is presumably an asymptomatic carrier. The incubation period is 48 to 72 hours, after which affected ferrets are anorexic and lethargic and

develop profuse green diarrhea that can persist for several days and longer. The morbidity rate can be high, but the mortality rate is low in ferrets that are treated appropriately.

Coronavirus may be detected by PCR testing of fecal or small intestinal tissue samples (Diagnostic Center for Population and Animal Health, Michigan State University, Lansing, MI, or Veterinary Molecular Diagnostics, Milford, OH). Sample submission must be expedited because of the labile nature of RNA viruses. New research has established an enzyme-linked immunosorbent assay (ELISA)-based serologic test to detect serum antibodies against ferret coronavirus.<sup>53</sup>

Treat debilitated ferrets with aggressive fluid therapy, antibiotics, and supportive care and isolate them from asymptomatic or unexposed ferrets. After recovering from ECE, some adult ferrets develop a persistent, intermittent malabsorption syndrome with tan, seed-like diarrhea. The clinical course can last weeks to months. Recovery may be accelerated by treating with prednisone (1 mg/kg every 12 hours for 14 days) and feeding an easily absorbed diet. Tylosin powder (5 mg/kg mixed in soft food every 12 hours) may also be useful for long-term treatment of chronic diarrhea.

Ferret systemic coronavirus (FSCV) has been identified as the causative agent of a progressive systemic pyogranulomatous disease in young ferrets that resembles the dry form of FIP.<sup>4,27,49,55,64</sup> Affected ferrets average 11 months of age and exhibit chronic weight loss, a palpable abdominal mass or masses, diarrhea, hypergammaglobulinemia, leukocytosis, and anemia. Central nervous system (CNS) signs are also possible.<sup>28</sup>

Diagnosis of FSCV requires immunohistochemical staining of affected tissues with the anti-coronavirus antibody, FIPV3-70. The disease is progressive and carries a high mortality rate, with the duration of clinical illness averaging 67 days.<sup>27</sup> There is no treatment for this form of coronavirus in ferrets. Immunosuppressive therapy and supportive care—including nutritional supplementation, GI protectants, antiemetics, and empirical antibiotic therapy—were helpful in maintaining a favorable quality of life for 1 year after diagnosis in one ferret (see Table 3.3).<sup>4,55</sup>

### Rotavirus

Farm outbreaks of diarrhea from infection with rotavirus are associated with high morbidity and mortality rates in neonatal kits from 2 to 6 weeks of age.<sup>82,90</sup> Morbidity is low in adult ferrets, but infection may result in a transient, green, mucoid diarrhea. Diagnosis is by PCR testing of fecal or tissue samples (jejunum or ileum) (Diagnostic Center for Population and Animal Health, Michigan State University). Treatment is supportive.

### Canine Distemper

Canine distemper is caused by a highly contagious paramyxovirus that is usually fatal in unvaccinated ferrets. Clinical signs include diarrhea, nasal and ocular discharges, and a generalized orange-tinged dermatitis (see Chapter 6). Vaccination of ferrets against canine distemper virus has greatly limited its incidence. However, cold-like symptoms, dermatitis, and diarrhea in newly acquired, unvaccinated ferrets should arouse suspicion.

**TABLE 3.3 Suggested Therapeutic Protocol for Systemic Coronavirus Disease**

Drug	Dosage
Prednisolone	1–2 mg/kg PO every 12 h, initial dosing then taper
Doxycycline	10 mg/kg every 12 h
Pentoxifylline	20 mg/kg PO every 12 h
Polyprenyl immunostimulant	3 mg/kg PO 3 times weekly
Cimetidine	10 mg/kg PO every 8–12 h
Feline vitamin supplement	As directed on label and dosed by body weight

PO, By mouth.

Data from Murray J, Kiupel M, Maes RK. Ferret coronavirus-associated diseases. *Vet Clin North Am Exot Anim Pract* 2010;13:543–560.

### Influenza

Ferrets infected with influenza, which is caused by an orthomyxovirus, sometimes have transient diarrhea. The virus also causes upper respiratory disease associated with coughing, sneezing, inappetence, and lethargy. Affected ferrets are often febrile (see Chapter 6).

### Parasitic Disease

Although ferrets are susceptible to intestinal parasites, there are surprisingly few clinical reports. The most significant enteric parasitic disease appears to be coccidiosis. Severe morbidity and mortality associated with outbreaks of *Eimeria furonis* have been described in groups of densely populated ferrets.<sup>75</sup> Ferrets of all ages were affected and presented with acute diarrhea and dehydration. Fecal shedding was sporadic and inconsistent. Affected ferrets were treated with aggressive supportive care and sulfadimethoxine; however, some ferrets died despite treatment. Long-term therapy with sulfadimethoxine was ineffectual in completely eradicating the disease.

*Giardia* is rarely isolated in ferrets, and its clinical significance is unknown. In one report, 1180 fecal samples from small mammals in Europe were tested for *Giardia* by ELISA, and five ferrets tested positive for *G. duodenalis*.<sup>62</sup>

Cryptosporidiosis is described in ferrets but may not result in clinical disease.<sup>1,69</sup> Young ferrets can have subclinical infections of *Cryptosporidium parvum*, and coccidial oocysts can be shed by clinically normal ferrets. The zoonotic potential of the ferret genotype of *C. parvum* is unknown; however, if oocysts are detected, discuss the potential of transmission to immunocompromised owners.

### Inflammatory Disease

#### Inflammatory Bowel Disease

Inflammatory bowel disease (IBD) is a relatively common cause of gastroenteritis in ferrets.<sup>8,16</sup> The pathogenesis is unknown. Inflammation, which occurs in the stomach and small intestine, is typically lymphoplasmacytic and can vary in severity. Although some eosinophilic infiltration can be seen, IBD should be distinguished from eosinophilic gastroenteritis, which often involves multiple tissues and eosinophilia (see below). Because it resembles ECE, dietary indiscretion, and lymphoma, IBD is



easily overlooked in ferrets. Chronic GI inflammation has been associated with the development of MALT lymphoma (see above under *Helicobacter*).

Affected ferrets can have loose, seed-like stools, intermittent nausea, occasional vomiting, and weight loss. Clinical signs can be subtle and chronic, or some ferrets can have acute vomiting and lethargy. Ferrets with IBD are usually young or middle-aged adults and in multiple-ferret households; however, typically only one ferret in the household is affected. Results of blood tests may reveal an increase in liver enzymes and plasma globulins, and lymphocytosis is occasionally present. In some ferrets, laboratory results are unremarkable.

Diagnosis is based on clinical signs; a detailed clinical history that eliminates the possibility of exposure to ECE; and results of diagnostic tests. Intestinal lymphoma is the primary differential diagnosis (see Chapter 8). Definitive diagnosis can only be made by histologic examination of gastric and intestinal biopsy samples retrieved surgically or endoscopically.<sup>16</sup> Multiple full-thickness jejunal biopsy specimens may be necessary to distinguish IBD from lymphoma.<sup>86</sup>

Empirical treatment is common. Prednisone (1 mg/kg PO every 12–24 hours) is often used, but some ferrets with IBD respond poorly to long-term corticosteroid treatment. Azathioprine (Imuran, Prometheus Laboratories, San Diego, CA) (0.9 mg/kg PO every 24–72 hours) is another treatment option and seems to be well tolerated by ferrets.<sup>8</sup> Hypoallergenic diets made for cats (z/d feline; Hill's Pet Nutrition, Topeka, KS) can be tried, but ferrets are often reluctant to make dietary conversions. Avoid grain-free formulations, because some have been associated with the formation of cysteine uroliths (see Chapter 4).

### Eosinophilic Gastroenteritis

Eosinophilic gastroenteritis is uncommon in ferrets. Affected animals typically have chronic diarrhea, with or without mucus and blood, and severe weight loss. Granulomas and a thickened bowel may be palpable. Signs may be clinically indistinguishable from persistent ECE. In all reported cases in ferrets, animals are older than 6 months; however, because of the small number of reports, the incidence of disease in young animals is unknown.<sup>10,19,24,61</sup>

Peripheral eosinophilia is common and highly suggestive of the disease. No pathogens have been observed in or isolated from lesions. A causative agent has not been found in ferrets, but food allergy is implicated in humans and some dogs. No reports of food elimination tests in affected ferrets could be found in the literature.

Remission has occurred in ferrets treated with prednisone (1.25–2.5 mg/kg PO every 24 hours for 7 days and every 48 hours thereafter). Immediate recovery also followed removal of an enlarged mesenteric lymph node in one ferret and treatment with ivermectin (0.4 mg/kg SC) in another.<sup>61</sup>

## RECTAL DISEASE

Rectal prolapse can occur in ferrets. It is most often associated with diarrhea and is usually a disease of young ferrets. Possible causes include coccidiosis, proliferative bowel disease, colitis, and neoplasia.

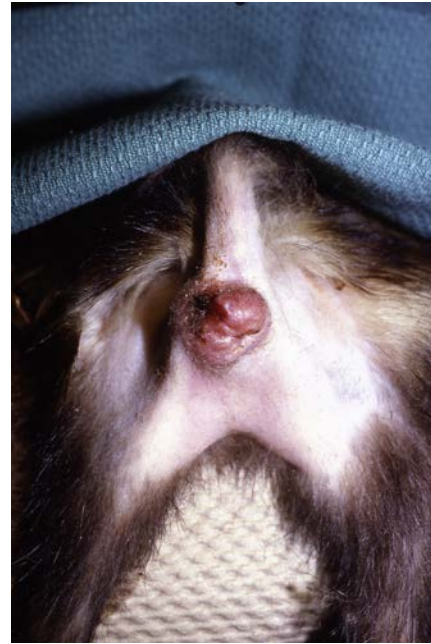

Fig. 3.5 Rectal leiomyosarcoma in a ferret.

In some young ferrets, protrusion of rectal mucosa occurs subsequent to poor anal saccullectomy technique. Straining from prostatic disease, urinary outflow obstruction, or an enlarged sublumbar lymph node (e.g., with lymphoma) may result in rectal protrusion. Anal sac impactions or abscesses are rare in surgically descended ferrets; however, they can be seen in intact ferrets or ferrets that have been neutered but not descended. Sedate the ferret for a controlled removal of anal sac secretions. Anal sac removal is described in Chapter 31.

Neoplasia is rare in the rectal area, with one recent report of anal sac apocrine adenocarcinoma.<sup>57</sup> The author has seen a descended ferret with leiomyosarcoma that surrounded the rectal opening (Fig. 3.5). The ferret presented for rectal prolapse, and a tumor was detected on palpation.

In ferrets that present for straining, perform radiography and a fecal wet mount and flotation to check for parasites. Colonoscopy can be performed to obtain biopsy specimens (see Chapter 34).

Rectal prolapse often resolves with treatment of the underlying condition. Treat with antibiotics and parasiticides, as indicated. Control diarrhea with a kaolin/pectin oral preparation (1–2 mL/kg PO every 2–6 hours as required) and loperamide (0.2 mg/kg every 12 hours) if needed. Apply a topical corticosteroid ointment or hemorrhoid cream for palliation (Preparation H; Pfizer Inc, New York, NY). Although rarely necessary, rectal purse-string sutures can be placed if the prolapse is extensive. However, the owner must closely monitor the ferret for defecation, especially when the stool regains its normal consistency. Sutures should be removed in 2 to 3 days.

In young ferrets that have prolapse from poor anal saccullectomy technique, a surgical procedure to tighten the sphincter may be necessary.<sup>39</sup> Two or four wedge-shaped pieces of skin are removed from the perianal skin and closed with 5-0 suture to decrease the rectal opening. Treatment of rectal neoplasia

involves surgical debulking, possible rectoplasty, and possible localized radiation therapy. Prognosis is poor.

## GASTROINTESTINAL AND PANCREATIC NEOPLASIA

Pyloric adenocarcinoma and MALT lymphoma can occur in ferrets and may be related to chronic *Helicobacter*-induced gastritis (see above). Intestinal lymphoma tends to blend imperceptibly with surrounding tissue, whereas adenocarcinoma has more substantial tumor formation that can lead to intestinal blockage. Clinical signs with adenocarcinoma include nonresponsive diarrhea and weight loss, which is rapidly progressive and fatal. Differential diagnosis may include intestinal foreign body or systemic coronavirus with granulomas.

Intestinal lymphoma is common in ferrets but occurs less frequently than lymphoma in visceral and mesenteric lymph nodes, the liver, and the spleen (see Chapter 8). Intestinal lymphoma results in chronic weight loss and diarrhea and is often overlooked because it resembles other, more common causes of chronic diarrhea, such as ECE and IBD. Neoplasia affecting the gastrointestinal tract is described in more detail in Chapter 8.

Pancreatic endocrine neoplasia is much more common than exocrine neoplasia in ferrets, although both have been reported. Pancreatic islet cell tumor (beta cell carcinoma or insulinoma) is common and results in elevated insulin levels and hypoglycemia (see Chapter 7). Tumors of the exocrine pancreas often demonstrate aggressive behavior and can spread throughout the abdomen, resulting in carcinomatosis.<sup>36,41,71,87</sup> It is important to differentiate carcinomatosis from the gross lesions of ferret systemic coronavirus.

## HEPATOBILIARY DISEASE

In most ferrets with liver disease, a high concentration of alanine aminotransferase (>275 IU/L) is present on plasma biochemical analysis. Alkaline phosphatase and  $\gamma$ -glutamyl transferase concentrations are sometimes increased. High total bilirubin levels can be seen, and affected ferrets are usually icteric with pigmented urine. Be cautious in diagnosing liver disease in ferrets based solely on high liver enzyme concentrations, because these findings are also common in ferrets with intestinal disease. Instead, base the diagnosis on persistently high liver enzyme concentrations, radiographic and ultrasound findings, and—for definitive diagnosis—analysis of liver biopsy samples. Although ultrasound-guided needle biopsy of the liver is possible, a full abdominal exploratory is often recommended because of the likelihood of concomitant disease in ferrets.

### Inflammatory Hepatitis

Chronic lymphocytic-plasmacytic portal hepatitis is a common finding on histologic examination of hepatic biopsy samples in ferrets and is often subclinical. The cause is unknown but may be related to GI disease, such as IBD. In one ferret colony, chronic lymphocytic cholangiohepatitis with biliary hyperplasia was reported in 8 of 34 cohabitating ferrets.<sup>26</sup> Spiral-shaped bacteria were identified in the livers of three ferrets. The clustering of cases and pathologic findings suggested a possible infectious cause.

Recently, a novel hepatitis E virus (HEV) was identified in ferrets in the Netherlands, as well as in ferrets imported from the United States into Japan.<sup>44,67</sup> One study of 63 imported ferrets in Japan demonstrated subclinical infection, acute hepatitis, or persistent infection.<sup>44</sup> Hepatitis E virus is also known to cause acute hepatitis in people.<sup>51</sup> Although HEV is zoonotic, there are no reports to date of disease in humans resulting from exposure to infected ferrets.

### Copper Toxicosis

Copper toxicosis was diagnosed in two sibling ferrets on the basis of high hepatic copper concentrations and histologic changes in hepatic tissue.<sup>25</sup> Clinical signs were mostly nonspecific and included severe CNS depression with hypothermia and hyperthermia, respectively. One ferret was icteric. Both ferrets died within a few days of clinical evaluation despite supportive care. A genetic predisposition to copper toxicosis was proposed, because the ferrets had the same phenotypic coat color and no environmental source of copper could be identified.

Copper toxicity was identified and treated in a 5-year-old pet ferret that presented with lethargy and high liver enzymes.<sup>30</sup> Liver biopsy revealed vacuolar changes, and 25% to 50% of hepatocytes stained positive for intracellular copper. Quantitative copper levels on a liver sample were 1720 ppm (normal in other species, 120–400 ppm). Treatment consisted of penicillamine (15 mg/kg PO every 12 hours), liver protectants (silybin, S-adenosylmethionine) and a low-copper diet. Dietary levels of copper are being evaluated in an ongoing study (Jennifer Graham, DVM, personal communication, December 2019).

### Neoplasia

Several different types of hepatic neoplasms have been reported in ferrets (see Chapter 8).<sup>15</sup> Biliary cystadenomas are common and are often incidental findings. However, their multilocular cystic structures—although benign—can become quite large and invasive, resulting in significant morbidity.<sup>38</sup> When caught early, cystadenomas can be successfully treated with a partial liver lobectomy (see Chapter 31).

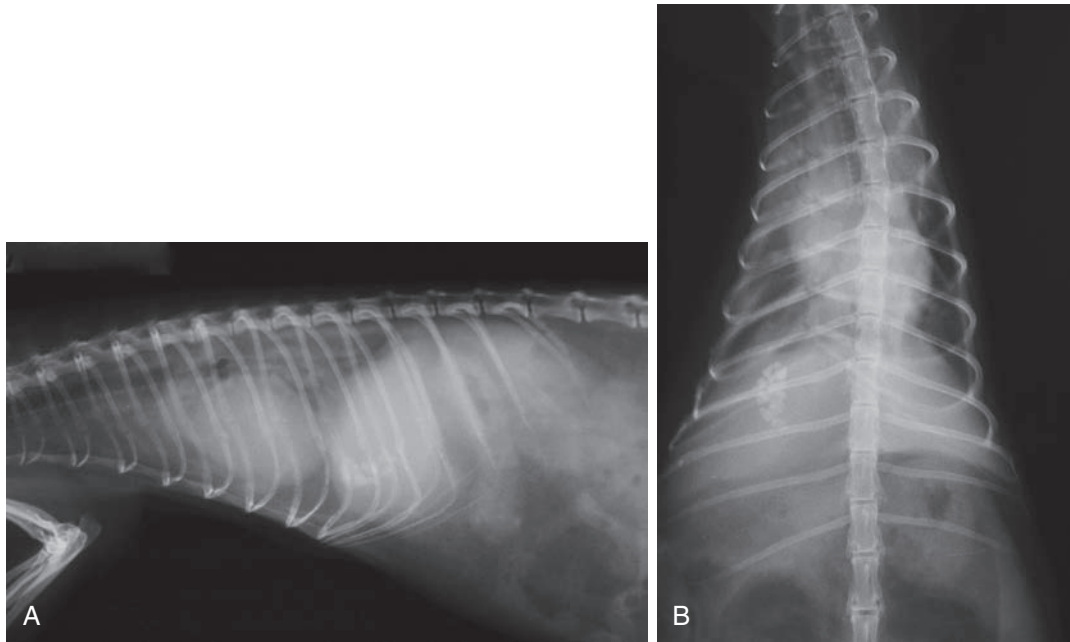
Pancreatic islet cell tumors, adrenal adenocarcinoma, exocrine pancreatic carcinomas, and hemangiosarcoma can metastasize to the liver. Prognosis is guarded regardless of tumor type.

### Other Hepatopathies

Other than neoplastic diseases, primary hepatopathies are uncommon in ferrets. One 6-year-old ferret had an acute liver lobe torsion of the left lateral lobe.<sup>84</sup> The ferret presented with an acute abdomen and severe jaundice. Liver lobe torsion was diagnosed by radiology and ultrasonography. Hepatic lipodosis can be found in association with long-standing anorexia, which can result from chronic GI disease. Steroid hepatopathy is rare in ferrets, even with long-term steroid administration or hyperadrenocorticism.

### Gall Bladder Disease

Cholelithiasis and cholestasis have been described in ferrets and may be underdiagnosed in clinical practice.<sup>32,34,37</sup> One ferret had



**Fig. 3.6** (A) Lateral and (B) ventrodorsal radiographs in a ferret that presented with heart failure. There is cardiomegaly with edema and several choleliths in the gall bladder, which were considered an incidental finding.

cholecystitis with gallbladder rupture and subsequent bile peritonitis. Bacteriologic culture of the gallbladder revealed a pure growth of *Pseudomonas aeruginosa*.<sup>37</sup> In some other ferrets with extrahepatic biliary obstruction, no bacteria were cultured. This author treated a ferret with a foreign body in the proximal duodenum that obstructed the bile duct as it entered the small intestine. The ferret presented with jaundice and anorexia and had liver enzyme elevation and severe bilirubinemia. Enterotomy and foreign body removal were curative. Extrahepatic biliary obstruction can also be caused by pancreatic or other neoplasia.<sup>71</sup>

Diagnosis of gallbladder disease generally requires radiographs and ultrasound. Interestingly, one ferret with cholestasis, cholelithiasis, and very high liver enzymes had no clinical signs associated with liver disease.<sup>32</sup> This author has also found choleliths in several ferrets, which appeared to be incidental findings. Screening radiographs showed mineral densities in the right cranial abdomen, which were associated with the liver and confirmed on ultrasonography (Fig. 3.6).

Treatment for gallbladder disease is either medical or surgical. If possible, perform an ultrasound-guided cholecystocentesis to sample the bile for culture. Whereas some reports indicated no bacterial growth, *Pseudomonas* species, *E.coli*, and *Clostridium* species have been cultured.<sup>37,38</sup> Choose combination antibiotic therapy that targets both gram-negative bacteria and anaerobes. Surgical procedures include cholecystectomy or choledochoduodenostomy.

## REFERENCES

1. Abe N, Iseki M. Identification of genotypes of *Cryptosporidium parvum* isolates from ferrets in Japan. *Parasitol Res.* 2003;89(5):422–424.
2. Alder JD, Ewing PJ, Mitten MJ, et al. Relevance of the ferret model of *Helicobacter*-induced gastritis to evaluation of antibacterial therapies. *Am J Gastroenterol.* 1996;91(11):2347–2354.
3. Antinoff N. Diagnosis and successful treatment of myasthenia gravis in a ferret. *Proc Ann Conf Assoc Exot Mamm Vet.* 2015. San Antonio, Texas.
4. Autieri CR, Miller CL, Scott KE, et al. Systemic coronaviral disease in 5 ferrets. *Comp Med.* 2015;65(6):508–516.
5. Avallone G, Forlani A, Tecilla M, et al. Neoplastic diseases in the domestic ferret (*Mustela putorius furo*) in Italy: classification and tissue distribution of 856 cases (2000–2010). *BMC Vet Res.* 2016;12(1):275–283.
6. Bell JA, Manning DD. Evaluation of *Campylobacter jejuni* colonization of the domestic ferret intestine as a model of proliferative colitis. *Am J Vet Res.* 1991;52(6):826–832.
7. Blanco MC, Fox JG, Rosenthal K, et al. Megaesophagus in nine ferrets. *J Am Vet Med Assoc.* 1994;205(3):444–447.
8. Burgess M, Garner M. Clinical aspects of inflammatory bowel disease in ferrets. *Exot Dvm.* 2002;4(2):29–34.
9. Caliguiri R, Bellah JR, Collins BR, et al. Medical and surgical management of esophageal foreign body in a ferret. *J Am Med Vet Assoc.* 1989;195(7):969–971.
10. Carmel B. Eosinophilic gastroenteritis in three ferrets. *Vet Clin North Am Exot Anim Pract.* 2006;9(3):707–712.
11. Castillo-Alcala F, Mans C, Bos AS, et al. Clinical and pathologic features of an adenomatous polyp of the colon in a domestic ferret (*Mustela putorius furo*). *Can Vet J.* 2010;51(11):1261–1264.
12. Church RR. Impact of diet on the dentition of the domesticated ferret. *Exot Dvm.* 2007;9(2):30–39.
13. Cooper DM, Swanson DL, Gebhart CJ. Diagnosis of proliferative enteritis in frozen and formalin-fixed, paraffin-embedded tissues from a hamster, horse, deer and ostrich using a *Lawsonia intracellularis*-specific multiplex PCR assay. *Vet Microbiol.* 1997;54:47–62.
14. Couturier J, Huynh M, Boussarie D, et al. Autoimmune myasthenia gravis in a ferret. *J Am Vet Med Assoc.* 2009;235(12):1462–1466.
15. Darby C, Ntavlourou V. Hepatic hemangiosarcoma in two ferrets (*Mustela putorius furo*). *Vet Clin North Am Exot Anim Pract.* 2006;9(3):689–694.



16. Devaux L, Huynh M, Nicolier A. Lymphoplasmacytic gastritis in ferrets: case series. *Proc Annual Conf Assoc Exot Mamm Vet*. 2014.
17. Erdman SE, Correa P, Coleman LA, et al. *Helicobacter mustelae*-associated gastric MALT lymphoma in ferrets. *Am J Pathol*. 1997;151(1):273–280.
18. Eroshin VV, Reiter AM, Rosenthal K, et al. Oral examination results in rescued ferrets: clinical findings. *J Vet Dent*. 2011; 28(1):8–15.
19. Fazakas S. Eosinophilic gastroenteritis in a domestic ferret. *Can Vet J*. 2000;41(9):707–709.
20. Fox JG, Correa P, Taylor NS, et al. *Helicobacter mustelae*-associated gastritis in ferrets. An animal model of *Helicobacter pylori* gastritis in humans. *Gastroenterology*. 1990;99(2):352–361.
21. Fox JG, Dangler CA, Sager W, et al. *Helicobacter mustelae*-associated gastric adenocarcinoma in ferrets (*Mustela putorius furo*). *Vet Pathol*. 1997;34(3):225–229.
22. Fox JG, Marini RP. *Helicobacter mustelae* infection in ferrets: pathogenesis, epizootiology, diagnosis, and treatment. *Semin Avian Exot Pet Med*. 2001;10(1):36–44.
23. Fox JG, Murphy JC, Ackerman JI, et al. Proliferative colitis in ferrets. *Am J Vet Res*. 1982;43(5):858–864.
24. Fox JG, Palley LS, Rose R. Eosinophilic gastroenteritis with Splendore-Hoeppli material in the ferret (*Mustela putorius furo*). *Vet Pathol*. 1992;29(1):21–26.
25. Fox JG, Zeman DH, Mortimer JD. Copper toxicosis in sibling ferrets. *J Am Vet Med Assoc*. 1994;205(8):1154–1156.
26. Garcia A, Erdman SE, Xu S, et al. Hepatobiliary inflammation, neoplasia, and argyrophilic bacteria in a ferret colony. *Vet Pathol*. 2002;39(2):173–179.
27. Garner MM, Ramsell K, Morera N, et al. Clinicopathologic features of a systemic coronavirus-associated disease resembling feline infectious peritonitis in the domestic ferret (*Mustela putorius*). *Vet Pathol*. 2008;45(2):236–246.
28. Gnirs K, Quinton JF, Dally C, et al. Cerebral pyogranuloma associated with systemic coronavirus infection in a ferret. *J Small Anim Pract*. 2016;57(1):36–39.
29. Graham J, Fidel J, Mison M. Rostral maxillectomy and radiation therapy to manage squamous cell carcinoma in a ferret. *Vet Clin North Am Exot Anim Pract*. 2006;9(3):701–706.
30. Graham JE, Heinze C, Beamer G, et al. Management of copper toxicosis in a ferret (*Mustela putorius furo*). *Proc Ann Conf Assoc Exot Mamm Vet (ExotisCon)*. 2016:441.
31. Webb J, Graham JE, Fordham M, et al. Diagnosis and treatment of esophageal foreign body or stricture in three ferrets (*Mustela putorius furo*). *J Am Vet Med Assoc*. 2017;251(4):451–457.
32. Hall BA, Ketz-Riley CJ. Cholestasis and cholelithiasis in a domestic ferret (*Mustela putorius furo*). *J Vet Diagn Invest*. 2011;23(4):836–839.
33. Harms CA, Andrews GA. Megaesophagus in a domestic ferret. *Lab Anim Sci*. 1993;43(5):506–508.
34. Hauptman K, Jekl V, Knotek Z. Extrahepatic biliary obstruction in two ferrets (*Mustela putorius furo*). *J Small Anim Pract*. 2011;52(7):371–375.
35. Hinton JD, Aitken-Palmer C, Joyner PH, et al. Fatal gastric dilation in two adult black-footed ferrets (*Mustela nigripes*). *J Zoo Wildl Med*. 2016;47(1):367–369.
36. Hoefler HL, Patnaik AK, Lewis AD. Pancreatic adenocarcinoma with metastasis in two ferrets. *J Am Vet Med Assoc*. 1992;201(3):466–467.
37. Huynh M, Guillaumot P, Hernandez J, Ragetly G. Gall bladder rupture associated with cholecystitis in a domestic ferret (*Mustela putorius*). *J Small Anim Pract*. 2014;55(9):479–482.
38. Huynh M, Laloi F. Diagnosis of liver disease in domestic ferrets (*Mustela putorius*). *Vet Clin North Am Exot Anim Pract*. 2013;16(1):121–144.
39. Johnson-Delaney CA, ed. Common surgical procedures. *Ferret Medicine and Surgery*. Boca Raton, FL: CRC Press; 2017:418–419.
40. Johnson-Delaney CA. Anatomy and disorders of the oral cavity of ferrets and other exotic companion carnivores. *Vet Clin North Am Exot Anim Pract*. 2016;19(3):901–928.
41. Kornegay RW, Morris JM, Cho D, Lozano-Alarcon F. Pancreatic adenocarcinoma with osseous metaplasia in a ferret. *J Comp Path*. 1991;105(1):117–121.
42. Krueger KL, Murphy JC, Fox JG. Treatment of proliferative colitis in ferrets. *J Am Vet Med Assoc*. 1989;194(10):1435–1436.
43. Li X, Fox JG, Padrid PA. Neoplastic diseases in ferrets: 574 cases (1968–1997). *J Am Vet Med Assoc*. 1998;212(9):1402–1406.
44. Li TC, Yang T, Yoshizaki S, et al. Ferret hepatitis E virus infection induces acute hepatitis and persistent infection in ferrets. *Vet Microbiol*. 2016;183:30–36.
45. Lucas J, Lucas A, Furber H, et al. *Mycobacterium genavense* infection in two aged ferrets with conjunctival lesions. *Aust Vet J*. 2000;78(10):685–689.
46. Lugton IW, Wobeser G, Morris RS, Caley P. Epidemiology of *Mycobacterium bovis* infection in feral ferrets (*Mustela furo*) in New Zealand: II. Routes of infection and excretion. *N Z Vet J*. 1997;45(4):151–157.
47. Lunn JA, Martin P, Zaki S, et al. Pneumonia due to *Mycobacterium abscessus* in two domestic ferrets (*Mustela putorius furo*). *Aust Vet J*. 2005;83(9):542–546.
48. Marini RP, Fox JG, Taylor NS, et al. Ranitidine bismuth citrate and clarithromycin, alone or in combination, for eradication of *Helicobacter mustelae* in ferrets. *Am J Vet Res*. 1999;60(10):1280–1286.
49. Martinez J, Renacher M, Perpiñan D, Ramis A. Identification of group 1 coronavirus antigen in multisystemic granulomatous lesions in ferrets (*Mustela putorius furo*). *J Comp Pathol*. 2008;138(1):54–58.
50. Maurer KJ, Fox JG. Salivary microliths. In: Fox JG, Marini RP, eds. *Biology and Disease of the Ferret*. 3rd ed. Hoboken: Wiley Blackwell; 2014.
51. Meng XJ. Hepatitis E virus: animal reservoirs and zoonotic risk. *Vet Microbiol*. 2010;140(3–4):256–265.
52. Mentre V, Bulliot C. A retrospective study of 17 cases of mycobacteriosis in domestic ferrets (*Mustela putorius furo*) between 2005 and 2013. *J Exot Anim Med*. 2015;24(3):340–349.
53. Minami S, Terada Y, Shimoda H, et al. Establishment of serological test to detect antibody against ferret coronavirus. *J Vet Med Sci*. 2016;78(6):1013–1017.
54. Mullen HS, Scavelli TD, Quesenberry KE, Hillyer E. Gastrointestinal foreign body in ferrets: 25 cases (1986–1990). *J Am Anim Hosp Assoc*. 1992;28:13–19.
55. Murray J, Kiupel M, Maes RK. Ferret coronavirus-associated diseases. *Vet Clin North Am Exot Anim Pract*. 2010;13(3):543–560.
56. Nakata M, Miwa Y, Tsuboi M, Uchida K. Mycobacteriosis in a domestic ferret (*Mustela putorius furo*). *J Vet Med Sci*. 2014;76(5):705–709.
57. Nakata M, Miwa Y, Nakayama H, et al. Localised radiotherapy for a ferret with possible anal sac apocrine adenocarcinoma. *J Small Anim Pract*. 2008;49(9):476–478.
58. Nemeč A, Zadravec M, Račnik J. Oral and dental diseases in a population of domestic ferrets (*Mustela putorius furo*). *J Small Anim Pract*. 2016;57(10):553–560.
59. Nemeč A, Brown AW, Wallace SM, et al. Immune response to and histopathology of *Campylobacter jejuni* infection in ferrets (*Mustela putorius furo*). *Comp Med*. 2009;59(4):363–371.



60. Otto G, Fox JG, Wu P, et al. Eradication of *Helicobacter mustelae* from the ferret stomach: an animal model of Helicobacter pylori chemotherapy. *Antimicrob Agents Chemother*. 1990;34(6):1232–1236.
61. Palley LS, Fox JG. Eosinophilic gastroenteritis in the ferret. In: Kirk RW, Bonagura JD, eds. *Kirk's Current Veterinary Therapy XI: Small Animal Practice*. Philadelphia: WB Saunders; 1992:1182–1184.
62. Pantchev N, Broglia A, Paoletti B, et al. Occurrence and molecular typing of *Giardia* isolates in pet rabbits, chinchillas, guinea pigs and ferrets collected in Europe during 2006–2012. *Vet Rec*. 2014;175(1):18.
63. Parkinson S, Tolbert K, Messenger K, et al. Evaluation of the effect of orally administered acid suppressants on intragastric pH in cats. *J Vet Intern Med*. 2015;29(1):104–112.
64. Perpiñan D, Lopez C. Clinical aspects of systemic granulomatous inflammatory syndrome in ferrets (*Mustela putorius furo*). *Vet Rec*. 2008;162(6):180–184.
65. Piseddu E, Trotta M, Tortoli E, et al. Detection and molecular characterization of *Mycobacterium celatum* as a cause of splenitis in a domestic ferret (*Mustela putorius furo*). *J Comp Pathol*. 2011;144(2–3):214–218.
66. Poddar S, Jacob S. Gross and microscopic anatomy of the major salivary glands of the ferret. *Acta Anat*. 1977;98(4):434–443.
67. Raj VS, Smits SL, Pas SD, et al. Novel hepatitis E virus in ferrets, The Netherlands. *Emerg Infect Dis*. 2012;18(8):1369–1370.
68. Ramsell KD, Garner MM. Disseminated idiopathic myofasciitis in ferrets. *Vet Clin North Am Exot Anim Pract*. 2010;13(3):561–575.
69. Rehg JE, Gigliotti F, Stokes DC. Cryptosporidiosis in ferrets. *Lab Anim Sci*. 1988;38(2):155–158.
70. Rice LE, Stahl SJ, McLeod Jr CG. Pyloric adenocarcinoma in a ferret. *J Am Vet Med Assoc*. 1992;200(8):1117–1118.
71. Rhody JL, Williams BH. Exocrine pancreatic adenocarcinoma and associated extrahepatic biliary obstruction in a ferret. *J Exot Pet Med*. 2013;22(2):206–211.
72. Saunders GK, Thomsen BV. Lymphoma and *mycobacterium avium* infection in a ferret (*Mustela putorius furo*). *J Vet Diagn Invest*. 2006;18:513–515.
73. Schulman FY, Montali RJ, Hauer PJ. Gastroenteritis associated with clostridium perfringens type A in black-footed ferrets (*Mustela nigripes*). *Vet Pathol*. 1993;30(3):308–310.
74. Schultheiss PC, Dolginow SZ. Granulomatous enteritis caused by *Mycobacterium avium* in a ferret. *J Am Vet Med Assoc*. 1994;204(8):1217–1218.
75. Sledge DG, Bolin SR, Lim A, et al. Outbreaks of severe enteric disease associated with *Eimeria furonis* infection in ferrets (*Mustela putorius furo*) of 3 densely populated groups. *J Am Vet Med Assoc*. 2011;239(12):1584–1588.
76. Sleeman JM, Clyde VL, Jones MP, Mason GL. Two cases of pyloric adenocarcinoma in the ferret (*Mustela putorius furo*). *Vet Rec*. 1995;17:272.
77. Stables R, Campbell C, Clayton N, et al. Gastric anti-secretory, mucosal protective, anti-pepsin and anti-*Helicobacter* properties of ranitidine bismuth citrate. *Aliment Pharmacol Ther*. 1993;7(3):237–246.
78. Swennes AG, Fox JG. Bacterial and mycoplasmal diseases: *Helicobacter mustelae*. In: Fox JG, Marini RP, eds. *Biology and Diseases of the Ferret*. 3rd ed. Hoboken: Wiley Blackwell; 2014:528–534.
79. Swennes AG, Fox JG. Bacterial and mycoplasmal diseases: proliferative bowel disease. In: Fox JG, Marini RP, eds. *Biology and Diseases of the Ferret*. 3rd ed. Hoboken, NJ: Wiley Blackwell; 2014:538–541.
80. Thas I, Cohen-Solal NA. Acquired oronasal fistula in a domestic ferret (*Mustela putorius furo*). *J Exot Pet Med*. 2014;23(4):409–414.
81. Tolbert K, Bissett S, King A, et al. Efficacy of oral famotidine and 2 omeprazole formulations for the control of intragastric pH in dogs. *J Vet Intern Med*. 2011;25(1):47–54.
82. Torres-Medina A. Isolation of an atypical rotavirus causing diarrhea in neonatal ferrets. *Lab Anim Sci*. 1987;37(2):167–171.
83. Valheim M, Djonne B, Heiene R, Caugant DA. Disseminated *Mycobacterium celatum* (type 3) infection in a domestic ferret (*Mustela putorius furo*). *Vet Pathol*. 2001;38(4):460–463.
84. Vilalta L, Espada Y, Majo N, Martorell J. Liver lobe torsion in a domestic ferret (*Mustela putorius furo*). *J Exot Pet Med*. 2016;25(4):321–326.
85. Wagner R, Finkler MR. Diagnosing gastric hairballs in ferrets. *Exot Dvm*. 2008;10(2):9–23.
86. Watson MK, Cazzini P, Mayer J, et al. Histology and immunohistochemistry of severe inflammatory bowel disease versus lymphoma in the ferret (*Mustela putorius furo*). *J Vet Diagn Invest*. 2016;28(3):198–206.
87. Whittington JK, Emerson JA, Satkus TM, et al. Exocrine pancreatic carcinoma and carcinomatosis with abdominal effusion containing mast cells in a ferret (*Mustela putorius furo*). *Vet Clin North Am Exot Anim Pract*. 2006;9(3):643–650.
88. Williams BH, Kiupel M, West KH, et al. Coronavirus-associated epizootic catarrhal enteritis in ferrets. *J Am Vet Med Assoc*. 2000;217(4):526–530.
89. Wise AG, Kiupel M, Maes RK. Molecular characterization of a novel coronavirus associated with epizootic catarrhal enteritis (ECE) in ferrets. *Virology*. 2006;349(1):164–174.
90. Wise AG, Smedley RC, Kiupel M, Maes RK. Detection of group C rotavirus in juvenile ferrets (*Mustela putorius furo*) with diarrhea by reverse transcription polymerase chain reaction: sequencing and analysis of the complete coding region of the VP6 gene. *Vet Pathol*. 2009;46(5):985–991.