

## Review Article

# The Role of Continuous Peripheral Nerve Blocks

José Aguirre,<sup>1</sup> Alicia Del Moral,<sup>2</sup> Irina Cobo,<sup>2</sup> Alain Borgeat,<sup>1</sup> and Stephan Blumenthal<sup>3</sup>

<sup>1</sup> Division of Anesthesiology, Balgrist University Hospital, 8008 Zurich, Switzerland

<sup>2</sup> Department of Anesthesiology, General University Hospital of Valencia, 46014 Valencia, Spain

<sup>3</sup> Department of Anesthesiology, Triemli Hospital, 8063 Zurich, Switzerland

Correspondence should be addressed to José Aguirre, jose.aguirre@balgrist.ch

Received 7 February 2012; Revised 10 April 2012; Accepted 17 April 2012

Academic Editor: Didier Morau

Copyright © 2012 José Aguirre et al. This is an open access article distributed under the Creative Commons Attribution License, which permits unrestricted use, distribution, and reproduction in any medium, provided the original work is properly cited.

A continuous peripheral nerve block (cPNB) is provided in the hospital and ambulatory setting. The most common use of cPNBs is in the peri- and postoperative period but different indications have been described like the treatment of chronic pain such as cancer-induced pain, complex regional pain syndrome or phantom limb pain. The documented benefits strongly depend on the analgesia quality and include decreasing baseline/dynamic pain, reducing additional analgesic requirements, decrease of postoperative joint inflammation and inflammatory markers, sleep disturbances and opioid-related side effects, increase of patient satisfaction and ambulation/functioning improvement, an accelerated resumption of passive joint range-of-motion, reducing time until discharge readiness, decrease in blood loss/blood transfusions, potential reduction of the incidence of postsurgical chronic pain and reduction of costs. Evidence deriving from randomized controlled trials suggests that in some situations there are also prolonged benefits of regional anesthesia after catheter removal in addition to the immediate postoperative effects. Unfortunately, there are only few data demonstrating benefits after catheter removal and the evidence of medium- or long-term improvements in health-related quality of life measures is still lacking. This review will give an overview of the advantages and adverse effects of cPNBs.

## 1. Background

Since its first description in 1946, cPNB has evolved from a case report of a needle inserted through a cork taped to a patient's chest to a wide-spread and validated analgesic technique in the postoperative setting [1]. The earliest reports of cPNB focused on prolonging intraoperative surgical anesthesia and the treatment of intractable hiccups [1–3]. The indication for cPNB has evolved since then, and many indications have been described in the literature: treatment of vasospasm induced by Raynaud disease [4]; induction of sympathectomy and vasodilation for improvement of blood flow after vascular surgery/trauma [5, 6], replantation or limb salvage [7, 8]; treatment of peripheral embolism [9, 10]; analgesia in the setting of trauma [11]; treatment of chronic pain syndrome such as trigeminal neuralgia [12], complex regional pain syndrome [13], terminal cancer pain, [14], and phantom limb pain [15, 16]. Independently of these indications, the majority of publications dealing with cPNB focus on postsurgical pain treatment, where evidence supports the concept that regional anesthesia and analgesia

offers superior pain relief to systemic opioid analgesia following major surgery [17]. However, postsurgical pain is the only indication which has been validated using randomized controlled trials (RCTs) [18–22]. Compared with opioid analgesics cPNBs provide superior analgesia with a lower incidence of opioid-induced side effects like nausea, vomiting, pruritus, and sedation [21]. Moreover, in a meta-analysis Rodgers et al. suggested that mortality associated with major surgery was reduced by 30% when central regional anesthesia was used combined or not with general anesthesia [23]. On the other hand, a Cochrane review showed no impact of regional anesthesia compared to general anesthesia on mortality after hip fracture. Only the acute postoperative confusion was reduced after regional anesthesia [24]. However, for continuous peripheral regional anesthesia these findings cannot be extrapolated. Though, continuous peripheral regional anesthesia offers improved functional outcomes after extremity surgery at least for a short term period (up to 6 months) [25–27].

Despite this evidence of value, the hypothesis that regional anesthesia has an overall beneficial and long-lasting

TABLE 1: Incidence of persistent postsurgical pain and associated disability. Based on data from [37, 71–73].

Surgery	Incidence	Severe disability
Amputation	30–85%	5–10%
Thoracotomy	5–67%	10%
Inguinal hernia repair	10–30%	2–4%
Breast surgery	11–65%	5–10%
Coronary artery bypass graft	30–50%	5–10%
Cesarean section	10–18%	4%

effect on patient outcome following surgery still remains difficult to prove and has been challenged, especially in times with reduced resources. For more than 30 years, regional anesthesia has challenged anesthesiologists to determine whether it offers real benefits over other types of anesthesia, such as preserving cognitive function after major surgery compared to general anesthesia, improving long-term joint function and rehabilitation leading to earlier return to work, reducing costs, reducing the need for blood transfusions and increasing patient-reported outcomes such as satisfaction, quality of life, and quality of recovery.

The implications of regional anesthesia after major surgery are multifaceted and not fully elucidated, thus requiring future studies with a focus on evaluating issues like implicating roles of mismanaged pain, environmental factors, stress responses associated with the perioperative period, long-term followups focusing on joint mobilisation and quality of life.

This paper will elucidate the benefits of cPNB over intravenous analgesia and single-shot perineural blocks (sPNB) according to the published literature and show some aspects for possible future directions.

## 2. The Need for Optimal Postsurgical Analgesia

In western countries, 50–70% of in hospital patients suffer from moderate-to-severe pain after surgery [28], and 40% of ambulatory surgical patients have moderate/severe pain during the first 24–48 h [29]. Orthopedic surgery remains the major indication for peripheral nerve blocks for anesthesia and postoperative analgesia [30]. Orthopedic surgery is one of the most if not the most painful surgery [31, 32]. In fact, after orthopedic surgery significant increases in pain scores may persist for 2 to 3 days [33, 34]. In postoperative evaluations of hip and knee surgeries using questionnaires 28% of patients after total hip arthroplasty [35] and 33% of patients after total knee arthroplasty [36] suffered from chronic pain. The common finding between these patients was the intensity of immediate postoperative pain. Intense persistent postsurgical pain has indeed been described as a risk factor for the development of chronic pain [37, 38]. Therefore, an improvement in postsurgical pain therapy could be an important factor to reduce pain chronification and its adverse effects on health system costs [39] (Table 1).

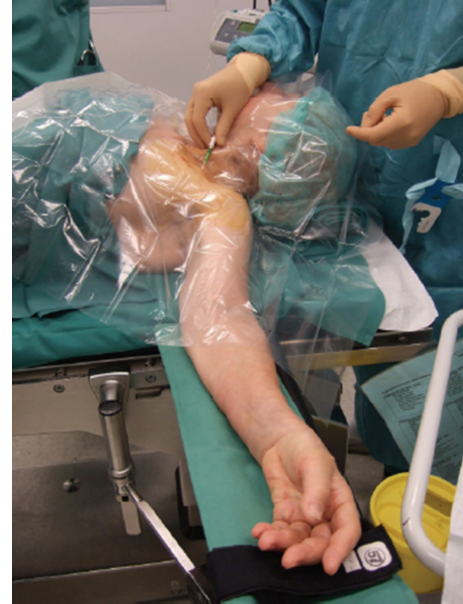

FIGURE 1: Sterile precautions for regional anesthesia.

## 3. cPNB Insertion Techniques

**3.1. Skin Preparation and Patient Draping.** Sterility is of utmost importance for the performance of cPNB independently of the technique performed (neurostimulation or ultrasound). The American Society of Regional Anesthesia and Pain Medicine (ASRA) recommends antiseptic hand washing, sterile gloves, surgical mask and hats, and the use of alcohol-based chlorhexidine antiseptic solutions [40]. Further sterile protection of the ultrasound probe is essential [41]. The catheter dressing after insertion has to be sterile and transparent to avoid and recognize catheter infection (Figures 1 and 2).

**3.2. Needle Choice.** Short bevel needles are widely accepted as standard practice in regional anesthesia. The literature is not conclusive to support the notion that nerve injury is minimized using short bevel needles [42–44]. The use of ultrasound for catheter placement is increasing and apart from thin-walled needles also Tuohy needles remain popular with this technique. However, despite the use of ultrasound, the risk of intraepineurial local anesthetic injections may be quite common as described by Liu et al. in a large prospective study on ultrasound-guided interscalene and supraclavicular blockade for shoulder surgery [45] and different case reports [46, 47]. For fascia iliaca blocks a blunt needle (pencil point or Tuohy) offers a better recognition of a “pop” as tactile feedback when the different fascias are pierced [48].

**3.3. Nerve Stimulation.** Before introduction of portable nerve stimulators in 1962 [49], PNB were performed using induced paresthesia (“no paresthesia and no analgesia”), [50] fascial “pop,” [51] or even with fluoroscopic guidance [52]. Despite the fact that there has never been a repeated comparison of nerve stimulation and paresthesia which has

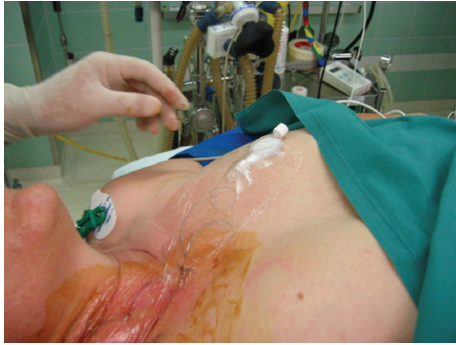

FIGURE 2: Sterile catheter dressing after catheter tunneling.

been for a long time the most wide-spread technique and is still used, nerve stimulation has been considered the gold standard at least until the introduction of ultrasound in 1989 [53]. Using electrical current to place an insulated needle close to a peripheral nerve to inject local anesthetic or place a perineural catheter is the basic principle of nerve stimulation [54]. Without doubt, if properly used nerve stimulation offers a high success rate for sPNB and for cPNB [55–62]. The most important rules to achieve competitive success rates for sPNB are

- (i) use a proper technique with logical (adaptable to all patients, independent of body height and weight) and reproducible landmarks [56–59];
- (ii) accept only responses with previously described high success rate (e.g., distal responses of the posterior cord for infraclavicular block; inversion for popliteal block) [56, 57, 63];
- (iii) inject only at following nerve stimulator setting (with still weak motor response visible): amplitude width: 0.1 ms, frequency: 2 Hz, and impulse: 0.3–0.4 mA;
- (iv) use the correct block for the planned surgery (e.g., not an interscalene block for elbow surgery [64] but an infraclavicular block) (Table 2).

Often comparative studies which described unacceptable low success rate for nerve stimulation are based on violation of at least one of the above-mentioned principles [64–67]. Although unclear data exists showing a consistent relationship between stimulating current and proximity to the nerve [68–70], the above-mentioned nerve stimulator setting is associated with high success and low complication rates [56].

For catheter placement, it is of prime importance that the needle is guided tangentially to the nerve to avoid nerve injury and to guarantee a catheter placement parallel to the nerve (Figure 3). In this case, a 3-orifice catheter will facilitate a spread of the local anesthetic along the nerve compared with an end-orifice catheter. To avoid early catheter displacement, the insertion should be performed before injection of local anesthetic [74]. To our mind, for catheter placement the cannula over the needle technique [26] threading the perineural catheter 3–4 cm past the tip of

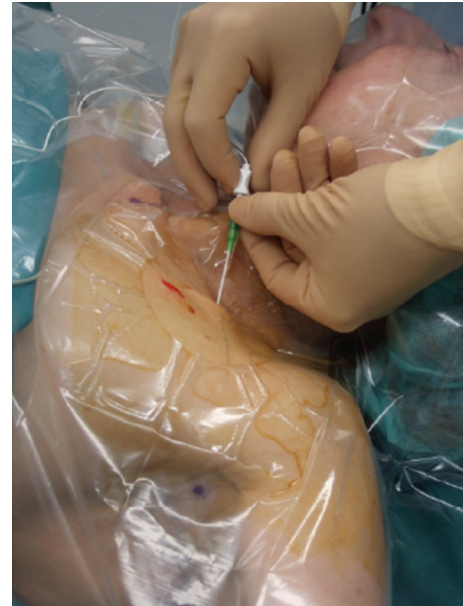


FIGURE 3: Cannula over the needle technique.

the cannula with subsequent subcutaneous tunneling for 4–5 cm to avoid displacement after insertion is the technique of choice (Figures 3, 4, 5 and 6). The optimal distance to advance a perineural catheter past the needle tip remains unknown according to the literature, but data suggests that increasing the insertion distance >5 cm is correlated with an increased risk of catheter coiling [75]. As there is no data suggesting insertion lengths >5 cm, the maximal insertion depth should be considered 5 cm [75, 76].

An further option is the use of stimulating catheters: with an insulated needle electrical current is used to locate the target nerve, followed by the insertion of a perineural catheter that conducts current to its tip [77]. Although there is evidence supporting some advantages in certain anatomic locations (popliteal fossa, femoral, and interscalene region) [78–80], the clinical relevance considering the significantly increased material costs remains unclear [81–83].

**3.4. Ultrasound.** The introduction of ultrasound for regional anesthesia has been an important development. First it was considered a supplement to nerve stimulation, now it is recognized as a “stand-alone” technique [84]. Unfortunately, a nonending dispute between nerve stimulation and ultrasound has distracted the focus of interest from clinically important questions [85, 86]. Almost all comparative studies violate in a way or another at least one of the crucial points for correct nerve stimulation mentioned above and have been subject to criticism [87–89]. The recent review by Abrahams et al. [90] dealing with this topic emphasized the superiority of ultrasound according to the present “evidence” and was severely disputed in web publications of letters to the editor [91]. There are also some publications comparing ultrasound-guided catheter insertion versus nerve stimulation catheter insertion [92–95]. Actually, some of these studies report at least similar analgesia between

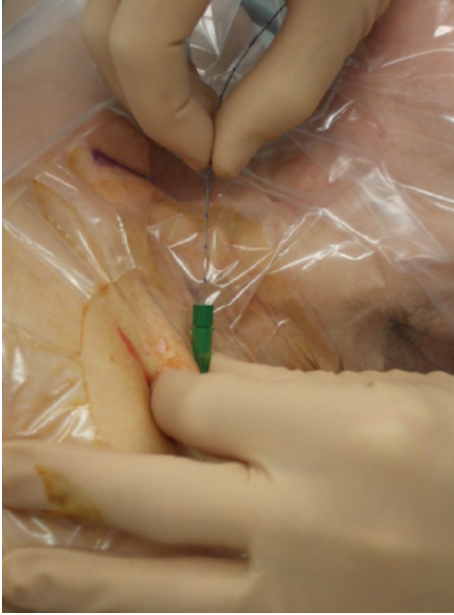


FIGURE 4: Catheter insertion through the cannula. Catheter is advanced up to 5 cm over the cannula tip.

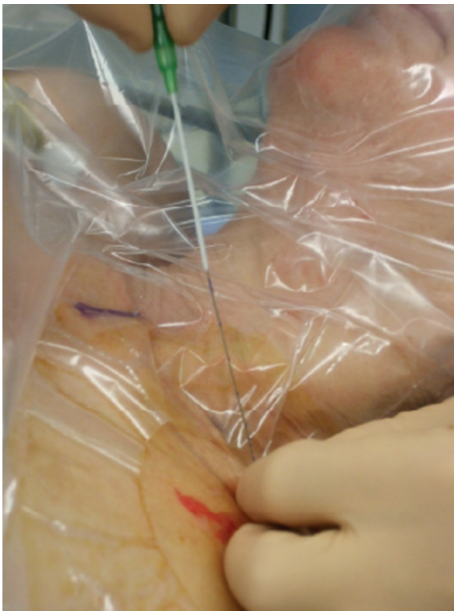

FIGURE 5: Cannula removal leaving the catheter in place.

both techniques [96–98]. Regrettably, in most of these publications the inappropriate use of neurostimulation lead to intolerable low success rates (<80%). Moreover, surrogate outcome like needle passes through the skin, needle time under the skin, patient satisfaction, local anesthetic volume, and other parameters of doubtful clinical importance have been introduced to compare these techniques. The comparison of ultrasound with stimulating catheters shows a similar picture: ultrasound is at least as effective with improvement of insertion-related discomfort and insertion time [93, 99]. The limited length and the main focus of this

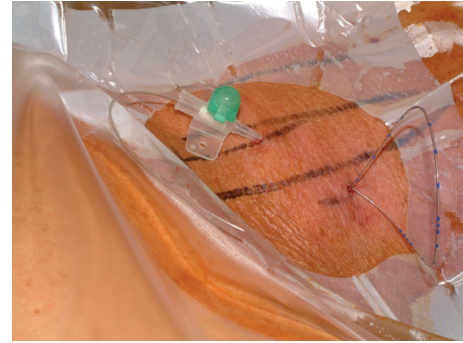

FIGURE 6: Catheter tunneling.

TABLE 2: Suggested catheter insertions for different surgical procedures. First choice is the first mentioned. The used literature for interscalene [58, 103, 104], cervical paravertebral [105–109], infraclavicular [59, 110–113], supraclavicular [114–116], axillary block [117–119], psoas compartment [120, 121], fascia iliaca [122–124], femoral [125–127], obturator [128, 129], popliteal sciatic [56, 57], and proximal sciatic [130–133].

Surgery	Catheter insertion location
Shoulder/proximal humerus	Interscalene; cervical paravertebral
Distal humerus, elbow, forearm, and hand	Infraclavicular; supraclavicular; axillary block
Hip	Psoas compartment; fascia iliaca; femoral
Thigh/knee	Femoral; fascia iliaca; obturator; proximal sciatic
Calf/ankle/foot	Sciatic (popliteal; proximal); add femoral nerve block for major ankle surgery [26]

review preclude a further indepth discussion of this topic. Indeed, there are randomized controlled trials suggesting that stimulating catheters for popliteal blocks [100], and the combination of ultrasound and nerve stimulation for catheter insertion improve analgesia [101]. Both techniques have to be considered equal if properly used with the respective advantages and disadvantages. This statement is in accordance with the most recent recommendation of the ASRA [102].

Data from controlled trials involving ultrasound-guided sPNB is not automatically applicable to ultrasound-guided cPNB. However, many reports confirm the feasibility of ultrasound-guided catheter-insertion with a great success rate [134, 135] also if there are few RCTs available [19, 136–138]. The description of the different techniques for ultrasound-guided catheter insertion (needle out-of-plane with nerve in short-axis approach and needle in-plane with nerve in short-axis or long-axis approaches) are well described in a recent editorial [139].

The combination of nerve stimulation (insulated needle or stimulating catheter) and ultrasound guidance for catheter placement is controversially discussed in the literature,

and often the difficulties are major compared to the single use of either technique [101, 140–142].

In certain situations ultrasound might be, at least theoretically, superior to nerve stimulation for example when sensory nerves are the target [143], after limb amputations [144] if there is no phantom sensation to guide nerve stimulation [145], when vascular puncture is an absolute contraindication like in anticoagulated patients [146], or when an electrically induced muscle response is impossible [147] or not desired [148]. However, ultrasound needle and catheter tip visualization are often difficult specially in deep structures. In these cases, nerve stimulation might prove beneficial [149].

#### 4. Local Anesthetics, Infusion Rates, and Delivery Strategies

*4.1. Local Anesthetics & Adjuncts.* The most commonly used local anesthetics for cPNB are bupivacaine and ropivacaine, and both seem to provide adequate analgesia without major toxicity. However, ropivacaine is known to be more “motor sparing” [55] and less cardiotoxic compared to bupivacaine [150]. However, cases of toxicity involving both bupivacaine and ropivacaine are almost exclusively related to a single large injection of local anesthetic. At the concentrations of 0.15% for bupivacaine and 0.2% for ropivacaine, they seem to provide similar analgesia with little difference in hand strength preservation [151, 152]. Recently, for interscalene cPNB after open rotator cuff repair ropivacaine 0.3% was compared to 0.2% showing a decrease in morphine consumption, a better sleep quality, and no impairment in hand strength [55].

To prolong the effect of local anesthetics, the addition of different drugs to local anesthetics has been suggested for sPNB and cPNB like opioids [165, 166], epinephrine [167], and clonidine [168], but their safety or clinical benefits like reduction of local anesthetic use for cPNB remain unclear [169, 170].

*4.2. Infusion Rates and Delivery Strategies.* Preliminary evidence does not suggest a rigid local anesthetic delivery system for all cPNB. According to the literature, total local anesthetic dose and not its concentration or its delivery rate mainly influences clinical effects, although this issue is currently disputed in the literature [55, 162, 171–176]. At the moment, insufficient information is available to base recommendations on the optimal basal rate, bolus volume, and lockout period for the different variables that may affect these values (catheter location, catheter type, surgical procedure, etc.). As a rule, we can state that basal infusion of local anesthetic reduces breakthrough pain and improves sleep quality [33, 173, 177]. The addition of patient-controlled bolus doses further improves analgesia allowing a reduction of the basal rate and further allowing a reduction of opioids and their related side effects [33]. However, the comparison of basal-bolus and basal-only techniques related to pain scores and patient satisfaction is controversially disputed in the literature [33, 34, 177].

Reducing the basal rate might reduce the risk of toxicity and the reduction of motor and sensory block could prevent the risk for patient falls [178].

Until prospectively collected data are available, possible dose recommendations based on randomized controlled studies and clinical experience are given in Table 3. Although the maximum recommended hourly total dose of all local anesthetics during perineural infusion is still unknown [179], a wide safety margin has been reported in numerous clinical trials [180, 181].

For the outpatient setting, many types of pumps are on the market: reusable and disposable, nonelectronic and electronic, basal-only and basal-bolus capable [22, 182]. Nonelectronic disposable infusion pumps are divided in elastomeric, positive-pressure (spring-powered and gas-pressure-powered), and negative-pressure (vacuum) pumps [183]. The model chosen has to be adapted to the needs of the patient and meet with the costs. In clinical trials comparing electronic-programmable pumps with elastomeric pumps, elastomeric pumps have been shown to offer similar postoperative analgesia for fewer technical problems and lower costs [184]. In clinical practice, they were easy to use and accurate in function [185].

#### 5. Why cPNB Instead of sPNB?

*5.1. Pain Therapy.* Different case reports suggest beneficial effects of cPNB for different indications [12, 186, 187], but published RCTs include only postoperative patients and address mainly pain relief, which is considered to be the main indication for cPNB [21].

Although single-injection nerve blocks (sPNB) also provide excellent analgesia, cPNB increases the flexibility of both duration and density of local anesthetic effect depending on the chosen dose. SPNB offers a good pain therapy for up to 24 hours but for this duration a dense motor block and important sensory loss must be taken into account. In situations like trauma surgery, where compartment syndrome might be masked by these dense and long-lasting blocks, these properties are not wished by the surgeon. However, there is not enough evidence to support the thesis that patient-controlled analgesia with opioids or regional analgesia delay the diagnosis of compartment syndrome provided patients are adequately monitored [188, 189]. Continuous peripheral nerve blocks offer the possibility to adapt to the different needs by lowering the volume or the concentration of the local anesthetic [153, 190]. This flexibility reduces the need for a large initial bolus reducing the risk of systemic toxicity. Moreover, the reduction of dense motor and sensory blocks reduces the risk of falls and positioning injury [178, 191, 192]. An increase of local anesthetic concentration can also improve patient outcome. Borgeat et al. increased the ropivacaine concentration for interscalene blocks from 0.2 to 0.3% after rotator cuff repair and described a significant reduction of morphine consumption and a better sleep quality for the first postoperative night without increasing the intensity of motor block or side effects [55].

TABLE 3: Recommended doses of different local anesthetics for different catheter locations and their administration regimen according to clinical practice of the authors (CP), own publications or based on selected randomized controlled trials. Ropi: ropivacaine; Bupi: bupivacaine; B: basal rate (ml/h); Bo: bolus (ml); L: lockout (min). The used literature for Interscalene [55, 58, 153–157], infraclavicular [33, 59], axillary, [7] femoral [158–160], Fascia iliaca [161], subgluteal sciatic [162], and popliteal sciatic [51, 52, 78, 163, 164].

Catheter location	Local anesthetic	Infusion rate
Interscalene	(i) Ropi 0.2%	(i) CP: B: 4–6; Bo: 4–6; L: 20–30
	(ii) Ropi 0.3%	(ii) CP: B: 3–5; Bo: 3–4; L: 20–30
	(iii) Bupi 0.125% (sufentanil 0.1 µg/ml and clonidine 1 µg/ml)	(ii) CP: B: 5; Bo: 2.5; L: 30
Infraclavicular	(i) Ropi 0.2%	(i) CP: B: 4–6; Bo: 4–6; L: 20–60
Axillary	(i) Bupi 0.25%	(i) B: 10 / B: 0; Bo: 10; L: 60
Femoral (i) Hip surgery (ii) Knee surgery	(i) Hip	(i) Hip
	(a) Ropi 0.2%	(a) B: 6; Bo: 4; L: 30
	(b) Bupi 0.125% (+sufentanil 0.1 µg/ml and clonidine 1 µg/ml)	(b) B: 10 / B: 0; Bo: 10; L: 60 / B: 0; Bo 5; L: 30
	(ii) Knee	(ii) Knee
	(a) Ropi 0.2%	(a) CP: B: 3–6; Bo: 2–4; L: 20–30 min
	(b) Bupi 0.125% (clonidine 1 µg/ml)	(b) B: 5; Bo: 2.5; L: 30
Fascia iliaca (knee surgery)	(i) Ropi 0.2%	(i) B: 5; Bo: 5; L: 60 / B: 0; Bo: 10; L: 60
Subgluteal sciatic	(i) Ropi 0.2%	(i) B: 5; Bo: 5; L: 60
Popliteal sciatic	(i) Ropi 0.2%	(i) CP: B: 4–6; Bo: 4–6; L: 20
	(ii) Levobupi 0.125%	(ii) B: 5; Bo: 3; L: 15

5.2. *Upper Extremity.* Most of cPNB benefits are mainly dependent on successfully improving pain control, reducing opioid consumption and its related side effects and increasing patient satisfaction [21]. Like for shoulder and elbow surgery, potent analgesia is achieved and maintained with cPNB due to their complete innervation by nerves affected by the perineural infusion [55, 58, 59].

For shoulder and upper arm surgery, the interscalene nerve block (ISNB) has become a standard procedure in specialized centers [193]. This technique has been evaluated in different RCTs using either neurostimulator or ultrasound and as has been shown to be superior to settings using subcutaneous/oral opioids or even opioid-based patient controlled analgesia (PCA) [27, 34, 58, 138, 153–155, 194–200]. The superiority of continuous interscalene block (cISNB) towards single-shot interscalene block (sISNB) was demonstrated for moderate painful and extremely painful surgery in different studies [153–155, 196, 200, 201].

The benefits for elbow surgery using continuous infraclavicular perineural block is well validated [202], but good analgesia needs a high dose of local anesthetic leading to insensate extremities [175]. However, for surgical procedures distal to the elbow, brachial plexus infusions seem to provide less impressive analgesia [202]. Moreover, benefits of axillary [203] and supraclavicular [204, 205] continuous infusions demonstrated by RCTs are still lacking.

5.3. *Lower Extremity.* Femoral or posterior lumbar plexus infusions are well validated for hip [158, 187, 206, 207] and knee surgery in RCTs [208–210] but might result in dangerous quadriceps femoris and hip adductor weakness if high doses of local anesthetic are administered to optimize analgesia [178]. Moreover, contrary to the brachial plexus, in

the lower extremity a single perineural infusion will not cover all surgical sites as these are innervated by multiple nerves. Therefore, a single perineural infusion might not provide optimal analgesia without the concurrent use of additional analgesics [171, 211]. A valid method to achieve optimal analgesia is the supplementation of a continuous perineural infusion with a separate single-injection peripheral nerve block as is often done for knee arthroplasty (continuous femoral nerve block complemented by a sciatic block) [212]. Inserting a second catheter for continuous perineural infusion has been suggested [26, 206, 213], but limited available data are conflicting and not useful to establish a clear clinical practice [26, 214]. Moreover, the recent review by Paul et al. [215] has brought new light into the clinical standard for pain management after total knee arthroplasty. Only two RCTs [211, 216] compared single-shot femoral nerve block to continuous infusion of local anesthetic according to his inclusion criteria. The additional use of single-shot sciatic nerve block was also investigated. According to the chosen methodology he suggested that at the moment, there is not enough evidence to support the use of neither a single-shot sciatic nerve block nor a continuous perineural femoral nerve block in addition to a single-injection femoral nerve block [217]. Despite the emotional reactions to this review [218] fearing that the use of cPNB will be questioned by surgeons according to the missing evidence, further studies should address this question to establish the correct approach for this surgery [212].

Also if lumbar epidural provides generally equivalent analgesia to femoral perineural infusion for both, hip and knee arthroplasty cPNB offers a more favorable side effect profile avoiding the risk of epidural hematoma during anticoagulant administration [25, 207]. Therefore, cPNB has

to be considered the method of choice if regional anesthesia is indicated for the lower extremity.

For foot and ankle surgery, the use of cPNB has clearly demonstrated its superiority to other analgesia regimens. It has been shown to decrease hospital costs and length of stay [219]. Several studies have shown that regional anesthesia for foot surgery is safe and does lead to reduced perioperative opioid requirements [56, 57, 220]. Patients have reported improved sleep, reduced pain scores, and faster recovery times [162, 190, 221–223]. Patient satisfaction scores improved after regional anesthesia compared with general anesthetic with following systemic analgesia [224–226]. Recently, Blumenthal et al. described, that an additional femoral nerve catheter with ropivacaine 0.2% to a continuous popliteal catheter with ropivacaine 0.2% both for 48 hours for major ankle surgery reduces pain during motion compared to popliteal catheter alone. This effect was still present after 6 months suggesting that short-duration regional anesthesia has a late impact on residual pain after major ankle surgery [26].

## 6. Functional Outcome

**6.1. Short-Term Use of cPNB.** The effects of the short-term use of cPNB on functional outcome after orthopedic surgery are still controversially discussed. Ilfeld et al. reported in a retrospective study that in the 3 days after a total shoulder arthroplasty, a continuous interscalene block using ropivacaine 0.2% was associated with increased range of shoulder motion due to the complete analgesia provided [227]. These results were supplemented by a following prospective study analyzing the effects of ambulatory continuous interscalene nerve block after shoulder arthroplasty [27]. Authors concluded that an ambulatory continuous interscalene nerve block considerably decreased the time until readiness for discharge (defined as achievement of a previously established range of motion and good pain control) after shoulder arthroplasty. This result was achieved primarily by providing potent analgesia permitting greater passive shoulder movement and by the avoidance of intravenous opioids. However, recently Hofmann-Kiefer et al. compared a continuous interscalene infusion of local anesthetic with an opioid-based PCA regimen. They reported that continuous interscalene block improved analgesia without improving postoperative function during early rehabilitation of the shoulder joint. [198]. For knee surgery, De Ruyter et al. reported that a continuous femoral nerve block provided satisfactory analgesia, improved rehabilitation, and reduced hospital length of stay compared with opiates [228]. Contrary, Raimer et al. described better analgesia with continuous psoas and sciatic blocks or epidural catheters compared to opioid PCA regarding pain levels, analgesic requirements, and patient satisfaction. However, there was no difference in functional outcome between the 3 groups [229].

**6.2. Benefits after Catheter Removal.** Despite the overwhelming evidence highlighting cPNB benefits during local anesthetic infusion, there exist few data demonstrating

benefits after catheter removal. These data include improved analgesia a few days after removal [61, 186, 216] and after 6 months [26], faster resumption of unassisted standing [186], and improved passive knee flexion leading to earlier discharge from rehabilitation centers [25, 230]. The often cited increase in health-related quality of life has been shown only in 1 study [231] but could not be reproduced in many other more recent studies [232–236].

These results are in accordance with the review by Liu and Wu analyzing the effect of analgesic technique on postoperative patient-reported outcomes [20]. Authors found that regional anesthesia offered better postoperative analgesia control with reduction of opioid-related side effects, but there were insufficient and inconsistent data to support subsequent improvement in quality of life, quality of recovery, satisfaction, and length of hospital stay.

Therefore, more studies focusing on the medium- or long-term improvements in health-related quality-of-life measures are needed [234, 237].

**6.3. Impact on Postoperative Cognitive Dysfunction.** Postoperative cognitive dysfunction (POCD) is an important issue in an aging society. Postoperative cognitive dysfunction is a poorly defined condition as numerous studies use different definitions and neuropsychological tests to detect potentially altered short- or longer-term memory, motor control or information processing following anesthesia. There is evidence that altered intraoperative physiology may influence POCD and longer-term outcomes. A meta-analysis of 21 studies on POCD and postoperative delirium (POD) found no effect of anaesthesia type on the odds ratio of developing POD (0.88, 95% CI 0.51–1.51) [238]. However, it has been suggested that avoidance of general anesthesia and of central acting analgesics in the elderly leads to reduced postoperative long-term cognitive dysfunction [163]. The most recent study suggesting that anesthesia regimen has no impact on cognitive dysfunction had severe protocol inaccuracies, as the regional anesthesia group (spinal anesthesia) was premedicated with a benzodiazepine, another benzodiazepine was added prior to spinal anesthesia, a bispectral index <60 was achieved with propofol or with gas during surgery, and pain therapy was performed with oral oxycodone and subsequent morphine PCA [164]. Further well-designed studies are needed to assess the impact of continuous regional anesthesia for surgery and postoperative pain treatment on the incidence of POCD.

## 7. Ambulatory and Home Therapy

Apart from the classical postoperative setting, cPNB has been successfully introduced in the ambulatory surgery setting for both adults [134, 191] and pediatric patients [239].

Continuous peripheral nerve blocks offer the opportunity to deliver effective pain therapy at home and are considered to be a valid alternative to opioid-based analgesia and its related side effects [240]. However, a proper patient selection is essential for safe cPNB at home, as not all patients

are willing to accept the extra responsibility of the catheter and pump system [191, 240].

Additionally, patients with known hepatic or renal insufficiency are excluded from ambulatory cPNB to avoid possible local anesthetic toxicity [241]. Obese patients and those with heart or lung disease who cannot compensate for mild hypercarbia and/or hypoxia are excluded from interscalene and cervical paravertebral infusions, which are known to affect the phrenic nerve and ipsilateral diaphragm function [155].

## 8. Economical Outcome

The advantages of sPNB over general anesthesia related to cost-effectiveness in the operation theatre have been recently described by Gonano et al. for shoulder arthroscopy [242]. Authors could show that ultrasound-guided interscalene blocks lead to an improvement of anesthesia-related workflow and to a reduction of postanesthesia care unit (PACU) time compared to general anesthesia. The positive effects of regional anesthesia on the anesthesia-related costs are well known: reduction of postoperative nausea and vomiting, reduced length of stay, successful same day discharge, reduction of unplanned admission or readmission, reduction of multiple-day hospitalizations to single days, earlier discharge, reduction or even elimination of PACU length of stay leading to reduced postoperative nursing interventions, faster discharge times, and reduction of operating room time without increase in turnover time [211, 243–245]. Fredrickson and Stewart compared recently continuous interscalene nerve block for rotator cuff repair to combined single injection interscalene block with additional postoperative intermittent intra-articular local anaesthetic infiltration and to intermittent intra-articular only local anaesthetic infiltration. Authors concluded that continuous interscalene nerve block following rotator cuff repair in a multiprovider setting was associated with reduced total opioid/tramadol and antiemetic consumption, without a significant increase in the monetary costs [246].

Unfortunately, there are no studies comparing sPNB and cPNB regarding cost-effectiveness. However, the duration of hospitalization [247] or even the need for hospitalization [248] can be reduced by the use of cPNB reducing inpatient treatment costs.

## 9. Benefits of cPNBs

The impact of cPNBs on analgesia has been described in many RCTs and has been elucidated above [21]. The related dramatic decrease in required supplemental opioids, opioid-related side effects, and sleep disturbances, while simultaneously increasing patient satisfaction are further benefits [190]. Moreover, a decreased time to adequate ambulation with additional optimization of daily activities after ambulatory cPNB compared with intravenous opioids has been described [34]. For continuous regional anesthesia following shoulder and knee arthroplasty, an accelerated improvement of passive joint range of motion potentially

leading to shorter hospitalization has been described [25, 27, 216, 230].

Ambulatory shoulder arthroplasty and 23-hour-stay knee and hip arthroplasty using ambulatory continuous interscalene, femoral, and psoas compartment nerve blocks, respectively have been reported [247, 249, 250].

However, although postknee arthroplasty inflammation is reduced after a continuous femoral nerve block [186], the cPNB could not produce major improvements in long-term outcomes such as decreased chronic pain and improved health-related quality of life [20, 235, 251]. Studies focusing on long-term outcomes are lacking to evaluate the effects of cPNB after 6 and 12 months on costs, functional outcome and socioeconomic aspects.

## 10. Adverse Effects

Two prospective investigations involving more than 2.100 patients suggest that the incidence of cPNB-related complications is very low and comparable to sPNB techniques [58, 252]. However, different catheter insertion techniques, different anatomic locations, variations in equipment and different infusion regimens make comparisons difficult. In fact, several prospective studies report an incidence of secondary block (during infusion) failure of 1% [253], 20% [197], and 50% [254]. Therefore, all reported complications in this chapter cannot be translated to the different clinical practices.

*10.1. Minor Complications.* These complications are frequently seen in clinical practice and include catheter obstruction, catheter dislodgement, fluid leakage, disconnection from the pump system, infusion pump malfunction, and skin irritation or allergic reactions to the sterile catheter dressing [202, 252, 253, 255, 256].

*10.2. cPNB-Specific Complications.* These seldom but possible complications include inaccurate catheter tip placement resulting too far from the target nerve and therefore lacking successful analgesia, [74] or in an undesirable position like intravascular [257], intrapleural [258], intraneural [259], epidural [260] or even intrathecal. [261–263]. However, whether catheter migration is possible after correct placement remains unclear [264, 265].

*10.3. Infections.* Most studies reporting infection in relation with cPNB derive from hospitalized patients even if data for large outpatient series are increasing. Although the reported rates of inflammation (3%–4%) [86, 252, 253] and catheter bacterial colonization (6%–57%) are apparently high [266, 267], the incidence of catheter infection for inpatients ranges from 0% to 3.2% [252, 266, 268], and for outpatient rates are below 1% [191, 269].

Risk factors for infection in the setting of cPNB include lack of or inappropriate antibiotic prophylaxis, and axillary or femoral catheter location [269]. However, other studies have reported the interscalene location as the most problematic for infection [253, 268]. Further risk factors



are admission to an intensive care unit, male sex [252], and increased infusion duration [252]. Though, some case reports demonstrate that prolonged catheter use for more than 30 days is possible without increased rate of infection [15]. There is limited evidence proving that subcutaneous catheter tunneling [270] may decrease the risk of bacterial colonization and infection.

Although life-threatening catheter-related infections and sepsis have been reported in the literature [271, 272], no published case of permanent injury due to cPNB-related infection is reported in the literature [269].

Sterility precautions while filling the infusion pumps are of utmost importance. In a recent case report of a severe, deep cellulitis, evolving to mediastinitis was attributed to contaminated infusate from a pump which was manipulated in nonsterile conditions [272]. Therefore, anesthesiologists should act upon the recommendations of the American Society of Regional Anesthesia and Pain Medicine (ASRA) using sterile precautions such as antiseptic hand washing, sterile gloves, surgical masks and hats, and using alcohol-based chlorhexidine antiseptic solutions to avoid such complications [40].

**10.4. Neurologic Complications.** Although neurologic injury associated with cPNB is usually transient ranging from 0.3% to 2.0% [33], it remains the most feared concern performing regional anesthesia. Injury may occur during catheter placement or even in the postoperative period. For regional anesthesia in general the incidence of transient adverse neurologic symptoms associated with cPNB is 0% to 1.4% for interscalene [253, 273], 0.4% to 0.5% for femoral [252, 274], and 0% to 1.0% for sciatic catheters [266, 274]. Neuburger et al. described a 0.2% incidence of neurologic deficits lasting more than 6 weeks in nearly 3,500 catheters from multiple anatomic locations [253]. However, it remains unknown whether the deficits resolved spontaneously after the 6-week study period. Other prospective investigations report that the overwhelming majority of neurologic symptoms still present at 4 to 6 weeks resolve spontaneously within 3 months of surgery [252, 273].

There are also cases of long-term or permanent nerve injury in patients after perineural infusion [275]. In five large, prospective series with patient followups at least three months after, 3 cases of unresolved adverse neurologic events were found [58, 252, 266, 273, 274]. The combination of these results including 4,148 patients suggests that the risk of neurologic injury lasting longer than 9 months associated with cPNB is 0.07%. The role of the continuous infusion for the evolution of these complications remains unclear.

Only few reports of nerve injury in patients sent home with cPNB are described in the current literature. However, pressure injury due to insensate extremity has been implicated as a likely cause [10]. Therefore, particular precautions must be taken when casts or splints are placed on patients with insensate extremities.

A further important neurologic concern associated with in- and out-patient cPNB is the risk of falls. Williams et al. reported recently 1.7% of outpatients treated with continuous femoral nerve block fell due to insensate lower

extremity despite adequate instructions how to behave at home [192]. Ilfeld et al. pooled data from 3 previously published, randomized, triple-masked, and placebo-controlled studies of cPNB involving the femoral nerve after knee and hip arthroplasty and demonstrated a causal relationship between cPNB and the risk of falling after these surgical interventions [178].

This complication elucidates the potential benefit in providing low-concentration blocks that preserve more motor function and proprioception. Moreover, the desire to offer complete analgesia should be balanced against the risk of falling. Therefore, the recently published study dealing with multimodal analgesic approaches including regional anesthesia can offer a solution to achieve excellent analgesia while preserving motor function [276].

**10.5. Local Anesthetic Toxicity.** Most investigators report basal hourly infusion rates of 5 to 10 mL/h using dilute solutions of either ropivacaine or bupivacaine [33, 34]. Despite these low rates of infusion, local anesthetic toxicity is reported as a possible complication of cPNB [277]. Systemic local anesthetic toxicity is a serious but rare complication using cPNB [278, 279]. Although, continuous infusion is unlikely to result in sudden onset of toxicity, patients treated with a pump with bolus capability are at risk if intravascular migration should occur. A further rare complication is myonecrosis after repeated large boluses of bupivacaine [280]. Also if there is in vitro and animal evidence for local anesthetic-caused neurotoxicity [281, 282], there seems to be little evidence that the risk of nerve injury from prolonged local anesthetic exposure might be increased in patients suffering diabetes or preexisting neuropathies [283, 284].

## 11. Future Directions

Local anesthetics act on the voltage-gated sodium channels [285]. The  $Na_{v1.7}$  is the main channel for pain transmission in the peripheral nerves [286, 287]. Selective blocking of this channel for the postoperative period could be of special interest for ambulant cPNB avoiding the risk of falls. A high selective  $Na_{v1.7}$  local anesthetic would increase the ambulant use of cPNB with probably a remarkable impact in health costs.

Liposomes as reservoirs for drugs are biocompatible due to their biodegradability and low toxicity [288]. They can reduce the exposure of sensitive tissues like nerves to potentially toxic drugs like high concentrations of local anesthetics. Their administration is independent of technical skills required for catheter placement as a variety of routes are possible (topical, intramuscular, nasal, subcutaneous, oral, pulmonary, and intravenous) [289]. Even though not yet approved for peripheral nerve blocks, liposomal formulations of various local anesthetics offer an increase in clinical efficacy compared with the plain drugs [290]. Actual limitations of encapsulated local anesthetics are myotoxicity, neurotoxicity, tachyphylaxis, viscosity, and motor block [291]. Clinical studies describe a prolonged analgesia after infiltration and epidural application [292, 293]. Once the

potential adverse effects like a prolonged motor block and toxicity are eliminated, these promising clinical results might be transferred to peripheral regional anesthesia.

## 12. Conclusions

The Literature provides a plethora of information involving cPNB, but some aspects of perineural infusion remain controversial: the optimal catheter insertion modality, the optimal technique for each indication, the infusates offering the best safety, standardized local anesthetic delivery regimens, and optimization of continuous ambulatory infusion to reduce possible risks (as falling). The optimal analgesic technique for many surgical procedures has to be further elucidated, and cPNB must be compared with possible new analgesic techniques/regimens [231].

The new application areas for local anesthetic such as anti-inflammatory effects/anticancer effects [294, 295] have to be further investigated, and cPNB must be included in clinical trials addressing these topics.

The socioeconomic aspect of anesthesia remains an important issue, and the role of cPNB for in hospital and at home use and their effects in the healing process and the readmission of the patients at work after surgery must be clarified.

Prospective research addressing the above-mentioned issues can maximize the potential benefits and minimize the potential risks of cPNBs.

## Conflict of Interests

The authors declare that they have no conflicts of interests.

## References

- [1] F. P. Ansbro, "A method of continuous brachial plexus block," *The American Journal of Surgery*, vol. 71, no. 6, pp. 716–722, 1946.
- [2] J. A. DeKrey, C. F. Schroeder, and D. R. Buechel, "Continuous brachial plexus block," *Anesthesiology*, vol. 30, no. 3, p. 332, 1969.
- [3] S. J. Sarnoff and L. C. Sarnoff, "Prolonged peripheral nerve block by means of indwelling plastic catheter; treatment of hiccup; note on the electrical localization of peripheral nerve," *Anesthesiology*, vol. 12, no. 3, pp. 270–275, 1951.
- [4] R. A. Greengrass, N. G. Feinglass, P. M. Murray, and S. D. Trigg, "Continuous regional anesthesia before surgical peripheral sympathectomy in a patient with severe digital necrosis associated with Raynaud's phenomenon and scleroderma," *Regional Anesthesia and Pain Medicine*, vol. 28, no. 4, pp. 354–358, 2003.
- [5] R. Franz, J. Hartman, and M. Wright, "Comparison of anesthesia technique on outcomes of endovascular repair of abdominal aortic aneurysms: a five-year review of monitored anesthesia care with local anesthesia vs. general or regional anesthesia," *Journal of Cardiovascular Surgery*, vol. 52, no. 4, pp. 567–577, 2011.
- [6] E. B. Malinzak and T. J. Gan, "Regional anesthesia for vascular access surgery," *Anesthesia and analgesia*, vol. 109, no. 3, pp. 976–980, 2009.
- [7] J. P. Mezzatesta, D. A. Scott, S. A. Schweitzer, and D. E. Selander, "Continuous axillary brachial plexus block for postoperative pain relief intermittent bolus versus continuous infusion," *Regional Anesthesia*, vol. 22, no. 4, pp. 357–362, 1997.
- [8] N. Vadivelu, M. Gesquire, S. Mitra et al., "Safety of local anesthesia combined with monitored intravenous sedation for American Society of Anesthesiologists 3 and 4 patients undergoing lower limb-preservation procedures," *Journal of Foot and Ankle Surgery*, vol. 49, no. 2, pp. 152–154, 2010.
- [9] S. M. Smith and V. L. Rees, "The use of prolonged continuous spinal anesthesia to relieve vasospasm and pain in peripheral embolism," *Anesthesiology*, vol. 9, pp. 229–238, 1948.
- [10] L. N. Cheeley, "Treatment of peripheral embolism by continuous sciatic nerve block," *Current Researches in Anesthesia & Analgesia*, vol. 31, no. 3, pp. 211–212, 1952.
- [11] J. J. Wu, L. Lollo, and A. Grabinsky, "Regional anesthesia in trauma medicine," *Anesthesiology Research and Practice*, vol. 2011, Article ID 713281, 7 pages, 2011.
- [12] M. Umino, H. Kohase, S. Ideguchi, and N. Sakurai, "Long-term pain control in trigeminal neuralgia with local anesthetics using an indwelling catheter in the mandibular nerve," *Clinical Journal of Pain*, vol. 18, no. 3, pp. 196–199, 2002.
- [13] J. Kato, D. Gokan, K. Ueda, M. Shimizu, T. Suzuki, and S. Ogawa, "Successful pain management of primary and independent spread sites in a child with CRPS type I using regional nerve blocks," *Pain Medicine*, vol. 12, no. 1, p. 174, 2011.
- [14] K. C. P. Vissers, K. Besse, M. Wagemans et al., "23. Pain in patients with cancer," *Pain Practice*, vol. 11, no. 5, pp. 453–475, 2011.
- [15] B. Borghi, M. D'Addabbo, P. F. White et al., "The use of prolonged peripheral neural blockade after lower extremity amputation: the effect on symptoms associated with phantom limb syndrome," *Anesthesia and Analgesia*, vol. 111, no. 5, pp. 1308–1315, 2010.
- [16] S. Preißler, C. Dietrich, W. Meissner et al., "Brachial plexus block in phantom limb pain: a case report," *Pain Medicine*, vol. 12, no. 11, pp. 1649–1654, 2011.
- [17] L. Le-Wendling and F. K. Enneking, "Continuous peripheral nerve blockade for postoperative analgesia," *Current Opinion in Anaesthesiology*, vol. 21, no. 5, pp. 602–609, 2008.
- [18] S. S. Liu, J. Ngeow, and R. S. John, "Evidence basis for ultrasound-guided block characteristics: onset, quality, and duration," *Regional anesthesia and pain medicine*, vol. 35, no. 2, pp. S26–S35, 2010.
- [19] S. S. Liu, J. E. Ngeow, and J. T. YaDeau, "Ultrasound-guided regional anesthesia and analgesia: a qualitative systematic review," *Regional Anesthesia and Pain Medicine*, vol. 34, no. 1, pp. 47–59, 2009.
- [20] S. S. Liu and C. L. Wu, "The effect of analgesic technique on postoperative patient-reported outcomes including analgesia: a systematic review," *Anesthesia and Analgesia*, vol. 105, no. 3, pp. 789–808, 2007.
- [21] J. M. Richman, S. S. Liu, G. Courpas et al., "Does continuous peripheral nerve block provide superior pain control to opioids? A meta-analysis," *Anesthesia and Analgesia*, vol. 102, no. 1, pp. 248–257, 2006.
- [22] B. M. Ilfeld, "Continuous peripheral nerve blocks: a review of the published evidence," *Anesthesia & Analgesia*, vol. 113, pp. 904–925, 2011.
- [23] A. Rodgers, N. Walker, S. Schug et al., "Reduction of postoperative mortality and morbidity with epidural or spinal anaesthesia: results from overview of randomised trials,"

- British Medical Journal*, vol. 321, no. 7275, pp. 1493–1497, 2000.
- [24] M. J. Parker, H. H. Handoll, and R. Griffiths, “Anaesthesia for hip fracture surgery in adults,” *Cochrane Database of Systematic Reviews*, no. 4, Article ID CD000521, 2004.
  - [25] X. Capdevila, Y. Barthelet, P. Biboulet, Y. Ryckwaert, J. Rubenovitch, and F. D’Athis, “Effects of perioperative analgesic technique on the surgical outcome and duration of rehabilitation after major knee surgery,” *Anesthesiology*, vol. 91, no. 1, pp. 8–15, 1999.
  - [26] S. Blumenthal, A. Borgeat, C. Neudrfer, R. Bertolini, N. Espinosa, and J. Aguirre, “Additional femoral catheter in combination with popliteal catheter for analgesia after major ankle surgery,” *British Journal of Anaesthesia*, vol. 106, no. 3, pp. 387–393, 2011.
  - [27] B. M. Ilfeld, K. Vandenborne, P. W. Duncan et al., “Ambulatory continuous interscalene nerve blocks decrease the time to discharge readiness after total shoulder arthroplasty: a randomized, triple-masked, placebo-controlled study,” *Anesthesiology*, vol. 105, no. 5, pp. 999–1007, 2006.
  - [28] I. Power, “Recent advances in postoperative pain therapy,” *British Journal of Anaesthesia*, vol. 95, no. 1, pp. 43–51, 2005.
  - [29] J. L. Apfelbaum, C. Chen, S. S. Mehta, and T. J. Gan, “Postoperative pain experience: results from a national survey suggest postoperative pain continues to be undermanaged,” *Anesthesia and Analgesia*, vol. 97, no. 2, pp. 534–540, 2003.
  - [30] T. T. Horlocker, “Pain management in total joint arthroplasty: a historical review,” *Orthopedics*, vol. 33, no. 9, pp. 14–19, 2010.
  - [31] H. Y. V. Ip, A. Abrishami, P. W. H. Peng, J. Wong, and F. Chung, “Predictors of postoperative pain and analgesic consumption: a qualitative systematic review,” *Anesthesiology*, vol. 111, no. 3, pp. 657–677, 2009.
  - [32] M. P. Ekstein and A. A. Weinbroum, “Immediate postoperative pain in orthopedic patients is more intense and requires more analgesia than in post-laparotomy patients,” *Pain Medicine*, vol. 12, no. 2, pp. 308–313, 2011.
  - [33] B. M. Ilfeld, T. E. Morey, and F. K. Enneking, “Infraclavicular perineural local anesthetic infusion: a comparison of three dosing regimens for postoperative analgesia,” *Anesthesiology*, vol. 100, no. 2, pp. 395–402, 2004.
  - [34] X. Capdevila, C. Dadure, S. Bringuier et al., “Effect of patient-controlled perineural analgesia on rehabilitation and pain after ambulatory orthopedic surgery: a multicenter randomized trial,” *Anesthesiology*, vol. 105, no. 3, pp. 566–573, 2006.
  - [35] L. Nikolajsen, B. Brandsborg, U. Lucht, T. S. Jensen, and H. Kehlet, “Chronic pain following total hip arthroplasty: a nationwide questionnaire study,” *Acta Anaesthesiologica Scandinavica*, vol. 50, no. 4, pp. 495–500, 2006.
  - [36] P. A. E. Puolakka, M. G. F. Rorarius, M. Roviola, T. J. S. Puolakka, K. Nordhausen, and L. Lindgren, “Persistent pain following knee arthroplasty,” *European Journal of Anaesthesiology*, vol. 27, no. 5, pp. 455–460, 2010.
  - [37] H. Kehlet, T. S. Jensen, and C. J. Woolf, “Persistent postsurgical pain: risk factors and prevention,” *Lancet*, vol. 367, no. 9522, pp. 1618–1625, 2006.
  - [38] F. M. Perkins and H. Kehlet, “Chronic pain as an outcome of surgery: a review of predictive factors,” *Anesthesiology*, vol. 93, no. 4, pp. 1123–1133, 2000.
  - [39] M. N. Raftery, P. Ryan, C. Normand, A. W. Murphy, D. De La Harpe, and B. E. McGuire, “The economic cost of chronic noncancer pain in Ireland: results from the PRIME study, part 2,” *Journal of Pain*, vol. 13, no. 2, pp. 139–145, 2012.
  - [40] J. R. Hebl, “The importance and implications of aseptic techniques during regional anesthesia,” *Regional Anesthesia and Pain Medicine*, vol. 31, no. 4, pp. 311–323, 2006.
  - [41] C. Aveline, H. Le Hetet, A. Le Roux et al., “Perineural ultrasound-guided catheter bacterial colonization: a prospective evaluation in 747 cases,” *Regional Anesthesia and Pain Medicine*, vol. 36, no. 6, pp. 579–584, 2011.
  - [42] D. Selander, K. G. Dhuner, and G. Lundborg, “Peripheral nerve injury due to injection needles used for regional anesthesia. An experimental study of the acute effects of needle point trauma,” *Acta Anaesthesiologica Scandinavica*, vol. 21, no. 3, pp. 182–188, 1977.
  - [43] A. S. C. Rice and S. B. McMahon, “Peripheral nerve injury caused by injection needles used in regional anaesthesia: influence of bevel configuration, studied in a rat model,” *British Journal of Anaesthesia*, vol. 69, no. 5, pp. 433–438, 1992.
  - [44] X. Sala-Blanch, T. Ribalta, E. Rivas et al., “Structural injury to the human sciatic nerve after intraneural needle insertion,” *Regional Anesthesia and Pain Medicine*, vol. 34, no. 3, pp. 201–205, 2009.
  - [45] S. S. Liu, M. A. Gordon, P. M. Shaw, S. Wilfred, T. Shetty, and J. T. YaDeau, “A prospective clinical registry of ultrasound-guided regional anesthesia for ambulatory shoulder surgery,” *Anesthesia and Analgesia*, vol. 111, no. 3, pp. 617–623, 2010.
  - [46] J. M. Cohen and A. T. Gray, “Functional deficits after intraneural injection during interscalene block,” *Regional Anesthesia and Pain Medicine*, vol. 35, no. 4, pp. 397–399, 2010.
  - [47] J. Dooley, M. Fingerman, S. Melton, and S. M. Klein, “Contralateral local anesthetic spread from an outpatient interscalene catheter,” *Canadian Journal of Anesthesia*, vol. 57, no. 10, pp. 936–939, 2010.
  - [48] D. Morau, S. Lopez, P. Biboulet, N. Bernard, J. Amar, and X. Capdevila, “Comparison of continuous 3-in-1 and fascia iliaca compartment blocks for postoperative analgesia: feasibility, catheter migration, distribution of sensory block, and analgesic efficacy,” *Regional Anesthesia and Pain Medicine*, vol. 28, no. 4, pp. 309–314, 2003.
  - [49] G. M. Greenblatt and J. S. Denson, “Needle nerve stimulator/locator: nerve blocks with a new instrument for locating nerves,” *Anesthesia and analgesia*, vol. 41, pp. 599–602, 1962.
  - [50] D. Kulenkampff, “Anesthesia of the brachial plexus,” *Zentralblatt für Chirurgie*, vol. 28, pp. 1337–1350, 1911.
  - [51] D. Selander, “Catheter technique in axillary plexus block. Presentation of a new method,” *Acta Anaesthesiologica Scandinavica*, vol. 21, no. 4, pp. 324–329, 1977.
  - [52] W. A. Tan and D. G. Spigos, “Sciatic nerve block under fluoroscopic guidance,” *CardioVascular and Interventional Radiology*, vol. 9, no. 1, pp. 59–60, 1986.
  - [53] P. L. Ting and V. Sivagnanaratnam, “Ultrasonographic study of the spread of local anaesthetic during axillary brachial plexus block,” *British Journal of Anaesthesia*, vol. 63, no. 3, pp. 326–329, 1989.
  - [54] J. De Andrés, J. M. Alonso-Iñigo, X. Sala-Blanch, and M. A. Reina, “Nerve stimulation in regional anaesthesia: theory and practice,” *Best Practice and Research: Clinical Anaesthesiology*, vol. 19, no. 2, pp. 153–174, 2005.
  - [55] A. Borgeat, J. Aguirre, M. Marquardt, J. Mrdjén, and S. Blumenthal, “Continuous interscalene analgesia with ropivacaine 0.2% versus ropivacaine 0.3% after open rotator cuff repair: the effects on postoperative analgesia and motor function,” *Anesthesia and Analgesia*, vol. 111, no. 6, pp. 1543–1547, 2010.

- [56] A. Borgeat, S. Blumenthal, D. Karovic, A. Delbos, and P. Vienne, "Clinical evaluation of a modified postetior anatomical approach to performing the popliteal block," *Regional Anesthesia and Pain Medicine*, vol. 29, no. 3, pp. 290–296, 2004.
- [57] A. Borgeat, S. Blumenthal, M. Lambert, P. Theodorou, and P. Vienne, "The feasibility and complications of the continuous popliteal nerve block: a 1001-case survey," *Anesthesia and Analgesia*, vol. 103, no. 1, pp. 229–233, 2006.
- [58] A. Borgeat, A. Dullenkopf, G. EkatoDRAMIS, and L. Nagy, "Evaluation of the lateral modified approach for continuous interscalene block after shoulder surgery," *Anesthesiology*, vol. 99, no. 2, pp. 436–442, 2003.
- [59] A. Borgeat, G. EkatoDRAMIS, and C. Dumont, "An evaluation of the infraclavicular block via a modified approach of the Raj technique," *Anesthesia and Analgesia*, vol. 93, no. 2, pp. 436–441, 2001.
- [60] S. A. Grant, K. C. Nielsen, R. A. Greengrass, S. M. Steele, and S. M. Klein, "Continuous peripheral nerve block for ambulatory surgery," *Regional Anesthesia and Pain Medicine*, vol. 26, no. 3, pp. 209–214, 2001.
- [61] B. A. Williams, M. L. Kentor, M. T. Vogt et al., "Reduction of verbal pain scores after anterior cruciate ligament reconstruction with 2-day continuous femoral nerve block: a randomized clinical trial," *Anesthesiology*, vol. 104, no. 2, pp. 315–327, 2006.
- [62] W. B. Silverstein, M. U. Saiyed, and A. R. Brown, "Interscalene block with a nerve stimulator: a deltoid motor response is a satisfactory endpoint for successful block," *Regional Anesthesia and Pain Medicine*, vol. 25, no. 4, pp. 356–359, 2000.
- [63] H. Lecamwasam, J. Mayfield, L. Rosow, Y. Chang, C. Carter, and C. Rosow, "Stimulation of the posterior cord predicts successful infraclavicular block," *Anesthesia and Analgesia*, vol. 102, no. 5, pp. 1564–1568, 2006.
- [64] S. Kapral, M. Greher, G. Huber et al., "Ultrasonographic guidance improves the success rate of interscalene brachial plexus blockade," *Regional Anesthesia and Pain Medicine*, vol. 33, no. 3, pp. 253–258, 2008.
- [65] V. W. S. Chan, A. Perlas, C. J. L. McCartney, R. Brull, D. Xu, and S. Abbas, "Ultrasounds guidance improves success rate of axillary brachial plexus block," *Canadian Journal of Anesthesia*, vol. 54, no. 3, pp. 176–182, 2007.
- [66] A. Perlas, R. Brull, V. W. S. Chan, C. J. L. McCartney, A. Nuica, and S. Abbas, "Ultrasound guidance improves the success of sciatic nerve block at the popliteal fossa," *Regional Anesthesia and Pain Medicine*, vol. 33, no. 3, pp. 259–265, 2008.
- [67] P. Marhofer, K. SchröGendorfer, H. Koinig, S. Kapral, C. Weinstabl, and N. Mayer, "Ultrasonographic guidance improves sensory block and onset time of three-in-one blocks," *Anesthesia and Analgesia*, vol. 85, no. 4, pp. 854–857, 1997.
- [68] M. Rigaud, P. Filip, P. Lirk, A. Fuchs, G. Gemes, and Q. Hogan, "Guidance of block needle insertion by electrical nerve stimulation: a pilot study of the resulting distribution of injected solution in dogs," *Anesthesiology*, vol. 109, no. 3, pp. 473–478, 2008.
- [69] W. F. UrmeY and J. Stanton, "Inability to consistently elicit a motor response following sensory paresthesia during interscalene block administration," *Anesthesiology*, vol. 96, no. 3, pp. 552–554, 2002.
- [70] C. A. Bollini, W. F. UrmeY, L. Vascello, and F. Cacheiro, "Relationship between evoked motor response and sensory paresthesia in interscalene brachial plexus block," *Regional Anesthesia and Pain Medicine*, vol. 28, no. 5, pp. 384–388, 2003.
- [71] J. P. Kainu, J. Sarvela, E. Tiippana, E. Halmesmäki, and K. T. Korttila, "Persistent pain after caesarean section and vaginal birth: a cohort study," *International Journal of Obstetric Anesthesia*, vol. 19, no. 1, pp. 4–9, 2010.
- [72] A. S. Poobalan, J. Bruce, P. M. King, W. A. Chambers, Z. H. Krukowski, and W. C. S. Smith, "Chronic pain and quality of life following open inguinal hernia repair," *British Journal of Surgery*, vol. 88, no. 8, pp. 1122–1126, 2001.
- [73] W. A. Macrae, "Chronic post-surgical pain: 10 years on," *British Journal of Anaesthesia*, vol. 101, no. 1, pp. 77–86, 2008.
- [74] F. V. Salinas, "Location, location, location: continuous peripheral nerve blocks and stimulating catheters," *Regional Anesthesia and Pain Medicine*, vol. 28, no. 2, pp. 79–82, 2003.
- [75] X. Capdevila, P. Biboulet, D. Morau et al., "Continuous three-in-one block for postoperative pain after lower limb orthopedic surgery: where do the catheters go?" *Anesthesia and Analgesia*, vol. 94, no. 4, pp. 1001–1006, 2002.
- [76] K. Enneking, "Close counts," *Regional Anesthesia and Pain Medicine*, vol. 32, no. 4, pp. 280–281, 2007.
- [77] A. M. Morin, P. Kranke, H. Wulf, R. Stienstra, and L. H. J. Eberhart, "The effect of stimulating versus nonstimulating catheter techniques for continuous regional anesthesia: a semiquantitative systematic review," *Regional Anesthesia and Pain Medicine*, vol. 35, no. 2, pp. 194–199, 2010.
- [78] A. Casati, G. Fanelli, G. Danelli et al., "Stimulating or conventional perineural catheters after hallux valgus repair: a double-blind, pharmaco-economic evaluation," *Acta Anaesthesiologica Scandinavica*, vol. 50, no. 10, pp. 1284–1289, 2006.
- [79] F. V. Salinas, J. M. Neal, L. A. Sueda, D. J. Kopacz, and S. S. Liu, "Prospective comparison of continuous femoral nerve block with nonstimulating catheter placement versus stimulating catheter-guided perineural placement in volunteers," *Regional Anesthesia and Pain Medicine*, vol. 29, no. 3, pp. 212–220, 2004.
- [80] M. F. Stevens, R. Werdehausen, E. Golla et al., "Does interscalene catheter placement with stimulating catheters improve postoperative pain or functional outcome after shoulder surgery? A prospective, randomized and double-blinded trial," *Anesthesia and Analgesia*, vol. 104, no. 2, pp. 442–447, 2007.
- [81] D. Q. H. Tran, L. Muñoz, G. Russo, and R. J. Finlayson, "Ultrasonography and stimulating perineural catheters for nerve blocks: a review of the evidence," *Canadian Journal of Anesthesia*, vol. 55, no. 7, pp. 447–457, 2008.
- [82] M. J. Barrington, D. J. Olive, C. A. McCutcheon et al., "Stimulating catheters for continuous femoral nerve blockade after total knee arthroplasty: a randomized, controlled, double-blinded trial," *Anesthesia and Analgesia*, vol. 106, no. 4, pp. 1316–1321, 2008.
- [83] S. M. Hayek, R. M. Ritchey, D. Sessler et al., "Continuous femoral nerve analgesia after unilateral total knee arthroplasty: stimulating versus nonstimulating catheters," *Anesthesia and Analgesia*, vol. 103, no. 6, pp. 1565–1570, 2006.
- [84] B. D. Sites, J. M. Neal, and V. Chan, "Editorial: Ultrasound in regional anesthesia: where should the "focus" be set?" *Regional Anesthesia and Pain Medicine*, vol. 34, no. 6, pp. 531–533, 2009.
- [85] B. A. Williams, S. L. Orebaugh, B. Ben-David, and P. E. Bigeleisen, "Electrical stimulation: an important force behind the growth of regional anesthesia," *Canadian Journal of Anesthesia*, vol. 54, no. 7, pp. 585–586, 2007.

- [86] A. Borgeat and X. Capdevila, "Neurostimulation/ultrasonography: the Trojan War will not take place," *Anesthesiology*, vol. 106, no. 5, pp. 896–898, 2007.
- [87] S. Mannion and X. Capdevila, "Ultrasound guidance and success rates of axillary brachial plexus block - II," *Canadian Journal of Anesthesia*, vol. 54, no. 7, p. 584, 2007.
- [88] J. Aguirre, S. Blumenthal, and A. Borgeat, "Ultrasound guidance and success rates of axillary brachial plexus block - I," *Canadian Journal of Anesthesia*, vol. 54, no. 7, p. 583, 2007.
- [89] M. J. Fredrickson, A. Borgeat, J. Aguirre, and A. P. Boezaart, "Ultrasound-guided interscalene block should be compared with the accepted standard for the neurostimulation technique," *Regional Anesthesia and Pain Medicine*, vol. 34, no. 2, p. 180, 2009.
- [90] M. S. Abrahams, M. F. Aziz, R. F. Fu, and J. L. Horn, "Ultrasound guidance compared with electrical neurostimulation for peripheral nerve block: a systematic review and meta-analysis of randomized controlled trials," *British Journal of Anaesthesia*, vol. 102, no. 3, pp. 408–417, 2009.
- [91] J. Aguirre, "A questionable review will not change facts about neurostimulation compared to ultrasound technique," *BJA*, 2009, <http://bja.oxfordjournals.org/content/102/3/408/reply>.
- [92] T. F. Bendtsen, T. D. Nielsen, C. V. Rohde, K. Kibak, and F. Linde, "Ultrasound guidance improves a continuous popliteal sciatic nerve block when compared with nerve stimulation," *Regional Anesthesia and Pain Medicine*, vol. 36, no. 2, pp. 181–184, 2011.
- [93] E. R. Mariano, G. S. Cheng, L. P. Choy et al., "Electrical stimulation versus ultrasound guidance for popliteal-sciatic perineural catheter insertion a randomized controlled trial," *Regional Anesthesia and Pain Medicine*, vol. 34, no. 5, pp. 480–485, 2009.
- [94] E. R. Mariano, V. J. Loland, N. S. Sandhu et al., "Ultrasound guidance versus electrical stimulation for femoral perineural catheter insertion," *Journal of Ultrasound in Medicine*, vol. 28, no. 11, pp. 1453–1460, 2009.
- [95] E. R. Mariano, V. J. Loland, R. H. Bellars et al., "Ultrasound guidance versus electrical stimulation for infraclavicular brachial plexus perineural catheter insertion," *Journal of Ultrasound in Medicine*, vol. 28, no. 9, pp. 1211–1218, 2009.
- [96] M. J. Fredrickson and T. K. Danesh-Clough, "Ambulatory continuous femoral analgesia for major knee surgery: a randomised study of ultrasound-guided femoral catheter placement," *Anaesthesia and Intensive Care*, vol. 37, no. 5, pp. 758–766, 2009.
- [97] M. J. Fredrickson, C. M. Ball, and A. J. Dalgleish, "A prospective randomized comparison of ultrasound guidance versus neurostimulation for interscalene catheter placement," *Regional Anesthesia and Pain Medicine*, vol. 34, no. 6, pp. 590–594, 2009.
- [98] M. J. Fredrickson, C. M. Ball, A. J. Dalgleish, A. W. Stewart, and T. G. Short, "A prospective randomized comparison of ultrasound and neurostimulation as needle end points for interscalene catheter placement," *Anesthesia and Analgesia*, vol. 108, no. 5, pp. 1695–1700, 2009.
- [99] S. Dhir and S. Ganapathy, "Comparative evaluation of ultrasound-guided continuous infraclavicular brachial plexus block with stimulating catheter and traditional technique: a prospective-randomized trial," *Acta Anaesthesiologica Scandinavica*, vol. 52, no. 8, pp. 1158–1166, 2008.
- [100] E. R. Mariano, V. J. Loland, N. S. Sandhu et al., "Comparative efficacy of ultrasound-guided and stimulating popliteal-sciatic perineural catheters for postoperative analgesia," *Canadian Journal of Anesthesia*, vol. 57, no. 10, pp. 919–926, 2010.
- [101] C. Aveline, A. Le Roux, H. Le Hetet, P. Vautier, F. Cognet, and F. Bonnet, "Postoperative efficacies of femoral nerve catheters sited using ultrasound combined with neurostimulation compared with neurostimulation alone for total knee arthroplasty," *European Journal of Anaesthesiology*, vol. 27, no. 11, pp. 978–984, 2010.
- [102] J. M. Neal, R. Brull, V. W. Chan et al., "The ASRA evidence-based medicine assessment of ultrasound-guided regional anesthesia and pain medicine: executive summary," *Regional anesthesia and pain medicine*, vol. 35, no. 2, pp. S1–S9, 2010.
- [103] V. W. S. Chan, "Applying ultrasound imaging to interscalene brachial plexus block," *Regional Anesthesia and Pain Medicine*, vol. 28, no. 4, pp. 340–343, 2003.
- [104] A. P. Winnie, S. Ramamurthy, Z. Durrani, and R. Radonjic, "Interscalene cervical plexus block: a single injection technique," *Anesthesia and Analgesia*, vol. 54, no. 3, pp. 370–375, 1975.
- [105] A. P. Boezaart, R. Koorn, and R. W. Rosenquist, "Paravertebral approach to the brachial plexus: an anatomic improvement in technique," *Regional Anesthesia and Pain Medicine*, vol. 28, no. 3, pp. 241–244, 2003.
- [106] A. P. Boezaart, J. F. De Beer, and M. L. Nell, "Early experience with continuous cervical paravertebral block using a stimulating catheter," *Regional Anesthesia and Pain Medicine*, vol. 28, no. 5, pp. 406–413, 2003.
- [107] I. Sandefo, G. Iohom, A. Van Elstraete, T. Lebrun, and B. Polin, "Clinical efficacy of the brachial plexus block via the posterior approach," *Regional Anesthesia and Pain Medicine*, vol. 30, no. 3, pp. 238–242, 2005.
- [108] J. G. Antonakakis, B. D. Sites, and J. Shiffrin, "Ultrasound-guided posterior approach for the placement of a continuous interscalene catheter," *Regional Anesthesia and Pain Medicine*, vol. 34, no. 1, pp. 64–68, 2009.
- [109] E. R. Mariano, V. J. Loland, and B. M. Ilfeld, "Interscalene perineural catheter placement using an ultrasound-guided posterior approach," *Regional Anesthesia and Pain Medicine*, vol. 34, no. 1, pp. 60–63, 2009.
- [110] C. H. Salazar and W. Espinosa, "Infraclavicular brachial plexus block: variation in approach and results in 360 cases," *Regional Anesthesia and Pain Medicine*, vol. 24, no. 5, pp. 411–416, 1999.
- [111] J. L. Wilson, D. L. Brown, G. Y. Wong, R. L. Ehman, and D. R. Cahill, "Infraclavicular brachial plexus block: parasagittal anatomy important to the coracoid technique," *Anesthesia and Analgesia*, vol. 87, no. 4, pp. 870–873, 1998.
- [112] Z. J. Koscielniak-Nielsen, H. Rasmussen, L. Hesselbjerg, Y. Gürkhan, and B. Belhage, "Clinical evaluation of the lateral sagittal infraclavicular block developed by MRI studies," *Regional Anesthesia and Pain Medicine*, vol. 30, no. 4, pp. 329–334, 2005.
- [113] H. C. Rettig, M. J. M. Gielen, E. Boersma, J. Klein, and G. J. Groen, "Vertical infraclavicular block of the brachial plexus: effects on hemidiaphragmatic movement and ventilatory function," *Regional Anesthesia and Pain Medicine*, vol. 30, no. 6, pp. 529–535, 2005.
- [114] A. P. Winnie and V. J. Collins, "The subclavian perivascular technique of brachial plexus anesthesia," *Anesthesiology*, vol. 25, pp. 353–363, 1964.
- [115] D. L. Brown, D. R. Cahill, and L. D. Bridenbaugh, "Supraclavicular nerve block: anatomic analysis of a method to prevent pneumothorax," *Anesthesia and Analgesia*, vol. 76, no. 3, pp. 530–534, 1993.

- [116] V. W. S. Chan, A. Perlas, R. Rawson, and O. Odukoya, "Ultrasound-guided supraclavicular brachial plexus block," *Anesthesia and Analgesia*, vol. 97, no. 5, pp. 1514–1517, 2003.
- [117] H. Bouaziz, P. Narchi, F. J. Mercier et al., "Comparison between conventional axillary block and a new approach at the midhumeral level," *Anesthesia and Analgesia*, vol. 84, no. 5, pp. 1058–1062, 1997.
- [118] D. C. Moore, "A simplified maneuver for transarterial approach to axillary block for use by a single anesthesiologist—needs more explanation!," *Regional Anesthesia*, vol. 22, no. 3, pp. 293–294, 1997.
- [119] F. C. Liu, J. T. Liou, Y. F. Tsai et al., "Efficacy of ultrasound-guided axillary brachial plexus block: a comparative study with nerve stimulator-guided method," *Chang Gung Medical Journal*, vol. 28, no. 6, pp. 396–402, 2005.
- [120] D. Chayen, H. Nathan, and M. Chayen, "The psoas compartment block," *Anesthesiology*, vol. 45, no. 1, pp. 95–99, 1976.
- [121] X. Capdevila, P. Macaire, C. Dadure et al., "Continuous psoas compartment block for postoperative analgesia after total hip arthroplasty: new landmarks, technical guidelines, and clinical evaluation," *Anesthesia and Analgesia*, vol. 94, no. 6, pp. 1606–1613, 2002.
- [122] S. Lopez, T. Gros, N. Bernard, C. Plasse, and X. Capdevila, "Fascia iliaca compartment block for femoral bone fractures in prehospital care," *Regional Anesthesia and Pain Medicine*, vol. 28, no. 3, pp. 203–207, 2003.
- [123] B. Dalens, G. Vanneville, and A. Tanguy, "Comparison of the fascia iliaca compartment block with the 3-in-1 block in children," *Anesthesia and Analgesia*, vol. 69, no. 6, pp. 705–713, 1989.
- [124] O. Paut, M. Sallabery, E. Schreiber-Deturmeny, C. Rémond, B. Bruguerolle, and J. Camboulives, "Continuous fascia iliaca compartment block in children: a prospective evaluation of plasma bupivacaine concentrations, pain scores, and side effects," *Anesthesia and Analgesia*, vol. 92, no. 5, pp. 1159–1163, 2001.
- [125] C. Cauhepe, M. Olivier, R. Colombani, and N. Railhac, "The '3 in 1' block: myth or reality?" *Annales Françaises d'Anesthésie et de Réanimation*, vol. 8, no. 4, pp. 376–378, 1989.
- [126] P. Marhofer, C. Našel, C. Sitzwohl, and S. Kapral, "Magnetic resonance imaging of the distribution of local anesthetic during the three-in-one block," *Anesthesia and Analgesia*, vol. 90, no. 1, pp. 119–124, 2000.
- [127] S. A. Lang, R. W. Yip, P. C. Chang, and M. A. Gerard, "The femoral 3-in-1 block revisited," *Journal of Clinical Anesthesia*, vol. 5, no. 4, pp. 292–296, 1993.
- [128] O. Choquet, X. Capdevila, K. Bennourine, J. L. Feugeas, S. Binguier-Branchereau, and J. C. Manelli, "A new inguinal approach for the obturator nerve block: anatomical and randomized clinical studies," *Anesthesiology*, vol. 103, no. 6, pp. 1238–1245, 2005.
- [129] D. Macalou, S. Trueck, P. Meuret et al., "Postoperative analgesia after total knee replacement: the effect of an obturator nerve block added to the femoral 3-in-1 nerve block," *Anesthesia and Analgesia*, vol. 99, no. 1, pp. 251–254, 2004.
- [130] R. Guardini, B. A. Waldron, and W. A. Wallace, "Sciatic nerve block: a new lateral approach," *Acta Anaesthesiologica Scandinavica*, vol. 29, no. 5, pp. 515–519, 1985.
- [131] P. C. Chang, S. A. Lang, and R. W. Yip, "Reevaluation of the sciatic nerve block," *Regional Anesthesia*, vol. 18, no. 1, pp. 18–23, 1993.
- [132] C. D. Franco, "Posterior approach to the sciatic nerve in adults: is Euclidean geometry still necessary?" *Anesthesiology*, vol. 98, no. 3, pp. 723–728, 2003.
- [133] P. Di Benedetto, G. Fanelli, J. E. Chelly, A. Casati, F. V. Salinas, and S. S. Liu, "Continuous sciatic nerve block: how to choose among different proximal approaches? Gluteal or subgluteal continuous sciatic nerve block," *Anesthesia and Analgesia*, vol. 97, no. 1, pp. 296–297, 2003.
- [134] M. J. Fredrickson, C. M. Ball, and A. J. Dalgleish, "Successful continuous interscalene analgesia for ambulatory shoulder surgery in a private practice setting," *Regional Anesthesia and Pain Medicine*, vol. 33, no. 2, pp. 122–128, 2008.
- [135] J. J. Davis, J. D. Swenson, P. E. Greis, R. T. Burks, and R. Z. Tashjian, "Interscalene block for postoperative analgesia using only ultrasound guidance: the outcome in 200 patients," *Journal of Clinical Anesthesia*, vol. 21, no. 4, pp. 272–277, 2009.
- [136] M. E. Slater, S. R. Williams, P. Harris et al., "Preliminary evaluation of infraclavicular catheters inserted using ultrasound guidance: through-the-catheter anesthesia is not inferior to through-the-needle blocks," *Regional Anesthesia and Pain Medicine*, vol. 32, no. 4, pp. 296–302, 2007.
- [137] A. Z. Wang, L. Gu, Q. H. Zhou, W. Z. Ni, and W. Jiang, "Ultrasound-guided continuous femoral nerve block for analgesia after total knee arthroplasty: catheter perpendicular to the nerve versus catheter parallel to the nerve," *Regional Anesthesia and Pain Medicine*, vol. 35, no. 2, pp. 127–131, 2010.
- [138] M. J. Fredrickson, C. M. Ball, and A. J. Dalgleish, "Posterior versus anterolateral approach interscalene catheter placement: a prospective randomized trial," *Regional Anesthesia and Pain Medicine*, vol. 36, no. 2, pp. 125–133, 2011.
- [139] B. M. Ilfeld, M. J. Fredrickson, and E. R. Mariano, "Ultrasound-guided perineural catheter insertion: three approaches but few illuminating data," *Regional Anesthesia and Pain Medicine*, vol. 35, no. 2, pp. 123–126, 2010.
- [140] G. J. van Geffen, M. Scheuer, A. Müller, J. Garderniers, and M. Gielen, "Ultrasound-guided bilateral continuous sciatic nerve blocks with stimulating catheters for postoperative pain relief after bilateral lower limb amputations," *Anaesthesia*, vol. 61, no. 12, pp. 1204–1207, 2006.
- [141] A. Walker and S. Roberts, "Stimulating catheters: a thing of the past?" *Anesthesia and Analgesia*, vol. 104, no. 4, pp. 1001–1002, 2007.
- [142] M. J. Fredrickson, "The sensitivity of motor response to needle nerve stimulation during ultrasound guided interscalene catheter placement," *Regional Anesthesia and Pain Medicine*, vol. 33, no. 4, pp. 291–296, 2008.
- [143] A. Stojadinovic, A. Auton, G. E. Peoples et al., "Responding to challenges in modern combat casualty care: innovative use of advanced regional anesthesia," *Pain Medicine*, vol. 7, no. 4, pp. 330–338, 2006.
- [144] A. R. Plunkett, D. S. Brown, J. M. Rogers, and C. C. Buckenmaier, "Supraclavicular continuous peripheral nerve block in a wounded soldier: when ultrasound is the only option," *British Journal of Anaesthesia*, vol. 97, no. 5, pp. 715–717, 2006.
- [145] C. Heiring and B. B. Kristensen, "Sciatic nerve block performed with nerve stimulation technique in an amputee—a case study," *Ugeskrift for Læger*, vol. 170, no. 6, p. 461, 2008.
- [146] P. E. Bigeleisen, "Ultrasound-guided infraclavicular block in an anticoagulated and anesthetized patient," *Anesthesia and Analgesia*, vol. 104, no. 5, pp. 1285–1287, 2007.
- [147] V. Minville, P. J. Zetlaoui, C. Fessenmeyer, and D. Benhamou, "Ultrasound guidance for difficult lateral popliteal catheter insertion in a patient with peripheral vascular disease,"

- Regional Anesthesia and Pain Medicine*, vol. 29, no. 4, pp. 368–370, 2004.
- [148] S. H. Renes, G. J. Van Geffen, H. C. Rettig, M. J. Gielen, and G. J. Scheffer, “Ultrasound-guided continuous phrenic nerve block for persistent hiccups,” *Regional Anesthesia and Pain Medicine*, vol. 35, no. 5, pp. 455–457, 2010.
- [149] B. M. Ilfeld, V. J. Loland, and E. R. Mariano, “Prepuncture ultrasound imaging to predict transverse process and lumbar plexus depth for psoas compartment block and perineural catheter insertion: a prospective, observational study,” *Anesthesia and Analgesia*, vol. 110, no. 6, pp. 1725–1728, 2010.
- [150] B. M. K. Emanuelsson, D. Zaric, P. A. Nydahl, and K. H. Axelsson, “Pharmacokinetics of ropivacaine and bupivacaine during 21 hours of continuous epidural infusion in healthy male volunteers,” *Anesthesia and Analgesia*, vol. 81, no. 6, pp. 1163–1168, 1995.
- [151] N. Rawal, R. Allvin, K. Axelsson et al., “Patient-controlled regional analgesia (PCRA) at home: controlled comparison between bupivacaine and ropivacaine brachial plexus analgesia,” *Anesthesiology*, vol. 96, no. 6, pp. 1290–1296, 2002.
- [152] A. Borgeat, F. Kalberer, H. Jacob, Y. A. Ruetsch, and C. Gerber, “Patient-controlled interscalene analgesia with ropivacaine 0.2% versus bupivacaine 0.15% after major open shoulder surgery: the effects on hand motor function,” *Anesthesia and Analgesia*, vol. 92, no. 1, pp. 218–223, 2001.
- [153] A. Borgeat, B. Schäppi, N. Biasca, and C. Gerber, “Patient-controlled analgesia after major shoulder surgery: patient-controlled interscalene analgesia versus patient-controlled analgesia,” *Anesthesiology*, vol. 87, no. 6, pp. 1343–1347, 1997.
- [154] A. Borgeat, E. Tewes, N. Biasca, and C. Gerber, “Patient-controlled interscalene analgesia with ropivacaine after major shoulder surgery: PCIA vs PCA,” *British Journal of Anaesthesia*, vol. 81, no. 4, pp. 603–605, 1998.
- [155] A. Borgeat, H. Perschak, P. Bird, J. Hodler, and C. Gerber, “Patient-controlled interscalene analgesia with ropivacaine 0.2% versus patient-controlled intravenous analgesia after major shoulder surgery: effects on diaphragmatic and respiratory function,” *Anesthesiology*, vol. 92, no. 1, pp. 102–108, 2000.
- [156] F. J. Singelyn, S. Seguy, and J. M. Gouverneur, “Interscalene brachial plexus analgesia after open shoulder surgery: continuous versus patient-controlled infusion,” *Anesthesia and Analgesia*, vol. 89, no. 5, pp. 1216–1220, 1999.
- [157] M. J. Fredrickson, A. Abeysekera, D. J. Price, and A. C. Wong, “Patient-initiated mandatory boluses for ambulatory continuous interscalene analgesia: an effective strategy for optimizing analgesia and minimizing side-effects,” *British Journal of Anaesthesia*, vol. 106, no. 2, pp. 239–245, 2011.
- [158] B. M. Ilfeld, E. R. Mariano, S. J. Madison et al., “Continuous femoral versus posterior lumbar plexus nerve blocks for analgesia after hip arthroplasty: a randomized, controlled study,” *Anesthesia & Analgesia*, vol. 113, no. 4, pp. 897–903, 2011.
- [159] F. J. Singelyn, P. E. Vanderelst, and J. M. A. Gouverneur, “Extended femoral nerve sheath block after total hip arthroplasty: continuous versus patient-controlled techniques,” *Anesthesia and Analgesia*, vol. 92, no. 2, pp. 455–459, 2001.
- [160] F. J. Singelyn and J. M. A. Gouverneur, “Extended “three-in-one” block after total knee arthroplasty: continuous versus patient-controlled techniques,” *Anesthesia and Analgesia*, vol. 91, no. 1, pp. 176–180, 2000.
- [161] J. J. Eledjam, P. Cuvillon, X. Capdevila et al., “Postoperative analgesia by femoral nerve block with ropivacaine 0.2% After major knee surgery: continuous versus patient-controlled techniques,” *Regional Anesthesia and Pain Medicine*, vol. 27, no. 6, pp. 604–611, 2002.
- [162] P. Di Benedetto, A. Casati, and L. Bertini, “Continuous subgluteus sciatic nerve block after orthopedic foot and ankle surgery: comparison of two infusion techniques,” *Regional Anesthesia and Pain Medicine*, vol. 27, no. 2, pp. 168–172, 2002.
- [163] J. Steinmetz, K. S. Funder, B. T. Dahl, and L. S. Rasmussen, “Depth of anaesthesia and post-operative cognitive dysfunction,” *Acta Anaesthesiologica Scandinavica*, vol. 54, no. 2, pp. 162–168, 2010.
- [164] L. Evered, D. A. Scott, B. Silbert, and P. Maruff, “Postoperative cognitive dysfunction is independent of type of surgery and anesthetic,” *Anesthesia and Analgesia*, vol. 112, no. 5, pp. 1179–1185, 2011.
- [165] Z. Wajima, Y. Nakajima, C. Kim et al., “I.v. compared with brachial plexus infusion of butorphanol for postoperative analgesia,” *British Journal of Anaesthesia*, vol. 74, no. 4, pp. 392–395, 1995.
- [166] P. R. Picard, M. R. Tramèr, H. J. McQuay, and R. Andrew Moore, “Analgesic efficacy of peripheral opioids (all except intra-articular): a qualitative systematic review of randomized controlled trials,” *Pain*, vol. 72, no. 3, pp. 309–318, 1997.
- [167] B. L. Partridge and D. Phil, “The effects of local anesthetics and epinephrine on rat sciatic nerve blood flow,” *Anesthesiology*, vol. 75, no. 2, pp. 243–251, 1991.
- [168] D. M. Pöpping, N. Elia, E. Marret, M. Wenk, and M. R. Tramèr, “Clonidine as an adjuvant to local anesthetics for peripheral nerve and plexus blocks: a meta-analysis of randomized trials,” *Anesthesiology*, vol. 111, no. 2, pp. 406–415, 2009.
- [169] B. M. Ilfeld, T. E. Morey, L. J. Thannikary, T. W. Wright, and F. K. Enneking, “Clonidine added to a continuous interscalene ropivacaine perineural infusion to improve postoperative analgesia: a randomized, double-blind, controlled study,” *Anesthesia and Analgesia*, vol. 100, no. 4, pp. 1172–1178, 2005.
- [170] A. Casati, F. Vinciguerra, G. Cappelleri et al., “Adding clonidine to the induction bolus and postoperative infusion during continuous femoral nerve block delays recovery of motor function after total knee arthroplasty,” *Anesthesia and Analgesia*, vol. 100, no. 3, pp. 866–872, 2005.
- [171] B. M. Ilfeld, V. J. Loland, J. C. Gerancher et al., “The effects of varying local anesthetic concentration and volume on continuous popliteal sciatic nerve blocks: a dual-center, randomized, controlled study,” *Anesthesia and Analgesia*, vol. 107, no. 2, pp. 701–707, 2008.
- [172] L. T. Le, V. J. Loland, E. R. Mariano et al., “Effects of local anesthetic concentration and dose on continuous interscalene nerve blocks: a dual-center, randomized, observer-masked, controlled study,” *Regional Anesthesia and Pain Medicine*, vol. 33, no. 6, pp. 518–525, 2008.
- [173] B. M. Ilfeld, T. E. Morey, T. W. Wright, L. K. Chidgey, and F. K. Enneking, “Interscalene perineural ropivacaine infusion: a comparison of two dosing regimens for postoperative analgesia,” *Regional Anesthesia and Pain Medicine*, vol. 29, no. 1, pp. 9–16, 2004.
- [174] B. M. Ilfeld, L. K. Moeller, E. R. Mariano et al., “Continuous peripheral nerve blocks: is local anesthetic dose the only factor, or do concentration and volume influence infusion effects as well?” *Anesthesiology*, vol. 112, no. 2, pp. 347–354, 2010.
- [175] B. M. Ilfeld, L. T. Le, J. Ramjohn et al., “The effects of local anesthetic concentration and dose on continuous

- infraclavicular nerve blocks: a multicenter, randomized, observer-masked, controlled study," *Anesthesia and Analgesia*, vol. 108, no. 1, pp. 345–350, 2009.
- [176] G. Brodner, H. Buerkle, H. Van Aken et al., "Postoperative analgesia after knee surgery: a comparison of three different concentrations of ropivacaine for continuous femoral nerve blockade," *Anesthesia and Analgesia*, vol. 105, no. 1, pp. 256–262, 2007.
- [177] B. M. Ilfeld, L. J. Thannikary, T. E. Morey, R. A. Vander Griend, and F. K. Enneking, "Popliteal sciatic perineural local anesthetic infusion: a comparison of three dosing regimens for postoperative analgesia," *Anesthesiology*, vol. 101, no. 4, pp. 970–977, 2004.
- [178] B. M. Ilfeld, K. B. Duke, and M. C. Donohue, "The association between lower extremity continuous peripheral nerve blocks and patient falls after knee and hip arthroplasty," *Anesthesia and Analgesia*, vol. 111, no. 6, pp. 1552–1554, 2010.
- [179] P. H. Rosenberg, B. T. Veering, and W. F. Urmev, "Maximum recommended doses of local anesthetics: a multifactorial concept," *Regional Anesthesia and Pain Medicine*, vol. 29, no. 6, pp. 564–575, 2004.
- [180] L. L. Bleckner, S. Bina, K. H. Kwon, G. McKnight, A. Dragovich, and C. C. Buckenmaier, "Serum ropivacaine concentrations and systemic local anesthetic toxicity in trauma patients receiving long-term continuous peripheral nerve block catheters," *Anesthesia and Analgesia*, vol. 110, no. 2, pp. 630–634, 2010.
- [181] G. Ekatothramis, A. Borgeat, G. Huledal, L. Jeppsson, L. Westman, and J. Sjövall, "Continuous interscalene analgesia with ropivacaine 2 mg/ml after major shoulder surgery," *Anesthesiology*, vol. 98, no. 1, pp. 143–150, 2003.
- [182] B. M. Ilfeld, "Continuous peripheral nerve blocks in the hospital and at home," *Anesthesiology Clinics*, vol. 29, no. 2, pp. 193–211, 2011.
- [183] E. A. Skryabina and T. S. Dunn, "Disposable infusion pumps," *American Journal of Health-System Pharmacy*, vol. 63, no. 13, pp. 1260–1268, 2006.
- [184] X. Capdevila, P. Macaire, P. Akinin, C. Dadure, N. Bernard, and S. Lopez, "Patient-controlled perineural analgesia after ambulatory orthopedic surgery: a comparison of electronic versus elastomeric pumps," *Anesthesia and Analgesia*, vol. 96, no. 2, pp. 414–417, 2003.
- [185] J. Aguirre, B. Baulig, C. Dora et al., "Continuous epicapsular ropivacaine 0.3% infusion after minimally invasive hip arthroplasty: a prospective, randomized, double-blinded, placebo-controlled study comparing continuous wound infusion with morphine patient-controlled analgesia," *Anesthesia and Analgesia*, vol. 114, no. 2, pp. 456–461, 2012.
- [186] F. Martin, V. Martinez, J. X. Mazoit et al., "Antiinflammatory effect of peripheral nerve blocks after knee surgery: clinical and biologic evaluation," *Anesthesiology*, vol. 109, no. 3, pp. 484–490, 2008.
- [187] A. Chudinov, H. Berkenstadt, M. Salai, A. Cahana, and A. Perel, "Continuous psoas compartment block for anesthesia and perioperative analgesia in patients with hip fractures," *Regional Anesthesia and Pain Medicine*, vol. 24, no. 6, pp. 563–568, 1999.
- [188] G. J. Mar, M. J. Barrington, and B. R. McGuirk, "Acute compartment syndrome of the lower limb and the effect of postoperative analgesia on diagnosis," *British Journal of Anaesthesia*, vol. 102, no. 1, pp. 3–11, 2009.
- [189] D. J. G. Johnson and G. A. Chalkiadis, "Does epidural analgesia delay the diagnosis of lower limb compartment syndrome in children?" *Paediatric Anaesthesia*, vol. 19, no. 2, pp. 83–91, 2009.
- [190] B. M. Ilfeld, T. E. Morey, R. D. Wang, and F. K. Enneking, "Continuous popliteal sciatic nerve block for postoperative pain control at home: a randomized, double-blinded, placebo-controlled study," *Anesthesiology*, vol. 97, no. 4, pp. 959–965, 2002.
- [191] J. D. Swenson, N. Bay, E. Loose et al., "Outpatient management of continuous peripheral nerve catheters placed using ultrasound guidance: an experience in 620 patients," *Anesthesia and Analgesia*, vol. 103, no. 6, pp. 1436–1443, 2006.
- [192] B. A. Williams, M. L. Kentor, and M. T. Bottegall, "The incidence of falls at home in patients with perineural femoral catheters: a retrospective summary of a randomized clinical trial," *Anesthesia and Analgesia*, vol. 104, no. 4, p. 1002, 2007.
- [193] J. Aguirre and A. Borgeat, "Anesthesia for shoulder surgery," *Anesthesia International* 2010.
- [194] S. Lehtipalo, L. O. D. Koskinen, G. Johansson, J. Kolmodin, and B. Biber, "Continuous interscalene brachial plexus block for postoperative analgesia following shoulder surgery," *Acta Anaesthesiologica Scandinavica*, vol. 43, no. 3, pp. 258–264, 1999.
- [195] S. M. Klein, S. A. Grant, R. A. Greengrass et al., "Interscalene brachial plexus block with a continuous catheter insertion system and a disposable infusion pump," *Anesthesia and Analgesia*, vol. 91, no. 6, pp. 1473–1478, 2000.
- [196] J. Kean, C. A. Wigderowitz, and D. M. Coventry, "Continuous interscalene infusion and single injection using levobupivacaine for analgesia after surgery of the shoulder," *Journal of Bone and Joint Surgery B*, vol. 88, no. 9, pp. 1173–1177, 2006.
- [197] B. M. Ilfeld, T. E. Morey, T. W. Wright, L. K. Chidgey, and F. K. Enneking, "Continuous interscalene brachial plexus block for postoperative pain control at home: a randomized, double-blinded, placebo-controlled study," *Anesthesia and Analgesia*, vol. 96, no. 4, pp. 1089–1095, 2003.
- [198] K. Hofmann-Kiefer, T. Eiser, D. Chappell, S. Leuschner, P. Conzen, and D. Schwender, "Does patient-controlled continuous interscalene block improve early functional rehabilitation after open shoulder surgery?" *Anesthesia and Analgesia*, vol. 106, no. 3, pp. 991–996, 2008.
- [199] E. R. Mariano, R. Afra, V. J. Loland et al., "Continuous interscalene brachial plexus block via an ultrasound-guided posterior approach: a randomized, triple-masked, placebo-controlled study," *Anesthesia and Analgesia*, vol. 108, no. 5, pp. 1688–1694, 2009.
- [200] M. J. Fredrickson, C. M. Ball, and A. J. Dagleish, "Analgesic effectiveness of a continuous versus single-injection interscalene block for minor arthroscopic shoulder surgery," *Regional Anesthesia and Pain Medicine*, vol. 35, no. 1, pp. 28–33, 2010.
- [201] S. Goebel, J. Stehle, U. Schwemmer, S. Reppenhagen, B. Rath, and F. Gohlke, "Interscalene brachial plexus block for open-shoulder surgery: a randomized, double-blind, placebo-controlled trial between single-shot anesthesia and patient-controlled catheter system," *Archives of Orthopaedic and Trauma Surgery*, vol. 130, no. 4, pp. 533–540, 2010.
- [202] B. M. Ilfeld, T. E. Morey, and F. K. Enneking, "Continuous infraclavicular brachial plexus block for postoperative pain control at home: a randomized, double-blinded, placebo-controlled study," *Anesthesiology*, vol. 96, no. 6, pp. 1297–1304, 2002.
- [203] M. H. A. Salonen, "Evaluation of efficacy and plasma concentrations of ropivacaine in continuous axillary brachial plexus block: high dose for surgical anesthesia and low dose



- for postoperative analgesia," *Regional Anesthesia and Pain Medicine*, vol. 25, no. 1, pp. 47–51, 2000.
- [204] E. R. Mariano, N. S. Sandhu, V. J. Loland et al., "A randomized comparison of infraclavicular and supraclavicular continuous peripheral nerve blocks for postoperative analgesia," *Regional Anesthesia and Pain Medicine*, vol. 36, no. 1, pp. 26–31, 2011.
- [205] P. B. Cornish, C. J. Leaper, G. Nelson, F. Anstis, C. Mcquillan, and R. Stienstra, "Avoidance of phrenic nerve paresis during continuous supraclavicular regional anaesthesia," *Anaesthesia*, vol. 62, no. 4, pp. 354–358, 2007.
- [206] H. Bagry, J. C. de la Cuadra Fontaine, J. F. Asenjo, D. Bracco, and F. Carli, "Effect of a continuous peripheral nerve block on the inflammatory response in knee arthroplasty," *Regional Anesthesia and Pain Medicine*, vol. 33, no. 1, pp. 17–23, 2008.
- [207] F. J. Singelyn, T. Ferrant, M. F. Malisse, and D. Joris, "Effects of intravenous patient-controlled analgesia with morphine, continuous epidural analgesia, and continuous femoral nerve sheath block on rehabilitation after unilateral total-hip arthroplasty," *Regional Anesthesia and Pain Medicine*, vol. 30, no. 5, pp. 452–457, 2005.
- [208] M. W. Watson, D. Mitra, T. C. McLintock, and S. A. Grant, "Continuous versus single-injection lumbar plexus blocks: comparison of the effects on morphine use and early recovery after total knee arthroplasty," *Regional Anesthesia and Pain Medicine*, vol. 30, no. 6, pp. 541–547, 2005.
- [209] W. T. Long, S. R. Ward, L. D. Dorr, J. Raya, M. Boutary, and L. E. Sirianni, "Postoperative pain management following total knee arthroplasty: a randomized comparison of continuous epidural versus femoral nerve infusion," *The journal of knee surgery*, vol. 19, no. 2, pp. 137–143, 2006.
- [210] C. B. Johnson and S. K. Steele-Moses, "The use of continuous femoral nerve blocks versus extended release epidural morphine: a study comparing outcomes in total knee arthroplasty procedures," *Orthopaedic Nursing*, vol. 30, no. 1, pp. 44–53, 2011.
- [211] B. M. Ilfeld, L. T. Le, R. S. Meyer et al., "Ambulatory continuous femoral nerve blocks decrease time to discharge readiness after tricompartment total knee arthroplasty: a randomized, triple-masked, placebo-controlled study," *Anesthesiology*, vol. 108, no. 4, pp. 703–713, 2008.
- [212] J. T. Wegener, B. Van Ooij, C. N. Van Dijk, M. W. Hollmann, B. Preckel, and M. F. Stevens, "Value of single-injection or continuous sciatic nerve block in addition to a continuous femoral nerve block in patients undergoing total knee arthroplasty: a prospective, randomized, controlled trial," *Regional Anesthesia and Pain Medicine*, vol. 36, no. 5, pp. 481–488, 2011.
- [213] G. Mistraretti, J. C. De La Cuadra-Fontaine, F. J. Asenjo et al., "Comparison of analgesic methods for total knee arthroplasty: metabolic effect of exogenous glucose," *Regional Anesthesia and Pain Medicine*, vol. 31, no. 3, pp. 260–269, 2006.
- [214] A. M. Morin, C. D. Kratz, L. H. J. Eberhart et al., "Postoperative analgesia and functional recovery after total-knee replacement: comparison of a continuous posterior lumbar plexus (Psoas Compartment) block, a continuous femoral nerve block, and the combination of a continuous femoral and sciatic nerve block," *Regional Anesthesia and Pain Medicine*, vol. 30, no. 5, pp. 434–445, 2005.
- [215] J. E. Paul, A. Arya, L. Hurlburt et al., "Femoral nerve block improves analgesia outcomes after total knee arthroplasty: a meta-analysis of randomized controlled trials," *Anesthesiology*, vol. 113, no. 5, pp. 1144–1162, 2010.
- [216] F. V. Salinas, S. S. Liu, and M. F. Mulroy, "The effect of single-injection femoral nerve block versus continuous femoral nerve block after total knee arthroplasty on hospital length of stay and long-term functional recovery within an established clinical pathway," *Anesthesia and Analgesia*, vol. 102, no. 4, pp. 1234–1239, 2006.
- [217] A. Hadzic, T. T. Houle, X. Capdevila, and B. M. Ilfeld, "Femoral nerve block for analgesia in patients having knee arthroplasty," *Anesthesiology*, vol. 113, no. 5, pp. 1014–1015, 2010.
- [218] M. J. Barrington, D. J. Olive, and R. Kluger, "Inappropriate conclusion from meta-analysis of randomized controlled trials," *Anesthesiology*, vol. 114, no. 6, pp. 1494–1495, 2011.
- [219] L. Collins, A. Halwani, and H. Vaghadia, "Impact of a regional anesthesia analgesia program for outpatient foot surgery," *Canadian Journal of Anaesthesia*, vol. 46, no. 9, pp. 840–845, 1999.
- [220] S. M. Klein, R. Pietrobon, K. C. Nielsen, D. S. Warner, R. A. Greengrass, and S. M. Steele, "Peripheral nerve blockade with long-acting local anesthetics: a survey of the Society for Ambulatory Anesthesia," *Anesthesia and Analgesia*, vol. 94, no. 1, pp. 71–76, 2002.
- [221] D. Zaric, K. Boysen, J. Christiansen, U. Haastrup, H. Kofoed, and N. Rawal, "Continuous popliteal sciatic nerve block for outpatient foot surgery—a randomized, controlled trial," *Acta Anaesthesiologica Scandinavica*, vol. 48, no. 3, pp. 337–341, 2004.
- [222] P. F. White, T. Issioui, G. D. Skrivaneck, J. S. Early, and C. Wakefield, "The use of a continuous popliteal sciatic nerve block after surgery involving the foot and ankle: does it improve the quality of recovery?" *Anesthesia and Analgesia*, vol. 97, no. 5, pp. 1303–1309, 2003.
- [223] J. E. Chelly, J. Greger, A. Casati, T. Al-Samsam, W. McGarvey, and T. Clanton, "Continuous lateral sciatic blocks for acute postoperative pain management after major ankle and foot surgery," *Foot and Ankle International*, vol. 23, no. 8, pp. 749–752, 2002.
- [224] K. Rongstad, R. A. Mann, D. Prieskorn, S. Nicholson, and G. Horton, "Popliteal sciatic nerve block for postoperative analgesia," *Foot and Ankle International*, vol. 17, no. 7, pp. 378–382, 1996.
- [225] D. H. McLeod, D. H. W. Wong, R. J. Claridge, and P. M. Merrick, "Lateral popliteal sciatic nerve block compared with subcutaneous infiltration for analgesia following foot surgery," *Canadian Journal of Anaesthesia*, vol. 41, no. 8, pp. 673–676, 1994.
- [226] D. M. Grosser, M. J. Herr, R. J. Claridge, and L. G. Barker, "Preoperative lateral popliteal nerve block for intraoperative and postoperative pain control in elective foot and ankle surgery: a prospective analysis," *Foot and Ankle International*, vol. 28, no. 12, pp. 1271–1275, 2007.
- [227] B. M. Ilfeld, T. W. Wright, F. K. Enneking, and T. E. Morey, "Joint range of motion after total shoulder arthroplasty with and without a continuous interscalene nerve block: a retrospective, case-control study," *Regional Anesthesia and Pain Medicine*, vol. 30, no. 5, pp. 429–433, 2005.
- [228] M. L. De Ruyter, K. E. Brueilly, B. A. Harrison, R. A. Greengrass, J. D. Putzke, and M. P. Brodersen, "A pilot study on continuous femoral perineural catheter for analgesia after total knee arthroplasty: the effect on physical rehabilitation and outcomes," *Journal of Arthroplasty*, vol. 21, no. 8, pp. 1111–1117, 2006.
- [229] C. Raimer, K. Priem, A. A. Wiese et al., "Continuous psoas and sciatic block after knee arthroplasty: good effects compared to epidural analgesia or i.v. opioid analgesia: a

- prospective study of 63 patients,” *Acta Orthopaedica*, vol. 78, no. 2, pp. 193–200, 2007.
- [230] F. J. Singelyn, M. Deyaert, D. Joris, E. Pendeville, and J. M. Gouverneur, “Effects of intravenous patient-controlled analgesia with morphine, continuous epidural analgesia, and continuous three-in-one block on postoperative pain and knee rehabilitation after unilateral total knee arthroplasty,” *Anesthesia and Analgesia*, vol. 87, no. 1, pp. 88–92, 1998.
- [231] F. Carli, A. Clemente, J. F. Asenjo et al., “Analgesia and functional outcome after total knee arthroplasty: periarticular infiltration vs continuous femoral nerve block,” *British Journal of Anaesthesia*, vol. 105, no. 2, pp. 185–195, 2010.
- [232] B. M. Ilfeld, S. T. Ball, P. F. Gearen et al., “Health-related quality of life after hip arthroplasty with and without an extended-duration continuous posterior lumbar plexus nerve block: a prospective, 1-year follow-up of a randomized, triple-masked, placebo-controlled study,” *Anesthesia and Analgesia*, vol. 109, no. 2, pp. 586–591, 2009.
- [233] L. Kadic, M. C. Boonstra, M. C. De Waal Malefijt, S. J. Lako, J. Van Egmond, and J. J. Driessen, “Continuous femoral nerve block after total knee arthroplasty?” *Acta Anaesthesiologica Scandinavica*, vol. 53, no. 7, pp. 914–920, 2009.
- [234] B. A. Williams, Q. Dang, J. E. Bost et al., “General health and knee function outcomes from 7 days to 12 weeks after spinal anesthesia and multimodal analgesia for anterior cruciate ligament reconstruction,” *Anesthesia and Analgesia*, vol. 108, no. 4, pp. 1296–1302, 2009.
- [235] B. M. Ilfeld, R. S. Meyer, L. T. Le et al., “Health-related quality of life after tricompartment knee arthroplasty with and without an extended-duration continuous femoral nerve block: a prospective, 1-year follow-up of a randomized, triple-masked, placebo-controlled study,” *Anesthesia and Analgesia*, vol. 108, no. 4, pp. 1320–1325, 2009.
- [236] B. M. Ilfeld, J. J. Shuster, D. W. Theriaque et al., “Long-term pain, stiffness, and functional disability after total knee arthroplasty with and without an extended ambulatory continuous femoral nerve block: a prospective, 1-year follow-up of a multicenter, randomized, triple-masked, placebo-controlled trial,” *Regional Anesthesia and Pain Medicine*, vol. 36, no. 2, pp. 116–120, 2011.
- [237] C. F. Shum, N. N. Lo, S. J. Yeo, K. Y. Yang, H. C. Chong, and S. N. Yeo, “Continuous femoral nerve block in total knee arthroplasty: immediate and two-year outcomes,” *Journal of Arthroplasty*, vol. 24, no. 2, pp. 204–209, 2009.
- [238] S. E. Mason, A. Noel-Storr, and C. W. Ritchie, “The impact of general and regional anesthesia on the incidence of post-operative cognitive dysfunction and post-operative delirium: a systematic review with meta-analysis,” *Journal of Alzheimer’s Disease*, vol. 22, no. 3, pp. S67–S79, 2010.
- [239] A. Ganesh, J. B. Rose, L. Wells et al., “Continuous peripheral nerve blockade for inpatient and outpatient postoperative analgesia in children,” *Anesthesia and Analgesia*, vol. 105, no. 5, pp. 1234–1242, 2007.
- [240] B. M. Ilfeld and F. K. Enneking, “Continuous peripheral nerve blocks at home: a review,” *Anesthesia and Analgesia*, vol. 100, no. 6, pp. 1822–1833, 2005.
- [241] D. D. Denson, P. P. Raj, and F. Saldahna, “Continuous perineural infusion of bupivacaine for prolonged analgesia: pharmacokinetic considerations,” *International Journal of Clinical Pharmacology Therapy and Toxicology*, vol. 21, no. 12, pp. 591–597, 1983.
- [242] C. Gonano, S. C. Kettner, M. Ernstbrunner, K. Schebesta, A. Chiari, and P. Marhofer, “Comparison of economical aspects of interscalene brachial plexus blockade and general anaesthesia for arthroscopic shoulder surgery,” *British Journal of Anaesthesia*, vol. 103, no. 3, pp. 428–433, 2009.
- [243] B. A. Williams, M. L. Kentor, M. T. Vogt et al., “Economics of nerve block pain management after anterior cruciate ligament reconstruction: potential hospital cost savings via associated postanesthesia care unit bypass and same-day discharge,” *Anesthesiology*, vol. 100, no. 3, pp. 697–706, 2004.
- [244] A. Hadzic, B. A. Williams, P. E. Karaca et al., “For outpatient rotator cuff surgery, nerve block anesthesia provides superior same-day recovery over general anesthesia,” *Anesthesiology*, vol. 102, no. 5, pp. 1001–1007, 2005.
- [245] A. Hadzic, P. E. Karaca, P. Hobeika et al., “Peripheral nerve blocks result in superior recovery profile compared with general anesthesia in outpatient knee arthroscopy,” *Anesthesia and Analgesia*, vol. 100, no. 4, pp. 976–981, 2005.
- [246] M. J. Fredrickson and A. W. Stewart, “Continuous interscalene analgesia for rotator cuff repair: a retrospective comparison of effectiveness and cost in 205 patients from a multi-provider private practice setting,” *Anaesthesia and Intensive Care*, vol. 36, no. 6, pp. 786–791, 2008.
- [247] B. M. Ilfeld, E. R. Mariano, B. A. Williams, J. N. Woodard, and A. Macario, “Hospitalization costs of total knee arthroplasty with a continuous femoral nerve block provided only in the hospital versus on an ambulatory basis: a retrospective, case-control, cost-minimization analysis,” *Regional Anesthesia and Pain Medicine*, vol. 32, no. 1, pp. 46–54, 2007.
- [248] M. C. Pourtales, H. Kuntzmann, F. Bertrand, T. Pottecher, S. Gouzou, and P. Liverneaux, “Continuous at-home postoperative analgesia using a catheter in the case of hand surgery: preliminary study about 40 cases,” *Chirurgie de la Main*, vol. 29, no. 2, pp. 82–87, 2010.
- [249] B. M. Ilfeld, T. W. Wright, F. K. Enneking et al., “Total shoulder arthroplasty as an outpatient procedure using ambulatory prerineural local anesthetic infusion: a pilot feasibility study,” *Anesthesia and Analgesia*, vol. 101, no. 5, pp. 1319–1322, 2005.
- [250] B. M. Ilfeld, P. F. Gearen, F. K. Enneking et al., “Total hip arthroplasty as an overnight-stay procedure using an ambulatory continuous psoas compartment nerve block: a prospective feasibility study,” *Regional Anesthesia and Pain Medicine*, vol. 31, no. 2, pp. 113–118, 2006.
- [251] J. E. Bost, B. A. Williams, M. T. Bottegall, Q. Dang, and D. M. Rubio, “The 8-item Short-Form Health Survey and the physical comfort composite score of the quality of recovery 40-item scale provide the most responsive assessments of pain, physical function, and mental function during the first 4 days after ambulatory knee surgery with regional anesthesia,” *Anesthesia and Analgesia*, vol. 105, no. 6, pp. 1693–1700, 2007.
- [252] X. Capdevila, P. Pirat, S. Bringuier et al., “Continuous peripheral nerve blocks in hospital wards after orthopedic surgery: a multicenter prospective analysis of the quality of postoperative analgesia and complications in 1,416 patients,” *Anesthesiology*, vol. 103, no. 5, pp. 1035–1045, 2005.
- [253] M. Neuburger, J. Breitbarth, F. Reisig, D. Lang, and J. Büttner, “Complications and adverse events in continuous peripheral regional anesthesia. Results of investigations on 3,491 catheters,” *Anaesthesist*, vol. 55, no. 1, pp. 33–40, 2006.
- [254] S. Ganapathy, R. A. Wasserman, J. T. Watson et al., “Modified continuous femoral three-in-one block for postoperative pain after total knee arthroplasty,” *Anesthesia and Analgesia*, vol. 89, no. 5, pp. 1197–1202, 1999.

- [255] B. M. Ilfeld, S. T. Ball, P. F. Gearen et al., "Ambulatory continuous posterior lumbar plexus nerve blocks after hip arthroplasty: a dual-center, randomized, triple-masked, placebo-controlled trial," *Anesthesiology*, vol. 109, no. 3, pp. 491–501, 2008.
- [256] B. A. Williams, M. A. Bolland, S. L. Orebaugh, M. T. Bottegal, and M. L. Kentor, "Skin reactions at the femoral perineural catheter insertion site: retrospective summary of a randomized clinical trial," *Anesthesia and Analgesia*, vol. 104, no. 5, pp. 1309–1310, 2007.
- [257] M. K. Tuominen, P. Pere, and P. H. Rosenberg, "Unintentional arterial catheterization and bupivacaine toxicity associated with continuous interscalene brachial plexus block," *Anesthesiology*, vol. 75, no. 2, pp. 356–358, 1991.
- [258] V. Souron, Y. Reiland, A. De Traverse, L. Delaunay, and L. Lafosse, "Interpleural migration of an interscalene catheter," *Anesthesia and Analgesia*, vol. 97, no. 4, pp. 1200–1201, 2003.
- [259] J. Rodríguez, M. Taboada, M. Blanco, J. Oliveira, M. Bárcena, and J. Alvarez, "Intraneural catheterization of the sciatic nerve in humans: a pilot study," *Regional Anesthesia and Pain Medicine*, vol. 33, no. 4, pp. 285–290, 2008.
- [260] A. Faust, R. Fournier, O. Hagon, P. Hoffmeyer, and Z. Gamulin, "Partial sensory and motor deficit of ipsilateral lower limb after continuous interscalene brachial plexus block," *Anesthesia and Analgesia*, vol. 102, no. 1, pp. 288–290, 2006.
- [261] B. Lekhak, C. Bartley, I. D. Conacher, and S. M. Nouraei, "Total spinal anaesthesia in association with insertion of a paravertebral catheter," *British Journal of Anaesthesia*, vol. 86, no. 2, pp. 280–282, 2001.
- [262] R. M. Pousman, Z. Mansoor, and D. Sciard, "Total spinal anesthetic after continuous posterior lumbar plexus block," *Anesthesiology*, vol. 98, no. 5, pp. 1281–1282, 2003.
- [263] R. J. Litz, O. Vicent, D. Wiessner, and A. R. Heller, "Misplacement of a psoas compartment catheter in the subarachnoid space," *Regional Anesthesia and Pain Medicine*, vol. 29, no. 1, pp. 60–64, 2004.
- [264] C. R. Jenkins and M. K. Karmakar, "An unusual complication of interscalene brachial plexus catheterization: delayed catheter migration," *British Journal of Anaesthesia*, vol. 95, no. 4, pp. 535–537, 2005.
- [265] W. Harrop-Griffiths, N. Denny, H. Jutzi et al., "Migration of interscalene catheter—not proven," *British Journal of Anaesthesia*, vol. 96, no. 2, pp. 266–267, 2006.
- [266] V. Compère, J. F. Legrand, P. G. Guitard et al., "Bacterial colonization after tunneling in 402 perineural catheters: a prospective study," *Anesthesia and Analgesia*, vol. 108, no. 4, pp. 1326–1330, 2009.
- [267] P. Cuvillon, J. Ripart, L. Lalourcey et al., "The continuous femoral nerve block catheter for postoperative analgesia: bacterial colonization, infectious rate and adverse effects," *Anesthesia and Analgesia*, vol. 93, no. 4, pp. 1045–1049, 2001.
- [268] M. Neuburger, J. Büttner, S. Blumenthal, J. Breitbart, and A. Borgeat, "Inflammation and infection complications of 2285 perineural catheters: a prospective study," *Acta Anaesthesiologica Scandinavica*, vol. 51, no. 1, pp. 108–114, 2007.
- [269] X. Capdevila, S. Bringuier, and A. Borgeat, "Infectious risk of continuous peripheral nerve blocks," *Anesthesiology*, vol. 110, no. 1, pp. 182–188, 2009.
- [270] G. Ekatodramis and A. Borgeat, "Subcutaneous tunneling of the interscalene catheter," *Canadian Journal of Anaesthesia*, vol. 47, no. 7, pp. 716–717, 2000.
- [271] S. R. Clendenen, C. B. Robards, R. D. Wang, and R. A. Greengrass, "Continuous interscalene block associated with neck hematoma and postoperative sepsis," *Anesthesia and Analgesia*, vol. 110, no. 4, pp. 1236–1238, 2010.
- [272] X. Capdevila, S. Jaber, P. Pesonen, A. Borgeat, and J. J. Eledjam, "Acute neck cellulitis and mediastinitis complicating a continuous interscalene block," *Anesthesia and Analgesia*, vol. 107, no. 4, pp. 1419–1421, 2008.
- [273] A. Borgeat, G. Ekatodramis, F. Kalberer, and C. Benz, "Acute and nonacute complications associated with interscalene block and shoulder surgery," *Anesthesiology*, vol. 95, no. 4, pp. 875–880, 2001.
- [274] M. Wiegel, U. Gottschaldt, R. Hennebach, T. Hirschberg, and A. Reske, "Complications and adverse effects associated with continuous peripheral nerve blocks in orthopedic patients," *Anesthesia and Analgesia*, vol. 104, no. 6, pp. 1578–1582, 2007.
- [275] A. Dullenkopf, P. Zingg, A. Curt, and A. Borgeat, "Persistent neurological deficit of the upper extremity after a shoulder operation under general anaesthesia combined with a preoperatively placed interscalene catheter," *Anaesthetist*, vol. 51, no. 7, pp. 547–551, 2002.
- [276] J. R. Hebl, J. A. Dilger, D. E. Byer et al., "A pre-emptive multimodal pathway featuring peripheral nerve block improves perioperative outcomes after major orthopedic surgery," *Regional Anesthesia and Pain Medicine*, vol. 33, no. 6, pp. 510–517, 2008.
- [277] B. D. Bergman, J. R. Hebl, J. Kent, and T. T. Horlocker, "Neurologic complications of 405 consecutive continuous axillary catheters," *Anesthesia and Analgesia*, vol. 96, no. 1, pp. 247–252, 2003.
- [278] S. Dhir, S. Ganapathy, P. Lindsay, and G. S. Athwal, "Case report: ropivacaine neurotoxicity at clinical doses in interscalene brachial plexus block," *Canadian Journal of Anesthesia*, vol. 54, no. 11, pp. 912–916, 2007.
- [279] V. Compère, N. Rey, O. Baert et al., "Major complications after 400 continuous popliteal sciatic nerve blocks for postoperative analgesia," *Acta Anaesthesiologica Scandinavica*, vol. 53, no. 3, pp. 339–345, 2009.
- [280] Q. Hogan, R. Dotson, S. Erickson, R. Kettler, and K. Hogan, "Local anesthetic myotoxicity: a case and review," *Anesthesiology*, vol. 80, no. 4, pp. 942–947, 1994.
- [281] R. Werdehausen, S. Fazeli, S. Braun et al., "Apoptosis induction by different local anaesthetics in a neuroblastoma cell line," *British Journal of Anaesthesia*, vol. 103, no. 5, pp. 711–718, 2009.
- [282] J. S. Kroin, A. Buvanendran, D. K. Williams et al., "Local anesthetic sciatic nerve block and nerve fiber damage in diabetic rats," *Regional Anesthesia and Pain Medicine*, vol. 35, no. 4, pp. 343–350, 2010.
- [283] B. A. Williams and B. B. Murinson, "Diabetes mellitus and subclinical neuropathy: a call for new paths in peripheral nerve block research," *Anesthesiology*, vol. 109, no. 3, pp. 361–362, 2008.
- [284] S. Blumenthal, A. Borgeat, K. Maurer et al., "Preexisting subclinical neuropathy as a risk factor for nerve injury after continuous ropivacaine administration through a femoral nerve catheter," *Anesthesiology*, vol. 105, no. 5, pp. 1053–1056, 2006.
- [285] H. M. Nguyen and A. L. Goldin, "Sodium channel carboxyl-terminal residue regulates fast inactivation," *Journal of Biological Chemistry*, vol. 285, no. 12, pp. 9077–9089, 2010.

- [286] S. England, "Voltage-gated sodium channels: the search for subtype-selective analgesics," *Expert Opinion on Investigational Drugs*, vol. 17, no. 12, pp. 1849–1864, 2008.
- [287] J. Lai, F. Porreca, J. C. Hunter, and M. S. Gold, "Voltage-gated sodium channels and hyperalgesia," *Annual Review of Pharmacology and Toxicology*, vol. 44, pp. 371–397, 2004.
- [288] E. A. Shipton, "New formulations of local anaesthetics-Part i," *Anesthesiology Research and Practice*, vol. 2012, Article ID 546409, 11 pages, 2012.
- [289] S. A. Grant, "The Holy Grail: long-acting local anaesthetics and liposomes," *Best Practice and Research: Clinical Anaesthesiology*, vol. 16, no. 2, pp. 345–352, 2002.
- [290] P. Mura, F. Maestrelli, M. L. González-Rodríguez, I. Michelacci, C. Ghelardini, and A. M. Rabasco, "Development, characterization and in vivo evaluation of benzocaine-loaded liposomes," *European Journal of Pharmaceutics and Biopharmaceutics*, vol. 67, no. 1, pp. 86–95, 2007.
- [291] C. F. Weiniger, M. Golovanevski, M. Sokolsky-Papkov, and A. J. Domb, "Review of prolonged local anesthetic action," *Expert Opinion on Drug Delivery*, vol. 7, no. 6, pp. 737–752, 2010.
- [292] G. J. Grant, Y. Barenholz, E. M. Bolotin et al., "A novel liposomal bupivacaine formulation to produce ultralong-acting analgesia," *Anesthesiology*, vol. 101, no. 1, pp. 133–137, 2004.
- [293] J. G. Boogaerts, N. D. Lafont, A. G. Declercq et al., "Epidural administration of liposome-associated bupivacaine for the management of postsurgical pain: a first study," *Journal of Clinical Anesthesia*, vol. 6, no. 4, pp. 315–320, 1994.
- [294] B. R. Swenson, A. Gottschalk, L. T. Wells et al., "Intravenous lidocaine is as effective as epidural bupivacaine in reducing ileus duration, hospital stay, and pain after open colon resection: a randomized clinical trial," *Regional Anesthesia and Pain Medicine*, vol. 35, no. 4, pp. 370–376, 2010.
- [295] G. S. De Oliveira, S. Ahmad, J. C. Schink, D. K. Singh, P. C. Fitzgerald, and R. J. McCarthy, "Intraoperative neuraxial anesthesia but not postoperative neuraxial analgesia is associated with increased relapse-free survival in ovarian cancer patients after primary cytoreductive surgery," *Regional Anesthesia and Pain Medicine*, vol. 36, no. 3, pp. 271–277, 2011.